

Role of doxycycline to resolve different types of non-malignant lung and pleural pathology: The results of a pilot observation

Parthasarathi Bhattacharyya, Rana Dey, Dipanjan Saha, Saikat Nag, Subhasish Ghosh, Sushmita Roy Chowdhury, Dhiman Ganguly

Department of Clinical pulmonary medicine, Institute of Pulmocare and Research, Kolkata, West Bengal, India

ABSTRACT

Background: Lung lesions may develop from tissue reactions to known or unknown stimuli and present with different morphological descriptions. The pathogenesis may be induced and maintained by different bioactive substances, of which, the upregulation matrix metalloproteinases (MMPs) play a vital role. Inhibition of the MMPs, therefore, may be a prospective mode of therapy for such lesions. **Materials and Methods:** A number of patients with lung lesions of different morphologies and presentations were treated empirically with long-term oral doxycycline (100 mg BID) upon exclusion of malignancy and infection in an open, single-arm, prospective, observational pilot study. The effect of the treatment was recorded on serial x-rays/computed tomography (CT) scans and the impact of treatment was measured with a visual analog scale (VAS) or a Likert-like scale. Furthermore, six independent pulmonologists' opinion (expressed on a '0' to '100' scale) were pooled with regard to the significance and the expectedness of such a change. **Results:** Twenty-six patients (mean age 49.33 years and male: female ratio = 10:3) with different types of pulmonary parenchymal/pleural lesions were treated with long-term oral doxycycline for a mean duration of 386.88 days related to the available radiological comparison. They showed a mean improvement of 3.99 on the Likert-like scale and 78% on the VAS scale. The mean significance of the change was 83.33%, with a mean expectedness of 18% as per the pooled opinion of the pulmonologists. **Inference:** The significant and unexpected resolution of different tissue lesions from long-term doxycycline appears to be a novel observation. This needs proper scientific validation.

KEY WORDS: Doxycycline, lung lesions, matrix metalloproteinase

Address for correspondence: Dr. Parthasarathi Bhattacharyya, AK 46, Salt Lake, Sector II, Kolkata - 700 091, West Bengal, India. E-mail: parthachest@yahoo.com

INTRODUCTION

Different types of lung and pleural lesions are encountered by clinicians, often without any defined etiology or even, at times, without a clear-cut pathological diagnosis. They are usually radiologically described, evaluated, observed, and followed up, while the patients are often left untreated to move from one doctor to another or are convinced to stay with the lesion with or without any

symptoms and/or functional jeopardy. Here we present a series of such patients showing consistent improvement on long-term doxycycline therapy, which had been offered as a non-specific anti-MMP agent,^[1,2] to treat such lung lesions.

MATERIALS AND METHODS

Patients with lung or pleural lesions attending a tertiary outpatient services in Kolkata (IPCR) were screened by a single consultant to include them in the prospective single-arm pilot observational study when their pulmonary/pleural lesions appeared to: (a) persist despite whatever treatment had been given and/or (b) develop as a known sequel of the disease (viz., tuberculosis). The lesions were first described morphologically on a chest x-ray (posteroanterior (PA) view), and thereafter, those with a suspicion of malignancy were evaluated with selected high-resolution computed tomography (HRCT)

Access this article online	
Quick Response Code: 	Website: www.lungindia.com
	DOI: 10.4103/0970-2113.148447

cuts and concomitant tissue sampling through CT-guided fine needle aspiration cytology (FNAC) or bronchoscopic needle aspiration. Simultaneously, the possibility of the presence of active infection and/or the likely infective origin was assessed clinically (with symptoms such as fever, cough, purulent expectorations), and also with a routine hemogram, HRCT chest and sputum or tissue sampling, as and when possible and when deemed essential. Patients with confirmed or suspected malignancy and those with suspected infective origin of the lesions were outright excluded from the study along with those having a history of intolerance to doxycycline. Upon availability of a proper informed written consent, these patients were given oral doxycycline (100 mg once or twice daily for body weight below or over 40 kg), to take for long-term on a prospective protocol that had been approved by the Institutional Ethics Committee (IEC). The patients were clinicoradiologically followed up and the medication was continued upon demonstration of signs of improvement on at least three months of therapy. Some of the patients were continued with the medication when they had a feeling of subjective well-being, while showing no change on radiological evaluation till a follow-up period of up to six months.

The lesions were categorized according to the morphological descriptions apparent on x-ray pictures as, scar/fibrosis, mass/mass-like lesion, pleural thickening, solitary pulmonary nodules, and so on. The investigator had the complete freedom to stop the medication when he felt that maximum improvement had already taken place. The study protocol was discussed with all the patients, including side effects of doxycycline, and they were instructed to report on the development of any sure or suspected side effects. Those who accepted and complied with the proposed pharmacological intervention were then assessed for radiological improvement, based on the Likert-like scale of scoring the change on a 0-5 scale; (no improvement as '0' and total clearance as '5') and also on a visual analog scale (VAS) ranging from 0 to 100.

The data available was subsequently analyzed. Six different experienced pulmonologists each practicing over at least 10 years were then allowed to view all or at least six patient's radiological changes randomly and then score the significance of the improvement on a '0' to '100' scale. They were also requested to offer a scoring regarding the expectedness of such change on a similar scale (on the natural course and on any existing treatment separately).

RESULTS

A total of 34 patients were included; of them, one developed gastrointestinal intolerance and had to stop doxycycline, three were excluded for suspected infective origin on review after initial inclusion, and four lost to follow up. Telephonic enquiry made to the last group revealed that they did not have any side effects, two had themselves stopped the medicine after a variable length of time and

the other two had been advised to stop doxycycline by some other doctor. The calculation, therefore, was possible with the data from 26 patients [Table 1]. All these patients on oral doxycycline had shown improvement (mean 3.99 in the Likert-like scale and 78% on the VAS: See Table 1) on comparison of the two x-rays done in a gap of a mean duration of 386.88 days.

The maximum improvement has been found in cases with parapneumonic effusions, followed by nodules and mass and mass-like lesions with the changes been scored as 4.8, 4.5, and 4.41 respectively on the Likert-like scale and 91%, 88% and 90% on VAS. Picture one depicts the morphological changes in the serial x-rays [Figure 1].

The pooled opinion of the six expert pulmonologists showed the changes to be significant to the tune of 83.33% (*>60% was arbitrarily taken as significant*). Regarding the expectedness of such changes, one expert expressed that he could not say anything, while the other five opined it to be less than 18% and 25%, respectively, without and with some treatment (where over 40% of the expectedness was arbitrarily decided as 'significant').

DISCUSSION

Unresolved lung or pleural lesions on a chest x-ray, following infective or unknown insult, is not uncommon in clinical practice. The prevailing practice mandates to exclude malignancy in them even with the slightest suspicion, and thereafter, observe a lesion for future trend, unless it is suspected to be of infective origin. There has been no recommended treatment or guideline available for these lesions and both the patients and the physicians are left with a choice of accepting the abnormality to stay in the lungs for long term/lifelong, with a variable degree of symptoms and functional jeopardy with unknown prospect of any spontaneous resolution or subject it to surgical resection, especially when it is localized and respectable, as in pleural thickening or a lung nodule.

All the lesions selected in our series were, therefore, in the category of 'unlikely to resolve' and 'unlikely to be malignant or infective in origin,' where the clinician decided to prescribe doxycycline instead of simply observing them (over years) on a prospective fashion, which allowed follow up and repeat evaluation on a relatively 'soft' protocol according to the convenience of the patients. This was done in a pulmonologist's real world practice. The possibility of malignancy were practically excluded with CT-guided aspiration cytology or transbronchial needle aspiration cytology, whenever applicable (nodules, mass, mass-like lesions, and organized lesions).

The improvement in all categories of our patients have been impressive with over 80% resolution in parapneumonic pleural thickening, nodules, and mass or mass-like lesions. The rest of the lesions too had over 60% resolution on VAS.

Table 1: Different types of lesions and different degrees of resolution with long-term oral doxycycline therapy

Category	Type	No. of patients	Average Age (years)	Male: Female	Duration between x-rays (Days)	Average improvement in Likert-like scale (0 to 5)	Average improvement in visual scale %
(A)	Scar+fibrosis	6	56.66	5:1	418	3.58	68
(B)	Mass or mass-like	6	46	6:0	606	4.41	90
(C)	Organized lesion	2	59.5	2:0	215	3.25	73
(D)	Pleural thickening	3	27.5	2:1	295	4.02	77
(E)	Nodule	4	58.5	2:2	301	4.5	88
(F)	Others	1	68	1:0	468	0	0
(G)	Paraneumonic effusion	4	38	2:2	233	4.8	91
Total		26	49.33±18.30	10:3	386.88±282.19	3.99±1.23	78.46±24.32

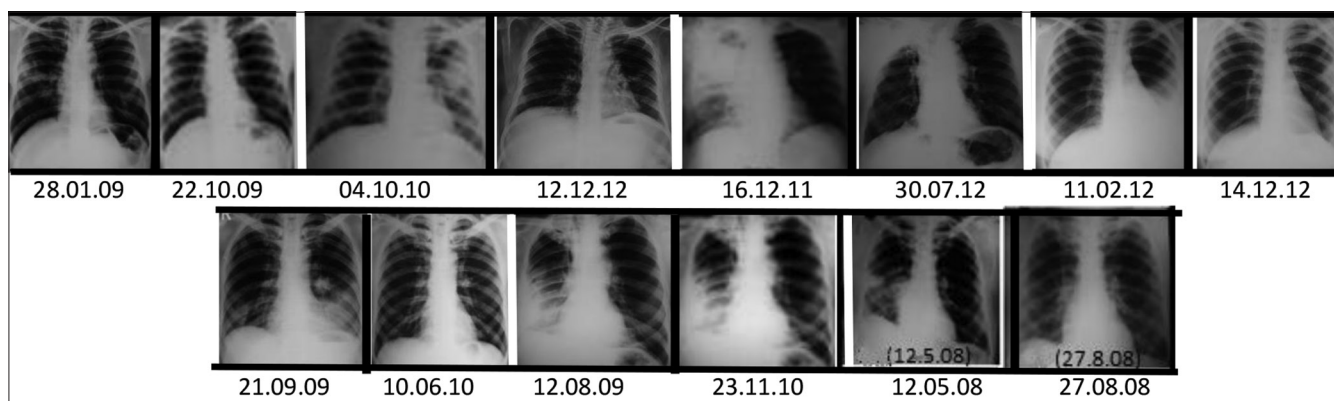


Figure 1: The picture elaborates the examples of changes in the different morphological lesions on long-term use of doxycycline. Each pair of photos of the x-rays (demarcated from the next by white bar) shows the change in each type of lesion that has been cured or reduced, except the case (second from the left at the lower panel) that did not show any change

The overall improvement in all the types had a mean of 3.99 ± 1.23 on Likert-like scale and 78.46 ± 24.32 on the VAS. The change in VAS correlated to the change assessed by the Likert-like scale. There was also a parallel clinical improvement in the patients who had symptoms (pleuritic chest pain, vague tightness, and cough in occasional patients) relating to the pathology. As we had no control arm to assess the quality and the quantity of the change, we adopted a novel method to pool the opinion of six local experts (pulmonologists with postgraduate qualifications and over 10 years of practice experience) regarding the perceived significance of the change, on a scale of zero to hundred, keeping them blind about the treatment modality. We also asked them to randomly score their expectedness of resolution on the natural course and on any intervention, again on a scale of zero to hundred. The pooled result showed that the changes seen were significant to the tune of 83.33%, with the expectedness of such a change being barely 18% if the lesions were left untreated. Thus, the pooled opinion supported our view that the changes observed from treatment with long-term oral doxycycline in these different types of lung lesions had been significant, despite having no control group to compare it with. The only case that did not show any improvement had extensive pleural calcification [Figure 2]; the patient had a pleural effusion in the past, without any clear-cut history and no pertinent investigation was available. Possibly a calcified lesion was resistant to the observed re-remodeling by long-term doxycycline therapy.

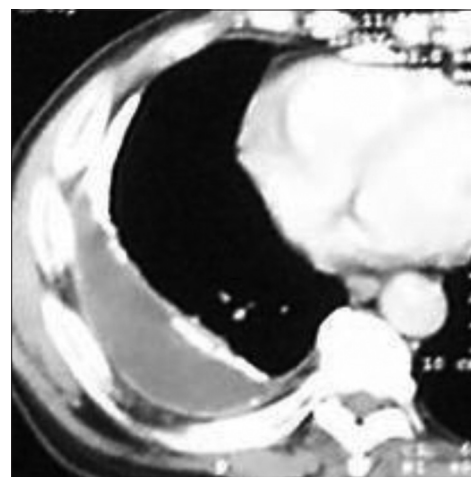


Figure 2: The CT cut of the thorax at the lower lung field (mediastinal window) showing thickening of the pleura and calcification both at the parietal and the visceral surfaces. This patient did not respond to oral doxycycline given for slightly over six months

People may wonder why we used doxycycline to treat these cases. Fortunately, by the time the patients presented to us, we were already engaged in utilizing the anti-MMP properties of doxycycline for the treatment of Idiopathic pulmonary fibrosis (IPF).^[1] Our initial review of literature had given an insight that the agent could be useful in tissue remodeling and treatment of apparently different unexplained non-malignant lesions. Now, we

know that the drug has many more properties such as anti-angiogenesis,^[2,3] apart from its inhibitory effects on fibrogenesis.^[4] MMPs function as regulatory enzymes in the pathways of tissue injury, inflammatory disorders, malignancies, and remodeling of the lung.^[5] Moreover, MMP inhibition has been regarded as a target of therapy for many conditions, such as, IPF, Chronic obstructive pulmonary disease (COPD), and asthma. MMP inhibition may possibly play a role in pro-apoptotic activities too.^[6] It is not clear how the MMPs play a role in tissue organization from different known and unknown stimuli/insults and how different morphological lesions appear without the apparent presence of infection or malignancy. However, this is clear from the available evidence that probably no pathology can ensue or continue without the participation of this enzyme system being dysregulated.^[7]

Although it looks attractive to postulate the anti-MMPs hypothesis for making the changes with long-term doxycycline, it is still possible that the anti-infective property of the agent has been responsible for the observed improvement. Doxycycline has a broad spectrum of anti-bacterial activities and one may postulate that atypical organisms could be responsible for the aberrant tissue reaction in the lungs, such as a nodule, mass, or mass-like lesions. However, even though the postulation itself can be questioned, we have not done an adequate workup for infection, especially for atypical pathogens. Had the lesions been simply an infective sequel, the resolution should have taken only a few weeks and not months together as has been seen in our observation. Thus, it appears likely that the anti-MMPs property of doxycycline may be the main mechanism in resolving the lesions, although we have not tried to demonstrate it in the affected tissue, before and after administration of the agent. Incidentally, there are certain rare entities that can project radiologically as a nodule or mass; they may be listed as minute meningothelial nodules, nodular lymphoid hyperplasia, inflammatory pseudotumor, localized organizing pneumonia, nodular amyloid, hyalinising granuloma, bronchial inflammatory polyp, micronodular pneumocyte hyperplasia, endometriosis, round atelectasis, and so on.^[8] In our series, most of them do not morphologically match the patients and the cytological examinations, which makes these rare entities all the more unlikely. Although inflammatory pseudotumor and localized organizing pneumonia can be possible in one or two cases, it will be an interesting observation to see them resolved with long-term doxycycline. This facet appears novel and needs serious future research.

There may be ethical questions about the rationale and the long-term use of the drug, doxycycline. First, it is used long-term in several conditions, with an excellent safety record^[9-13] and the molecule has been in the market for over 30 years, with the physicians having had a vast experience with it. Second, it has a non-specific anti-MMPs property^[14-16] that has been utilized for the

treatment of periodontal disease as an US Food and Drug Association (FDA)-approved indication.^[17]

There are points to criticize the presentation. However, despite major limitations, such as, absence of the control arm and having no effort to prove the hypothesis of doxycycline inhibiting the MMPs locally in our patients, the observation appears unique with its potential to open up a new prospect of treating such apparently unexplained lesions in future.

REFERENCES

- Bhattacharyya PS, Nag S, Ghosh D, Chowdhury SR, Bardhan S, Mukherjee A. Treatment of probable idiopathic pulmonary fibrosis with long term doxycycline, a matrix metalloproteinase inhibitor. *Indian J Chest Dis Allied Sci* 2007;49:180.
- Strieter RM, Belperio JA, Keane MP. CXC chemokines in angiogenesis related to pulmonary fibrosis. *Chest*2002;122 Suppl 6:298S-301S.
- Stetler-Stevenson WG. Matrix metalloproteinases in angiogenesis: A moving target for therapeutic intervention. *J Clin Invest* 1999;103:1237-11.
- Pardo A, Selman M. Matrix metalloproteases in aberrant fibrotic tissue remodeling. *Proc Am Thorac Soc*2006;3:383-8.
- Borcuk AC. Benign tumors and tumorlike conditions of the lung. *Arch Pathol Lab Med* 2008;132:1133-48.
- Nyormoi O, Mills L, Bar-Eli M. An MMP-2/MMP-9 inhibitor, 5a, enhances apoptosis induced by ligands of the TNF receptor superfamily in cancer cells. *Cell Death Differ* 2003;10:558-69.
- Müller-Quernheim J. MMPs are regulatory enzymes in pathways of inflammatory disorders, tissue injury, malignancies and remodelling of the lung. *Eur Respir J* 2011;38:12-4.
- McCawley LJ, Matrisian LM. Matrix metalloproteinases: They're not just for matrix anymore! *Curr Opin Cell Biol*2001;13:534-40.
- Ginns LC, Roberts DH, Mark EJ, Bruschi JL, Marler JJ. Pulmonary Capillary hemangiomatosis with atypical endotheliomatosis: Successful antiangiogenic therapy with doxycycline. *Chest* 2003;124:2017-22.
- Calza L, Attard L, Manfredi R, Chiodo F. Doxycycline and chloroquine as treatment for chronic Q fever endocarditis. *J Infect* 2002;45:127-9.
- Raoult D, Houpiakian P, Tissot Dupont H, Riss JM, Arditi-Djiane J, Brouqui P. Treatment of Q fever endocarditis: Comparison of 2 regimens containing doxycycline and ofloxacin or hydroxychloroquine. *Arch Intern Med*1999;159:167-73.
- G: \Doxy Use\NaTHNaCfrequently Asked Questions on Malaria Prevention, Health Professionals.htm Advisory Committee for Malaria Prevention (ACMP). Available from: http://www.hpa.org.uk/infections/topics_az/malaria/.
- Bhattacharyya P, Nag S, Bardhan S, Acharya D, Paul R, Dey R, *et al.* The role of long-term doxycycline in patients of idiopathic pulmonary fibrosis: The results of an open prospective trial. *Lung India* 2009;26:81-5.
- Pires PW, Rogers CT, McClain JL, Garver HS, Fink GD, Dorrance AM. Doxycycline, a matrix metalloprotease inhibitor, reduces vascular remodelling and damage after cerebral ischemia in stroke-prone spontaneously hypertensive rats. *Am J Physiol Heart Circ Physiol* 2011;301:H87-97.
- Ren S, Guo LL, Yang J, Liu DS, Wang T, Chen L, *et al.* Doxycycline attenuates acrolein-induced mucin production, in part by inhibiting MMP-9. *Eur J Pharmacol* 2011;650:418-23.
- Kaito K, Urayama H, Watanabe G. Doxycycline treatment in a model of early abdominal aortic aneurysm. *Surg Today* 2003;33:426-33.
- Golub LM, Lee HM, Ryan ME, Giannobile WV, Payne J, Sorsa T. Tetracyclines inhibit connective tissue breakdown by multiple non-antimicrobial mechanisms. *Adv Dent Res* 1998;12:12-26.

How to cite this article: Bhattacharyya P, Dey R, Saha D, Nag S, Ghosh S, Chowdhury SR, *et al.* Role of doxycycline to resolve different types of non-malignant lung and pleural pathology: The results of a pilot observation. *Lung India* 2015;32:40-3.

Source of Support: Nil, **Conflict of Interest:** None declared.