

Revisional Percutaneous Full Endoscopic Disc Surgery for Recurrent Herniation of Previous Open Lumbar Discectomy

Kyung Hyun Shin¹, Ho-Guen Chang², Nam Kyou Rhee¹, Kwahn Sue Lim¹

¹Department of Orthopaedic Surgery, Shin Hospital, Suwon, Korea

²Department of Spine Surgery, Hangang Sacred Heart Hospital, Hallym University College of Medicine, Seoul, Korea

Study Design: A retrospective study.

Purpose: To determine the feasibility and effectiveness of revisional percutaneous full endoscopic discectomy for recurrent herniation after conventional open disc surgery.

Overview of the Literature: Repeated open discectomy with or without fusion has been the most common procedure for recurrent lumbar disc herniation. Percutaneous endoscopic lumbar discectomy for recurrent herniation has been thought of as an impossible procedure. Despite good results with open revisional surgery, major problems may be caused by injuries to the posterior stabilized structures. Our team did revisional full endoscopic lumbar disc surgery on the basis of our experience doing primary full endoscopic disc surgery.

Methods: Between February 2004 and August 2009 a total of 41 patients in our hospital underwent revisional percutaneous endoscopic lumbar discectomy using a YESS endoscopic system and a micro-osteotome (designed by the authors). Indications for surgery were recurrent disc herniation following conventional open discectomy; with compression of the nerve root revealed by Gadolinium-enhanced magnetic resonance imaging; corresponding radiating pain which was not alleviated after conservative management over 6 weeks. Patients with severe neurologic deficits and isolated back pain were excluded.

Results: The mean follow-up period was 16 months (range, 13 to 42 months). The visual analog scale for pain in the leg and back showed significant post-treatment improvement ($p < 0.001$). Based on a modified version of MacNab's criteria, 90.2% showed excellent or good outcomes. There was no measurable blood loss. There were two cases of recurrence of and four cases with complications.

Conclusions: Percutaneous full-endoscopic revisional disc surgery without additional structural damage is feasible and effective in terms of there being less chance of fusion and bleeding. This technique can be an alternative to conventional repeated discectomy.

Key Words: Endoscopic discectomy, Interlaminar discectomy, Transforaminal discectomy, Percutaneous discectomy, Recurrent disc herniation, Lumbar spine

Introduction

Recurrent herniation has been reported in 5-11% of

patients after disc excision, and represents a major cause of surgical failure. Recent experience indicates that the outcome of the revision surgery for the treatment of recurred disc herniation is favorable [1-5]. However, the surgical

Received May 22, 2010; 1st Revised Aug 1, 2010; 2nd Revised Sep 13, 2010; Accepted Oct 5, 2010

Corresponding author: **Kyung-Hyun Shin, MD, PhD**

Department of Orthopaedic Surgery, Shin Hospital, 45 Gosaek-dong, Gwonseon-gu, Suwon 441-805, Korea

Tel: +82-10-8709-6682, Fax: +82-31-294-0872, E-mail: osshin312@daum.net

* Portion of this work were presented in abstract form at the APOA (Asian Pacific Orthopaedic Association), Jeju, Korea, June 7, 2008.

options for the treatment of recurrent lumbar disc herniation are still not standardized. In particular, the advantages of repeated disc excision alone or disc excision with fusion is controversial [6]. Although many authors have recommended a repeated discectomy, that could produce less satisfactory results than the primary operations, and approach-related complications could develop [7]. Scar tissue makes a repeated discectomy more difficult, increasing the risk of dural tear or nerve injury. Further removal of posterior structures, including the facet joint, could increase the risk of segmental instability. In recent years, a number of percutaneous endoscopic procedures for lumbar disc herniation have been developed to allow minimally invasive spine surgery that has clinical outcomes comparable to those of conventional open surgery [8-14]. Percutaneous endoscopic lumbar discectomy (PELD) as revisional surgery for recurrent disc herniation has been thought of as an impossible procedure. Ruetten et al. commented that revision surgery can be conducted using the full endoscopic transforaminal and interlaminar discectomy after percutaneous endoscopic discectomy as the index operation [11,15-17]. However, there have been few previous studies on the outcomes of endoscopic discectomy for recurrent lumbar disc herniation after open discectomy as the index operation [18,19]. The purpose of this study was to determine the feasibility and effects of revisional PELD after open discectomy.

Materials and Methods

1. Patient characteristics

Between February 2004 to August 2009 a total of 41 patients underwent revisional PELD in our hospital. There were 13 female and 28 male patients. Their ages ranged from 25 to 70 years (mean, 42.9 years). All patients presented with clinically significant symptomatic recurrent disc herniation following previous open disc surgery and the herniation was confirmed by gadolinium-enhanced magnetic resonance (MR) imaging [20]. Indications for surgery were (i) intractable pain that had not responded to conservative management over 6 weeks and (ii) recurrent disc herniation with compression of nerve root confirmed by MR imaging. The duration of pain-free intervals after previous open disc surgery ranged from 7 months to 13 years. All operations were performed under general anesthesia. Thirty-two patients (78%) underwent an interlaminar procedure

and 9 (22%) had a transforaminal procedure. The number of operations at different spinal levels was: 1 at L2-3, 1 at L3-4, 26 at L4-5, and 13 at L5-S1. Interlaminar approaches were done for all cases at L2-3 and L5-S1, and 18 were done at L4-5. The number of transforaminal approaches were: 1 at L3-4 and 8 at L4-5. The authors took an interlaminar approach when ruptured fragments were located in the lateral recess, and took a transforaminal approach when herniations were located at disc level, or when they were central or somewhat proximal to disc level. In L5-S1 lesions, an interlaminar approach was inevitable because of anatomical features. We excluded patients with cauda equina syndrome, combined spinal stenosis, severe neurologic deficits, instability or isolated back pain.

2. Postoperative outcome evaluation

Postoperative outcomes were evaluated using modified MacNab's criteria, and visual analog scales (VAS) for leg and back pain. All patients were notified of their follow up and we received answers to our questionnaires by telephone. The VAS-derived leg and back scores were checked preoperatively and at the last follow-up. According to the modified MacNab's criteria, excellent or good were both defined as successful outcomes. Statistical analysis was done using a paired *t*-test, for which *p*-values less than 0.05 were considered statistically significant.

3. Surgical technique: interlaminar approach

The portal site was determined at the intersection of (i) the medial interpedicular line on a posteroanterior (PA) view and (ii) a line parallel to the lower vertebral upper end plate on a lateral fluoroscopy view (Fig. 1). An 8 mm skin incision was made on the portal site with the patient in the prone position on a radiolucent Wilson frame. An obturator is inserted bluntly. Soft tissue and bony margin of previous laminectomy window can be palpated with blunt obturator tip. Working sleeve is slid over the obturator and endoscope were sequentially inserted into the working sleeve. The surgeon was able to palpate and discriminate scar tissue and the bony margin of the previous laminectomy window. Scar tissues from the bony margin at the superolateral corner of the previous laminectomy window was removed with an endoscopic punch and radiofrequency (RF) waves. Then, an additional partial laminotomy at the superolateral corner of the previous laminectomy window was done with a 2

mm micro-osteotome (Fig. 2). With the aid of a clear endoscopic view, this can be performed safely and without difficulty. A relatively clear endoscopic operating field can be maintained by controlling bleeding using RF and hydrostatic cold water pressure. A small rent between bone and scar tissue in the superolateral corner was a landmark for the site at which the dissection was begun. Dissection with a sharp freer and an endoscopic curett along the bony margin was continued proximally along the bony margin until the nor-

mal epidural fat was found. After identifying the epidural fat, the surgeon dissected the epidural scar tissue cranially, caudally and somewhat medially to detect ruptured disc fragments. Usually recurring fragments were walled-off by hard scar tissue and had not migrated far (Fig. 3).

4. Surgical technique: transforaminal approach

With the patient in the prone position on the radiolucent

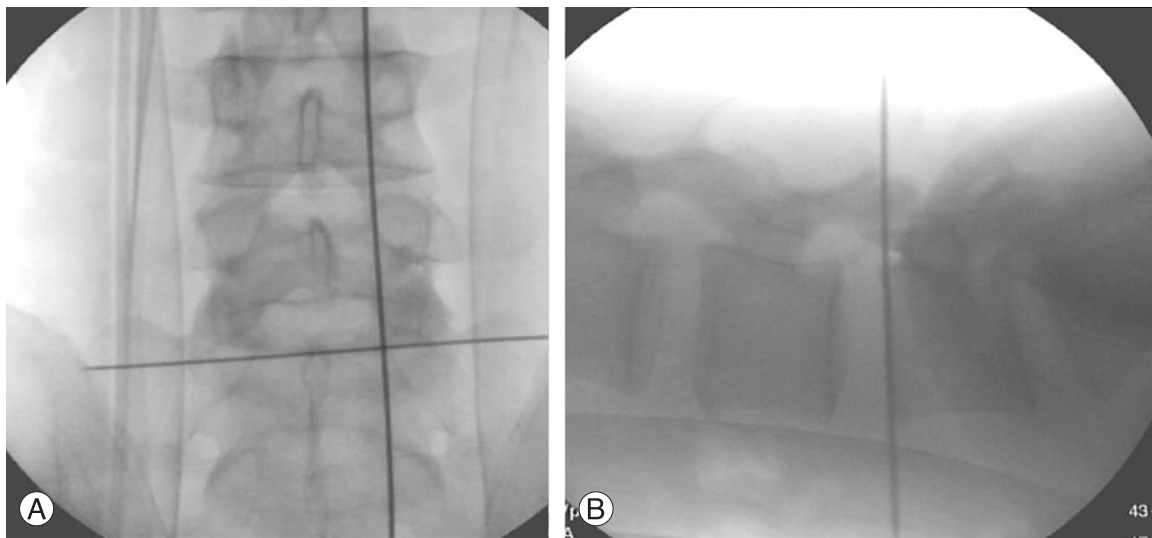


Fig. 1. Intraoperative C-arm images posteroanterior view (A) and lateral view (B) with interlaminar access.

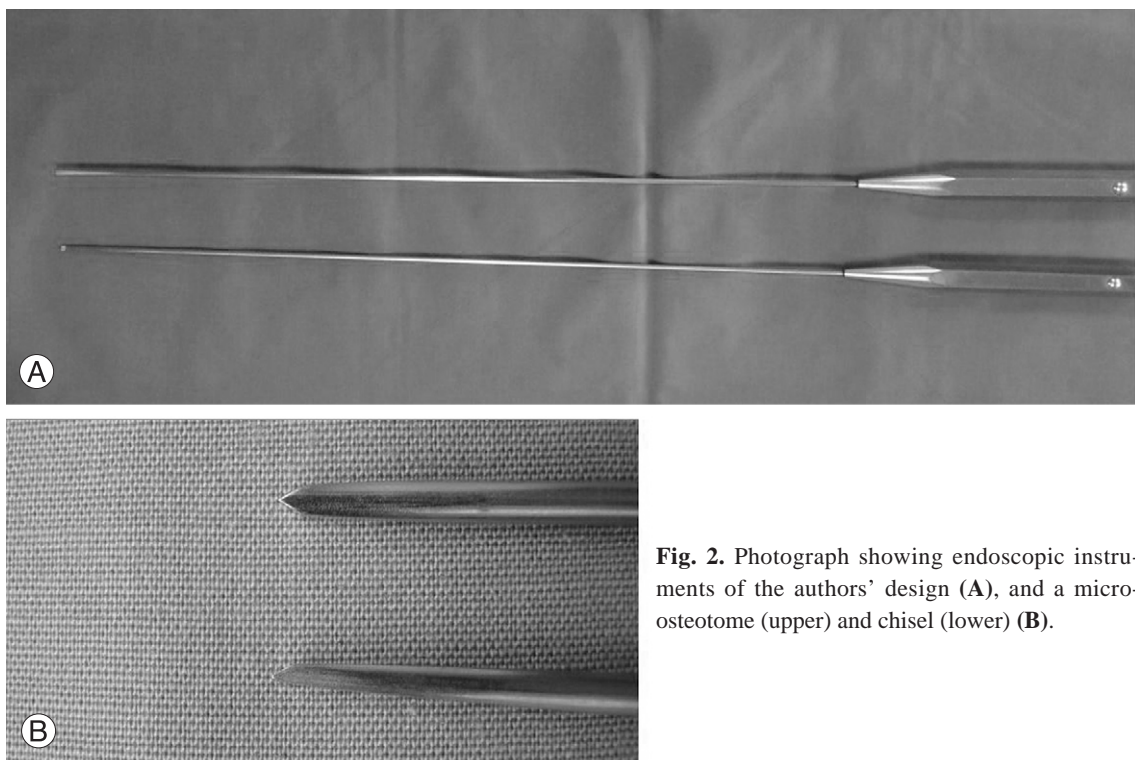


Fig. 2. Photograph showing endoscopic instruments of the authors' design (A), and a micro-osteotome (upper) and chisel (lower) (B).

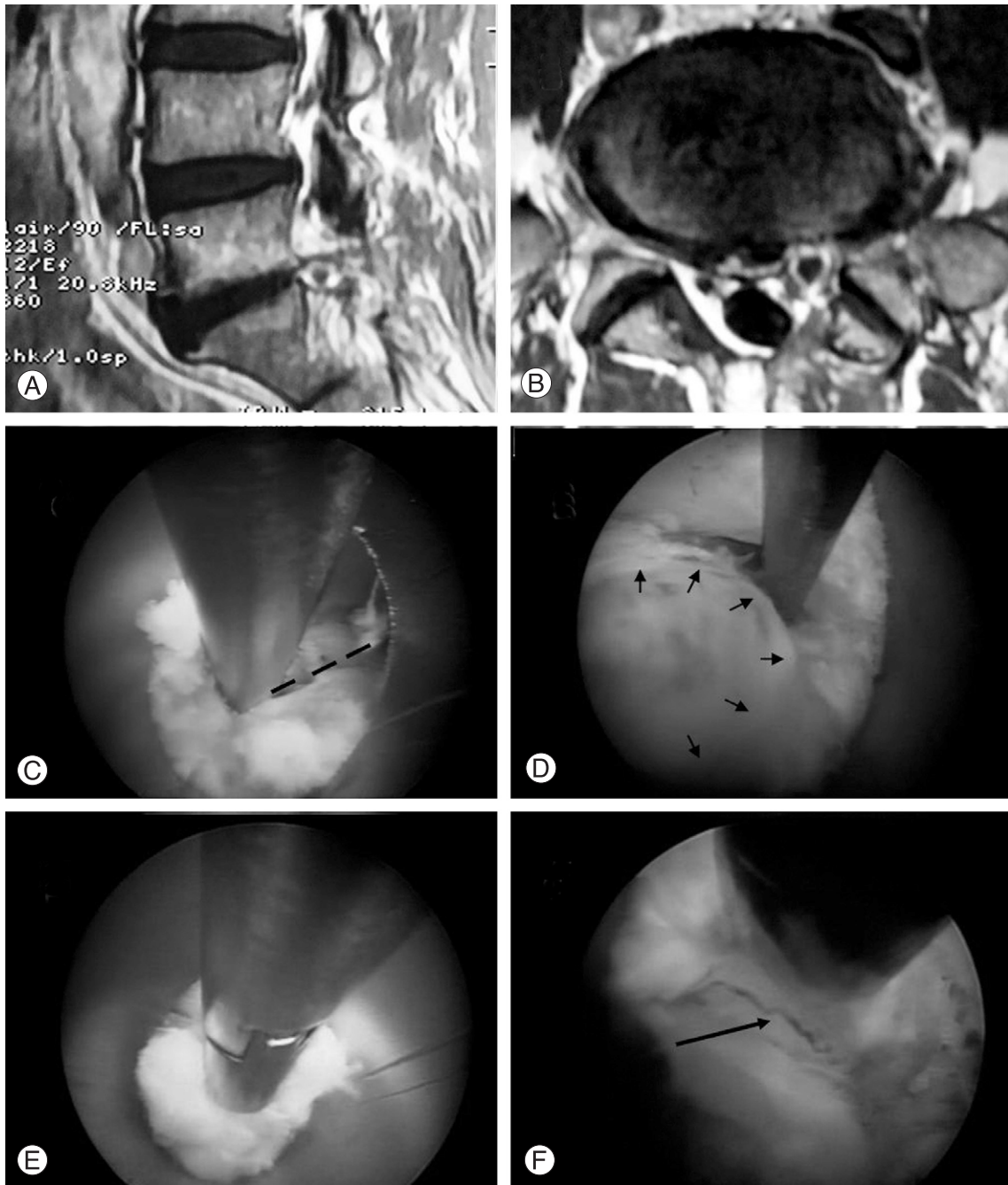


Fig. 3. Interlaminar case. (A, B) On magnetic resonance imaging, a ruptured disc at L5-S1 in the left paramedian is seen on sagittal and axial views. (C) Partial laminotomy (dotted line) at the superolateral corner of the previous window with a micro-osteotome is seen. (D) Ruptured fragment are walled-off by epidural scar tissue. (E) Walled off disc fragment are removed with an interlaminar approach. (F) After decompression, traversing the spinal nerve (arrow) can be seen.

Wilson frame, the portal site was determined according to the level and location of the herniation. In case of a central herniation at L4-5, a portal site is farther from the midline - about 12-15 cm. A 6 inch- long, 18 gauge needle was targeted from portal site with a 15-20° angle from the coronal plane, anteromedially towards the anatomical center of the

disc. In case of a central herniation at L1-2, a portal site was closer from the midline - about 6-8 cm - with needle insertion at a 45-60° angle from the coronal plane to protect retroperitoneal abdominal organs. A high angular transforaminal approach of upper lumbar vertebra can facilitate access to the midline of the anterior spinal canal because of

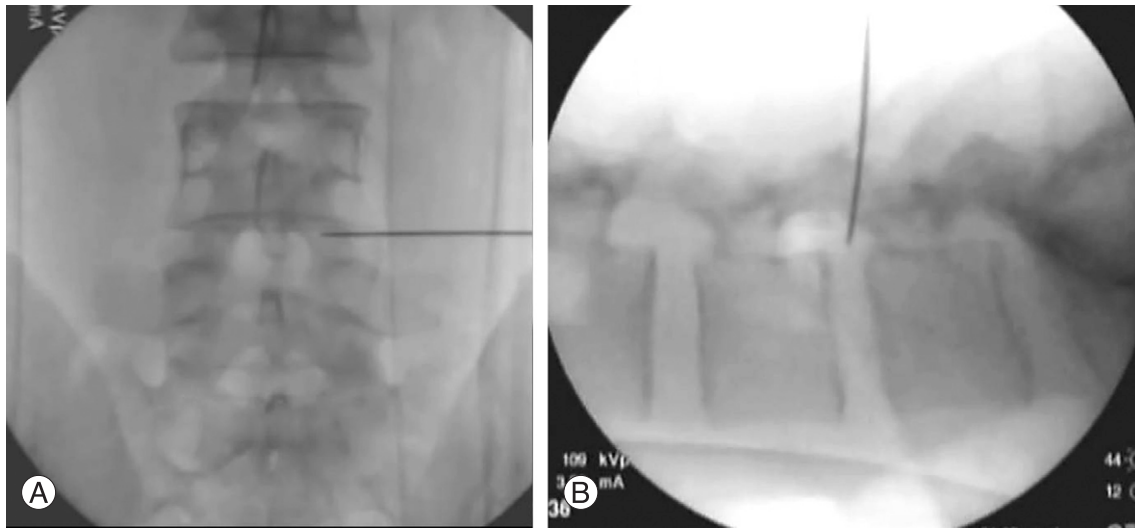


Fig. 4. Intraoperative C-arm images posteroanterior view (A) and lateral view (B) with transforaminal access.

the large neural foramen, more medially positioned isthmus, and the anatomically large triangular working zone. The ideal position of the needle tip was not beyond the medial interpedicular line on a PA view and the posterior vertebral body line on a lateral view of the C-arm intensifier (Fig. 4). The 18 gauge needle was targeted parallel to the end plate of the vertebra. A guide wire was inserted in the disc through a needle channel. After removing the needle, a bluntly tapered tissue dilating obturator was slipped over the guide wire until its tip was firmly engaged in the annular window, and then, an endoscope was inserted into the working sleeve. Then, the triangular working zone and the annulus fibrosus were observed, while making the annulus fibrosus window as medial as possible and pushing the working sleeve into the disc space. Decompression was continued under a direct clear visual field and constant saline irrigation. In recurrent herniation, ruptured fragments were walled-off by epidural scar tissue (Fig. 5).

Results

1. Patients characteristics

All 41 patients were included in the follow-up. The mean follow-up period was 16 months (range, 13 to 42 months).

2. Operative techniques

The mean operation time was 37 minutes (range, 25 to 96 minutes). There was no measurable blood loss perioperatively. To find the normal epidural fat, osseous resection

was required in all interlaminar cases and in 2 transforaminal cases.

3. Perioperative complications

There were no serious neurologic deficits or complications, such as nerve root injury or cauda equina syndrome. But there were two cases of injury to the thecal sac with cerebrospinal fluid (CSF) leakage. Since the CSF leakage was minimal, the patients were managed by increasing hydration instead of doing open repair. Two patients complained of transient postoperative dyesthesia in the leg. The patients were treated with oral gabapentin and improved after 2 months.

4. Recurrences

In two patients (4.8%), recurrences were seen within 3 weeks after the operation. The patients were operated on again with the same technique. Recurring fragments were mixed with desiccated degenerative disc and cartilage materials. The operation times were just 15 and 23 minutes for the 1st and 2nd operations, respectively. The 2nd was finished easily due to the previous laminectomy and little migration.

5. Clinical outcomes

The mean preoperative VAS for leg pain was 8.74 ± 1.50 (range, 5-10) and for back pain was 4.96 ± 2.54 (range, 1-10). At the last follow up, the mean postoperative VAS for leg pain was 2.88 ± 1.01 (range, 1-6) and for back

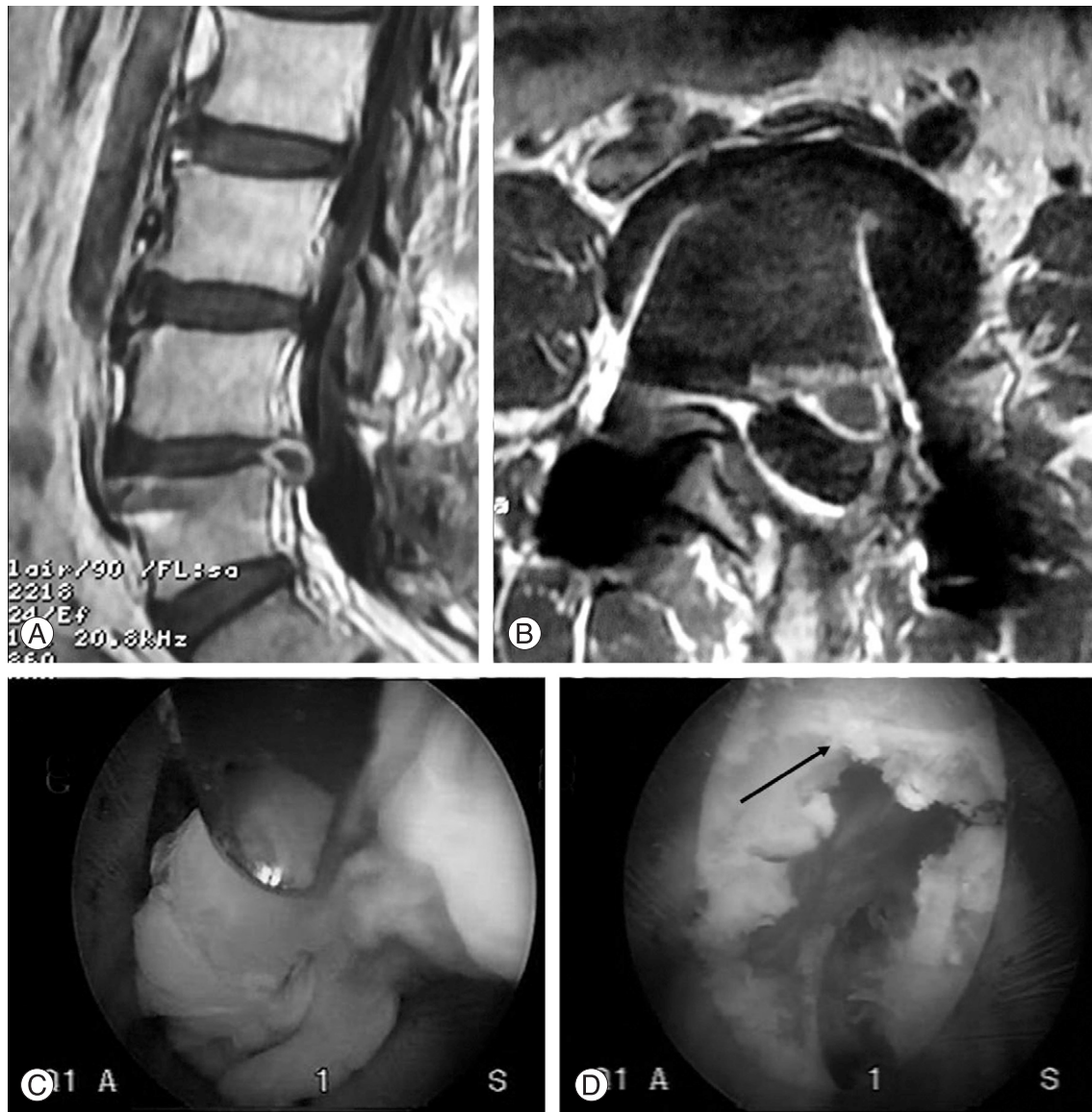

Fig. 5. Transforaminal case. (A, B) On magnetic resonance imaging, recurrent herniation of L4-5 with peridural scar formation is seen on sagittal and axial views. (C) Walled-off disc fragments are removed with a transforaminal approach. (D) After decompression, dura of cauda equina and scar tissue (arrow) can be seen.

pain was 3.25 ± 1.48 (range, 1-6). There was no significant operation-related worsening of leg and back pain. Indeed, the VAS for the leg and back were significantly reduced ($p < 0.001$). Based on the modified MacNab's criteria, the surgical outcomes were rated as follows: excellent in 18, good in 19, fair in 2 and poor in 2. Therefore, 90.2% showed excellent or good outcomes.

Discussion

The optimal surgical approach (simple discectomy with or without fusion of the affected segment) for recurrent disc herniation remains a subject of controversy [6]. In 1981,

Lehmann and LaRocca [21] treated 36 patients with chronic back and low leg pain following previous lumbar surgery by spinal canal exploration and spinal fusion. By contrast, in the studies of Cinotti et al. [22], Jönsson and Strömqvist [23], and of Suk et al. [5], the clinical outcome was good only with repeated decompression [1]. The open repeated discectomy has been considered the treatment of choice for recurrent lumbar disc herniation [7,24].

Revisional spinal surgery is more challenging than primary surgery due to the following problems. First, epidural or perineural scar tissue could disturb the dissection in the posterior approach, increasing the risk of dural tear or nerve injury [7]. Ebeling et al. [25] reported a complication rate of

13% after repeated discectomy, dural tears or infections being the most common problems. PELD provides an approach through unscarred virgin tissue, especially in the transforaminal approach [7,11,15-18,26-31]. However, when it comes to the interlaminar approach, our team overcame this problem with a feasible solution. We dissected with a sharp freer, an endoscopic curett, and the authors' specially designed micro-osteotome. We did this proximally along the bony margin until finding the normal epidural fat. After finding the epidural fat, we dissected epidural scar tissue cranially, caudally and somewhat medially to detect ruptured disc fragments, and we were able to do so without any problems. Four cases in our study had complications. Two had a dural tear, and the others had postoperative dyesthesia. Fortunately, the dyesthesia was very mild, and both of the patients recovered and returned to work.

Second, an extended muscle splitting dissection and laminectomy with further facetectomy could cause segmental instability and postoperative low back pain [3,7,32]. PELD does not damage the posterior paraspinal structures (laminae, facets, ligaments, and muscles) when using the transforaminal approach. It makes a resection for neglectable minimal laminectomy with micro-osteotome feasible when using the interlaminar approach and can preserve spinal stability through both approaches [33-38]. Tissue traumatization and complications of PELD are low compared to conventional procedures. We preferred a full-endoscopic interlaminar approach to a transforaminal approach because herniation was located within the spinal canal in all cases. Ruetten et al. reported that resection of intradiscal nucleus materials is frequently constrained because of the divergent level between the interlaminar window and the intervertebral space, which may be partly responsible for the 6.0% recurrence rate when using the interlaminar approach [15-17]. However, the authors overcame the divergence between the interlaminar window and the intervertebral space by widening of the narrow interlaminar window with an author-designed micro-osteotome. Furthermore, the authors selected the transforaminal approach for cases of herniation that were technically inoperable with an interlaminar approach, cases such as foraminal or extraforaminal disc herniation and proximally migrated herniation [39]. Eventually, the authors chose interlaminar or transforaminal approaches, taking into consideration the level and location of herniation because of the different anatomic features at each level.

In the present study, the authors found that full-endoscop-

ic interlaminar and transforaminal operation are possible as revision surgery for recurrent disc herniation. The goal of surgical treatment of recurrent disc herniation is sufficient decompression without neural injury and secondary post-operation trauma. Ruetten et al reported that a full-endoscopic operation achieves results similar to those of microscopic open discectomy [11,15-17]. In our study, there was no significant operation-related deterioration. Therefore, clinical results were good for open revisional surgery as well. The minimally invasive procedure as a new surgical technique was applied in the treatment of recurrent herniation after an open primary discectomy.

In our opinion, there are many advantages over the conventional open disc surgery: excellent visualization of anatomical structures, good illumination and expanded field of vision, reduced anatomical trauma, reduced bleeding, and high patient satisfaction. Moreover, even if the operation time is relatively long, there were no complications associated with epidural edema, which was responsible for the epidural scarring. However, disadvantages must be considered as well. Epidural scarring makes a revisional endoscopic operation more difficult to do as the revisional open surgery. Also, a steep learning curve is required to perform it successfully without complications.

Conclusions

The present study shows that predictably sufficient decompression under visual control is possible using full-endoscopic interlaminar and transforaminal techniques as revisional operations for recurrent disc herniation after conventional open discectomy. The authors have therefore concluded that full-endoscopic interlaminar and transforaminal approaches are possible and are an effective alternative to conventional revisional discectomy.

REFERENCES

1. Cinotti G, Roysam GS, Eisenstein SM, Postacchini F. Ipsilateral recurrent lumbar disc herniation: a prospective, controlled study. *J Bone Joint Surg Br* 1998;80:825-32.
2. Ehrendorfer S. Ipsilateral recurrent lumbar disc herniation. *J Bone Joint Surg Br* 1999;81:368.
3. Ozgen S, Naderi S, Ozek MM, Pamir MN. Findings and outcome of revision lumbar disc surgery. *J Spinal Disord* 1999;12:287-92.
4. Papadopoulos EC, Girardi FP, Sandhu HS, et al. Outcome

- of revision discectomies following recurrent lumbar disc herniation. *Spine (Phila Pa 1976)* 2006;31:1473-6.
5. Suk KS, Lee HM, Moon SH, Kim NH. Recurrent lumbar disc herniation: results of operative management. *Spine (Phila Pa 1976)* 2001;26:672-6.
 6. Fu TS, Lai PL, Tsai TT, Niu CC, Chen LH, Chen WJ. Long-term results of disc excision for recurrent lumbar disc herniation with or without posterolateral fusion. *Spine (Phila Pa 1976)* 2005;30:2830-4.
 7. Ahn Y, Lee SH, Park WM, Lee HY, Shin SW, Kang HY. Percutaneous endoscopic lumbar discectomy for recurrent disc herniation: surgical technique, outcome, and prognostic factors of 43 consecutive cases. *Spine (Phila Pa 1976)* 2004;29:E326-32.
 8. Knight MT, Ellison DR, Goswami A, Hillier VF. Review of safety in endoscopic laser foraminoplasty for the management of back pain. *J Clin Laser Med Surg* 2001;19:147-57.
 9. Knight MT, Goswami A, Patko JT, Buxton N. Endoscopic foraminoplasty: a prospective study on 250 consecutive patients with independent evaluation. *J Clin Laser Med Surg* 2001;19:73-81.
 10. Knight MT, Vajda A, Jakab GV, Awan S. Endoscopic laser foraminoplasty on the lumbar spine: early experience. *Minim Invasive Neurosurg* 1998;41:5-9.
 11. Ruetten S, Komp M, Godolias G. An extreme lateral access for the surgery of lumbar disc herniations inside the spinal canal using the full-endoscopic uniportal transforaminal approach-technique and prospective results of 463 patients. *Spine (Phila Pa 1976)* 2005;30:2570-8.
 12. Yeung AT, Yeung CA. Advances in endoscopic disc and spine surgery: foraminal approach. *Surg Technol Int* 2003;11:255-63.
 13. Yeung AT. The evolution of percutaneous spinal endoscopy and discectomy: state of the art. *Mt Sinai J Med* 2000;67:327-32.
 14. Yeung AT, Yeung CA. Minimally invasive techniques for the management of lumbar disc herniation. *Orthop Clin North Am* 2007;38:363-72.
 15. Ruetten S, Komp M, Merk H, Godolias G. Full-endoscopic interlaminar and transforaminal lumbar discectomy versus conventional microsurgical technique: a prospective, randomized, controlled study. *Spine (Phila Pa 1976)* 2008;33:931-9.
 16. Ruetten S, Komp M, Merk H, Godolias G. Use of newly developed instruments and endoscopes: full-endoscopic resection of lumbar disc herniations via the interlaminar and lateral transforaminal approach. *J Neurosurg Spine* 2007;6:521-30.
 17. Ruetten S, Komp M, Godolias G. A New full-endoscopic technique for the interlaminar operation of lumbar disc herniations using 6-mm endoscopes: prospective 2-year results of 331 patients. *Minim Invasive Neurosurg* 2006;49:80-7.
 18. Kim JM, Lee SH, Ahn Y, Yoon DH, Lee CD, Lim ST. Recurrence after successful percutaneous endoscopic lumbar discectomy. *Minim Invasive Neurosurg* 2007;50:82-5.
 19. Lee SH, Kang BU, Ahn Y, et al. Operative failure of percutaneous endoscopic lumbar discectomy: a radiologic analysis of 55 cases. *Spine (Phila Pa 1976)* 2006;31:E285-90.
 20. Mullin WJ, Heithoff KB, Gilbert TJ Jr, Renfrew DL. Magnetic resonance evaluation of recurrent disc herniation: is gadolinium necessary? *Spine (Phila Pa 1976)* 2000;25:1493-9.
 21. Lehmann TR, LaRocca HS. Repeat lumbar surgery: a review of patients with failure from previous lumbar surgery treated by spinal canal exploration and lumbar spinal fusion. *Spine (Phila Pa 1976)* 1981;6:615-9.
 22. Cinotti G, Gumina S, Giannicola G, Postacchini F. Contralateral recurrent lumbar disc herniation: results of discectomy compared with those in primary herniation. *Spine (Phila Pa 1976)* 1999;24:800-6.
 23. Jönsson B, Strömqvist B. Repeat decompression of lumbar nerve roots: a prospective two-year evaluation. *J Bone Joint Surg Br* 1993;75:894-7.
 24. Dai LY, Zhou Q, Yao WF, Shen L. Recurrent lumbar disc herniation after discectomy: outcome of repeat discectomy. *Surg Neurol* 2005;64:226-31; discussion 31.
 25. Ebeling U, Kalbarczyk H, Reulen HJ. Microsurgical reoperation following lumbar disc surgery: timing, surgical findings, and outcome in 92 patients. *J Neurosurg* 1989;70:397-404.
 26. Hoogland T, Schubert M, Miklitz B, Ramirez A. Transforaminal posterolateral endoscopic discectomy with or without the combination of a low-dose chymopapain: a prospective randomized study in 280 consecutive cases. *Spine (Phila Pa 1976)* 2006;31:E890-7.
 27. Kambin P, O'Brien E, Zhou L, Schaffer JL. Arthroscopic microdiscectomy and selective fragmentectomy. *Clin Orthop Relat Res* 1998;(347):150-67.
 28. Kambin P, Zhou L. Arthroscopic discectomy of the lumbar spine. *Clin Orthop Relat Res* 1997;(337):49-57.
 29. Lee DY, Ahn Y, Lee SH. Percutaneous endoscopic lumbar discectomy for adolescent lumbar disc herniation: surgical outcomes in 46 consecutive patients. *Mt Sinai J Med*

- 2006;73:864-70.
30. Lee S, Kim SK, Lee SH, et al. Percutaneous endoscopic lumbar discectomy for migrated disc herniation: classification of disc migration and surgical approaches. *Eur Spine J* 2007;16:431-7.
31. Sasani M, Ozer AF, Oktenoglu T, Canbulat N, Sarioglu AC. Percutaneous endoscopic discectomy for far lateral lumbar disc herniations: prospective study and outcome of 66 patients. *Minim Invasive Neurosurg* 2007;50:91-7.
32. Luukkonen MT. Medial facetectomy in recurrent lumbar nerve root compression. *J Spinal Disord Tech* 2005;18:48-51.
33. Choi G, Lee SH, Raiturker PP, Lee S, Chae YS. Percutaneous endoscopic interlaminar discectomy for intracanalicular disc herniations at L5-S1 using a rigid working channel endoscope. *Neurosurgery* 2006;58(1 Suppl):ONS59-68.
34. Kambin P, Savitz MH. Arthroscopic microdiscectomy: an alternative to open disc surgery. *Mt Sinai J Med* 2000;67:283-7.
35. Kambin P, Gennarelli T, Hermantin F. Minimally invasive techniques in spinal surgery: current practice. *Neurosurg Focus* 1998;4:e8.
36. Mayer HM, Brock M. Percutaneous endoscopic discectomy: surgical technique and preliminary results compared to microsurgical discectomy. *J Neurosurg* 1993;78:216-25.
37. Mayer HM, Brock M. Percutaneous endoscopic lumbar discectomy (PELD). *Neurosurg Rev* 1993;16:115-20.
38. Mayer HM, Brock M, Berlien HP, Weber B. Percutaneous endoscopic laser discectomy (PELD): a new surgical technique for non-sequestered lumbar discs. *Acta Neurochir Suppl (Wien)* 1992;54:53-8.
39. Jang JS, An SH, Lee SH. Transforaminal percutaneous endoscopic discectomy in the treatment of foraminal and extraforaminal lumbar disc herniations. *J Spinal Disord Tech* 2006;19:338-43.