

Combined therapeutic use of oral alitretinoin and narrow-band ultraviolet-B therapy in the treatment of Hailey-Hailey disease

Kaitlin A. Vanderbeck,¹ Lyne Giroux,²
Nirosha J. Murugan,^{3,4}
Lukasz M. Karbowski^{3,4}

¹Department of Medicine, Northern Ontario School of Medicine, Greater Sudbury; ²Department of Medicine, University of Ottawa; ³Behavioural Neuroscience Program and ⁴Department of Biomolecular Sciences, Laurentian University, Greater Sudbury, Canada

Abstract

Hailey-Hailey disease (HHD) is a chronic familial bullous disease characterized by recurrent blisters and erosions typically at friction-prone areas of the body accompanied by acantholysis upon histologic examination. There are a number of therapies used in the management of HHD. Its symptoms have been effectively treated with antimicrobial therapies, corticosteroids and other agents such as cyclosporine and prednisone. However, such treatments are not always effective. Therefore, there is a need for new treatments for the management of HHD. In this report, a patient with long-standing HHD responsive only to high levels of prednisone is described. After the successful tapering and cessation of oral prednisone the patient began a new combination therapy of complementary doses of oral alitretinoin, and narrowband UVB therapy, which yielded a favorable response within 2-3 weeks. After 6 weeks, a mono-therapy of daily (30 mg) oral alitretinoin was sufficient to maintain successful near-complete remission of the disease.

Introduction

Hailey-Hailey disease (HHD), otherwise known as familial benign chronic pemphigus is a rare autosomal dominant, acantholytic disease with incomplete penetrance that is characterized by recurrent blisters, plaques, and erosions often accompanied by a burning or pruritic sensation.¹⁻³ Patients typically experience a relapsing-remitting course of the disease.⁴ It is caused by a mutation in the *ATP2C1* gene on chromosome 3q21-q24, which encodes a disrupted Golgi associated Ca²⁺ ATPase.⁵

This mutation induces abnormal intracellular Ca²⁺ signaling which promotes premature keratinocyte proliferation leading to inappropriate desmosomal protein production causing failed keratinocyte adhesion and acantholysis, typically at flexural regions and friction prone sites.^{1-3,5,6}

We report a 64-year-old female with a 37-year history of severe Hailey-Hailey disease involving her whole body. Most recently, HHD lesions have appeared on her pubic region and middle back. The patient's HHD has been unresponsive to common therapies used in the management of HHD.

Case Report

In 2005, a then 55-year-old Caucasian female presented with clinical signs and symptoms of HHD, which had been active for 32 years. The patient initially developed symptoms of Hailey-Hailey disease in 1973 in her axillae and inframammary folds as well as her pubic region (namely her labia). A biopsy performed confirmed the HHD diagnosis. The patient reported a family history of the disease. She also reported that HHD lesions have previously appeared on her arms, neck, back, abdomen, popliteal regions, and oral mucosa. The presence of white bands on her fingernails, a rare manifestation of the disease, has also been documented.^{2,4} In 2003, the severity of the HHD lesions within her inframammary folds necessitated a double mastectomy. A second biopsy was performed and confirmed that the inframammary lesions were in fact HHD lesions. Most recently, the patient presented with erythematous and crusted erosions and erupted bullae on her pubic region and middle back (Figure 1).

Since the patient's initial presentation and diagnosis, several different treatments have been administered for the management of the disease and its symptoms including: steroid and non-steroidal anti-inflammatory treatments (systemic, topical and intra-lesional), cyclosporin, methotrexate, dapsone, botulinum toxin A, fraxelated CO₂ laser to affected regions, and a variety of oral and topical antimicrobial therapies with minimal relief. Of the treatments given the patient's disease and symptoms were best controlled by oral doses of prednisone during times of exacerbated symptoms with doses of 30-50 mg *per os*. However, attempts to taper the prednisone to doses less than 10 mg were met with the recurrence of symptoms of the disease. Recent studies have reported the use of narrowband UVB or alitretinoin as successful independent therapeutic options in the treatment of HHD.^{6,7} Considering the persistent nature of the patient's disease a combination therapy of

Correspondence: Kaitlin Vanderbeck, Department of Medicine, Northern Ontario School of Medicine, Ramsey Lake Rd, Greater Sudbury, ON P0M, Canada.
Tel.: +1.705.662.2294.
E-mail: kvanderbeck@nosm.ca

Key words: Hailey-Hailey disease, pemphigus, alitretinoin, narrowband UVB.

Contributions: the authors contributed equally.

Conflict of interests: the authors declare no potential conflict of interests.

Received for publication: 26 August 2014.

Accepted for publication: 26 October 2014.

This work is licensed under a Creative Commons Attribution NonCommercial 3.0 License (CC BY-NC 3.0).

©Copyright K.A. Vanderbeck et al., 2014
Licensee PAGEPress, Italy
Dermatology Reports 2014; 6:5604
doi:10.4081/dr.2014.5604

alitretinoin, an oral retinoid agent known as Tactino (30 mg *per os* daily), and narrowband UVB therapy was started.^{3,6,7} The narrowband UVB therapeutic dose range was determined by the patient's skin type.⁸ For our patient, the narrowband UVB range began at 0.200 J/cm² with an initial exposure time of 30 seconds. UVB therapy was administered twice weekly and was to be continued until a total of 30 treatments (approximately 4 months) had been reached. Treatment was administered using the Professional Full Body Unit by Ultralite Enterprises (Ultralite Enterprises, Lawrenceville, GA, USA). Based on the patient's positive response to the treatment, the UVB dose was increased by increments of 0.020 J/cm² each visit until a dose of 0.294 J/cm² was reached. The treatment doses administered throughout the patient's treatment were within a safe range as the minimum erythematous dose described by Hamada *et al.*⁷ was 0.300 J/cm². The course of treatment undertaken in this case is unique because existing literature describes the treatment of HHD with oral alitretinoin while the patient was tapering prednisone.^{6,9} The patient described in this report began the combination alitretinoin-narrowband UVB treatment within days of prednisone cessation.

The patient reported that the lesions found on her pubic region and middle back improved within the first 2-3 weeks of starting this new combination alitretinoin and narrowband UVB treatment. Upon follow-up 6 weeks after beginning this new treatment course, a marked increase in healing bullae and tissue on the patient's back were noted. Residual rubor from

UVB burns experienced during the fourth UVB session were also noted. Only after the fourth UVB treatment did the patient present with rubor from UVB burns, which led to the cessation of the UVB treatment, but continued use of oral alitretinoin as a mono-therapy. Healing HHD lesions could also be seen in the patient's pubic area at this time with no new lesions noted (Figure 2). No other topical or systemic treatments were used throughout this treatment period. Currently, a mono-therapy of oral alitretinoin has maintained remission of the disease for 14 weeks since the beginning of the initial combination alitretinoin and narrowband UVB treatment course. No other treatments or interventions have been used, and no new lesions have been experienced with the alitretinoin mono-therapy.

Discussion

Hailey-Hailey disease was first described by brothers Hailey and Hailey in 1939.¹⁰ Familial benign chronic pemphigus is an inherited, autosomal dominant bullous disease.^{1,2,4} HHD presents with recurrent bullae, vesicles, and erythematous patches and erosions. Patients usually experience a relapsing-remitting course of the disease.^{1,2,4,8} For many patients, a family history of HHD is present with lesions manifesting after adolescence.^{1,2} Lesions favoring the axillae, chest, neck, genital areas, and other flexural regions are usually noted.^{1,2} Eruptions are sometimes accompanied by a burning or pruritic sensation.² Secondary infection with candida and/or staphylococcus is often noted and considered to be a common complication of the disease.^{1,3} Several white bands on the fingernails have also been described in some cases. Involvement of the vulva, conjunctiva, and mucosae are considered rare manifestation of the disease.^{2,3}

This disease affects a patient's quality of life and can be quite distressing. The management of HHD can be challenging.^{1,3,4,11} There is currently no cure for HHD, however, treatment for managing the symptoms are available.^{3,6,7} In some cases, antibiotics, antifungal agents, as well as systemic, topical, and intralesional corticosteroids have proven effective for the management of HHD.^{1,3} Furthermore, other agents such as cyclosporine, retinoids, botulinum toxin A, and dapsone have also proven to be effective in some cases, and ineffective in others.^{1,3} According to Sardy and Ruzicka,⁶ there is a need for new treatments. The patient, whose case is described, presented with a severe manifestation of HHD with recurrent bullae, erythematous patches, and erosions.⁴ The patient has experienced HHD lesions on many different areas of her body including her genital region, neck, back, and oral mucosa, to

name a few. For this patient, HHD has been a part of her life for almost 40 years. Finding an effective treatment for her HHD has been challenging. Recently, the successful remission of HHD with narrowband UVB has been discussed.⁷ In this patient's case narrowband UVB was ceased after only four sessions due to UVB burns. This may be attributed to the oral alitretinoin, a retinoid agent that has been shown to induce photosensitivity.^{3,7,8,12}

The case report by Sardy and Ruzicka showed successful treatment with alitretinoin in a patient with HHD.⁶ The treatment was accompanied by a continued course of oral prednisone, which was later tapered while treatment with oral alitretinoin persisted.⁶

Conversely, in our patient's case, the combination daily oral alitretinoin (30 mg) and narrowband UVB therapy described, which resulted in the successful remission of the patient's HHD, was started after the tapering and complete cessation of prednisone use. Further, considerable and sustained clinical improve-

ment of the patient's HHD lesions has been noted with the administration of the daily oral alitretinoin therapy alone. Presently there has been no need for any treatment with further UVB, prednisone, or any other systemic or topical agents as the patient's disease appears to be in remission. For the first time in almost 40 years the patient has found relief and an effective treatment for her HHD.

Conclusions

In conclusion, we suggest that conjunctive therapy of oral alitretinoin with narrowband UVB therapy be considered as a therapeutic option for the treatment of HHD to be followed by a mono-therapy of alitretinoin. The use of oral alitretinoin and narrowband UVB therapy should be explored further. In addition, the efficacy of oral alitretinoin as a mono-therapy for HHD should be explored.

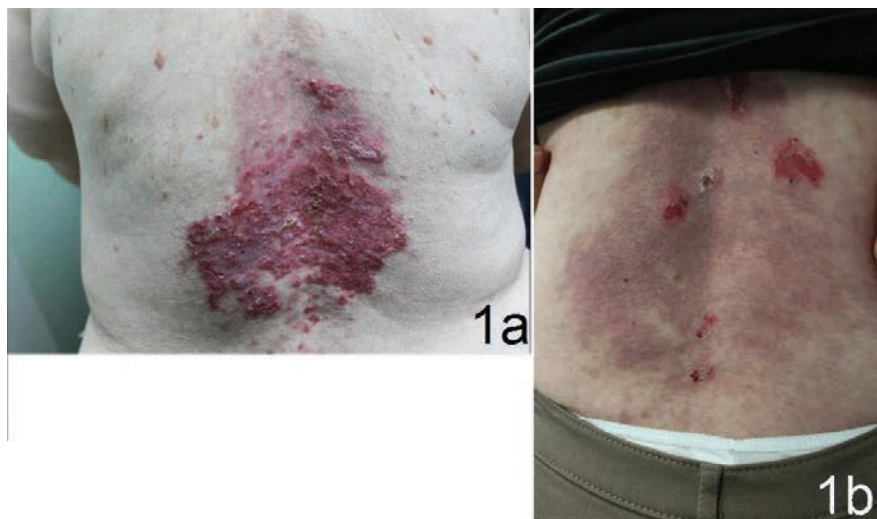


Figure 1. Erythematous Hailey-Hailey lesions on the patient's midback (A); healing Hailey-Hailey lesions with some residual rubour and erupted bullae on the patient's midback 6 weeks after combination alitretinoin and narrowband UVB course initiated (B).

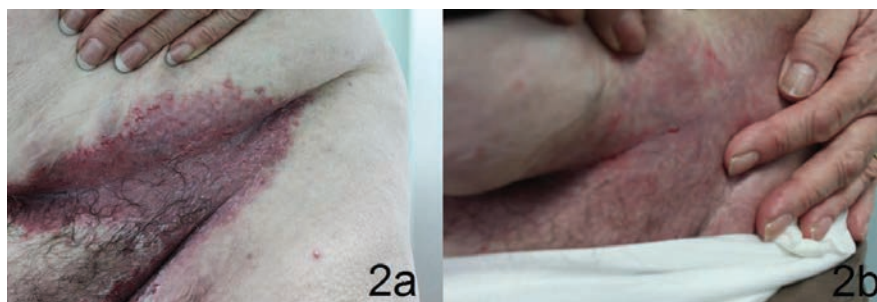


Figure 2. Erythematous Hailey-Hailey lesions on the patient's left groin (a); healing Hailey-Hailey lesions on patient's left groin 6 weeks after starting combination alitretinoin and narrowband UVB treatment (b).

References

1. James WD, Berger TG, Elston DM, eds. Familial benign chronic pemphigus (Hailey-Hailey Disease). In: Andrews' diseases of the skin clinical dermatology. 10th ed. Toronto: Elsevier Inc; 2006. pp 559-560.
2. Helm TM. Familial benign pemphigus (Hailey-Hailey disease). Available from: <http://emedicine.medscape.com/article/1063224-overview>. Accessed on: July 17, 2014.
3. D'Errico A, Bonciani DB, Bonciolini V, et al. Hailey-Hailey disease treated with methotrexate. *J Dermatol Case Rep* 2012;6:49-51.
4. Hunt R, O'Reilly K, Ralston J, et al. Familial benign chronic pemphigus (Hailey-Hailey disease). *Dermatol Online J* 2010;16:14.
5. Hu Z, Bonifas JM, Beech J, et al. Mutations in ATP2C1, encoding a calcium pump, cause Hailey-Hailey disease. *Nat Genet* 2000;24:61-5.
6. Sardy M, Ruzicka T. Successful therapy of refractory Hailey-Hailey disease with oral alitretinoin. *Br J Dermatol* 2014;170:209-11.
7. Hamada T, Umemura H, Aoyama Y, Iwatsuki K. Successful therapeutic use of targeted narrow-band ultraviolet B therapy for refractory Hailey-Hailey disease. *Acta Derm Venereol* 2012;93:110-1.
8. Do AN, Koo JYM. Initiating narrow-band UVB for the treatment of psoriasis. *Psoriasis forum*. Available from: <https://www.natbiocorp.com/pdf/do-koonpf.pdf>
9. Berth-Jones J, Smith SG, Graham-Brown RAC. Benign familial chronic pemphigus (Hailey-Hailey disease) responds to cyclosporin. *Clin Exp Dermatol* 1995;20:70-2.
10. Hailey H, Hailey H. Familial benign chronic pemphigus. *Arch Dermatol* 1982;118:774-80.
11. Ikeda S, Suga Y, Ogawa H. Successful management of Hailey-Hailey disease with potent topical steroid ointment. *J Dermatol Sci* 1993;5:205-11.
12. Mukherjee S, Date A, Patravale V, et al. Retinoids in the treatment of skin aging: an overview of clinical efficacy and safety. *Clin Interv Aging* 2006;1:27-348.