

# BMJ Open Effectiveness of acellular dermal matrix graft with a coronally advanced flap for the treatment of Miller Class I/II single gingival recession with thin gingival phenotype: study protocol for a split-mouth randomised controlled trial

Yalin Zhan , Miaozhen Wang, Xiaojing Cao, Feng Liu

**To cite:** Zhan Y, Wang M, Cao X, *et al.* Effectiveness of acellular dermal matrix graft with a coronally advanced flap for the treatment of Miller Class I/II single gingival recession with thin gingival phenotype: study protocol for a split-mouth randomised controlled trial. *BMJ Open* 2022;**12**:e047703. doi:10.1136/bmjopen-2020-047703

► Prepublication history for this paper is available online. To view these files, please visit the journal online (<http://dx.doi.org/10.1136/bmjopen-2020-047703>).

Received 15 December 2020  
Accepted 03 December 2021



© Author(s) (or their employer(s)) 2022. Re-use permitted under CC BY-NC. No commercial re-use. See rights and permissions. Published by BMJ.

For numbered affiliations see end of article.

## Correspondence to

Dr Feng Liu;  
[dentistliufeng@126.com](mailto:dentistliufeng@126.com)

## ABSTRACT

**Introduction** Gingival recession is one of the most common mucogingival deformities requiring surgical correction. The American Academy of Periodontology Regeneration Workshop recommended connective tissue graft (CTG) combined with coronally advanced flap (CAF) for the treatment of Miller Class I and II single-tooth gingival recession. The disadvantages of harvesting autogenous tissue include postoperative bleeding, pain and discomfort at the donor site, restricted tissue supply, increased morbidity and prolonged operative times. Acellular dermal matrix (ADM) contains undamaged collagen and elastin matrices that can be used as a substitute for CTG during root coverage procedures. However, the use of ADM is still controversial. The objective of this split-mouth; randomised, controlled, clinical study is to evaluate the long-term effects of ADM graft (ADMG) combined with CAF on root coverage, aesthetics and patient satisfaction for the treatment of single gingival recession with thin gingival phenotype.

**Methods and analysis** Forty participants with bilateral Miller Class I/II gingival recession will be randomised to receive an ADMG on one side and CTG on the contralateral side, combined with CAF. Gingival recession depth, gingival recession width and keratinised tissue width will be measured at baseline, 2 weeks and 1, 3, 6, 12 and 24 months. Mean root coverage, complete root coverage, root coverage aesthetic score, colour change ( $\Delta E$ ) and patient satisfaction will be assessed during follow-up visits.

**Ethics and dissemination** The present study has received approval from the Ethics Committee of Peking University School and Hospital of Stomatology (PKUSSIRB-202054029). Data of this study will be registered with the International Clinical Trials Registry Platform. Additionally, we will disseminate the results through scientific journal.

**Trial registration number** ChiCTR2000033230.

## INTRODUCTION

Gingival recession is defined as exposure of the root surface due to apical migration of

## Strengths and limitations of this study

- This will be a double-blind, split-mouth randomised controlled clinical trial.
- This trial will compare the long-term outcomes of acellular dermal matrix graft and connective tissue graft for treating gingival recessions with thin gingival phenotype.
- The patients will be followed up for 24 months.
- The results of this trial will improve treatments for gingival recession.
- The main limitation of this study will be that the condition of exposed roots will not be evaluated.

the gingival margin to the cemento-enamel junction (CEJ).<sup>1 2</sup> It is a common problem,<sup>3–5</sup> affecting 51% of the population.<sup>6 7</sup> Gingival recession is caused by anatomical and mechanical factors, such as biological width invasion, injury related to toothbrushing or oral piercing, muscle insertions and inflammation due to plaque.<sup>7 8</sup> Exposed root surfaces are associated with many problems, including dentinal hypersensitivity, poor dental aesthetics, root erosion, root caries and inadequate plaque removal.<sup>9</sup> Therefore, many patients request surgery for coverage of exposed root surfaces.

Different surgical techniques have been used for root coverage.<sup>10–20</sup> The coronally advanced flap (CAF) is an important component of periodontal plastic surgery used to treat Miller Class I/II gingival recessions. CAF can be used alone,<sup>21 22</sup> or in conjunction with a connective tissue graft (CTG),<sup>23–26</sup> enamel matrix derivative (EMD),<sup>27</sup> platelet-rich fibrin (PRF)<sup>28</sup> or low-intensity laser therapy<sup>29</sup> to improve outcomes. A systematic review<sup>30</sup> reported that CAF, with or without CTG, for

the treatment of Miller Class I/II recessions achieved predictable complete root coverage (CRC). The combination of CAF and CTG was associated with greater long-term stability of CRC, and is therefore the gold standard treatment for gingival recessions.<sup>31 32</sup>

The subepithelial connective tissue procedures provide excellent outcomes. They require two surgeries, which increases patient discomfort and the risk of postoperative pain and bleeding. In addition, the amount of graft may be limited by the palatal donor site and thickness, especially in the multiple gingival recession sites treatment.<sup>33–35</sup> To overcome the limitations of autogenous tissue harvesting, PRF,<sup>28</sup> platelet-rich plasma (PRP),<sup>36</sup> EMD,<sup>37</sup> xenogeneic collagen matrix (XCM)<sup>38–40</sup> and acellular dermal matrix (ADM)<sup>41 42</sup> and xenogeneic acellular dermal matrix<sup>43 44</sup> have been used as alternatives to CTG for plastic periodontal and implant surgery.

ADM involves the removal of cellular and epidermal components of human dermis, to eliminate the source of disease transmission and immunological reactions, which leaves a structurally intact connective tissue matrix, composed of collagen fibrillar network, proteins, elastin filaments, proteoglycans, hyaluronan and a basement membrane. Therefore, the ADM possesses the characteristics of a soft tissue graft material, and can be used as a scaffold to promote the growth of host tissues.<sup>45</sup> ADM was first used in the 20th century,<sup>46 47</sup> and has since been used extensively in various areas of dental practice.<sup>31 48</sup> ADM graft (ADMG) is recommended as an alternative to autogenous CTG for the treatment of alveolar ridge deformities,<sup>49</sup> to increase the width of the keratinised tissue (KT) around teeth and implants<sup>50–52</sup> and to guide bone<sup>53 54</sup> or tissue regeneration<sup>55</sup> and root coverage.<sup>56 57</sup> Although the clinical efficacy of ADMG has been discussed in several reviews,<sup>31 48 58</sup> the application of this material is still controversial. Moreover, the data on the long-term clinical and patient-reported outcomes after ADMG are of low quality.

Gingival phenotype affects the clinical outcomes of root coverage procedures.<sup>59 60</sup> Gingival thickness (GT) less than 1 mm is associated with a lower likelihood of CRC.<sup>61</sup> GT may have a greater influence on the final outcome of root coverage procedures than the amount of KT.<sup>59 62</sup> The ADM, as a ‘non-vital’ structure, depends on the recipient site for cells and blood supply for reorganisation. Therefore, the gingival phenotype is critical for a good clinical outcome. To the best of our knowledge, no randomised controlled clinical trial has compared the outcomes of CTG and ADM for the treatment of gingival recessions in patients with thin gingival phenotype. Therefore, the aim of this study is to compare root coverage, aesthetics and patient satisfaction between ADMG combined with CAF and CTG combined with CAF for the treatment of Miller Class I / II gingival recessions in patients with thin gingival phenotype.

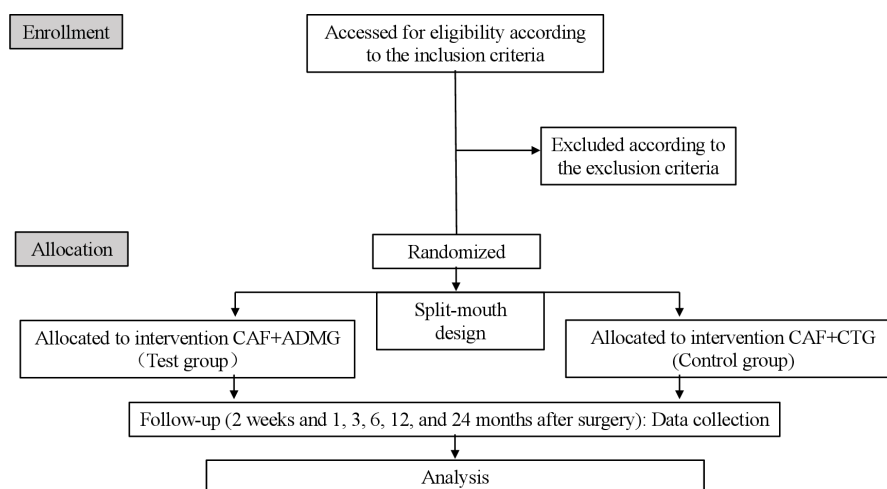
## METHODS AND ANALYSIS

This will be a prospective, single-centre, split-mouth randomised controlled clinical trial including 40 patients with Miller Class I/II gingival recessions who require root coverage. This study will be conducted at the First Clinical Division, Peking University School and Hospital of Stomatology, China. This study was approved by the Biomedical Ethics Committee of Peking University School and Hospital of Stomatology (PKUSSIRB-202054029), and registered in the International Clinical Trials Registry Platform (ICTRP). [Figure 1](#) summarises the research framework.

### Participant selection

Patients scheduled for a root coverage procedure at the First Clinical Division, Peking University School and Hospital of Stomatology, and who provide written, informed consent, will be recruited to the study.

Patients who meet the following inclusion criteria will be included: (1) age  $\geq 18$  years; (2) willing to attend the



**Figure 1** Consolidated standards of reporting trials diagram. ADMG, acellular dermal matrix graft; CAF, coronally advanced flap; CTG, connective tissue graft.

study and provide an informed consent; (3) systemically healthy with no contraindication to periodontal surgery; (4) Miller Class I or II adjacent gingival recessions  $\geq 3$  mm and a thin gingival phenotype (the white colour of a colour-coded phenotype probe (Hu-Friedy, Chicago, Illinois, USA) inserted into the sulcus should be clearly visible through the tissue<sup>63–65</sup>) affecting the same teeth (central or lateral incisors, canine or first or second premolars) on each side of the maxillary or mandibular arches, without any evidence of active or chronic periodontal disease; (5) gingival recession with at least 1 mm of KT apical to the recession; (6) full-mouth plaque and bleeding scores  $\leq 15\%$  (7) and no history of surgery in the relevant areas. In patients with multiple recessions, the deepest one will be selected, if all recessions are of the same depth, one will be selected according to the result of a coin toss.<sup>66</sup>

Patients with any of the following will be excluded: (1) habitual tobacco smoking and/or chewing; (2) habitual alcohol consumption; (3) pregnant or lactating women; (4) history of dental crown placement; (5) restorations involving the CEJ, or those with non-identifiable CEJ and (6) penicillin allergy or use of medications that may interfere with healing.

### Patient and public involvement

The priorities, experiences and preferences of patients will not be used to develop the research question or outcome measures. Patients will not be involved in the design, recruitment or conduct of the study. The study results will be disseminated through publications in dental journals. The study outcomes will be assessed by periodontists. Patient advisors will be acknowledged in the manuscript.

### Randomisation and blinding

Patients will be randomised by a professor using a software programme that generates random permuted blocks. The investigators will be blinded to the randomisation, and the allocation will be concealed in opaque envelopes, which will be opened immediately before the surgery to determine the test site. The corresponding contralateral tooth will be subjected to the control procedure. All participants will be treated by an experienced periodontist who will not be involved in the allocation, examination or statistical analysis. The examiner and statistician will be blinded to the treatment plan and allocation. Unblinding will be permissible in cases of postoperative adverse events.

### Interventions

All surgeries will be performed at the First Clinical Division, Peking University School and Hospital of Stomatology by the same periodontist. Preoperatively, the periodontal status will be evaluated, a comprehensive clinical examination will be performed and the aetiology of the recessions will be determined by a calibrated examiner. Identified etiological factors will be

treated as necessary, oral hygiene instructions (OHI) will be provided and full-mouth supragingival scaling and polishing will be performed. The participants will be re-evaluated at least 4 weeks before the surgery to confirm that they meet the inclusion criteria and have good oral hygiene.

The surgeries are performed by an experienced periodontist. Both the test and control surgeries will be performed during the same visit. The same surgical procedure will be used for both the test and control sites, except that the test sites will receive ADMG and the control sites CTG (figure 2). Following local anaesthesia, a CAF will be designed using the method described by Zucchelli *et al.*<sup>67</sup> Briefly, an intracrevicular incision will be made at the bottom of the crevice. Two mesial and distal vertical releasing incisions will be made, including the papillae adjacent to the area of gingival recession. The papillae will be de-epithelialised by interdental incisions. The flap will be elevated using a split-full-split approach in the apico-coronal direction, and full-thickness soft tissue apical to the exposed root will be elevated to cover the recession area. Finally, the apical part of the split-thickness flap will be raised to release muscle tension, and the flap will be positioned passively over the CEJ without tension. Following flap elevation, the exposed root surface will be gently planed using sharp cures (Gracey Cures, Hu-Friedy, Chicago, Illinois, USA).

As previously described, a single-incision technique will be used to obtain the subepithelial CTG (without harvesting the periosteum) from the lateral palate in the control group.<sup>23</sup> The connective tissue will be trimmed to a shape and size appropriate to cover the root surface and surrounding bone. The graft will be 1-mm thick.

In the test group, exposed root surface will be treated with ADM (Qingyuanweiye, Beijing, China) that is aseptically rehydrated in sterile saline. ADM will be rinsed with sterile saline three times before use, in accordance with the manufacturer's instructions. The graft will be trimmed to a shape and size appropriate to cover the root surface and surrounding bone. In accordance with the technique described by Harris, the graft will be positioned with the basement membrane adjacent to the bone and tooth, and the connective tissue adjacent to the flap.<sup>68</sup> The graft will be 1-mm thick.

The ADM and CT will cover the recipient area at the level of CEJ on the coronal site, as well as the vascular tissues located 3 mm lateral and apical to the recession. The grafts in both groups will be secured in the interdental areas and lateral sites using bioabsorbable suture material (6–0, DS-12; Serafit; Serag-Wiessner, Naila, Germany). The CAF will be positioned 1 mm coronal to the CEJ, covering the entire graft in both groups.<sup>67</sup> The CAF will be sutured using non-absorbable suture material (6–0, DS-15; Seralene; Serag-Wiessner, Naila, Germany) by sling and interrupted technique, without creating tension. This suture will also be used to secure the donor site. Microsurgical hand instruments (Hu-Friedy, Chicago, Illinois, USA) and 4.0×loupe (Q Optics, Texas)



follows: ((teeth with CRC)/(all treated teeth)) $\times$ 100%. The secondary outcomes of this trial are PD, CAL and VAS of patient satisfaction.

### Sample size

The sample size of this trial was calculated using the following formula:  $n = \left[ \frac{(z_{\frac{\alpha}{2}} + z_{\beta})\sigma}{\delta} \right]^2 \left( \frac{1}{Q_1} + \frac{1}{Q_2} \right)$ . In the preliminary experiment results and previously published articles,<sup>72</sup> the mean difference of the reduction in gingival recession ( $\delta$ ) was around 0.1 mm and the standard deviation ( $\sigma$ ) was around 0.3 mm.

If the inspection level ( $\alpha$ ) is set at 0.05 and the power of test ( $\beta$ ) at 90%, 36 participants will be required for each group. Assuming a loss to follow-up of 10%, 40 participants will be required in each group.

### Statistical analysis

The statistical analysis will be performed using a software program (SPSS V.22; IBM Corp., Armonk, New York, USA). The distribution of the variables was validated by D'Agostino-Pearson omnibus normality test. Parametric tests will be used for intergroup and intragroup comparisons. The paired t-test will be used for intergroup comparisons of the PLI, GI, PD, CAL, GRD, GRW, KTW and changes therein. Intragroup comparisons for the same variables will be performed using repeated measures one-way analysis of variance test, and followed by Bonferroni correction for post hoc multiple comparisons. The number of teeth with MRC and CRC in both groups will be compared using Fisher's exact test. Multiple imputations will be used to handle missing data. Two-tailed p-values $<$ 0.05 will be considered statistically significant.

Data analyses will be performed using SPSS software (V.22; IBM Corp., Armonk, New York, USA).

### Withdrawal

Participants will be allowed to withdraw from the study at any time without providing a reason. If a participant withdraws from the study, their treatment will not be affected. Intervention may be discontinued in case of postoperative adverse events.

### Dissemination of data

The results of this trial will be published at the International Clinical Trials Registry Platform (ICTRP) and in an international peer-reviewed journal, to ensure that the results are accessible to the public.

## DISCUSSION

Several graft substitutes for CTG and surgical techniques have been investigated to treat gingival recession.<sup>44 73 74</sup> ADM may increase the coverage of exposed roots and thickness of the keratinised gingiva.<sup>75 76</sup> However, previous studies that compared ADM and CTG reported conflicting results.<sup>75 77–79</sup>

Clinicians are becoming increasingly interested in the long-term outcomes of root coverage procedures.<sup>80–82</sup> A

study of the 20-year outcomes of CAF alone for the treatment of localised gingival recession reported that gingival recession decreased from 68.59% (at 1 year) to 56.11% (at 20 years), and the gingival margin remained stable in 56% of the treated sites.<sup>81</sup> In other study published by the same authors, patients treated with CAF +CTG for gingival recession were also evaluated, and CTG was reported to durable results, with minimal changes observed in the MRC (from 74.23% at 1 year to 67.69% at 20 years).<sup>83</sup> Similar results were reported for the recurrence of gingival recession following root coverage procedures.<sup>78 80 81 84</sup> A recent systematic review and network meta-analysis of periodontal soft tissue phenotype reported that graft materials significantly increased the GT. Additionally, KT was significantly increased after CTG and ADMG. The modification of periodontal soft tissue phenotype increased the expected benefits in root coverage procedures.<sup>62</sup> Previous studies have only evaluated the short-term outcomes of ADM during root coverage procedures.<sup>85–87</sup> However, long-term clinical studies reported significant worsening of the outcomes of root coverage using ADM.<sup>75 78</sup>

This study aims to compare the long-term outcomes of ADMG and CTG for treating single-tooth gingival recessions with a thin gingival phenotype. To the best of our knowledge, no previous studies have evaluated this. We hope that our results will improve the treatment for gingival recession. The main limitation of this study will be the lack of appraisal of the condition of exposed root. Additionally, the size of CTG may be limited by the palatal donor site in patients with multiple gingival recessions. Therefore, further studies will be required to evaluate the role of ADMG in the treatment of multiple gingival recessions.

### Trial status

The trial has been registered at International Clinical Trials Registry Platform (ICTRP), registered on 25 May 2020. The recruitment began in June 2020, and the recruitment will be completed in June 2021.

## ETHICS AND DISSEMINATION

The present study has received approval from the Ethics Committee of Peking University School and Hospital of Stomatology (PKUSSIRB-202054029). The patients will be enrolled in this trial only after their signature has been obtained. The study will be performed according to the 2013 revision of the Helsinki Declaration of 1975. Personal information of all subjects will be stored in Peking University School and Hospital of Stomatology. Data of this study will be registered with the International Clinical Trials Registry Platform. Additionally, we will disseminate the results through scientific journal.

### Author affiliations

First Clinical Division, Peking University School and Hospital of Stomatology & National Center of Stomatology & National Clinical Research Center for Oral Diseases & National Engineering Research Center of Oral Biomaterials and Digital

Medical Devices & Beijing Key Laboratory of Digital Stomatology & Research Center of Engineering and Technology for Computerized Dentistry Ministry of Health & NMPA Key Laboratory for Dental Materials, Beijing, Beijing, PR China

**Acknowledgements** We thank all enrolled subjects and patient advisers for their participation.

**Contributors** YZ, MW and FL conceive the study design and drafted the protocol. XC participates in the recruitment and allocation. YZ is the major contributor in writing the manuscript. All authors read and approved the final manuscript.

**Funding** This study is supported by research funds from the National Key Research and Development Programme: 2019YFB1404801 and the National Natural Science Foundations of China (NSFC): 81 800 976.

**Competing interests** None declared.

**Patient and public involvement** Patients and/or the public were not involved in the design, or conduct, or reporting or dissemination plans of this research.

**Patient consent for publication** Not required.

**Provenance and peer review** Not commissioned; externally peer reviewed.

**Open access** This is an open access article distributed in accordance with the Creative Commons Attribution Non Commercial (CC BY-NC 4.0) license, which permits others to distribute, remix, adapt, build upon this work non-commercially, and license their derivative works on different terms, provided the original work is properly cited, appropriate credit is given, any changes made indicated, and the use is non-commercial. See: <http://creativecommons.org/licenses/by-nc/4.0/>.

#### ORCID iD

Yalin Zhan <http://orcid.org/0000-0002-5387-9958>

#### REFERENCES

- Tugnait A, Clerehugh V. Gingival recession-its significance and management. *J Dent* 2001;29:381–94.
- Cortellini P, Bissada NF. Mucogingival conditions in the natural dentition: narrative review, case definitions, and diagnostic considerations. *J Periodontol* 2018;89 Suppl 1:S204–13.
- Wilson RD. Marginal tissue recession in general dental practice: a preliminary study. *Int J Periodontics Restorative Dent* 1983;3:40–53.
- Serino G, Wennström JL, Lindhe J, et al. The prevalence and distribution of gingival recession in subjects with a high standard of oral hygiene. *J Clin Periodontol* 1994;21:57–63.
- Löe H, Anerud A, Boysen H. The natural history of periodontal disease in man: prevalence, severity, and extent of gingival recession. *J Periodontol* 1992;63:489–95.
- Susin C, Haas AN, Oppermann RV, et al. Gingival recession: epidemiology and risk indicators in a representative urban Brazilian population. *J Periodontol* 2004;75:1377–86.
- Kassab MM, Cohen RE. The etiology and prevalence of gingival recession. *J Am Dent Assoc* 2003;134:220–5.
- Khocht A, Simon G, Person P, et al. Gingival recession in relation to history of hard toothbrush use. *J Periodontol* 1993;64:900–5.
- Paolantonio M, Dolci M, Esposito P, et al. Subpedicle acellular dermal matrix graft and autogenous connective tissue graft in the treatment of gingival recessions: a comparative 1-year clinical study. *J Periodontol* 2002;73:1299–307.
- Cohen DW, Ross SE. The double papillae repositioned flap in periodontal therapy. *J Periodontol* 1968;39:65–70.
- Sullivan HC, Atkins JH. Free autogenous gingival grafts. 3. utilization of grafts in the treatment of gingival recession. *Periodontics* 1968;6:152–60.
- Guinard EA, Caffesse RG. Treatment of localized gingival recessions. Part I. lateral sliding flap. *J Periodontol* 1978;49:351–6.
- Langer B, Langer L. Subepithelial connective tissue graft technique for root coverage. *J Periodontol* 1985;56:715–20.
- Tarnow DP. Semilunar coronally repositioned flap. *J Clin Periodontol* 1986;13:182–5.
- Allen EP, Miller PD. Coronal positioning of existing gingiva: short term results in the treatment of shallow marginal tissue recession. *J Periodontol* 1989;60:316–9.
- Pini Prato G, Pagliaro U, Baldi C, et al. Coronally advanced flap procedure for root coverage. flap with tension versus flap without tension: a randomized controlled clinical study. *J Periodontol* 2000;71:188–201.
- Cordioli G, Mortarino C, Chierico A, et al. Comparison of 2 techniques of subepithelial connective tissue graft in the treatment of gingival recessions. *J Periodontol* 2001;72:1470–6.
- Del Pizzo M, Zucchelli G, Modica F, et al. Coronally advanced flap with or without enamel matrix derivative for root coverage: a 2-year study. *J Clin Periodontol* 2005;32:1181–7.
- Trombelli L, Minenna L, Farina R, et al. Guided tissue regeneration in human gingival recessions. A 10-year follow-up study. *J Clin Periodontol* 2005;32:16–20.
- Pilloni A, Paolantonio M, Camargo PM. Root coverage with a coronally positioned flap used in combination with enamel matrix derivative: 18-month clinical evaluation. *J Periodontol* 2006;77:2031–9.
- Zucchelli G, Mele M, Mazzotti C, et al. Coronally advanced flap with and without vertical releasing incisions for the treatment of multiple gingival recessions: a comparative controlled randomized clinical trial. *J Periodontol* 2009;80:1083–94.
- Zucchelli G, De Sanctis M. The coronally advanced flap for the treatment of multiple recession defects: a modified surgical approach for the upper anterior teeth. *J Int Acad Periodontol* 2007;9:96–103.
- Zucchelli G. *Mucogingival esthetic surgery*. Milan: Quintessenza Edizione S.r.l, 2013.
- .Carvalho PFM, da Silva RC, Cury PR, et al. Modified coronally advanced flap associated with a subepithelial connective tissue graft for the treatment of adjacent multiple gingival recessions. *J Periodontol* 2006;77:1901–6.
- Chambrone LA, Chambrone L. Subepithelial connective tissue grafts in the treatment of multiple recession-type defects. *J Periodontol* 2006;77:909–16.
- Pini-Prato GP, Cairo F, Nieri M, et al. Coronally advanced flap versus connective tissue graft in the treatment of multiple gingival recessions: a split-mouth study with a 5-year follow-up. *J Clin Periodontol* 2010;37:644–50.
- Cordaro L, di Torresanto VM, Torsello F. Split-mouth comparison of a coronally advanced flap with or without enamel matrix derivative for coverage of multiple gingival recession defects: 6- and 24-month follow-up. *Int J Periodontics Restorative Dent* 2012;32:e10–20.
- Aroca S, Keglevich T, Barbieri B, et al. Clinical evaluation of a modified coronally advanced flap alone or in combination with a platelet-rich fibrin membrane for the treatment of adjacent multiple gingival recessions: a 6-month study. *J Periodontol* 2009;80:244–52.
- Ozturan S, Durukan SA, Ozcelik O, et al. Coronally advanced flap adjunct with low intensity laser therapy: a randomized controlled clinical pilot study. *J Clin Periodontol* 2011;38:1055–62.
- Hofmänner P, Alessandri R, Laugisch O, et al. Predictability of surgical techniques used for coverage of multiple adjacent gingival recessions--A systematic review. *Quintessence Int* 2012;43:545–54.
- Tatakis DN, Chambrone L, Allen EP, et al. Periodontal soft tissue root coverage procedures: a consensus report from the Aap regeneration workshop. *J Periodontol* 2015;86:S52–5.
- Cairo F, Cortellini P, Pilloni A, et al. Clinical efficacy of coronally advanced flap with or without connective tissue graft for the treatment of multiple adjacent gingival recessions in the aesthetic area: a randomized controlled clinical trial. *J Clin Periodontol* 2016;43:849–56.
- Monnet-Corti V, Santini A, Glise J-M, et al. Connective tissue graft for gingival recession treatment: assessment of the maximum graft dimensions at the palatal vault as a donor site. *J Periodontol* 2006;77:899–902.
- Klosek SK, Rungruang T. Anatomical study of the greater palatine artery and related structures of the palatal vault: considerations for palate as the subepithelial connective tissue graft donor site. *Surg Radiol Anat* 2009;31:245–50.
- Benninger B, Andrews K, Carter W. Clinical measurements of hard palate and implications for subepithelial connective tissue grafts with suggestions for palatal nomenclature. *J Oral Maxillofac Surg* 2012;70:149–53.
- Shepherd N, Greenwell H, Hill M, et al. Root coverage using acellular dermal matrix and comparing a coronally positioned tunnel with and without platelet-rich plasma: a pilot study in humans. *J Periodontol* 2009;80:397–404.
- Moses O, Artzi Z, Sculean A, et al. Comparative study of two root coverage procedures: a 24-month follow-up multicenter study. *J Periodontol* 2006;77:195–202.
- McGuire MK, Scheyer ET, Snyder MB. Xenogeneic collagen matrix with coronally advanced flap compared to connective tissue with coronally advanced flap for the treatment of dehiscence-type recession defects. *J Periodontol* 2010;81:1108–17.
- Cardaropoli D, Tamagnone L, Roffredo A, et al. Treatment of gingival recession defects using coronally advanced flap with a porcine collagen matrix compared to coronally advanced flap with connective tissue graft: a randomized controlled clinical trial. *J Periodontol* 2012;83:321–8.

- 40 Jepsen K, Stefanini M, Sanz M, *et al.* Long-term stability of root coverage by Coronally advanced flap procedures. *J Periodontol* 2017;88:626–33.
- 41 Aichelmann-Reidy ME, Yukna RA, Evans GH, *et al.* Clinical evaluation of acellular allograft dermis for the treatment of human gingival recession. *J Periodontol* 2001;72:998–1005.
- 42 Joly JC, Carvalho AM, da Silva RC, *et al.* Root coverage in isolated gingival recessions using autograft versus allograft: a pilot study. *J Periodontol* 2007;78:1017–22.
- 43 Cieslik-Wegemund M, Wierucka-Młynarczyk B, Tanasiewicz M, *et al.* Tunnel technique with collagen matrix compared with connective tissue graft for treatment of periodontal recession: a randomized clinical trial. *J Periodontol* 2016;87:1436–43.
- 44 Pietruska M, Skurska A, Podlewski Łukasz, *et al.* Clinical evaluation of Miller class I and II recessions treatment with the use of modified coronally advanced tunnel technique with either collagen matrix or subepithelial connective tissue graft: a randomized clinical study. *J Clin Periodontol* 2019;46:86–95.
- 45 Allen EP. Alloderm: an effective alternative to palatal donor tissue for treatment of gingival recession. *Dent Today* 2006;25:48, 50-2; quiz 52.
- 46 Wainwright DJ. Use of an acellular allograft dermal matrix (alloderm) in the management of full-thickness burns. *Burns* 1995;21:243–8.
- 47 Shulman J. Clinical evaluation of an acellular dermal allograft for increasing the zone of attached gingiva. *Pract Periodontics Aesthet Dent* 1996;8:201–8.
- 48 Chambrone L, Tatakis DN. Periodontal soft tissue root coverage procedures: a systematic review from the Aap regeneration workshop. *J Periodontol* 2015;86:S8–51.
- 49 Batista EL, Batista FC, Novaes AB, EL Jr B, AB Jr N. Management of soft tissue ridge deformities with acellular dermal matrix. clinical approach and outcome after 6 months of treatment. *J Periodontol* 2001;72:265–73.
- 50 Wei PC, Laurell L, Geivelis M, *et al.* Acellular dermal matrix allografts to achieve increased attached gingiva. Part 1. A clinical study. *J Periodontol* 2000;71:1297–305.
- 51 Wei P-C, Laurell L, Lingen MW, *et al.* Acellular dermal matrix allografts to achieve increased attached gingiva. Part 2. A histological comparative study. *J Periodontol* 2002;73:257–65.
- 52 Yan J-J, Tsai AY-M, Wong M-Y, *et al.* Comparison of acellular dermal graft and palatal autograft in the reconstruction of keratinized gingiva around dental implants: a case report. *Int J Periodontics Restorative Dent* 2006;26:287–92.
- 53 Novaes AB, Souza SL. Acellular dermal matrix graft as a membrane for guided bone regeneration: a case report. *Implant Dent* 2001;10:192–6.
- 54 Fernandes PG, Novaes AB, de Queiroz AC, *et al.* Ridge preservation with acellular dermal matrix and anorganic bone matrix cell-binding peptide P-15 after tooth extraction in humans. *J Periodontol* 2011;82:72–9.
- 55 de Andrade PF, de Souza SLS, de Oliveira Macedo G, Macedo GO, *et al.* Acellular dermal matrix as a membrane for guided tissue regeneration in the treatment of class II furcation lesions: a histometric and clinical study in dogs. *J Periodontol* 2007;78:1288–99.
- 56 de Queiroz Côrtes A, Sallum AW, Casati MZ, *et al.* A two-year prospective study of coronally positioned flap with or without acellular dermal matrix graft. *J Clin Periodontol* 2006;33:683–9.
- 57 Felipe MEMC, Andrade PF, Grisi MFM, *et al.* Comparison of two surgical procedures for use of the acellular dermal matrix graft in the treatment of gingival recessions: a randomized controlled clinical study. *J Periodontol* 2007;78:1209–17.
- 58 Cairo F, Nieri M, Pagliaro U. Efficacy of periodontal plastic surgery procedures in the treatment of localized facial gingival recessions. A systematic review. *J Clin Periodontol* 2014;41 Suppl 15:S44–62.
- 59 Woodyard JG, Greenwell H, Hill M, *et al.* The clinical effect of acellular dermal matrix on gingival thickness and root coverage compared to coronally positioned flap alone. *J Periodontol* 2004;75:44–56.
- 60 Hwang D, Wang H-L. Flap thickness as a predictor of root coverage: a systematic review. *J Periodontol* 2006;77:1625–34.
- 61 Berlucchi I, Francetti L, Del Fabbro M, *et al.* The influence of anatomical features on the outcome of gingival recessions treated with coronally advanced flap and enamel matrix derivative: a 1-year prospective study. *J Periodontol* 2005;76:899–907.
- 62 Barootchi S, Tavelli L, Zucchelli G, *et al.* Gingival phenotype modification therapies on natural teeth: a network meta-analysis. *J Periodontol* 2020;91:1386–99.
- 63 Jepsen S, Caton JG, Albandar JM, *et al.* Periodontal manifestations of systemic diseases and developmental and acquired conditions: consensus report of Workgroup 3 of the 2017 world workshop on the classification of periodontal and peri-implant diseases and conditions. *J Periodontol* 2018;89 Suppl 1:S237–48.
- 64 Rasperini G, Acunzo R, Cannalire P, *et al.* Influence of periodontal biotype on root surface exposure during orthodontic treatment: a preliminary study. *Int J Periodontics Restorative Dent* 2015;35:665–75.
- 65 Rasperini G, Codari M, Paroni L, *et al.* The influence of gingival phenotype on the outcomes of Coronally advanced flap: a prospective multicenter study. *Int J Periodontics Restorative Dent* 2020;40:e27–34.
- 66 Pilloni A, Schmidlin PR, Sahrman P, *et al.* Effectiveness of adjunctive hyaluronic acid application in coronally advanced flap in Miller class I single gingival recession sites: a randomized controlled clinical trial. *Clin Oral Investig* 2019;23:1133–41.
- 67 de Sanctis M, Zucchelli G. Coronally advanced flap: a modified surgical approach for isolated recession-type defects: three-year results. *J Clin Periodontol* 2007;34:262–8.
- 68 Harris RJ. Root coverage with a connective tissue with partial thickness double pedicle graft and an acellular dermal matrix graft: a clinical and histological evaluation of a case report. *J Periodontol* 1998;69:1305–11.
- 69 Schiott CR, Løe H, Jensen SB, *et al.* The effect of chlorhexidine mouthrinses on the human oral flora. *J Periodontol Res* 1970;5:84–9.
- 70 Cairo F, Rotundo R, Miller PD, *et al.* Root coverage esthetic score: a system to evaluate the esthetic outcome of the treatment of gingival recession through evaluation of clinical cases. *J Periodontol* 2009;80:705–10.
- 71 Cortellini P, Tonetti M, Baldi C, *et al.* Does placement of a connective tissue graft improve the outcomes of coronally advanced flap for coverage of single gingival recessions in upper anterior teeth? A multi-centre, randomized, double-blind, clinical trial. *J Clin Periodontol* 2009;36:68–79.
- 72 Ahmedbeyli C, Ipci Şebnem Dirikan, Cakar G, *et al.* Clinical evaluation of coronally advanced flap with or without acellular dermal matrix graft on complete defect coverage for the treatment of multiple gingival recessions with thin tissue biotype. *J Clin Periodontol* 2014;41:303–10.
- 73 Romanos AH, Abou-Araj RV, Cruz SE, *et al.* Clinical and patient-centered outcomes following treatment of multiple gingival recessions using acellular dermal matrix allografts. *Int J Periodontics Restorative Dent* 2017;37:843–51.
- 74 Vincent-Bugnas S, Borie G, Charbit Y. Treatment of multiple maxillary adjacent class I and II gingival recessions with modified coronally advanced tunnel and a new xenogeneic acellular dermal matrix. *J Esthet Restor Dent* 2018;30:89–95.
- 75 Harris RJ. A short-term and long-term comparison of root coverage with an acellular dermal matrix and a subepithelial graft. *J Periodontol* 2004;75:734–43.
- 76 Scarano A, Barros RRM, Iezzi G, *et al.* Acellular dermal matrix graft for gingival augmentation: a preliminary clinical, histologic, and ultrastructural evaluation. *J Periodontol* 2009;80:253–9.
- 77 Barros RRM, Macedo GO, de Queiroz AC, *et al.* A modified surgical flap for root coverage in association with grafting materials. *J Esthet Restor Dent* 2015;27:84–91.
- 78 Moslemi N, Mousavi Jazi M, Haghghati F, *et al.* Acellular dermal matrix allograft versus subepithelial connective tissue graft in treatment of gingival recessions: a 5-year randomized clinical study. *J Clin Periodontol* 2011;38:1122–9.
- 79 de Souza SLS, Novaes AB, Grisi DC, *et al.* Comparative clinical study of a subepithelial connective tissue graft and acellular dermal matrix graft for the treatment of gingival recessions: six- to 12-month changes. *J Int Acad Periodontol* 2008;10:87–94.
- 80 Nickles K, Ratka-Krüger P, Neukrand E, *et al.* Ten-year results after connective tissue grafts and guided tissue regeneration for root coverage. *J Periodontol* 2010;81:827–36.
- 81 Pini Prato GP, Magnani C, Chambrone L. 20 years) of the outcomes of coronally advanced flap in the treatment of single recession-type defects. *J Periodontol* 2018;89:265–74.
- 82 Rasperini G, Acunzo R, Pellegrini G, *et al.* Predictor factors for long-term outcomes stability of coronally advanced flap with or without connective tissue graft in the treatment of single maxillary gingival recessions: 9 years results of a randomized controlled clinical trial. *J Clin Periodontol* 2018;45:1107–17.
- 83 Pini Prato GP, Franceschi D, Cortellini P, *et al.* 20 years) of the outcomes of subepithelial connective tissue graft plus coronally advanced flap in the treatment of maxillary single recession-type defects. *J Periodontol* 2018;89:1290–9.
- 84 Pini Prato G, Rotundo R, Franceschi D, *et al.* Fourteen-Year outcomes of coronally advanced flap for root coverage: follow-up from a randomized trial. *J Clin Periodontol* 2011;38:715–20.



- 85 Ayub LG, Ramos UD, Reino DM, *et al.* A randomized comparative clinical study of two surgical procedures to improve root coverage with the acellular dermal matrix graft. *J Clin Periodontol* 2012;39:871–8.
- 86 Ozenci I, Ipci SD, Cakar G, *et al.* Tunnel technique versus coronally advanced flap with acellular dermal matrix graft in the treatment of multiple gingival recessions. *J Clin Periodontol* 2015;42:1135–42.
- 87 Wang H-L, Romanos GE, Geurs NC, *et al.* Comparison of two differently processed acellular dermal matrix products for root coverage procedures: a prospective, randomized multicenter study. *J Periodontol* 2014;85:1693–701.