

Case Study

Carpal tunnel syndrome after an electrical injury: a case report and review of literature

Yi-Sin Wong^{1,4}, Cheung-Ter Ong^{2,3}, Yi-Ying Hsieh¹, Tuey-Wen Hung¹ and How-Ran Guo^{4,5,6}

¹Department of Family Medicine, Ditmanson Medical Foundation Chia-Yi Christian Hospital, Chia-Yi, Taiwan, ²Department of Neurology, Ditmanson Medical Foundation Chia-Yi Christian Hospital, Chia-Yi, Taiwan, ³Department of Nursing, Chung Jen Junior College of Nursing, Health Science and Management, Chia-Yi, Taiwan, ⁴Department of Environmental and Occupational Health, National Cheng Kung University, Tainan, Taiwan, ⁵Department of Occupational and Environmental Medicine, National Cheng Kung University Hospital, Tainan, Taiwan and ⁶Occupational Safety, Health, and Medicine Research Center, National Cheng Kung University, Tainan, Taiwan

Abstract: Introduction: Carpal tunnel syndrome (CTS) is prevalent in workers who utilize hand-held vibration tools, engage in tasks involving repetitive wrist movements, and suffer from wrist overuse. Although electrical injuries involving the median nerve are a relatively rare but plausible cause of CTS, the related literature is limited. Here, we report a case of CTS in which the symptoms developed after an electrical injury, and review the related literature. **Case summary:** The patient was a right-handed male electrician who often used hand tools but had no symptoms of CTS before the injury, with the left hand as the point of entry. Typical symptoms of CTS manifested after the electrical injury, and a nerve conduction velocity test confirmed the presence of severe CTS in the left hand. Therefore, we believe that the symptoms can be largely attributed to the electrical injury. **Conclusions:** The available literature supports the occurrence of delayed compressive neuropathy caused by scarring from substantial cutaneous burns in patients with electrical injuries. This case shows that electrical injuries may cause CTS in the absence of severe scarring through other mechanisms such as direct injuries to the nerve. Therefore, patients with electrical burns should be routinely examined for peripheral nerve compression symptoms in follow-ups, even when there are minimal cutaneous burns.

(J Occup Health 2018; 60: 320-323)
doi: 10.1539/joh.2017-0247-CS

©Article author(s). This is an Open Access article distributed under the Creative Commons Attribution-NonCommercial-ShareAlike 4.0 International License. To view the details of this license, please visit (<https://creativecommons.org/licenses/by-nc-sa/4.0/>).

Key words: Burn, Carpal tunnel syndrome, Compressive neuropathy, Electrical injury, Nerve conduction velocity, Occupational medicine

Introduction

Carpal tunnel syndrome (CTS) is a peripheral mononeuropathy of the upper limb caused by the compression of the median nerve as it passes through the carpal tunnel and into the wrist. It is a common condition in working-age people, and occupational activities such as repeated and forceful movements of the hand and wrist and the use of hand-held vibration tools have been identified as risk factors¹. Typical symptoms of CTS consist of sensory and motor features such as gradual onset of numbness, tingling, and even pain in the median nerve distribution of the hand, together with evidence of delayed nerve conduction².

Damages to the median nerve induced by electrical injuries are a plausible cause of CTS. However, the literature regarding the association between electrical injuries and CTS is limited, and most of the previous reports have described cases with relatively severe burns which caused nerve compression due to scarring^{3,4}. Here, we present the case of a patient with CTS who developed symptoms af-

Received September 8, 2017; Accepted March 22, 2018

Published online in J-STAGE June 14, 2018

Correspondence to: H.R. Guo, Department of Environmental and Occupational Health, College of Medicine, National Cheng Kung University, 1 Daxue Road, East District, Tainan 701, Taiwan (e-mail: hrguo@mail.ncku.edu.tw)

Abbreviations

CTS = carpal tunnel syndrome, NCV = nerve conduction velocity

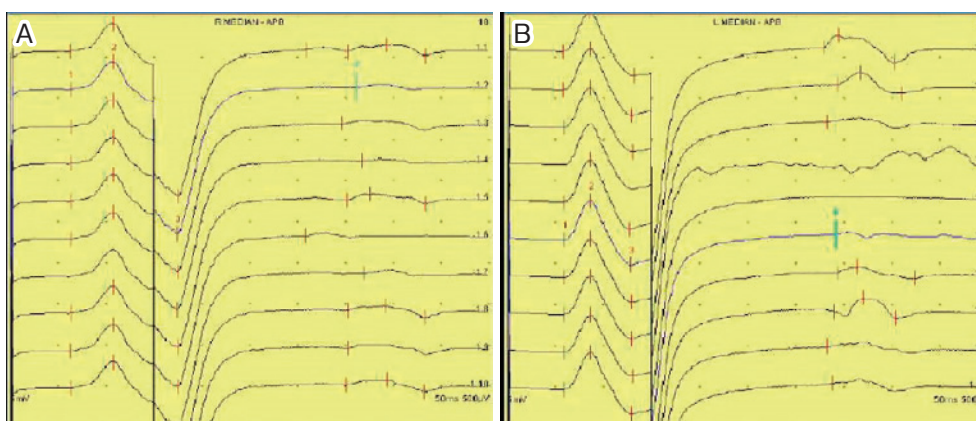


Fig. 1. Bilateral carpal tunnel syndrome observed in the nerve conduction velocity test.
 (A) Right median nerve (latency: 4.65 ms)
 (B) Left median nerve (latency: 5.45 ms)

ter an electrical injury with minimal burns, and we also review the relevant literature to discuss the possible mechanisms contributing to the case. We aim to demonstrate the plausibility of a low-voltage electrical injury causing CTS without significant burns that lead to scarring of peripheral tissue.

Case Report

A 49-year-old male was brought to the emergency department of a medical center after suffering from an electrical injury. The patient was right-handed and had been working as an electrician for more than 30 years, with 4 years at his current job at a resort. This work primarily involves weight-bearing, climbing up and down, and using hand tools to repair machines and electronics such as lights and air-conditioners. Tools used include screwdrivers, drills, wrenches, scissors, etc., and only a few are electrically powered. He works 8-9 hours per day and sometimes up to 12 hours with rotating shifts. The patient stated that he does not routinely work with his hands outside of his job, and had no systemic diseases that may involve the nerves such as diabetes and thyroid disease.

The patient was injured from a 220 V alternating current while repairing a machine on a rainy day. While holding a pair of scissors in his right hand, he accidentally touched a bare cable with his left hand. He wore rubber shoes but did not wear gloves. The patient lost consciousness and fell down backwards after being shocked, but regained consciousness after hitting his back on a cabinet. He was sent to the emergency department, where a first-degree burn approximately 1 cm in diameter was observed on his left hand, which was most likely caused by the electrical injury. His laboratory tests were generally within normal ranges, except for a slightly elevated myoglobin level, and imaging studies revealed normal findings. He was discharged on the same day after being diag-

nosed with an electrical injury. After discharge, he received follow-ups in the outpatient department as suggested.

A few days later, the patient developed bilateral lower leg soreness and pain and returned to the hospital. Mild rhabdomyolysis was suspected on the basis of these symptoms and the elevated level of myoglobin noted in the emergency department, and he rested for 2 months as suggested. However, during these 2 months he gradually developed numbness in both hands, causing him to wake up once or twice a night due to discomfort. After 2 months of rest, he returned to the same job, but the numbness in both hands progressed. He visited the occupational medicine outpatient department where the physical examination showed a positive Phalen's test but not Tinel's sign. A nerve conduction velocity (NCV) test showed bilateral CTS (Fig. 1) and bilateral cubital tunnel syndrome (Fig. 2), and the NCV test result was near the lower normal limit. Because of the severe numbness in both hands, he was treated with physical therapy and occupational therapy for about half a year. Following significant improvements in CTS symptoms, the patient was able to return to work.

Discussion

The individual predisposing factors of CTS include smoking, diabetes, obesity, hypothyroidism, and female sex⁵. Occupational risk factors include repetitive use of the hand such as heavy manual work, working with vibrating tools, and highly repetitive tasks¹. Typical clinical symptoms of CTS include gradual onset of numbness, tingling, and even pain in the median nerve distribution of the hand, together with evidence of delayed nerve conduction². Our case demonstrated these typical clinical presentations.

The severity of an electrical injury depends on the pas-

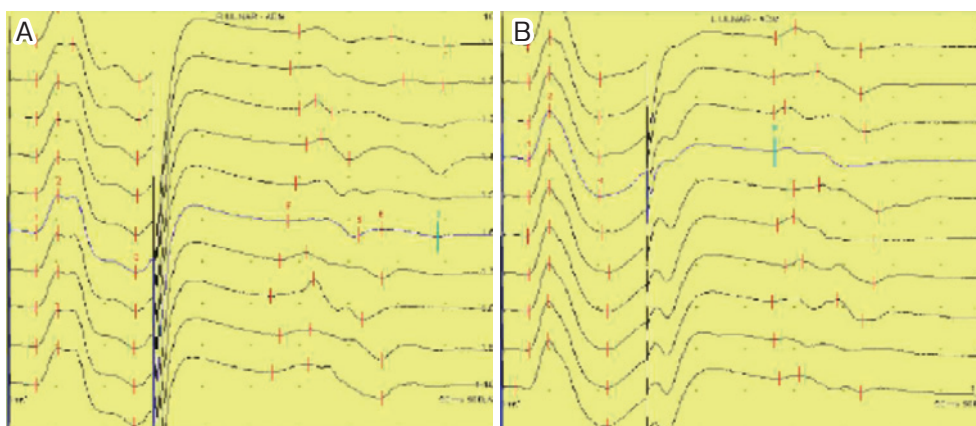


Fig. 2. Bilateral cubital tunnel syndrome observed in the nerve conduction velocity test.
 (A) Right ulnar nerve
 (B) Left ulnar nerve

sage of electric current through the body and other factors such as the type of circuit and current, the voltage of the circuit, the resistance of tissues, the amperage of the current, the pathway of the current, and the duration of contact^{6,7}. Charged particles collide with molecules in the tissue, losing energy in the form of heat. The amount of energy dissipated as heat by the electric current is given by the law $(\text{current})^2 \times \text{resistance} \times \text{time}$, and most of the tissue damage is caused by the disruption of cell membranes⁸. Electrical injuries are generally classified as those caused by high voltage (>1000 V) or low voltage (<1000 V);⁹ our case was in the low-voltage range (220 V).

Compressive neuropathy, especially CTS, is caused by direct pressure on a nerve and is not uncommon after electrical burns^{3,4,10-12}. In a 17-year review of burn unit admissions, 22% of the patients with electrical injuries were found to have permanent nerve damage. The upper limb was the most frequently injured, and the median and ulnar nerves are usually affected¹⁰. In a retrospective study aiming at identifying CTS following different types of burn injuries among burn center patients, 9 of the 28 patients with burns in the upper extremities had electrical burns⁴. In another study on patients requiring nerve decompression secondary to thermal or electrical burns, CTS was the most common cause of compression, accounting for 46% of the cases³. Four of the patients had electrical injuries, with three patients having high-voltage injuries and the fourth having a low-voltage injury. During the 4-year follow-up period, patients with electrical injuries had an average of 1.5 compressed nerves. CTS accounted for five (83%) of all the nerve decompressions in electrical burn injuries, with the remaining one being attributed to radial tunnel syndrome. Therefore, some clinicians have recommended fasciotomies for patients who have high-voltage (or associated crush) injuries with entrance or exit wounds in the extremities, and release of the carpal tunnel is practiced routinely in some services for cases with elec-

trical injuries¹³.

A low-voltage electrical injury may also lead to neuropathy. In a study of 648 burn patients, 16 patients developed mononeuropathy after a low-voltage electrical injury¹¹. One patient with only a 2% superficial partial-thickness burn on the right forearm developed median mononeuropathy on the wrist and a distal slowing of the ulnar nerve¹². Even without significant cutaneous burns, low-voltage electrical injuries may also lead to peripheral neuropathy¹⁰. Therefore, in addition to the compression caused by scar tissue after burns, several mechanisms have been proposed to explain the injury to neuronal tissue after electrocution, such as thermal damage, sympathetic stimulation, vascular damage, histological and electrophysiological changes, and direct mechanical trauma¹⁴. It has been shown by experiments that electrocution can lead to nerve dysfunction through both thermal and non-thermal mechanisms. The possible mechanisms that reflect the temporal relationship with the electrical injury include thermal injury to the perineural tissues, which leads to a progressive perineural fibrosis with compressive neuropathy, and direct thermal damage to the nerve resulting in necrosis^{10,15}.

In a study on electrical injuries with burns, compressive neuropathy was diagnosed 46 to 1,530 days after the burn injury, and CTS was the most common neuropathy, accounting for 46% of all nerve decompressions³. Our case developed numbness and was diagnosed with CTS within this time range.

Our patient suffered from electrical injuries when he touched a bare cable with his left hand while holding a pair of scissors with his right hand on a rainy day. Electricity passes through the path of least resistance, and the resistance of a nerve is lower than that of a muscle or bone¹⁵. Accordingly, the current most likely entered through his left hand and exited through his right hand. Therefore, it is reasonable that both his hands were af-

ected. When an electric current passes through a narrow pathway, such as the carpal tunnel or the cubital tunnel, the increased resistance and longer contact time may cause more energy to be transmitted as heat. Because more electrical energy is transformed to heat in high resistance areas, the damage caused by an electrical injury might be much more severe in the carpal and cubital tunnels than in a direct nerve injury. The heat energy generated when electricity passes through the narrow pathway such as the carpal tunnel or cubital tunnel may lead to perineural fibrosis and nerve damage. The NCV test showed damages to both the median and cubital nerves, and supports our interpretation. Because it is difficult to recover from such damage, the patient received regular follow-ups at our outpatient clinic.

Conclusion

Based on a review of the literature, we conclude that an electrical injury may cause neuropathies such as CTS, potentially through pathways such as perineural fibrosis and nerve necrosis. Moreover, a low-voltage electrical injury may still lead to CTS, even without cutaneous burns that cause sufficient scarring to induce remarkable nerve compression. Therefore, patients with electrical burns should be routinely examined for peripheral nerve symptoms during subsequent follow-ups.

Consent to Publish

Written informed consent was obtained from the patient for publication of this case report and accompanying images. A copy of the written consent is available for review by the Editor of this journal.

Authors' Contributions

Y-SW and H-RG were responsible for clinical management of the case and drafting the manuscript. Y-SW, C-TO, Y-YH, and T-WH contributed to the review of the literature and interpretation of data. All authors participated in the writing of the manuscript and have read and approved the final manuscript.

Acknowledgments: The work is supported by a grant from the Ministry of Labor, Taiwan, R.O.C. to H-RG.

Conflicts of interest: None declared.

References

- 1) Wieslander G, Norbäck D, Göthe CJ, et al. Carpal tunnel syndrome (CTS) and exposure to vibration, repetitive wrist movements, and heavy manual work: a case-referent study. *Br J Ind Med* 1989; 46(1): 43-47.
- 2) Said G, Krarup C. Compression and entrapment neuropathies. *Peripheral Nerve Disorders: Handbook of Clinical Neurology* (Series Editors: Aminoff, Boller and Swaab) 2013; 115: 311.
- 3) Ferguson JS, Franco J, Pollack J, et al. Compression neuropathy: a late finding in the postburn population: a four-year institutional review. *J Burn Care Res* 2010; 31(3): 458-461.
- 4) Hassan Z, Mullins RF, Alam B, et al. Carpal tunnel syndrome following burns. *Ann Burns Fire Disasters* 2008; 21(3): 153.
- 5) Karpitskaya Y, Novak CB, Mackinnon SE. Prevalence of smoking, obesity, diabetes mellitus, and thyroid disease in patients with carpal tunnel syndrome. *Ann Plast Surg* 2002; 48(3): 269-273.
- 6) Winkelman MD. Chapter 36 - Neurologic Complications of Thermal and Electric Burns A2 - Aminoff, Michael J. In: Josephson SA, editor. *Aminoff's Neurology and General Medicine*. Fifth Edition. Boston: Academic Press; 2014. p. 753-765.
- 7) Lochaitis A, Parker I, Stavropoulou V, et al. Neurological disorders following electrical burn injuries. *Annals of the MBC* 1991; 4: 84-89.
- 8) Tuttnauer A, Mordzynski SC, Weiss YG. Electrical and lightning injuries. *Contemporary Critical Care* 2006; 4(7): 1-9.
- 9) Rai J, Jeschke MG, Barrow RE, et al. Electrical injuries: a 30-year review. *J Trauma* 1999; 46(5): 933-936.
- 10) Smith MA, Muehlberger T, Dellon AL. Peripheral Nerve Compression Associated with Low-Voltage Electrical Injury without Associated Significant Cutaneous Burn. *Plast Reconstr Surg* 2002; 109(1): 137-144.
- 11) Tamam Y, Tamam C, Tamam B, et al. Peripheral neuropathy after burn injury. *Eur Rev Med Pharmacol Sci* 2013; 17(suppl 1): 107-111.
- 12) Rosenberg DB. Neurologic sequelae of minor electric burns. *Arch Phys Med Rehabil* 1989; 70: 914-915.
- 13) Piccolo NS, Piccolo MS, Piccolo PD, et al. Escharotomies, fasciotomies and carpal tunnel release in burn patients-review of the literature and presentation of an algorithm for surgical decision making. *Handchir Mikrochir Plast Chir* 2007; 39(3): 161-167.
- 14) Grube BJ, Heimbach DM, Engrav LH, et al. Neurologic consequences of electrical burns. *J Trauma* 1990; 30(3): 254-258.
- 15) Schaefer NR, Yaxley JP, O'Donohue P, et al. Electrical burn causing a unique pattern of neurological injury. *Plast and Reconstr Surg Glob Open* 2015; 3(4): e378.