

# Comparison of Anterior Chamber Depth between Normal and Keratoconic Eyes: A Systematic Review and Meta-Analysis

Hassan Hashemi<sup>1</sup>, AbbasAli Yekta<sup>2</sup>, Negareh Yazdani<sup>3</sup>, Hadi Ostadimoghaddam<sup>4</sup>, Mehdi Khabazkhoob<sup>5</sup>

<sup>1</sup>Noor Research Center for Ophthalmic Epidemiology, Noor Eye Hospital, Tehran, Iran, <sup>2</sup>Department of Optometry, School of Paramedical Sciences, Mashhad University of Medical Sciences, Mashhad, Iran, <sup>3</sup>Student Research Committee, Mashhad University of Medical Sciences, Mashhad, Iran, <sup>4</sup>Refractive Errors Research Center, School of Paramedical Sciences, Mashhad University of Medical Sciences, Mashhad, Iran, <sup>5</sup>Department of Medical Surgical Nursing, School of Nursing and Midwifery, Shahid Beheshti University of Medical Sciences, Tehran, Iran

## Abstract

**Purpose:** To review the published data about changes in the anterior chamber depth (ACD) in keratoconus patients.

**Methods:** In this systematic review and meta-analysis of observational studies, we reviewed the available and relevant literature on anterior segment changes in keratoconic eyes, with a special focus on the ACD, an effective factor in many surgical methods. Articles published up to December 2017 were identified in the following data sources: PubMed, Scopus, Ovid, ISI, ScienceDirect, and Google Scholar. Databases were comprehensively searched using the key words "Anterior Chamber Depth AND Anterior segment AND Keratoconus".

**Results:** A total of 496 studies including these key words were detected. Four hundred fifty-three studies were excluded, and overall 16 studies which precisely described the change in ACD were included in the literature review. The results show that with respect to the applied device, there was a statistically significant difference in ACD between keratoconic eyes and normal eyes except for Galilei analyzer.

**Conclusion:** Summarizing the results of studies, this review revealed that ACD is significantly deeper in keratoconic eyes as compared with normal eyes, which could be explained by the steeper corneal curvature.

**Keywords:** Anterior chamber depth, Anterior segment, Keratoconus

**Address for correspondence:** Negareh Yazdani, Student Research Committee, Mashhad University of Medical Sciences, Mashhad, Iran.  
E-mail: negar5236@gmail.com

**Submitted:** 24-Jul-2018; **Revised:** 11-Jan-2019; **Accepted:** 24-Jan-2019; **Published:** 23-Mar-2020

## INTRODUCTION

Keratoconus, is an ectatic, non-inflammatory, bilateral, and asymmetric disorder of the eye. It begins at puberty and stabilizes during the fourth decade.<sup>1</sup> Clinical application in keratoconus requires precise measurements of anterior segment parameters, particularly anterior chamber, which is important in ophthalmology, including preoperative examination and glaucoma management. Anterior chamber depth (ACD) is the distance between the posterior of the cornea and anterior surface of the crystalline lens, and is approximately 3 mm. Age, gender, refractive error, and cataract formation have been reported to affect the ACD.<sup>2</sup> Several studies compared

ACD in keratoconic and normal eyes, and results have been reported. Some inconsistency in results and the importance of precise ACD values in clinical decision led us to conduct the review to gain a better understanding of ACD changes in keratoconus patients.

## METHODS

Initially, we searched studies that have evaluated the ACD in keratoconus patients. A comprehensive computer literature search of databases PubMed, Scopus, Ovid, ISI, ScienceDirect,

This is an open access journal, and articles are distributed under the terms of the Creative Commons Attribution-NonCommercial-ShareAlike 4.0 License, which allows others to remix, tweak, and build upon the work non-commercially, as long as appropriate credit is given and the new creations are licensed under the identical terms.

**For reprints contact:** reprints@medknow.com

**How to cite this article:** Hashemi H, Yekta A, Yazdani N, Ostadimoghaddam H, Khabazkhoob M. Comparison of anterior chamber depth between normal and keratoconic eyes: A systematic review and meta-analysis. *J Curr Ophthalmol* 2020;32:94-8.

### Access this article online

Quick Response Code:



Website:  
www.jcurrophthalmol.org

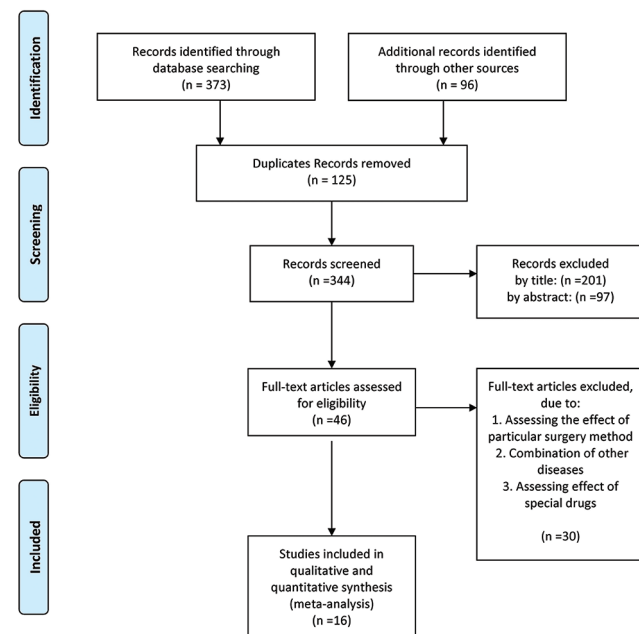
DOI:  
10.1016/j.joco.2019.01.010

and Google Scholar was conducted to find published articles on this topic. The search algorithm was based on combinations of the following terms: Anterior chamber depth, Anterior segment, and Keratoconus. A beginning date limit was not used, and the search was updated until December 2017 without language restrictions. To identify additional studies and expand our search, the references of the retrieved articles were also screened. Two of the authors (N.Y. and M.K.) independently conducted a systematic search.

Statistical analyses were performed using STATA version 11.0 (College Station, Texas) and RevMan Version 5.3 (Cochrane Collaboration). Mean, standard deviation, and sample size were extracted for both the keratoconus and normal group. Then standardized mean difference was calculated for each study. Standard deviation of the difference was calculated using Cohen approach. Cochran's Q-test of heterogeneity was applied to detect the heterogeneity, and between-study heterogeneity was quantified using the  $I^2$  Statistic. According to Higgins grading scale,  $I^2$  value achieving 0.7 or more shows high heterogeneity. Random-effect model was chosen for determining Pooled SMD. Meta-regression method was also applied to evaluate the impact of important factors, age, sample size, publication date, and device on the studies' heterogeneity. Meta-bias and Eggers test were used to evaluate the publication bias. Meta-funnel principles were used to create a funnel plot. Due to the low power of Eggers test, 0.1 was considered a level of significance. For other tests, 0.05 was the level of the statistical significance.

## RESULTS

Figure 1 illustrates the flow of literature reviewed. Our computerized search identified 469 relevant studies. From



**Figure 1:** Follow diagram of systematic review and meta-analysis

this, 125 were excluded because of duplication. Two hundred and one studies were excluded after title review. Ninety-seven studies were excluded at the abstract review stage, and 30 studies were excluded at full text screening stage. The final 16 eligible studies were included. One thousand four hundred thirty-five keratoconic eyes and 1334 normal eyes were analyzed.

Table 1 shows the extracted data of included studies.

Figure 2 shows the forest plot for Pooled SMD and 95% confidence interval (CI) based on applied device in each study. There was a statistically significant difference between Pooled SMD according to applied device ( $\chi^2$ : 41.23;  $P < 0.001$ ). As it has been illustrated, Pooled SMD for Pentacam was 0.61 (0.50-0.72), 1.22 (0.52-1.92) for optical coherence tomography, 0.50 (0.28-0.72) for Orbscan, and 1.06 (0.72-1.40) for Sirius. The results showed the significant deeper ACD in keratoconic eyes compared with normal eyes. Pooled SMD for Galilei analyzer did not show the significant difference in ACD between keratoconus and normal groups. (SMD: -0.02; 95% CI: -0.23 to 0.19).

Considering Q-test results, there was significant heterogeneity between Pooled SMD in each study ( $\chi^2$ : 52.84;  $P < 0.001$ ).  $I^2$  value of 72% implied considerable heterogeneity. Table 2 shows the results of meta-regression analysis. After adjusting for the factors of age, sample size, and year of publication, we found that applied device had considerable effect on heterogeneity ( $b$ : 0.213;  $P < 0.001$ ).

The result of Egger's test indicated that significant bias did not exist between studies ( $b$ : 1.78;  $P$ : 0.275) [Figure 3].

## DISCUSSION

This article represents a systematic and comprehensive review of published data involving ACD changes in keratoconus. Studies have shown that it is significantly deeper in keratoconus patients than normal controls.<sup>2,4,5</sup> A number of studies evaluated the rate of progression in ACD in different stages of keratoconus and reported that along with progression of the KCN, ACD will be deeper.<sup>1,3,6,8,16</sup> Just in one study by Abolbashi *et al.*, ACD was evaluated at center, 1 mm paracentral, and thinnest pachymetry in different stages of the KCN and compared with normal eye and reported a similar result.<sup>3</sup> In contradiction to previous above-mentioned studies, Montalbán *et al.* reported that there is no statistically significant difference in the ACD between keratoconic and normal eyes.<sup>13</sup> The difference in result could be due to the measurement system or the wide age-range of the population. This analysis demonstrates that ACD is one of the most important factors in ocular surgery, and glaucoma management is deeper in keratoconic eyes than normal, which could be due to anterior protrusion of the central. Therefore, accurately measured ACD is essential for preoperative examination and glaucoma management.

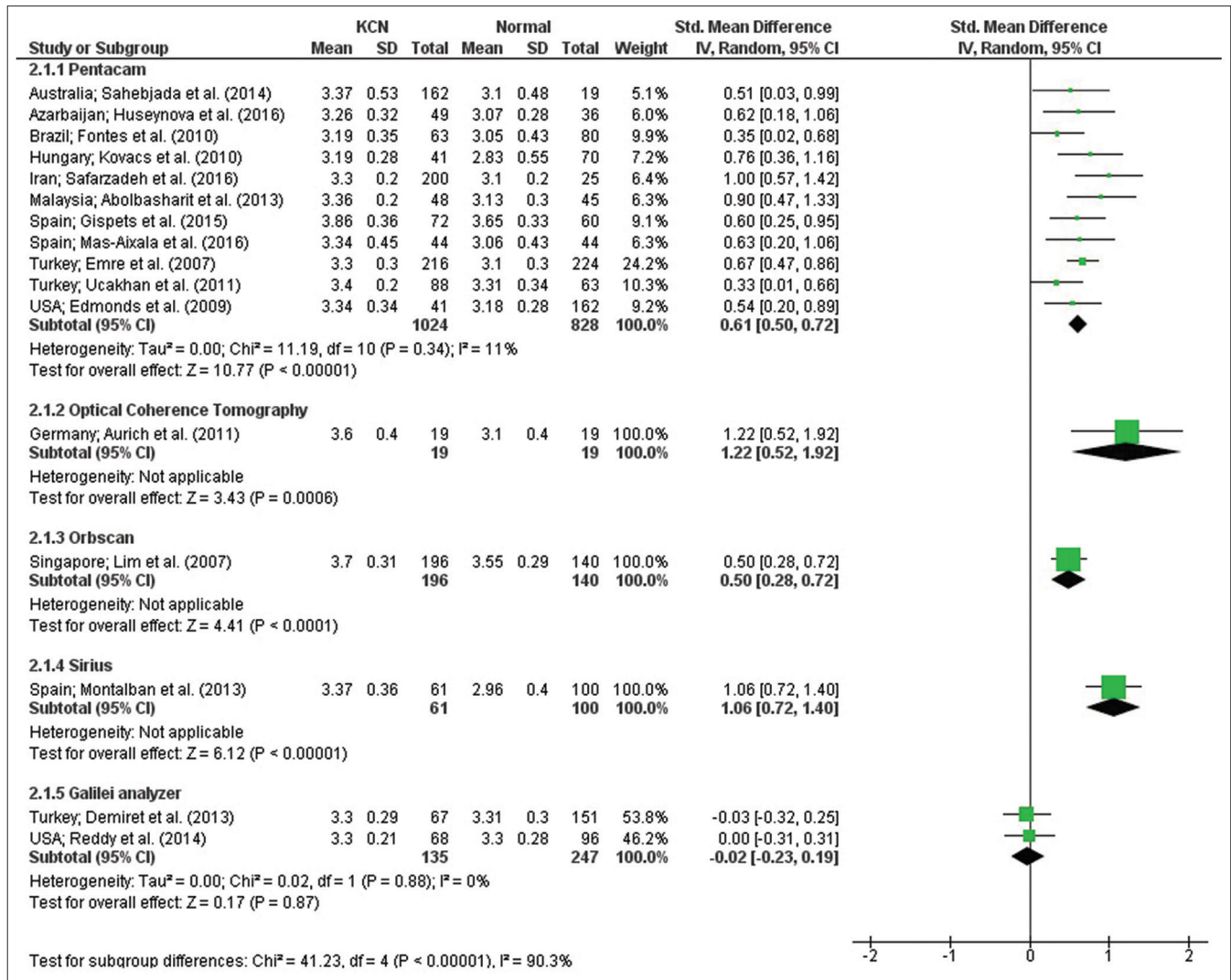


Figure 2: Forest plot for pooled standard mean differences (SMD) and 95% confidence interval (CI) based on applied device

Table 1: Extracted data

	Age (mean±SD)	Technique	Normal ACD	Keratoconic ACD	P
Abolbashari <i>et al.</i> <sup>3</sup>	N: 25.44±5.52 KCN: 24.27±6.17	Pentacam	3.13±0.30	Mild: 3.22±0.24 Moderate: 3.36±0.20 Severe: 3.65±0.40	0.0001
Kovács <i>et al.</i> <sup>4</sup>	N: 39.69±15.77 KCN: 35.25±10.67	Pentacam	2.83±0.55	3.19±0.28	<0.001
Reddy <i>et al.</i> <sup>5</sup>	N: 34±10 KCN: 31±11	Galilei analyzer	3.30±0.28	3.30±0.21	0.646
Edmonds <i>et al.</i> <sup>2</sup>	N: 41.90±12.40 KCN: 47.5±15	Pentacam	3.18±0.28	3.34±0.34	0.003
Gispets <i>et al.</i> <sup>6</sup>	N: 32.29±8.95 KCN: 37.46±13.75	Pentacam	3.65±0.33	Stage 1: 3.76±0.48 Stage 2: 3.68±0.42 Stage 3: 3.86±0.36 Stage 4: 4.09±0.34	–
Fontes <i>et al.</i> <sup>7</sup>	N: 35.23±12.60 KCN: 34.98±12.40	Pentacam	3.05±0.43	3.19±0.35	0.0416

Contd...

**Table 1: Contd...**

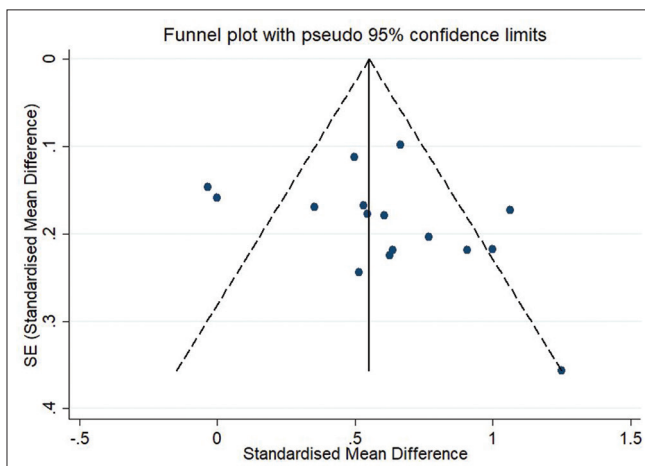
	Age (mean±SD)	Technique	Normal ACD	Keratoconic ACD	P
Emre <i>et al.</i> <sup>8</sup>	N: 28.50±8.80 KCN: 27.30±9.10	Pentacam	3.10±0.30	Mild: 3.20±0.30 Moderate: 3.30±0.30 Severe: 3.70±0.40	0.0001
Sahebjada <i>et al.</i> <sup>1</sup>	N: 40 KCN: 34.5	Pentacam	3.10±0.48	Mild: 3.39±0.55 Moderate: 3.31±0.48 Severe: 3.43±0.58	0.148 0.883
Demir <i>et al.</i> <sup>9</sup>	N: 26.30±8.30 KCN: 25.7±6.70	Galilei analyzer	3.31±0.30	3.30±0.29	0.149
Lim <i>et al.</i> <sup>10</sup>	N: 31.60±6.40 KCN: 29.60±9.20	Orbscan II	3.55±0.29	3.70±0.31	<0.01
Aurich <i>et al.</i> <sup>11</sup>	N: NA KCN: 32±7	Optical coherence tomography	3.1±0.40	3.60±0.40	<0.05
Mas-Aixala <i>et al.</i> <sup>12</sup>	N: 34.14±8.49 KCN: 35.29±13.21	Pentacam	3.06±0.43	3.34±0.45	0.004
Montalbán <i>et al.</i> <sup>13</sup>	N: 37 KCN: 35	Sirius	2.96±0.40	3.37±0.36	0.250
Huseynova <i>et al.</i> <sup>14</sup>	N: 23.19±4.52 KCN: 23.77±7.67	Pentacam	3.07±0.28	3.26±0.32	<0.0001
Uçakhan <i>et al.</i> <sup>15</sup>	N: 29.10±8.10 KCN: 26.10±5.90	Pentacam	3.31±0.34	3.47±0.27	0.019
Safarzadeh and Nasiri <sup>16</sup>	N: 28.7±7.00 KCN: 26±7.50	Scheimpflug-placido topography	3.1±0.20	Suspect: 3.20±0.30 Mild: 3.20±0.30 Moderate: 3.30±0.20 Severe: 3.60±0.30	0.840 0.340 <0.0001 0.006

SD: Standard deviation, ACD: Anterior chamber depth, KCN: Keratoconu, NA: Not available

**Table 2: Result of univariate meta-regression analysis to determine heterogeneity determinants of standardized mean difference**

Variable	Coefficient	95% CI	P
Device	0.213	0.122-0.303	<0.001
Sample size (eye)	-0.005	-0.002-0.001	0.534
Year publication	0.003	-0.057-0.065	0.893
Age mean (years)	-0.025	-0.078-0.027	0.325

Device variable coding - 1: Galilei analyzer, 2: Optical coherence tomography, 3: Orbscan, 4: Pentacam, 5: Sirius. CI: Confidence interval

**Figure 3:** Funnel plot for publication bias in result of different studies**Financial support and sponsorship**

Nil.

**Conflicts of interest**

There are no conflicts of interest.

**REFERENCES**

- Sahebjada S, Xie J, Chan E, Snibson G, Daniel M, Baird PN. Assessment of anterior segment parameters of keratoconus eyes in an Australian population. *Optom Vis Sci* 2014;91:803-9.
- Edmonds CR, Wung SF, Pemberton B, Surrent S. Comparison of anterior chamber depth of normal and keratoconus eyes using scheimpflug photography. *Eye Contact Lens* 2009;35:120-2.
- Abolbashari F, Mohidin N, Ahmadi Hosseini SM, Mohd Ali B, Retnasabapathy S. Anterior segment characteristics of keratoconus eyes in a sample of Asian population. *Cont Lens Anterior Eye* 2013;36:191-5.
- Kovács I, Miháltz K, Németh J, Nagy ZZ. Anterior chamber characteristics of keratoconus assessed by rotating scheimpflug imaging. *J Cataract Refract Surg* 2010;36:1101-6.
- Reddy JC, Rapuano CJ, Cater JR, Suri K, Nagra PK, Hammersmith KM. Comparative evaluation of dual scheimpflug imaging parameters in keratoconus, early keratoconus, and normal eyes. *J Cataract Refract Surg* 2014;40:582-92.
- Gispets J, Rodilla M, Cardona G. Corneal and anterior chamber

- parameters in keratoconus: Which are the best indicators of disease progression? *Contact Lens Anterior Eye* 2015;38:e24-5.
7. Fontes BM, Ambrósio R Jr., Jardim D, Velarde GC, Nosé W. Corneal biomechanical metrics and anterior segment parameters in mild keratoconus. *Ophthalmology* 2010;117:673-9.
  8. Emre S, Doganay S, Yologlu S. Evaluation of anterior segment parameters in keratoconic eyes measured with the pentacam system. *J Cataract Refract Surg* 2007;33:1708-12.
  9. Demir S, Sönmez B, Yeter V, Ortak H. Comparison of normal and keratoconic corneas by galilei dual-Scheimpflug Analyzer. *Cont Lens Anterior Eye* 2013;36:219-25.
  10. Lim L, Wei RH, Chan WK, Tan DT. Evaluation of keratoconus in Asians: Role of orbscan II and tomey TMS-2 corneal topography. *Am J Ophthalmol* 2007;143:390-400.
  11. Aurich H, Pham DT, Wirbelauer C. Biometric evaluation of keratoconic eyes with slit lamp-adapted optical coherence tomography. *Cornea* 2011;30:56-9.
  12. Mas-Aixala E, Gispets J, Lupón N, Cardona G. The variability of corneal and anterior segment parameters in keratoconus. *Cont Lens Anterior Eye* 2016;39:466-70.
  13. Montalbán R, Alio JL, Javaloy J, Piñero DP. Comparative analysis of the relationship between anterior and posterior corneal shape analyzed by scheimpflug photography in normal and keratoconus eyes. *Graefes Arch Clin Exp Ophthalmol* 2013;251:1547-55.
  14. Huseynova T, Abdulaliyeva F, Lanza M. Comparison of scheimpflug imaging parameters between steep and keratoconic corneas of Caucasian eyes. *Clin Ophthalmol* 2016;10:603-8.
  15. Uçakhan ÖÖ, Cetinkor V, Özkan M, Kanpolat A. Evaluation of scheimpflug imaging parameters in subclinical keratoconus, keratoconus, and normal eyes. *J Cataract Refract Surg* 2011;37:1116-24.
  16. Safarzadeh M, Nasiri N. Anterior segment characteristics in normal and keratoconus eyes evaluated with a combined scheimpflug/placido corneal imaging device. *J Curr Ophthalmol* 2016;28:106-11.