



## Case Report

# An Extremely Rare Case of Cementless Third Generation Corail Stem Neck Fracture With Fractographic Analysis

Andreja Baljovic, MD <sup>a, b, \*</sup>, Dragomir Glisic, PhD <sup>c</sup>, Nenad Radovic, PhD <sup>c</sup>,  
Zeljko Radovanović, PhD <sup>c</sup>, Zoran Bascarevic, MD, PhD <sup>a, b</sup>

<sup>a</sup> Institute of Orthopaedics Banjica, Belgrade, Serbia

<sup>b</sup> Faculty of Medicine, University of Belgrade, Belgrade, Serbia

<sup>c</sup> Faculty of Technology and Metallurgy, University of Belgrade, Belgrade, Serbia

## ARTICLE INFO

## Article history:

Received 17 March 2023

Received in revised form

20 June 2023

Accepted 21 June 2023

Available online xxx

## Keywords:

Hip revision

Corail stem

Neck fracture

## ABSTRACT

The cementless Corail stem is one of the most frequently implanted stems and has undergone several design changes. Currently in use is the third generation, named Corail AMT. Until now, only one third-generation Corail stem neck fracture has been described in 2020. In our paper, we present an almost identical complication with an additional analysis of the fracture using a scanning electron microscope. The revision surgery consisted of changing the broken implant with a Corail revision stem, along with replacing the polyethylene liner and the femoral head with new one, after which the patient achieved a full recovery. According to the available literature, this is the second case of this extremely rare complication.

© 2023 The Authors. Published by Elsevier Inc. on behalf of The American Association of Hip and Knee Surgeons. This is an open access article under the CC BY-NC-ND license (<http://creativecommons.org/licenses/by-nc-nd/4.0/>).

## Introduction

Implants in total hip arthroplasty have undergone numerous changes in the manufacturing process and the design itself, which has enabled longevity and predictable results. The cementless Corail stem (De Puy, Synthes, Warsaw, IN), which is also one of the most frequently implanted stems, has also undergone several changes [1]. The first generation, which was first introduced in 1986 and is characterized by thin and cylindrical neck, was replaced in 2002 by a new trapezoidal cylindrical neck design. It was soon shown that laser etching on the side of the neck caused weak areas, followed by frequent fractures in this region [2]. From December 2003 until today, the third generation named Corail AMT (Articul/EZE Mini Taper) has been in use. It is characterized by marks engraved on the distal portion of the Morse taper [3]. Registries show excellent survival of these implants of up to 98.5% during 10 years of follow-up [1,4].

As of now, only one third-generation Corail stem neck-level fracture has been described, which occurred in Florida, USA, in

2020 [5]. In our paper, we present an almost identical complication with an additional analysis of the fracture using a scanning electron microscope (SEM). According to the available literature, this is the second case of this kind in the world.

## Case history

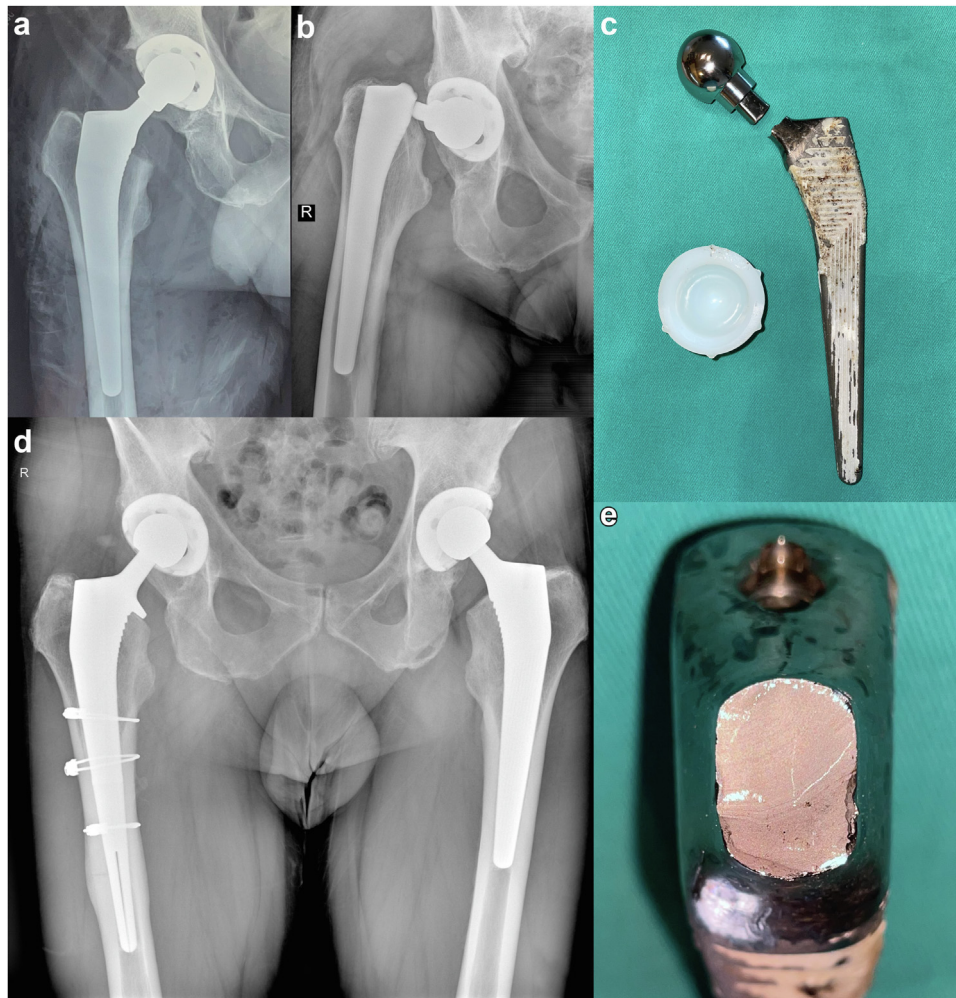
A 66-year-old patient came to our emergency room due to the sharp pain in his right hip that occurred suddenly when standing up from a chair. He underwent total arthroplasty of the right hip 6 years ago (Fig. 1a) and the left hip 4 years ago due to osteoarthritis, followed by full recovery. He is an office worker with no relevant and apparent traumatic events.

The physical examination revealed a completely healed surgical scar, moderate pain in the right groin, with shortening and external rotation of the right leg. Radiographs taken at that time showed a broken stem in neck region with transverse pattern (Fig. 1b).

The patient's past medical history was notable for hypertension and tachycardia with normal body mass index of 27.1 kg/m<sup>2</sup>. Laboratory blood tests (complete blood count, basic metabolic panel, C-reactive protein, and erythrocyte sedimentation rate) on admission were within the reference frame.

Revision surgery was performed using a posterolateral approach through the previous scar under general anesthesia. A minor intra-

\* Corresponding author. Department of Orthopaedic Surgery, Institute of Orthopaedics "Banjica", Mihaila Avramovica 28, Belgrade, Serbia. Tel.: +381 11 6660466.  
E-mail address: [andreja.baljovic@iohbb.edu.rs](mailto:andreja.baljovic@iohbb.edu.rs)



**Figure 1.** (a) Anteroposterior radiography showing preinjury right hip arthroplasty; (b) transverse neck fracture; (c) position of the fracture on the neck of the extracted hip prosthesis; (d) 8-month postoperative radiograph; (e) photograph of the fracture surface on the stem side.

articular hematoma was found, along with the mentioned fracture of the stem neck with consequent marginal damage to the polyethylene liner. The acetabular and femoral components were firmly fixed to the bone and adequately oriented. No signs of periprosthetic infection, metallosis, or wear of the polyethylene liner were found. The stem was removed through a transfemoral approach with an extended trochanteric osteotomy. The bony femoral flap was secured using 3 cerclage cables (Zimmer-Biomet, Warsaw, IN). A Corail revision stem size 18 (De Puy, Synthes, Warsaw, IN) was implanted. A new polyethylene liner Pinnacle (De Puy, Synthes, Warsaw, IN) size 56 mm with 10 degrees of inclination was placed. A new CoCr +9/32 mm femoral head (De Puy, Synthes, Warsaw, IN) was used (Fig. 1d).

Postoperatively, the patient was encouraged to walk with partial weight bearing from the first day using crutches. Full weight bearing was allowed after 2 months. Eight months after the operation, the patient returned to his everyday activities. The osteotomy site healed completely without any radiographic signs of stem loosening or migration.

The broken stem was subjected to SEM analysis in order to reveal the possible cause and the mechanism of the fracture of the implant.

Written informed consent was obtained that all data concerning this case would be submitted for publication.

## Discussion

Fractures of the femoral stem are very rare, and one of the latest review articles by Sukopp et al. states that they occur at a rate of 0.26%, which is in accordance with research from almost 30 years ago by Heck et al., who reported a 0.27% rate of femoral component fracture [6,7]. They can occur in all parts of the implant: neck, neck-shoulder junction, or body of the stem. Fracture of the neck of the femoral stem is extremely rare, especially in monoblock uncemented stems, and only a few papers have documented such failures [7].

The risk factors that lead to stem fractures can be divided into 3 groups: those of the patient, the surgical technique, and the implant itself [7]. The patient was neither obese nor actively involved in sports or hard physical work, so the risk factors on the part of the patient can be ruled out. Preinjury radiography shows adequately sized stem with no evidence of subsidence (Fig. 1a). Intraoperative assessment confirms adequate orientation with complete bony ongrowth, which rules out surgical technique factors. However, it should be noted that the femoral head had the largest available neck length (+13/32 mm), which increased the femoral offset and thus the force lever on the neck of the prosthesis. Thus far, the cracking of modular and thinner stems has been well documented [7]. Also, laser engraving in the neck area is shown to

be one of the main culprits of stress fractures. In this particular case, the stem was a monobloc design, size 18, with laser-engraved markings on the taper and not on the neck of the prosthesis. Therefore, our patient did not have any of the mentioned risk factors.

Publications so far are very scarce on the issue of neck fractures in monobloc stems.

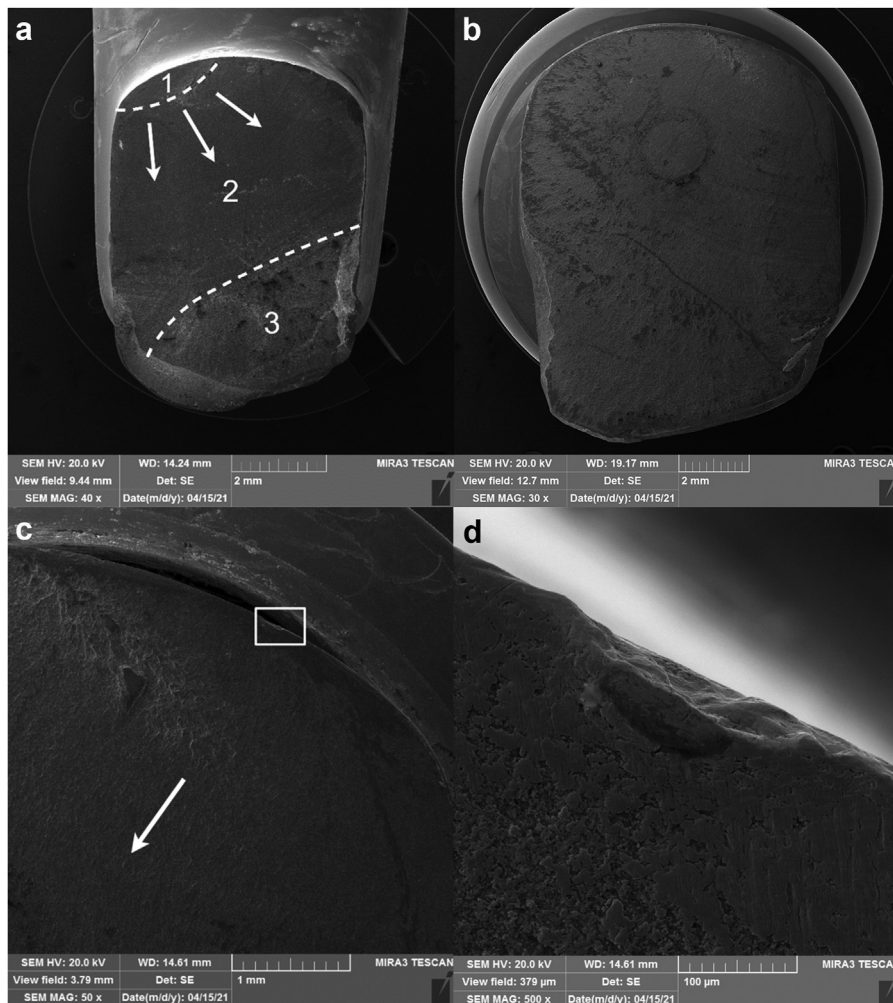
By reviewing the available literature, we found only one paper published in 2020 by Gibon and Deen that talks about the fracture of this same implant in an almost identical manner, under very similar circumstances, but without further fractographic analysis [5].

Figure 1c shows the failed hip prosthesis and the position of the fracture. A macroscopic overview of the fracture surface, shown in Figure 1e, reveals 2 distinct regions: the region covered with curved lines that occupy most of the fracture surface and the region with a granular appearance. In SEM images at low magnifications, shown in Figure 2a, 3 zones are distinguished. Curved lines that spread radially through the central zone of the fracture surface (marked as zone 2) are the traces of the fatigue crack propagation, known as beach marks. Beach marks are considered a clear indication of the fatigue fracture type. The curvature of the beach marks points back to the area of the fracture initiation placed at the edge of the

fracture area (Fig. 2a, marked as zone 1). The same features can be observed on the other, matching half of the fractured part (Fig. 2b). Traces at the fracture surface and the direction of the fatigue crack advance suggest that hip prosthesis has failed under the cyclic loading by unidirectional bending with fracture initiation on the anterolateral corner [8].

Takai et al. analyzed neck fractures in cementless stem using SEM and Finite Element Method. Their analysis conducted on the Ahfix Q stem (Kyocera, Japan) indicated that the place of greatest concentration of force is exactly at the anterolateral corner of the neck of the endoprosthesis, which corresponds to the place of initiation of the fracture in our case [7].

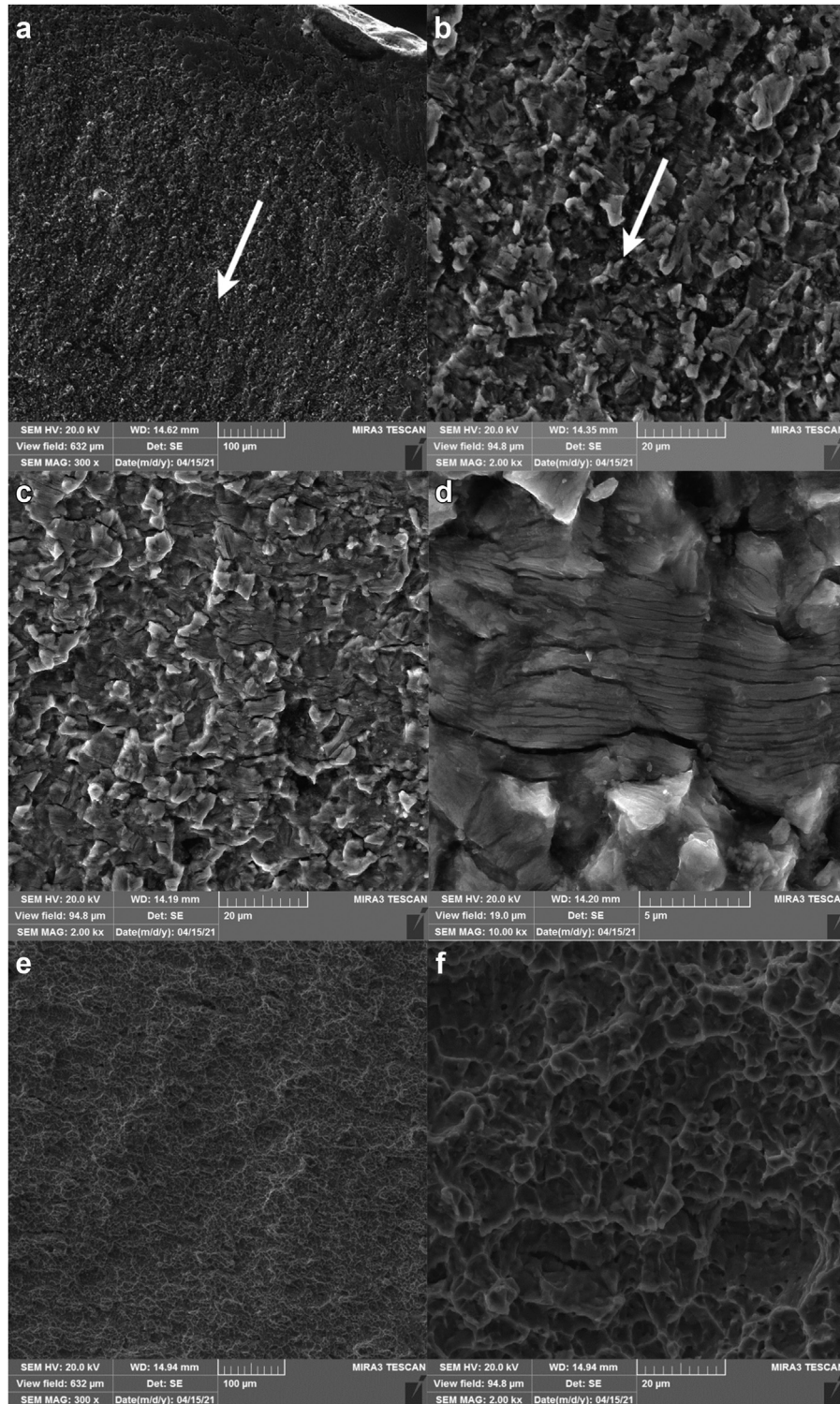
The ridge at the fracture surface up left in Figure 2a, also visible at matching surface up to the right in Figure 2b, is shown in Figure 2c under higher magnification and marked by a rectangle. This ridge is placed ahead of the fracture origin site, and it could be assumed that it was formed by the change in crack propagation plane in accordance with the acting tensile stress. The position of the fracture origin and the rotation of the fatigue crack propagation plane perpendicular to the direction of the acting tensile stress may suggest initial microcrack formation on the outer surface of the neck by the mechanism of dislocation slip (slip band formation), preferably in alpha grains [9]. However, many postfracture



**Figure 2.** (a) Macroscopic appearance of the fracture surface on the stem side with 3 distinct zones typical of the fatigue fracture; (b) matching fracture surface on the head side. Fracture surface near the origin of the fatigue fracture (head side); (c) damage at the edge of the fracture surface (rectangle) and crack propagation direction (arrow); (d) damage shown in micrograph enlarged.

damages formed at the contact between the 2 fracture surfaces prevent examination of the ridge in more detail. Similar flat areas with scratches on the surface can also be seen near the fracture origin, as shown in Figure 2d. Flattened areas were formed by the friction between the opposite fatigue fracture surfaces under the cyclic loading during the fatigue crack propagation.

Rubbing the opposite fracture surfaces during the fatigue crack propagation has damaged other possible traces in the vicinity of the fracture initiation site. Therefore, it is difficult to reveal the exact root cause of the initial microcrack formation, which propagated under the cyclic tensile-compressive loading into the macroscopic fatigue crack. A common cause of the failure cited in the literature is



**Figure 3.** Fracture surface in the vicinity of the crack origin on the neck side: (a) granular structure of the fracture surface; (b) very fine fatigue striations and secondary microcracks. Fracture surface near the crack origin on the stem side: (c) irregular fatigue striations and many secondary microcracks; (d) fatigue striations and secondary microcracks alongside intergranular secondary microcracks. The zone of the final fracture: (e) overview of the fracture surface; (f) ductile dimples in the zone of the final fracture.

the formation of the microcrack at the anterolateral surface, and the mechanisms usually involve stress corrosion cracking or fatigue corrosion, fretting and fretting corrosion, crevice corrosion, and hydrogen embrittlement, besides already mentioned mechanism of dislocation slip bands formation [10]. Nevertheless, considering the fatigue fracture origin position, it could be assumed that the initial microcrack formed at the surface of the neck and propagated as the fatigue crack under the influence of the stress concentration at the outer anterolateral curvature of the stem.

Figure 3 displays SEM micrographs of the fracture surface in the zone of fatigue crack propagation (zone 2) in early stages, near the fracture origin (up to the right in Fig. 3a). The arrow in the pictures in Figure 3a and b indicates the direction of the fatigue crack propagation front. The fracture surface in this zone is coarse, granular, and contains many irregular voids. Fatigue striations are barely visible at the magnification of the micrograph in Figure 3b. At even higher magnification in Figure 3c, striations become observable. Striations are the microscopic traces of the fatigue crack propagation through the mechanism of opening and closing of the crack, and therefore they serve as the confirmation of the failure by fatigue fracture. Besides fine fatigue striations, there are many deep secondary cracks perpendicular to the fatigue fracture surface (Fig. 3c). Secondary cracks may indicate the brittleness of the material [8]. Irregular and wavy striation lines in SEM micrograph in Figure 3d were formed by changing the plane of propagation upon encountering the obstacles in structure [8]. Grains between fatigue striations look smooth, but at higher magnifications, it can be observed that the striations in those parts are actually less pronounced and barely observable (Fig. 3d, lower part of the image).

The fracture surface in the third zone (zone 3 in Fig. 2a) is characteristic of the final rupture stage of the fatigue fracture. Ductile dimples at the fracture surface, visible in SEM images in Figure 3e, indicate the ductile type of the final fracture. Higher magnification reveals an equiaxed shape of ductile dimples (Fig. 3f), which indicate tensile stress acting perpendicularly to the fracture surface [8]. Therefore, the final fracture was due to the overload of the remaining cross-section area under the influence of tensile stress.

The manufacturer has been notified of this complication, but unfortunately, we do not have information on whether an analysis was carried out and what the results of their investigation were.

## Summary

The hip prosthesis failed by the fatigue fracture initiated in the region of the stress concentration by the curvature on the anterolateral side of the neck. However, the exact mechanism of the initial crack formation could not be determined. The authors trust that since all other causes have been ruled out, a potential explanation can be found after a detailed analysis of the alloy composition of the implant.

Considering the huge number of hip arthroplasties performed daily using this stem and the fact that this is only the second report

so far of such a complication, we can conclude that this is still an isolated case and not a new feature of this group of implants. After all the above, we believe that the described event should not affect the future use of these implants. On the other hand, the high frequency of implantation of these implants makes even the rarest complication a topic that will probably be more relevant. The analysis and presentation of such rare cases are very important for further monitoring and adequate understanding of the functioning of the implant in the biological environment.

## Conflicts of interest

The authors declare there are no conflicts of interest.

For full disclosure statements refer to <https://doi.org/10.1016/j.artd.2023.101176>.

## Informed patient consent

The author(s) confirm that written informed consent has been obtained from the involved patient(s) or if appropriate from the parent, guardian, power of attorney of the involved patient(s); and, they have given approval for this information to be published in this case report (series).

## References

- [1] Kärrholm J, Rogmark C, Naucler E, Nätman J, Vinblad J, Mohaddes M, et al. Swedish hip arthroplasty Register Annual report 2019. Gothenburg, Sweden: The Swedish Hip Arthroplasty Register; 2020.
- [2] Merini A, Viste A, Desmarchelier R, Fessy MH. Cementless Corail™ femoral stems with laser neck etching: long-term survival, rupture rate and risk factors in 295 stems. *Orthop Traumatol Surg Res* 2016;102:71–6. <https://doi.org/10.1016/j.otsr.2015.10.009>.
- [3] Louboutin L, Viste A, Desmarchelier R, Fessy MH. Long-term survivorship of the Corail™ standard stem. *Orthop Traumatol Surg Res* 2017;103:987–92. <https://doi.org/10.1016/j.otsr.2017.06.010>.
- [4] Gundersen T, Furnes O, Gjertsen JE, Fenstad AM, Visnes H, Hallan G, et al. Annual report 2021 Norwegian National Advisory Unit on arthroplasty and hip fractures. Norwegian Arthroplasty Register Norwegian Cruciate Ligament Register Norwegian Hip Fracture Register Norwegian Paediatric Hip Register. 2021. <https://doi.org/10.13140/RG.2.2.34266.26566>.
- [5] Gibon E, Deen JT. Fracture of the neck of a modern cementless, titanium femoral stem. *Arthroplast Today* 2020;6:176–9. <https://doi.org/10.1016/j.artd.2020.04.004>.
- [6] Sukopp M, Taylor D, Forst R, Seehaus F. Femoral stem fracture in hip revision arthroplasty: a systematic literature review of the real-world evidence. *Z Orthop Unfall* 2022;160:160–71. <https://doi.org/10.1055/a-1348-2873>.
- [7] Takai H, Nakayama D, Murayama M, Takahashi T. Analysis of a cementless femoral stem neck fracture using scanning electron microscopy and the finite element method. *Hindawi Limited Case Rep Orthop* 2019;2019:1–6. <https://doi.org/10.1155/2019/7204598>.
- [8] Hertzberg RW. *Deformation and fracture mechanics of Engineering materials*. 4th ed. Hoboken: John Wiley and Sons, Inc.; 1996.
- [9] Li WB, Umezawa O. A review of subsurface crack initiation models in high-cycle fatigue for titanium alloys. Trans Tech Publications, Ltd. *Key Eng Mater* 2017;741:76–81. <https://doi.org/10.4028/www.scientific.net/KEM.741.76>
- [10] Fokter SK, Rudolf R, Moličnik A. Titanium alloy femoral neck fracture—clinical and metallurgical analysis in 6 cases. *Informa UK Limited Acta Orthop* 2015; 1–6. <https://doi.org/10.3109/17453674.2015.1047289>.