

Available online at [www.sciencedirect.com](http://www.sciencedirect.com)

journal homepage: [www.elsevier.com/locate/radcr](http://www.elsevier.com/locate/radcr)

## Case Report

# Aseptic osteonecrosis of the maxilla after severe COVID-19 infection and its treatment<sup>☆</sup>

N. Slavkova, MD<sup>\*</sup>, M. Nedevska, MD, PhD

Department of diagnostic imaging, University Hospital “St. Ekaterina”, Medical University, Pencho Slaveikov 52A, 143, Sofia, Bulgaria

### ARTICLE INFO

#### Article history:

Received 16 April 2022

Revised 31 May 2022

Accepted 4 June 2022

#### Keywords:

COVID-19

Complications

Osteonecrosis

Maxilla

### ABSTRACT

The course of the new SARS-CoV-2 (COVID-19) is unpredictable and is still being investigated. Although the majority of complications are expected to affect the respiratory system, there have been reports in literature concerning the adverse effects of the infection on bone and joint tissue. Several complications have been observed in the maxillofacial area in people who suffered from the infection, including osteonecrosis and osteomyelitis of the jaw. These complications have been subject to various hypotheses. They may result either from the disease pathogenetic mechanism or from a response to the therapeutic modalities used to treat the underlying disease, and overuse of particular medications – glucocorticoids, antirheumatics, interleukin-6 inhibitors, and antibiotics. This article presents a case of osteonecrosis of the maxilla after severe COVID-19 infection.

© 2022 The Authors. Published by Elsevier Inc. on behalf of University of Washington.

This is an open access article under the CC BY-NC-ND license (<http://creativecommons.org/licenses/by-nc-nd/4.0/>)

## Introduction

A lot of questions regarding the consequences of a COVID-19 infection still remain unanswered. Even though the virus falls in the category of respiratory viruses, it can adversely affect multiple tissues and organs. The adverse effects on the pulmonary system include development of severe acute respiratory syndrome and pneumonia. The severe course of the infection can often lead to complications in other organs, including heart damage, renal failure, and gastrointestinal disorders [1]. SARS CoV-2 infection is known to affect the vascular system and coagulation properties of the blood, injuring vessel walls

and causing blood clots to form in both large and microscopic blood vessels [2,3]. Very little is known about the complications in the facial area including osteonecrosis of the maxilla, which can result from impaired microcirculation in this area [4,5].

The diagnosis of osteonecrosis of the jaw (ONJ) is primarily clinical. The most common reason why maxillofacial surgeons are using imaging modalities like CT or MRT is for jaw assessment prior to performing orofacial procedures. Imaging may play a role in determining the extent of the disease, diagnosing early stages of osteonecrosis, excluding other diseases of the jaws. CT and MR imaging appearance of ONJ are variable and nonspecific [6]. CT imaging appearance of bone

<sup>☆</sup> Competing Interests: The authors declare that they have no known competing financial interests or personal relationships that could have appeared to influence the work reported in this paper.

<sup>\*</sup> Corresponding author.

E-mail address: [niya.slavkova@gmail.com](mailto:niya.slavkova@gmail.com) (N. Slavkova).

<https://doi.org/10.1016/j.radcr.2022.06.009>

1930-0433/© 2022 The Authors. Published by Elsevier Inc. on behalf of University of Washington. This is an open access article under the CC BY-NC-ND license (<http://creativecommons.org/licenses/by-nc-nd/4.0/>)

alterations is variable – it can include predominantly lytic or sclerotic lesions, periosteal reaction, and pathologic fractures. Persistent alveolar sockets after recent tooth extraction are a common finding in patients with ONJ [7,8].

---

## Case report

A 70-year-old male patient with no known comorbidities was admitted to the maxillofacial surgery department with complaints of swelling and pulsating feeling on the right side of the face in the maxillo-zygomatic area, accompanied by a sensation that some of his facial bones are “moving and about to fall off”, especially when chewing and talking.

The patient suffered from a severe COVID-19 infection 2 months before coming to the clinic. His symptoms during the infection were fatigue, high temperature, coughing, and difficulty breathing. He was admitted to a hospital because he developed pneumonia with low oxygen saturation levels. He has been hospitalized for one month, stating he had a very hard time and barely survived the hospitalization. He had been on mechanical ventilation and treated with large amounts of corticosteroids and antibiotics.

Patient's first onset of facial-area symptoms started while he was still in the hospital. He developed a sensation of “peeling” in his mouth as well as high number of mouth ulcers. Before being discharged from the hospital he started feeling pulsations below the right eyeball and swelling of the right facial area.

A few days after the patient was discharged from the hospital, the swelling worsened, and he visited a dentist's office. The dentist believed the swelling was caused by teeth problems and performed several teeth extractions, followed by a course of antibiotics. During the last visit, the dentist diagnosed a pathologic communication connecting the maxillary sinus and the oral cavity of the patient and referred him to the maxillofacial surgery department.

Before admission to the surgical department, a contrast CT of the head (viscerocranium), neck, and upper mediastinum was performed. Multiplanar 3D reconstructions were made. CT showed pathological rearrangement of the structure of the right maxillary and zygomatic bone.

Impairments were found on the body of the maxilla with the wall of the maxillary sinus, the alveolar process, zygomatic process, and the palatine process. Only the frontal process was intact.

Bone alterations included ill-defined osteolytic areas, the bone had the typical moth-eaten appearance with a fine line of osteosclerosis on the periphery and a thin, linear periosteal reaction around the bone (Fig. 1). Pathological fractures were present. One irregular fracture line was seen on the alveolar process, above juga alveolaria and the palatine process, dividing almost completely the alveolar process from the other part of the bone like a bony fragment. Other pathologic fracture lines were seen in the zygomaticomaxillary suture area and in the area of the temporal and frontal process of the zygomatic bone which completely separated the bone from the viscerocranium. The masseter muscle and the insert point of temporalis muscle appeared bigger, swollen. Fat stranding was ob-

served in the area around the affected bone. The empty alveolar sockets of the recently extracted canine teeth, the premolars and first molar were seen, filled with gas bubbles and liquid. Gas and liquid were also present in the periodontal space.

Based on these findings the patient was diagnosed with aseptic necrosis of the maxilla. He was referred to the maxillofacial clinic where maxillary sequestrectomy was performed. The pathological specimen obtained from the necrotic bone sample showed acellular necrotic bone, osteolysis, and massive inflammatory infiltrate. There were signs of bone and soft tissue necrosis with underlying acute purulent inflammation. Areas with granulation tissue formation were present.

Microbiological testing isolated *Finnegoldia magna*, *Streptococcus anginosus*, and *Enterococcus faecalis*, and a course of antibiotics was prescribed in accordance with the antibiogram: Augmentin 1000 mg, 2 × 1 tablet.

The patient was discharged in improved condition with a recommendation of clinical follow-up care. After the surgery, he is still complaining of swelling below the right orbit. Currently, the patient is still receiving follow-up care and is considering maxillary reconstruction.

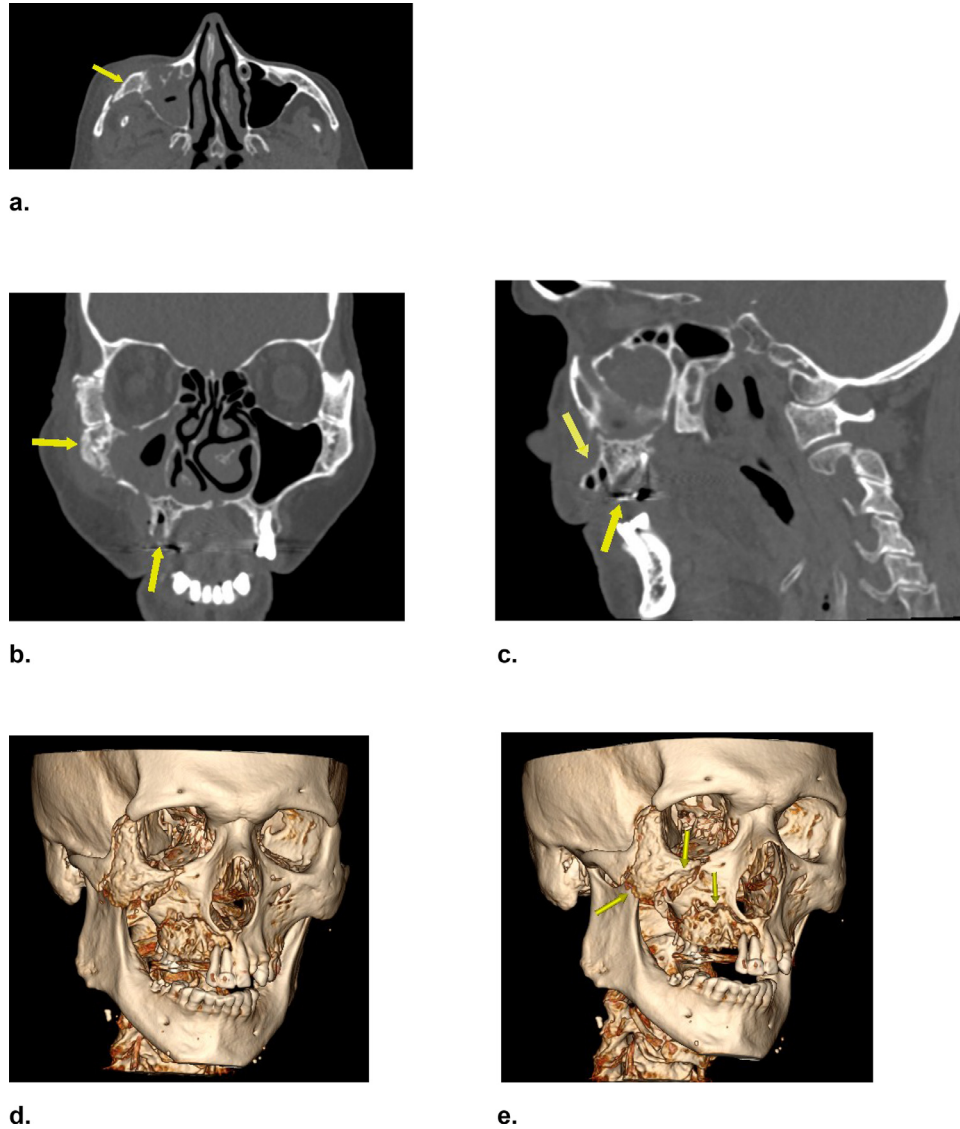
---

## Discussion

Osteonecrosis of the maxilla is a rare condition. In most of the cases, it can occur after a traumatic fracture or surgical osteotomy [9,10]. Other reasons may include infection, tumor, or radiation [11, 12]. Bisphosphonate osteonecrosis has been reported to be a complication in patients who underwent treatment for some types of bone cancer [13].

In general, osteonecrosis of the maxilla can occur in cases of vascular compromise. In the course of COVID-19 disease, microcirculation is disrupted – the occurring coagulopathies and microthrombi formation can cause local ischemia, which is likely to be the cause of osteonecrosis of the jaw [3]. One of the theories related to the origin of osteonecrosis is the systematic inflammation, the production of large amounts of cytokines – interleukin-1 (IL-1-b), gamma interferon (IFN-b), alpha tumor necrosis factor (TNF- $\alpha$ ), which can cause a hypercoagulability state, vasculitis, and thrombosis, whereas helper and killer T-cells induce B cell migration, increased degradation processes and bone necrosis [14]. Increased levels of inflammatory cytokines reduce the proliferation and differentiation of osteoblasts [15].

Development of osteonecrosis can be also induced by certain drugs. Medication-related osteonecrosis of the jaw (MROJ) is described in the literature as related to the administration of some drugs used in the treatment and rehabilitation of COVID-19 – some antirheumatic drugs; monoclonal antibodies (interleukin-6-inhibitors) and corticosteroids. Jawbones are more sensitive to drugs than other bones due to the higher vascularization and metabolism in the maxillofacial area (especially alveolar growth and periodontium) and the constant mechanical impact. The adverse effect of the administered drugs occurs due to angiogenesis inhibition, and weakened innate or acquired immunity, which is ac-



**Fig. 1 – CT with bony reconstruction of the facial skeleton (a–c) Axial, sagittal and coronal planes show complete reorganization of the bone structure with moth-eaten appearance, (c) shows the empty alveolar sockets of the extracted teeth (d, e) Multiplanar 3-D reconstructions showing the complete expansion of the process and the pathological fractures.**

accompanied by the existing effects of the infectious process [16].

The adverse effects of glucocorticoids on the skeletal bones are primarily due to their direct effect on osteoblasts and osteoclasts, increasing the apoptosis of osteoblasts while prolonging the lifespan of osteoclasts. Increased osteocyte apoptosis also occurs and is associated with vascular endothelial growth factor decrease, skeletal angiogenesis, bone interstitial fluid, and bone strength. In addition, high doses of corticosteroids increase Willebrand factor levels in plasma. Willebrand factor is produced and stored in endothelial cells, so an increase in its concentration results in endothelial cell damage. Vascular glucocorticoid injuries induce platelet adhesion and aggregation, leading to thrombosis and avascular necrosis [17].

There have been some reports about the relation of interleukin-6-inhibitors Tocilizumab and Denosumab to the

MROJ, but their exact mechanism of action is not yet well known [18].

It is noted that minor injuries in patients who were treated with that kind of medications (glucocorticoids or interleukin-6-inhibitors), particularly tooth extraction, may contribute to the development of osteonecrosis. Patients with periodontitis were at higher risk of developing osteonecrosis, too [19].

There is not a generally accepted gold standard of treatment of ONJ. In some cases, patients are treated with only a conservative approach including chlorhexidine mouthwash, long-term antibiotics treatment, periodic minor debridement of sequestrs, and wound irrigation to control pain, infection, and progress of exposed bone. However, conservative treatment has a low success rate. More aggressive methods, such as complete resection of the affected bone and primary wound closure show a higher success rate [20,21].

Nowadays, a new method using cell-based bone regeneration utilizing bone marrow mesenchymal stem cells (MSCs) has received increased attention. MSCs are known to promote wound healing and induce new bone formation in compromised tissue. A prospective study by Voss et al. [22] shows that surgical management in combination with MSCs transplantation seems to be a promising treatment modality in the therapy of MROJ.

## Conclusion

Serious complications have been observed in the facial area due to Covid-19 disease and/or its treatment, from minor changes in the oral cavity to osteonecrosis of the jaw. Even though imaging findings of osteonecrosis of the jaw are non-specific, it is important for the radiologist to be aware of this formation and to include osteonecrosis of the jaw in the differential diagnosis in patients with a history of COVID-19 infection and its treatment and current complaints in the facial area, and to point the attention of the referring physician at that direction, so as to avoid unwarranted biopsies with potentially hazardous outcomes.

## Patient consent statement

I declare that written informed consent for the case to be published (including images, case history, and data) was obtained from the patient for publication of this case report, including accompanying images.

## REFERENCES

- [1] Prezioso C, Marcocci ME, Palamara AT, De Chiara G, Pietropaolo V. The “Three Italy” of the COVID-19 epidemic and the possible involvement of SARS-CoV-2 in triggering complications other than pneumonia. *J. Neurovirol.* 2020;26:311–23. doi:10.1007/s13365-020-00862-z.
- [2] Christensen RH, Berg RMG. Vascular Inflammation as a therapeutic target in COVID-19 “Long Haulers”: HIITing the spot? *Front Cardiovasc Med* 2021;8:643626. doi:10.3389/fcvm.2021.643626.
- [3] Østergaard L. SARS CoV-2 related microvascular damage and symptoms during and after COVID-19: consequences of capillary transit-time changes, tissue hypoxia and inflammation. *Physiol Rep* 2021;9:e14726. doi:10.14814/phy2.14726.
- [4] Halboub E, Al-Maweri SA, Alanazi RH, Qaid NM, Abdulrab S. Orofacial manifestations of COVID-19: a brief review of the published literature. *Braz Oral Res* 2020;34:e124. doi:10.1590/1807-3107bor-2020.vol34.0124.
- [5] Boymuradov SA, Rustamova DA, Bobamuratova DT, Kurbanov YX, Karimberdiyev BI, Yusupov SSh, et al. Complications of COVID-19 in the maxillo-facial region: clinical case and review of the literature. *Adv Oral Maxillofac Surg* 2021;3:100091 ISSN 2667-1476. doi:10.1016/j.adoms.2021.100091.
- [6] Estilo CL, Van Poznak CH, Williams T, Bohle GC, Lwin PT, Zhou Q, et al. Osteonecrosis of the maxilla and mandible in patients with advanced cancer treated with bisphosphonate therapy. *Oncologist* 2008;13(8):911–20 Epub 2008 Aug 11. PMID: 18695259. doi:10.1634/theoncologist.2008-0091.
- [7] Bisdas S, Chambron Pinho N, Smolarz A, Sader R, Vogl TJ, Mack MG. Bisphosphonate-induced osteonecrosis of the jaws: CT and MRI spectrum of findings in 32 patients. *Clin Radiol* 2008;63(1):71–7 Epub 2007 Oct 22. PMID: 18068792. doi:10.1016/j.crad.2007.04.023.
- [8] Bianchi SD, Scoletta M, Cassione FB, Migliaretti G, Mozzati M. Computerized tomographic findings in bisphosphonate-associated osteonecrosis of the jaw in patients with cancer. *Oral Surg Oral Med Oral Pathol Oral Radiol Endod* 2007;104(2):249–58 Epub 2007 Jun 7. PMID: 17560140. doi:10.1016/j.tripleo.2007.01.040.
- [9] Cornah J, O’Hare PM. Total maxillary necrosis following severe facial injury. A case report. *Br J Oral Surg* 1981;19(2):148–50 PMID: 6942882. doi:10.1016/0007-117x(81)90042-1.
- [10] Kramer FJ, Baethge C, Swennen G, Teltzrow T, Schulze A, Berten J, et al. Intra- and perioperative complications of the LeFort I osteotomy: a prospective evaluation of 1000 patients. *J Craniofac Surg* 2004;15(6):971–7 discussion 978–9. PMID: 15547385. doi:10.1097/00001665-200411000-00016.
- [11] Auluck A. Maxillary necrosis by mucormycosis. a case report and literature review. *Med Oral Patol Oral Cir Bucal* 2007;12(5):E360 PMID: 17767099.
- [12] Reuther T, Schuster T, Mende U, Kübler A. Osteoradionecrosis of the jaws as a side effect of radiotherapy of head and neck tumour patients—a report of a thirty year retrospective review. *Int J Oral Maxillofac Surg* 2003;32(3):289–95 PMID: 12767877. doi:10.1054/ijom.2002.0332.
- [13] Estilo CL, Van Poznak CH, Williams T, Bohle GC, Lwin PT, Zhou Q, et al. Osteonecrosis of the maxilla and mandible in patients with advanced cancer treated with bisphosphonate therapy. *Oncologist* 2008;13(8):911–20 Epub 2008 Aug 11. PMID: 18695259. doi:10.1634/theoncologist.2008-0091.
- [14] Du F, Liu B, Zhang S. COVID-19: the role of excessive cytokine release and potential ACE2 down-regulation in promoting hypercoagulable state associated with severe illness. *J Thromb Thrombolysis* 2021;51(2):313–29 PMID: 32676883; PMID: PMC7365308. doi:10.1007/s11239-020-02224-2.
- [15] Lacey DC, Simmons PJ, Graves SE, Hamilton JA. Proinflammatory cytokines inhibit osteogenic differentiation from stem cells: implications for bone repair during inflammation. *Osteoarth Cartilage* 2009;17(6):735–42 Epub 2008 Nov 24. PMID: 19136283. doi:10.1016/j.joca.2008.11.011.
- [16] Zhang W, Gao L, Ren W, Li S, Zheng J, Li S, Jiang C, Yang S, Zhi K. The role of the immune response in the development of medication-related osteonecrosis of the jaw. *Front Immunol* 2021;12:606043 PMID: 33717086; PMID: PMC7947359. doi:10.3389/fimmu.2021.606043.
- [17] Weinstein RS. Glucocorticoid-induced osteonecrosis. *Endocrine* 2012;41(2):183–90 Epub 2011 Dec 15. PMID: 22169965; PMID: PMC3712793. doi:10.1007/s12020-011-9580-0.
- [18] Sakkas A, Heil S, Kargus S, Rebel M, Mischkowski RA, Thiele OC. Tocilizumab: another medication related to osteonecrosis of the jaws? A case report and literature review. *GMS Interdiscip Plast Reconstr Surg DGPW* 2021;10 Doc03. doi:10.3205/iprs000153.
- [19] Otto S, Aljohani S, Fliefel R, Ecke S, Ristow O, Burian E, et al. Infection as an important factor in medication-related osteonecrosis of the jaw (MRONJ). *Medicina (Kaunas)* 2021;57(5):463 PMID: 34065104; PMID: PMC8151678. doi:10.3390/medicina57050463.

- [20] Comas-Calonge A, Figueiredo R, Gay-Escoda C. Surgical treatment vs. conservative treatment in intravenous bisphosphonate-related osteonecrosis of the jaws. Systematic review. *J Clin Exp Dent* 2017;9(2):e302–7 PMID: 28210453; PMCID: PMC5303335.. doi:[10.4317/jced.53504](https://doi.org/10.4317/jced.53504).
- [21] Lobekk OK, Dijkstra W, Pedersen TØ. Surgical vs conservative treatment of medication-related osteonecrosis of the jaw: a complex systematic review and meta-analysis. *Oral Surg Oral Med Oral Pathol Oral Radiol* 2021;132(6):671–9 Epub 2021 Sep 20. PMID: 34657823. doi:[10.1016/j.oooo.2021.09.009](https://doi.org/10.1016/j.oooo.2021.09.009).
- [22] Voss PJ, Matsumoto A, Alvarado E, Schmelzeisen R, Duttenhöfer F, Poxleitner P. Treatment of stage II medication-related osteonecrosis of the jaw with necrosectomy and autologous bone marrow mesenchymal stem cells. *Odontology* 2017;105(4):484–93 Epub 2017 Feb 20. Erratum in: *Odontology*. 2019 Feb 5;: PMID: 28220264. doi:[10.1007/s10266-017-0295-4](https://doi.org/10.1007/s10266-017-0295-4).