

Regulation of Transforming Growth Factor β 1, Platelet-Derived Growth Factor, and Basic Fibroblast Growth Factor by Silicone Gel Sheeting in Early-Stage Scarring

Jaehoon Choi¹, Eun Hee Lee², Sang Woo Park³, Hak Chang⁴

¹Department of Plastic and Reconstructive Surgery, Keimyung University School of Medicine, Daegu; ²Department of Pathology, Samsung Changwon Hospital, Sungkyunkwan University School of Medicine, Changwon; ³Department of Plastic and Reconstructive Surgery, Samsung Changwon Hospital, Sungkyunkwan University School of Medicine, Changwon; ⁴Department of Plastic and Reconstructive Surgery, Institute of Ischemic and Hypoxic disease, Seoul National University College of Medicine, Seoul, Korea

Original Article

Background Hypertrophic scars and keloids are associated with abnormal levels of growth factors. Silicone gel sheets are effective in treating and preventing hypertrophic scars and keloids. There has been no report on the change in growth factors in the scar tissue following the use of silicone gel sheeting for scar prevention. A prospective controlled trial was performed to evaluate whether growth factors are altered by the application of a silicone gel sheet on a fresh surgical scar.

Methods Four of seven enrolled patients completed the study. Transforming growth factor (TGF)- β 1, platelet-derived growth factor (PDGF), and basic fibroblast growth factor (bFGF) were investigated immunohistochemically in biopsies taken from five scars at 4 months following surgery.

Results In both the epidermis and the dermis, the expression of TGF- β 1 ($P=0.042$ and $P=0.042$) and PDGF ($P=0.043$ and $P=0.042$) was significantly lower in the case of silicone gel sheet-treated scars than in the case of untreated scars. The expression of bFGF in the dermis was significantly higher in the case of silicone gel sheet-treated scars than in the case of untreated scars ($P=0.042$), but in the epidermis, the expression of bFGF showed no significant difference between the groups ($P=0.655$).

Conclusions The levels of TGF- β 1, PDGF, and bFGF are altered by the silicone gel sheet treatment, which might be one of the mechanisms of action in scar prevention.

Keywords Silicone gels / Cytokines / Cicatrix

Correspondence: Hak Chang
Department of Plastic and Reconstructive Surgery, Seoul National University Hospital, Seoul National University College of Medicine, 101 Daehang-ro, Jongno-gu, Seoul 110-744, Korea
Tel: +82-2-2072-3086
Fax: +82-2-747-5130
E-mail: hchang@snu.ac.kr

This study was supported by a research grant from Hans Biomed Corp. (Seoul, Republic of Korea), and Basic Science Research Program through the National Research Foundation of Korea (NRF) funded by the Ministry of Education, Science and Technology (R11-2005-065).

This article was presented at the 71th Annual Conference of the Korean Society of Plastic and Reconstructive Surgeons on November 1-3, 2013, in Seoul, Korea.

No potential conflict of interest relevant to this article was reported.

Received: 8 Apr 2014 • Revised: 18 Jun 2014 • Accepted: 26 Jun 2014

pISSN: 2234-6163 • eISSN: 2234-6171 • <http://dx.doi.org/10.5999/aps.2015.42.1.20> • Arch Plast Surg 2015;42:20-27

INTRODUCTION

Hypertrophic scars and keloids are the result of abnormal tissue repair, with the overproduction and reduced breakdown of the

extracellular matrix and are associated with abnormal levels of growth factors. The use of neutralizing antibodies for transforming growth factors (TGF)- β 1 and TGF- β 2, which stimulate fibroblasts to produce collagen, has been shown to inhibit scar

tissue formation [1].

Silicone gel sheets are used in the therapy of old, established hypertrophic scars and keloids, as well as to prevent or reduce scar formation. They have been reported to improve hypertrophic scars and keloids in 60% to 100% of cases [2,3] and to prevent their formation in 75% to 85% of cases [2,4,5].

There have been several papers reporting the change in growth factors after applying a silicone gel sheet on hypertrophic scars and keloids [6-9]. However, most of them were *in vitro* models, which are different from the real scar formation process. Human scar formation is a complicated process involving several cell types, extracellular matrices, and cytokines [6,7,9]. In addition, they have been proven to be affected not by a direct application of the silicone gel sheets but by the hydration effect, or occlusion, which is considered one of the mechanisms of action of silicone gel sheets [7,8].

We performed a prospective controlled clinical trial to evaluate whether growth factors involving the scar formation process are altered by an application of the silicone gel sheet when it is used for scar prevention. Ricketts et al. [10] evaluated the level of cytokine mRNA following an application of the silicone gel sheet. However, their study was different from ours in that they used the silicone gel sheeting as therapy on old, established hypertrophic scars. Further, there is a difference in the actual protein product rather than indirect evidence of increased growth factors obtained by assaying for messenger ribonucleic acid (mRNA) expression.

METHODS

Patients

Seven people undergoing debridement and scar revision surgery participated in this study between April 2007 and March 2008. Their scars were soft, supple, and clinically mature. The study was conducted after obtaining approval from the Institutional Review Board (D-0703-031-004). Exclusion criteria were patients having severe wound infection, a history of allergy to silicone gel sheeting, unhealed wounds, systemic diseases such as diabetic mellitus, blood abnormality, recent administration of oral steroids, pregnancy, and old age. Four of the seven enrolled patients completed the study. Of the remaining three, one patient was excluded after developing severe pruritus around a silicone gel sheet, another was lost to follow-up, and the other was noncompliant. Of the four patients who completed the study, one was a man and three were women; their mean age was 32.25 years (range, 21–52 years). One of the patients had two scars that were evaluated. The scars were located on the upper arm (four cases) and thigh (one case).

Each scar was divided into a proximal half and a distal half relative to the torso. Both halves were randomized into control and treatment groups. When the silicone gel sheet (Scarclenic, Hans Biomed Corp, Seoul, Korea) was given to the patient, a detailed explanation of which sheet to apply to which half of the scar was reinforced. The study information and instruction sheets were given to ensure understanding. The sheet included the doctors' telephone numbers in case the patients needed further assistance. Consent was obtained from the patients in the presence of a nurse, who acted as a witness. The application extended from the second week to the fourth month of the postoperative period. The instructions were to apply the silicone gel sheet continuously for at least 12 hours daily, to be removed and washed gently in warm, soapy water at least once daily and dried gently on paper before reapplication in order to prevent irritation and rashes. If any side effects such as maceration, rashes, pruritus, or infection developed, the patients were advised to discontinue the sheet application immediately and not resume the procedure until complete recovery. Silicone gel sheets must often be secured to the skin with tape or elastic garments, and they usually have to be replaced every 2 to 3 weeks. None of the patients received any treatment concurrent with the silicone gel sheet.

Immunohistochemistry

Four-millimeter punch biopsies were taken from the silicone gel sheet-treated and untreated scars 4 months postoperatively [10]. The punch biopsies were performed in the case of a linear scar. The punch biopsy sites were healed completely with secondary intention after 2 weeks. The tissue blocks were cut into 5- μ m sections, deparaffinized, rehydrated, rinsed in phosphate-buffered saline, and stained by the avidin-biotin-peroxidase complex method (labeled streptavidin-biotin-peroxidase; LSAB kit; Dako, Glostrup, Denmark). All the sections were incubated for 20 minutes in 0.3% (vol/vol) normal equine serum to block nonspecific antibody binding. The tissues were then incubated overnight at room temperature with a rabbit polyclonal antibody (Santa Cruz Biotechnology, Santa Cruz, CA, USA) for TGF- β 1 (1:200), platelet-derived growth factor (PDGF) (1:25), and basic fibroblast growth factor (bFGF) (1:50) diluted in phosphate-buffered saline or normal mouse control IgG. The color was developed by incubation with a 3,3'-diaminobenzidine solution for 5 minutes followed by counterstaining with Mayer's hematoxylin. The diaminobenzidine preparation was composed of 3 mg of diaminobenzidine per milliliter and Tris-HCl buffer containing 0.03% hydrogen peroxide. Appropriate external positive and negative controls were included in each case. All sections were mounted on Permount (Fisher Scientific, Fair Lawn, NJ, USA).

Microscopic evaluation

The sections were scored blindly in a random sequence three times by two investigators independently. A semi-quantitative estimate of the staining of these growth factors was made in each epidermal and dermal area by using a three-point scale: 0, none or single-stained cells; 1, intermediate number of stained cells; and 2, many stained cells. No attempt was made to quantify the staining intensity.

Statistical analysis

Data were analyzed using standard statistical software (SPSS ver. 12.0, SPSS Inc., Chicago, IL, USA). The Wilcoxon signed-rank test was used to compare the silicone gel sheet-treated and untreated variables. A P-value of less than 0.05 was considered statistically significant.

RESULTS

The untreated scars showed a diffuse and strong expression of TGF- β 1 in both the epidermis and the dermis (Fig. 1A, B). TGF- β 1 was mainly expressed in the basal and granular layers of the epidermis, and in the dermal fibroblasts and inflammatory cells. Silicone gel sheet-treated scars showed a weak and scattered expression of TGF- β 1 confined to the basal layer of the epidermis, and very little expression in the dermis (Fig. 1C, D). The expression of TGF- β 1 in both the epidermis and the dermis was significantly lower in the case of the silicone gel sheet-treated scars than in the case of the untreated scars ($P=0.042$ and $P=0.042$) (Fig. 2). The untreated scars showed a diffuse expression of PDGF throughout all the epidermal layers and a scattered expression in the dermis (Fig. 3A, B). The silicone gel

Fig. 1. Epidermal and dermal expression of TGF- β 1

(A) TGF- β 1 was expressed mainly in the basal and granular layers of the epidermis of the untreated scars. (B) TGF- β 1 was strongly expressed in the dermal fibroblasts and inflammatory cells of the untreated scars. (C) TGF- β 1 was weakly and sporadically expressed only in the basal layer of the epidermis of the silicone gel sheet-treated scars. (D) TGF- β 1 was weakly expressed in the dermis of the silicone gel sheet-treated scars (immunohistochemical staining $\times 400$ for A and C, and $\times 200$ for B and D). TGF- β 1, transforming growth factor β 1.

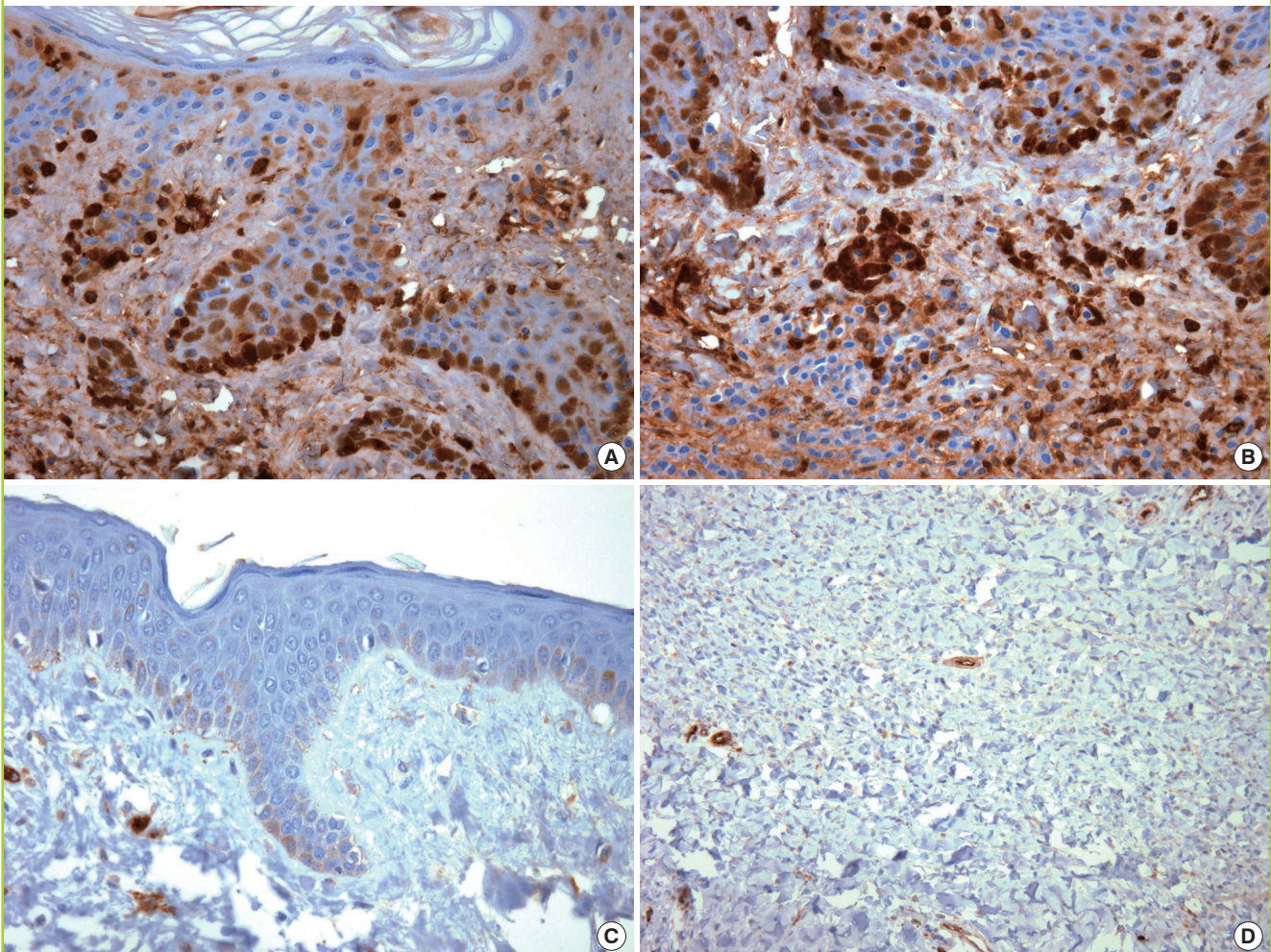


Fig. 2. Semi-quantitative estimate of the staining of growth factors

Expression of TGF- β 1, PDGF, and bFGF between silicone gel sheet-treated scars and untreated scars (^aP < 0.05). TGF- β 1, transforming growth factor β 1; PDGF, platelet-derived growth factor; bFGF, basic fibroblast growth factor.

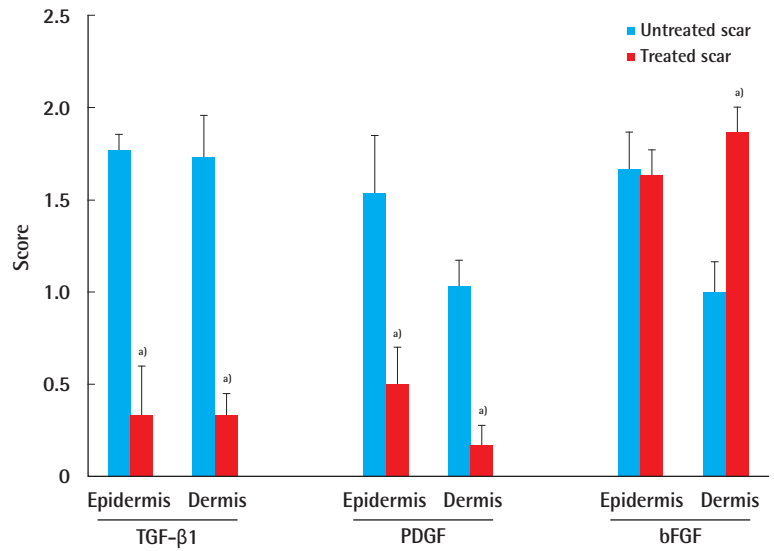


Fig. 3. Epidermal and dermal expression of PDGF

(A) PDGF was diffusely expressed throughout all the epidermal layers of the untreated scars. (B) PDGF was sporadically expressed in the dermis of the untreated scars. (C) PDGF was weakly expressed in the epidermis of the silicone gel sheet-treated scars. (D) PDGF was weakly expressed in the dermis of the silicone gel sheet-treated scars (immunohistochemical staining x400 for A, B, C, and D). PDGF, platelet-derived growth factor.

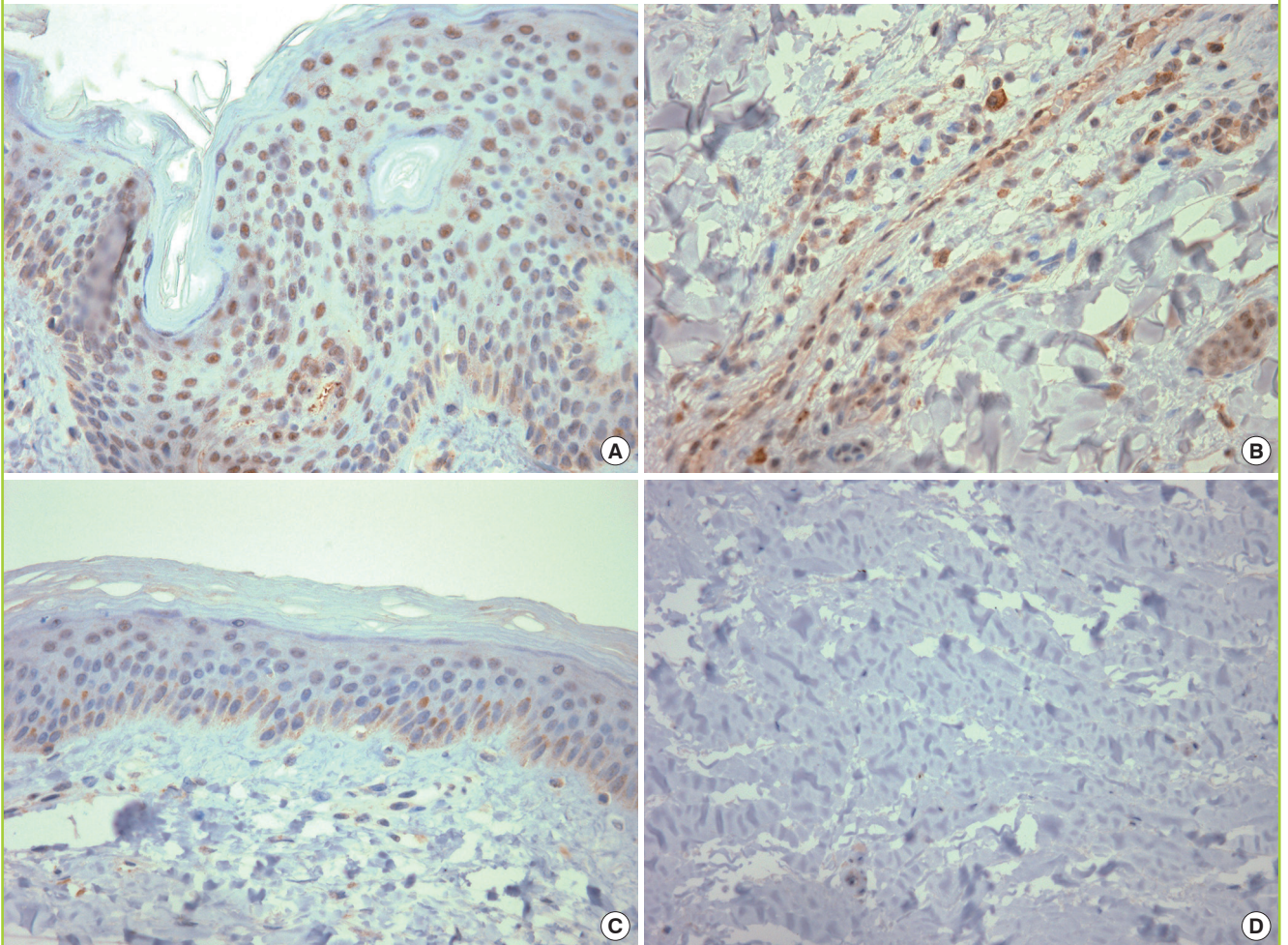
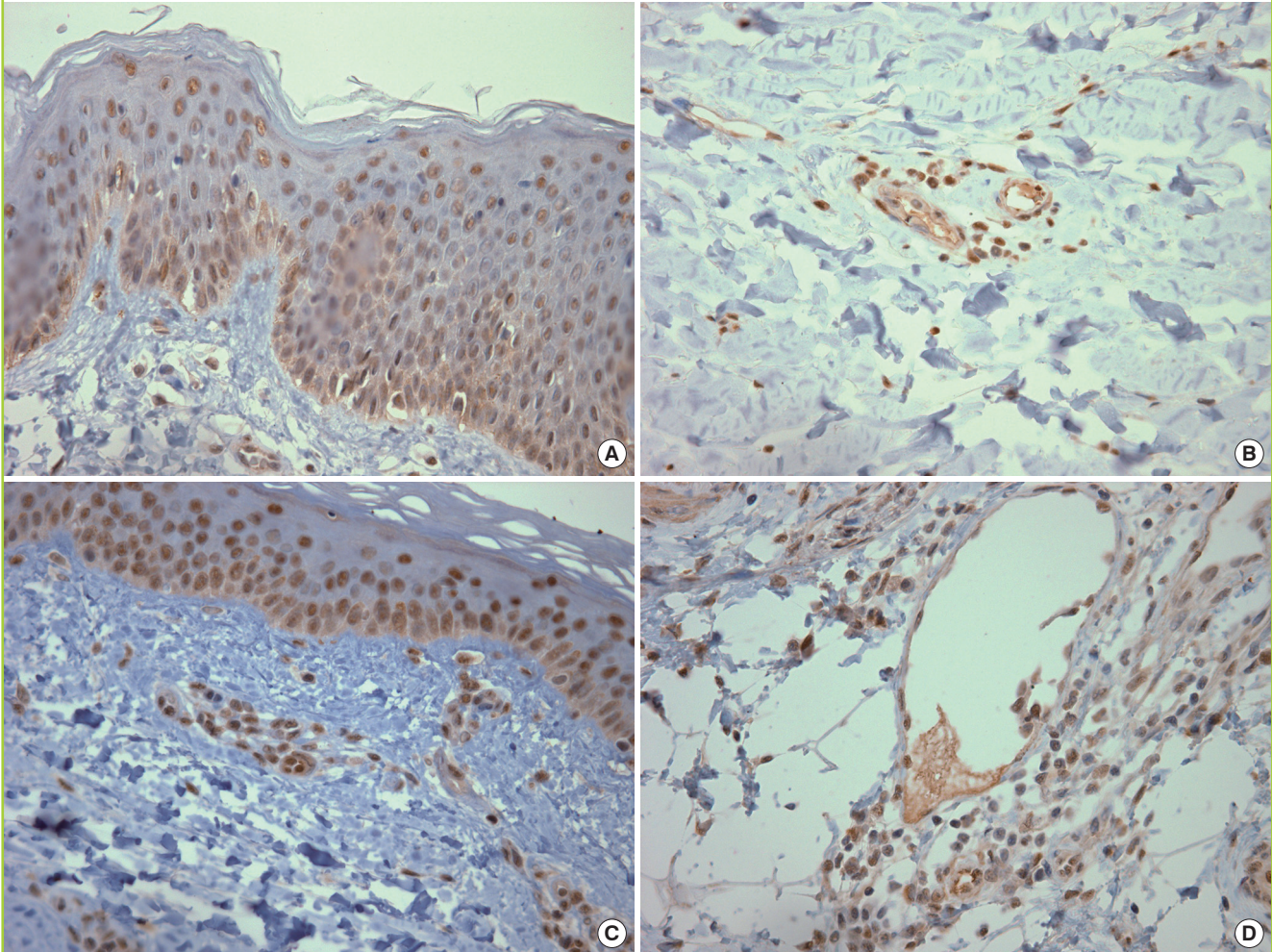


Fig. 4. Epidermal and dermal expression of bFGF

(A) bFGF was diffusely and strongly expressed throughout all the epidermal layers of the untreated scars. (B) bFGF was expressed only around the blood vessels in the dermis of the silicone gel sheet-treated scars. (C) bFGF was diffusely and strongly expressed throughout all the epidermal layers of the silicone gel sheet-treated scars. (D) PDGF was strongly and diffusely expressed in the dermal fibroblasts, endothelial cells, and inflammatory cells of the silicone gel sheet-treated scars (immunohistochemical staining x400 for A, B, C, and D). bFGF, basic fibroblast growth factor; PDGF, platelet-derived growth factor.



sheet-treated scars showed hardly any expression of PDGF in the epidermis and the dermis (Fig. 3C, D). The expression of PDGF was significantly lower in the epidermis and the dermis in the case of the silicone gel sheet-treated scars than in the case of the untreated scars ($P = 0.043$ and 0.042) (Fig. 2). Further, bFGF showed a high expression throughout all the epidermal layers in both groups (Fig. 4A, C). Between groups, bFGF showed no significant difference ($P = 0.655$) (Fig. 2). However, in the dermis, the untreated scars showed a localized expression of bFGF only around the blood vessels (Fig. 4B), and the silicone gel sheet-treated scars showed a diffuse and strong expression of bFGF in the fibroblasts, endothelial cells, and inflammatory cells (Fig. 4D). The dermal expression of bFGF was significantly higher in the case of the silicone gel sheet-treated scars than in the case of the untreated scars ($P = 0.042$) (Fig. 2).

DISCUSSION

There have been several papers reporting a change in growth factors after applying a silicone gel sheet on hypertrophic scars and keloids. Tandara et al. [7] noted that in an *in vitro* keratinocyte and fibroblast culture model, the hydration of keratinocytes modified their activity in cytokine secretion and fibroblasts reduced their rate of collagen synthesis when co-cultured with keratinocytes, depending on the hydration state of the keratinocytes. Hanaso et al. [6] evaluated the level of bFGF in an *in vitro*, serum-free fibroblast culture when it was exposed to silicone gel. An increase in the bFGF level associated with the silicone treatment of fibroblasts was also observed. They postulated that silicone gel treats and prevents hypertrophic scar tissue by modulating the expression of growth factors such as bFGF. However,

Tandara et al. [7] proved their results not by a direct application of the silicone gel sheets, but by the hydration effect, which is considered one of the mechanisms of action of silicone gel sheets. Hanaso et al. [6] used a silicone gel, but their study was limited to the use of an *in vitro* cell model because human scar formation is a complicated process involving several cell types, extracellular matrices, and cytokines [6,7,9]. Kuhn et al. [9] used a fibroblast-populated collagen lattice with burn hypertrophic scar fibroblasts as an *in vitro* hypertrophic scar model, which made it possible to apply silicone gel sheets directly onto the cells. Fibroblast activity and the level of TGF- β 2 were evaluated on the basis of the collagen lattice contraction and the supernatant from the collagen lattice. As a result, silicone gel sheeting downregulated fibroblast activity and decreased the level of TGF- β 2. They attempted to mimic the *in vivo* environment, not simply the *in vitro* cell culture model. However, the evaluation of fibroblast activity by using the collagen lattice contraction is limited, and they only evaluated the level of TGF- β 2 among the several cytokines involved in the scar formation process. By using the rabbit hypertrophic scar model, Gallant-Behm and Mustoe [8] observed that a Tegaderm dressing increased epidermal hydration and decreased keratinocyte activation, which significantly decreased the epidermal expression of the profibrotic cytokine interleukin-1b and increased the epidermal expression of antifibrotic cytokine TNF- α . These alterations in the epidermal gene expression resulted in concomitant changes in the expression of the TGF- β family members by the cells in the dermis, resulting in a decrease in profibrotic signaling within the dermis. An *in vivo* animal model was used in this study, but the occlusion effect by the Tegaderm dressing, not the silicone gel sheet, was proven.

We performed this prospective controlled clinical trial to evaluate whether growth factors involving scar formation are altered by the application of a silicone gel sheet when this sheet is used for scar prevention. Using a pilot, paired-comparison, nonrandomized clinical study, Ricketts et al. [10] evaluated the level of cytokine mRNA following the application of a silicone gel sheet, but it differed from our study in that they used the sheet for a therapeutic effect on old, established hypertrophic scars. Most patients in their study achieved clinical improvement with a reduction in firmness, pruritus, pain, and tenderness, but based on the cytokine mRNA levels, a comparison of a hypertrophic scar treated with silicone gel sheets with an untreated scar revealed that none of the changes approached significance. However, they postulated that more changes in the cytokine level would be observed when the silicone gel sheet was used for scar prevention on a fresh surgical scar because in the early phases of scar development, the growth factors are not only re-

leased from the extracellular matrix in an active form but are also secreted in larger amounts by the keratinocytes and fibroblasts [10]. Further, there is a difference in the actual protein product rather than indirect evidence of the increased growth factors obtained by assaying for mRNA expression.

In our study, TGF- β 1, PDGF, and bFGF were investigated immunohistochemically in biopsies taken from scars 4 months following surgery. TGF- β is one of the most well-studied growth factors, and it seems to be the most important factor responsible for excessive scar tissue formation. TGF- β stimulates collagen, elastin, and fibronectin synthesis while inhibiting extracellular matrix degradation [11,12]. TGF- β 1 is considered the most fibrogenic isoform of TGF- β . In our study, the expression of TGF- β 1 in both the epidermis and the dermis was significantly lower in the case of the silicone gel sheet-treated scars than in the case of the untreated scars at 4 months postsurgery. Similarly, triamcinolone acetonide, which has commonly been used for treating keloids, decreased the TGF- β 1 production in an *in vitro*, serum-free dermal fibroblast model [13]. Therefore, the silicone gel sheet might mediate its clinical effects on hypertrophic scars or keloids by reducing the production of TGF- β 1. In the study of Niessen et al. [14], TGF- β 1 showed no differences in dermal staining between hypertrophic and normal scars, at either 3 months or 12 months postsurgery. They hypothesized that TGF- β 1 plays a relatively important role during the earlier phases of the development of a fibrotic reaction in the case of hypertrophic scars and keloids [14]. The hypertrophic scar- and keloid-derived fibroblasts were more sensitive for TGF- β , and they responded to a lower concentration of the factor, than normal fibroblasts [15-17]. Therefore, even if the level of TGF- β 1 was not related to the clinical scar states, after a reasonable period of time, the silicone gel sheet would prolong the decrease in the level of TGF- β 1 from the onset of scar maturation; this would prevent the abnormal fibroblasts from responding to TGF- β 1.

Another important growth factor associated with tissue fibrosis is PDGF. Keloid fibroblasts showed an increased response to PDGF compared with normal fibroblasts [18]. An increased presence of PDGF was found in the case of hypertrophic scars compared with normal scars at both 3 months and 12 months postsurgery, and strong expressions in both the epidermis and the dermis were observed [14]. In our study, the expression of PDGF in both the epidermis and the dermis was significantly lower in the case of silicone gel sheet-treated scars than in the case of untreated scars at 4 months postsurgery.

Tan et al. [19] observed that in a keloid fibroblast culture model, bFGF caused a dose-dependent inhibition of hydroxyproline biosynthesis, an index of collagen production. The ac-

tions of bFGF opposed the fibrotic signal of TGF- β 1 by inhibiting collagen synthesis and stimulating collagen degradation [19]. However, in the study of Haisa et al. [20], keloid fibroblasts did not show a different response after bFGF stimulation. In our study, the expression of bFGF in the dermis was significantly higher in the case of silicone gel sheet-treated scars than in the case of untreated scars. Hanaso et al. [6] noted an increase in the bFGF level associated with the silicone treatment of normal fibroblasts, which are found in normal and hypertrophic scar tissue. Further, in the *in vitro* serum-free dermal fibroblast model, triamcinolone acetonide increased the production of bFGF by the fibroblasts [13]. However, in the epidermis, the expression of bFGF showed no significant differences between the silicone gel sheet-treated scars and the untreated scars. Hakvoort et al. [21] noted that the expression of bFGF in the burn scars at 1 month and 4 months postburn was clearly increased in the epidermis, compared with the unburned control skin of the same patients, but only sporadic dermal cells of the burn scars showed bFGF expression. Therefore, it was speculated that the silicone gel sheet caused no significant change in the bFGF level in the epidermis because bFGF was continually up-regulated in the epidermis of the scar tissue irrespective of the process of scar maturation. In our results, bFGF was highly expressed in the epidermis of both the silicone gel sheet-treated scars and the untreated scars.

On the other hand, the limitations of this study are as follows: 1) a small number (four) of patients and 2) non-correlation between clinical and histopathological data. A study of 4 patients is hardly sufficient to draw any conclusions. Therefore, a statistically relevant and justified number of patients is needed. Only having histopathological examinations does not make the research complete because a correlation of the clinical appearance is important to better understand how the histopathology connects to the clinical context.

In summary, in both the epidermis and the dermis, the expression of TGF- β 1 and PDGF was significantly lower in the case of silicone gel sheet-treated scars than in the case of untreated scars. The expression of bFGF in the dermis was significantly higher in the case of silicone gel sheet-treated scars than in the case of untreated scars, but in the epidermis, the expression of bFGF showed no significant differences between the groups. Thus, the levels of TGF- β 1, PDGF, and bFGF are altered by a silicone gel sheet treatment, which might be one of the mechanisms of action in scar prevention.

REFERENCES

- Shah M, Foreman DM, Ferguson MW. Neutralisation of TGF-beta 1 and TGF-beta 2 or exogenous addition of TGF-beta 3 to cutaneous rat wounds reduces scarring. *J Cell Sci* 1995;108(Pt 3):985-1002.
- Ahn ST, Monafo WW, Mustoe TA. Topical silicone gel for the prevention and treatment of hypertrophic scar. *Arch Surg* 1991;126:499-504.
- Carney SA, Cason CG, Gowar JP, et al. Cica-Care gel sheeting in the management of hypertrophic scarring. *Burns* 1994; 20:163-7.
- Fulton JE Jr. Silicone gel sheeting for the prevention and management of evolving hypertrophic and keloid scars. *Dermatol Surg* 1995;21:947-51.
- Cruz-Korchin NI. Effectiveness of silicone sheets in the prevention of hypertrophic breast scars. *Ann Plast Surg* 1996; 37:345-8.
- Hanasono MM, Lum J, Carroll LA, et al. The effect of silicone gel on basic fibroblast growth factor levels in fibroblast cell culture. *Arch Facial Plast Surg* 2004;6:88-93.
- Tandara AA, Kloeters O, Mogford JE, et al. Hydrated keratinocytes reduce collagen synthesis by fibroblasts via paracrine mechanisms. *Wound Repair Regen* 2007;15:497-504.
- Gallant-Behm CL, Mustoe TA. Occlusion regulates epidermal cytokine production and inhibits scar formation. *Wound Repair Regen* 2010;18:235-44.
- Kuhn MA, Moffit MR, Smith PD, et al. Silicone sheeting decreases fibroblast activity and downregulates TGFbeta2 in hypertrophic scar model. *Int J Surg Investig* 2001;2:467-74.
- Ricketts CH, Martin L, Faria DT, et al. Cytokine mRNA changes during the treatment of hypertrophic scars with silicone and nonsilicone gel dressings. *Dermatol Surg* 1996;22: 955-9.
- Babu M, Diegelmann R, Oliver N. Keloid fibroblasts exhibit an altered response to TGF-beta. *J Invest Dermatol* 1992; 99:650-5.
- Moulin V. Growth factors in skin wound healing. *Eur J Cell Biol* 1995;68:1-7.
- Carroll LA, Hanasono MM, Mikulec AA, et al. Triamcinolone stimulates bFGF production and inhibits TGF-beta1 production by human dermal fibroblasts. *Dermatol Surg* 2002;28:704-9.
- Niessen FB, Andriessen MP, Schalkwijk J, et al. Keratinocyte-derived growth factors play a role in the formation of hypertrophic scars. *J Pathol* 2001;194:207-16.
- Tredget EE. The molecular biology of fibroproliferative disorders of the skin: potential cytokine therapeutics. *Ann Plast Surg* 1994;33:152-4.
- Garner WL, Karmiol S, Rodriguez JL, et al. Phenotypic dif-

- ferences in cytokine responsiveness of hypertrophic scar versus normal dermal fibroblasts. *J Invest Dermatol* 1993; 101:875-9.
17. Dustan HP. Does keloid pathogenesis hold the key to understanding black/white differences in hypertension severity? *Hypertension* 1995;26:858-62.
 18. Leof EB, Proper JA, Goustin AS, et al. Induction of c-sis mRNA and activity similar to platelet-derived growth factor by transforming growth factor beta: a proposed model for indirect mitogenesis involving autocrine activity. *Proc Natl Acad Sci U S A* 1986;83:2453-7.
 19. Tan EM, Rouda S, Greenbaum SS, et al. Acidic and basic fibroblast growth factors down-regulate collagen gene expression in keloid fibroblasts. *Am J Pathol* 1993;142:463-70.
 20. Haisa M, Okochi H, Grotendorst GR. Elevated levels of PDGF alpha receptors in keloid fibroblasts contribute to an enhanced response to PDGF. *J Invest Dermatol* 1994;103: 560-3.
 21. Hakvoort T, Altun V, van Zuijlen PP, et al. Transforming growth factor-beta(1), -beta(2), -beta(3), basic fibroblast growth factor and vascular endothelial growth factor expression in keratinocytes of burn scars. *Eur Cytokine Netw* 2000; 11:233-39.