

INTEGRITY OF THE SUBSCAPULARIS TENDON AFTER OPEN SURGERY FOR THE TREATMENT OF ANTERIOR SHOULDER INSTABILITY: A CLINICAL AND RADIOLOGICAL EVALUATION

Osvandré Lech¹, Paulo Piluski², Renato Tambani³, Nero Castro⁴, Gilnei Pimentel⁵

ABSTRACT

Objective: To evaluate the integrity of the subscapularis tendon by strength, function and magnetic resonance imaging after deltopectoralis access for anterior shoulder instability. **Methods:** 20 patients with anterior shoulder instability have been evaluated. Minimum follow-up was 12 months, with a mean of 40 months. Only male patients were included, with a mean of age of 29 years (20 - 42 years). The patients have been submitted to physical examinations of mobility, muscular strength, Belly Test and Gerber Test. The isokinetic strength in internal and external rotation, in angular speeds of 60⁰/s and 180⁰/s, for both shoulders was measured using a dynamometer. In 15 patients magnetic resonance imaging (MRI) was carried out on both shoulders for evaluating the thickness, cross-sectional area and atrophy of the subscapularis muscle.

Results: A significant difference was found between torque peaks at the speed of 60⁰/s for internal ($p=0.036$) and external ($p=0.008$) rotation. However, at 180⁰/s the opposite happens (internal rotation: $p=0.133$; external rotation: $p=0.393$). Subscapularis muscle thickness and area are significantly smaller than the normal side, with a deficit of 19% and 23%, respectively. According to Rowe and UCLA scores, we find excellent and good results for the majority of patients, with a mean of 88 and 31.6 points, respectively. **Conclusion:** Despite of the good functional results, open surgery can limit strength and reduce the thickness and the cross-sectional area of subscapularis muscle. However, the best results were found in the patients who had the dominant side operated.

Keywords – Anterior shoulder instability; Subscapularis; Magnetic resonance imaging

INTRODUCTION

Glenohumeral joint dislocations are more common than those that occur in any other joint and the deformity and impairment of function that arise from a dislocated shoulder are widely known. The first evidence of the occurrence of dislocation are found in the paintings of the tombs of Ancient Egypt. Undoubtedly, prehistoric cavemen also recognized these lesions⁽¹⁾.

The dislocations can be classified into the traumatic, atraumatic, and recurrent. The traumatic type

is caused by violent force on the glenohumeral joint, which usually leads to injury of the labrum, the glenohumeral ligaments and capsule – called a Bankart lesion^(2,3). The occurrence of traumatic dislocations of the glenohumeral joint is relatively common, especially anterior dislocation, which affects 1.5 to 2% of the population in general and about 7% of athletes who use the upper limb. The incidence is more frequent in young individuals who perform some form of exercise and less common in older individuals, where the most

1 – Post-graduate Student, School of Medicine, Universidade de São Paulo (USP), Ribeirão Preto, SP, Brazil.

2 – Professor, Department of Biomechanics, Medicine and Rehabilitation of the Locomotor Apparatus, School of Medicine, Universidade de São Paulo (USP), Ribeirão Preto, SP, Brazil.

3 – Professor, Department of Internal Medicine, School of Medicine, Universidade de São Paulo (USP), Ribeirão Preto, SP, Brazil.

Study conducted at the Department of Biomechanics, Medicine and Rehabilitation of the Locomotor Apparatus, School of Medicine, Universidade de São Paulo (USP), Ribeirão Preto, with support from FAPESP and CAPES-PROBRAL.

Correspondence: Helton L.A. Defino, Rua Dornélia de Souza Mosca, 235, Jardim Canadá – 14024-120 – Ribeirão Preto (SP), Brasil. E-mail: hldefin@fmrp.usp.br

We declare no conflict of interest in this article

common injuries are fractures or injuries of the rotator cuff⁽³⁾. The atraumatic type occurs with subluxation episodes without trauma. The joint has a hypermobile capsule, allowing for excessive translation movement. Subluxation can be anterior, posterior, or inferior, and in most cases, a sum of directions constitutes a bidirectional or multidirectional instability⁽²⁻⁴⁾. The recurrent type occurs after minor trauma. Around 80% of primary traumatic dislocation cases progress to recurrences. The more intense the episodes of dislocation, the more frequent the recurrence, due to the progressive increase of the injury that occurs in successive dislocations⁽²⁻⁴⁾.

The Bankart lesion is the detachment of the anterior joint capsule and the labrum near the edge of the glenoid. This injury occurs in anterior scapulohumeral dislocations and is present in approximately 85% of recurrent dislocations. The understanding of the labral avulsion, known as a Bankart lesion or an "essential" lesion, was instrumental for the improvement of the surgical technique^(5,6).

Knowledge of the anatomy and biomechanics of the shoulder has improved considerably in recent years with magnetic resonance imaging (MRI), MR arthrography (arthro-MRI), more detailed biomechanical laboratory studies, and with the use of arthroscopy. The improvement of diagnostic methods and anatomical knowledge allowed new associated lesions to be revealed, such as SLAP (superior labrum anterior and posterior), GLAD (glenoid labrum articular disruption), ALPSA (anterior labroligamentous periosteal sleeve avulsion), HAGL (humeral avulsion of the glenohumeral ligament), changing the treatment method⁽⁷⁾.

The use of suture anchors decreased surgical time and made the procedure technically easier. Understanding the concepts of instability and capsuloligamentous laxity was also important in choosing the proper technique. Current surgical techniques aim to reconstruct associated lesions without restricting the mobility or activity of the patient⁽⁸⁾.

Treatment of recurrent dislocation of the shoulder can be performed using the conventional method, that is, open or arthroscopic surgery. Conventional treatment of recurrent dislocations, according to the

literature, results in recurrence rates ranging from 3 to 8%, depending on the author, and is still considered gold standard for this lesion^(2,5). Arthroscopy has made great advances, such as better knowledge of the associated lesions, better aesthetics, lower risk of failure of the subscapularis muscle, faster return to work and sports, and high patient satisfaction^(6,8,9,10). It presents results similar to open surgery when patients are appropriately selected^(8,9).

The objective of this study is to clinically and radiologically evaluate the postoperative integrity of the subscapularis muscle through strength, function, and MRI after deltopectoral approach for the treatment of recurrent anterior glenohumeral dislocation.

METHODS

From March 1997 to November 2006, 96 patients with recurrent anterior shoulder dislocation were operated on using a deltopectoral approach with the insertion of anchors at the Shoulder and Elbow Clinic at the Institute of Orthopedics and Traumatology (IOT), Passo Fundo, RS. Of these, 20 cases returned for the evaluative study. All cases had a minimum follow-up of 12 months and a maximum of 128, with an average of 40 months. The patients were all male, with a mean age 29 years (20-42 years), an average height of 1.76 m (1.67 to 1.89 m), and a mean weight of 76.1 kg (59-103 kg). The dominant side was affected in 13 patients (65%) (Table 1).

Patients underwent a physical examination of mobility, muscle strength, the belly-press test and the Gerber test.

For data analysis, we compared the differences between the isokinetic strength measurements in the operated and non-operated limbs for both internal and external rotation and 60°/s and 180°/s angular velocities. We also compared the strength deficits obtained for internal and external rotation for the same speed. To better understand the results, comparisons were also made by dividing the patients into two distinct groups: those with the dominant side being operated and non-dominant side being operated.

Magnetic resonance imaging (MRI) was performed in 15 patients on both shoulders to evaluate the thickness, the cross-sectional area, and the subscapularis muscle hypotrophy⁽¹²⁻¹⁴⁾. The images

Table 1 – Patient data.

Case	Name	PO months	Sex	Age (years)	Weight (kg)	Height (m)	Operated side	Dominant side	UCLA	Rowe
1	L.L.F.	20	M	37	78.0	1.71	right	right	33	100
2	W.R.L.	20	M	22	72.0	1.72	left	left	31	75
3	A.F.	81	M	42	80.0	1.70	left	right	26	75
4	J.A.C.	53	M	36	68.0	1.83	left	right	33	90
5	P.R.O.	23	M	25	60.0	1.70	right	right	31	100
6	C.P.	39	M	22	76.0	1.71	left	right	35	100
7	J.S.D.	30	M	28	59.0	1.67	right	right	31	90
8	M.G.	128	M	32	80.0	1.83	right	right	31	90
9	A.G.	64	M	25	82.5	1.82	right	right	24	70
10	A.C.G.	12	M	20	103.0	1.89	left	right	33	100
11	M.A.S.	22	M	23	68.0	1.72	right	right	31	100
12	T.P.R.	59	M	23	89.0	1.75	left	right	33	100
13	P.R.	38	M	26	62.0	1.70	left	right	31	90
14	L.A.	48	M	36	83.0	1.83	right	right	33	90
15	E.E.C.	40	M	36	68.0	1.75	left	left	31	90
16	D.B.D.	40	M	33	84.0	1.76	right	right	31	70
17	M.A.F.	14	M	26	83.0	1.79	right	right	33	50
18	F.G.L.	29	M	29	76.0	1.74	right	right	35	100
19	A.L.M.	14	M	27	72.0	1.75	right	right	33	100
20	S.G.	32	M	25	77.5	1.81	left	right	33	75

Legend: M: male, F: female.

Source: SAME-IOT, Passo Fundo, RS.

were made using the Siemens Avanto 1.5 Tesla at the Kozma radiology clinic, in Passo Fundo, RS. All images were obtained in the oblique sagittal and axial views, T1-weighted and DPW FAT SAT. The axial image chosen was the one that clearly showed the anterior and posterior labrum of the glenoid (Figure 2). In this image, a line was drawn parallel to the labrum; at the same level, the thickness, cross-sectional area, and fatty degeneration of the subscapularis tendon were measured on a sagittal image (Figure 3). To determine the thickness, a line was drawn perpendicular to the axis in the central part of the tendon connecting its

anterior and posterior margins in the sagittal image. The fatty degeneration was evaluated according to the Bernageau and Goutallier classification (Chart 1). Both the thickness and the cross-sectional area were measured with the aid of the image analysis software and FilmeLite.

The Rowe and UCLA (University of California at Los Angeles) scoring systems were used to assess patients.

The statistical analysis was performed using the paired Student's t-test. Results were considered statistically significant when $p < 0.05$.

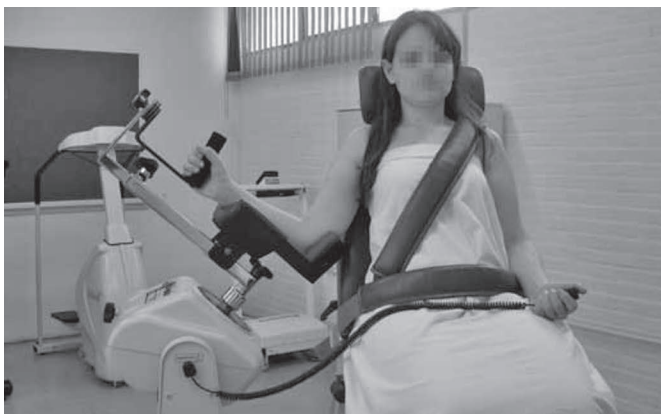

Figure 1 – Positioning the patient on the dynamometer in external and internal rotation.

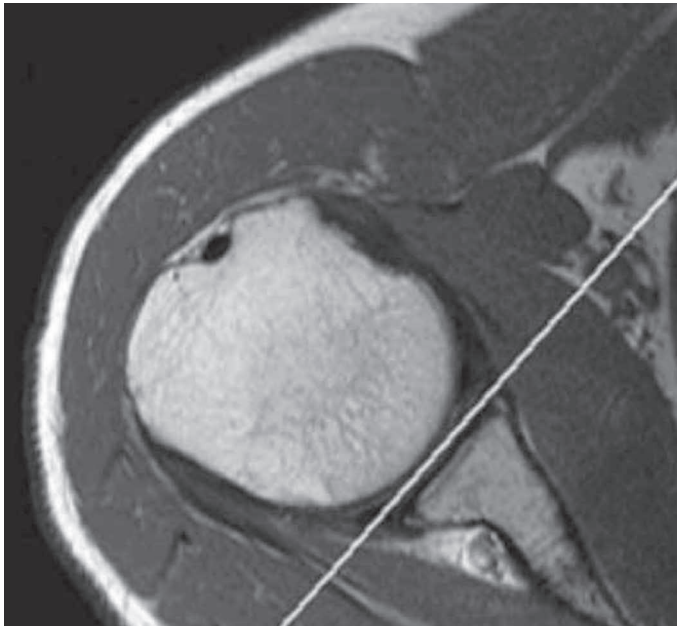


Figure 2 – MRI image in the axial plane.

Chart 1 – Classification of fatty degeneration according to Bernageau and Goutallier.

Grade 0	<i>Absence of fat</i>
Grau 1	<i>Small fatty striations</i>
Grade 2	<i>Proportion of fat is less than muscle</i>
Grade 3	<i>Equal proportion of fat and muscle</i>
Grade 4	<i>Proportion of fat is greater than muscle</i>

RESULTS

All patients had negative belly-press and Gerber tests.

The results of isokinetic strength assessments are presented in Table 2. Comparison of the peak torque obtained for the operated and non-operated shoulders

for the angular velocity of 60°/s for both internal ($p = 0.036$) and external ($p = 0.008$) rotation, revealed statistically significant differences. However, for the speed of 180°/s, reductions in peak torque were not significant (internal rotation: $p = 0.133$; external rotation: $p = 0.393$).

When the data are evaluated by dividing patients into two groups, those who were operated on the dominant side had differences between peak torque for both internal rotation (180°/s: $p = 0.205$; 60°/s: $p > 0.4$) as for the external (180°/s: $p = 0.076$; 60°/s: $p > 0.4$) at both speeds that were not statistically significant. However, for patients operated on the non-dominant side, the decrease in peak torque of the affected limb was significant.

In the comparison between the deficits in peak torque for external and internal rotation at the same speed, the difference found at 60°/s was statistically significant at a significance level of 5% ($p = 0.046$), with the deficit of internal rotation (20.87%) superior to that of external rotation (15.28%). For the speed of 180°/s, the difference between the deficits is not significant ($p > 0.400$), as both are approximately 16%. When comparing only patients operated on the non-dominant side, we observed that the largest deficit is for internal rotation at 180°/s (21.04%) (Figure 4), while for the group of patients with the dominant side operated, the largest deficit was found in internal rotation at 60°/s (23.37%) (Figure 5).

The results obtained with the MRI images are shown in Table 3.

The thickness of the subscapularis tendon in the affected limb is significantly smaller than that of the

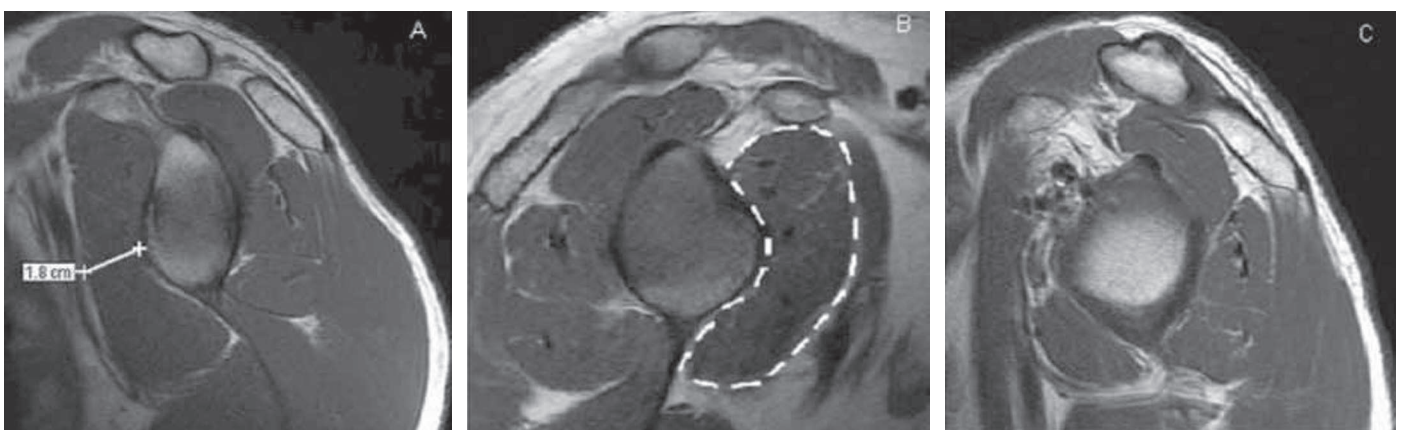


Figure 3 – MRI images in the sagittal plane. A) for measuring the thickness, B) for measuring the area, and C) for the assessment of fatty degeneration.

Table 2 – Evaluation of isokinetic strength.

Patient	60°/s						180°/s					
	External rotation			Internal rotation			External rotation			Internal rotation		
	Peak torque (N.m)		Deficit (%)	Peak torque (N.m)		Deficit (%)	Peak torque (N.m)		Deficit (%)	Peak torque (N.m)		Deficit (%)
	NO	O		NO	O		NO	O		NO	O	
L.L.F.	54.20	55.50	2.30	58.30	68.20	17.00	50.30	53.70	6.70	62.50	71.20	13.90
W.R.L.	26.80	18.80	29.80	40.60	23.40	42.40	13.70	18.70	36.40	16.80	18.20	8.20
A.F.	36.10	32.60	9.60	50.10	41.00	18.20	27.90	21.90	21.50	29.20	21.40	26.70
J.A.C.	23.40	20.20	13.60	41.90	43.00	2.70	17.70	18.90	6.70	41.30	34.00	17.60
P.R.O.	25.50	19.70	22.50	36.80	24.70	32.80	21.00	17.30	17.70	22.40	24.30	8.50
C.P.	36.30	31.50	13.20	50.00	37.10	25.80	18.00	23.00	27.50	24.00	28.40	18.20
J.S.D.	30.50	26.50	13.00	41.60	33.90	18.50	22.90	21.90	4.50	24.40	23.70	2.80
M.G.	23.00	39.10	70.30	38.80	51.70	33.40	20.40	29.00	42.50	28.60	32.30	13.00
A.G.	52.50	43.80	16.60	64.40	73.70	14.50	25.50	19.10	25.30	20.50	25.80	25.70
A.C.G.	23.30	22.70	2.40	29.40	31.20	6.00	19.40	22.50	16.00	30.40	37.00	21.60
M.A.S.	30.10	28.30	6.20	52.60	41.90	20.30	25.90	27.00	4.30	47.10	39.60	15.90
T.P.R.	64.30	53.50	16.80	104.70	80.80	22.90	61.10	46.30	24.20	89.80	71.60	20.20
P.R.	37.40	31.30	16.30	48.90	46.30	5.20	32.80	35.50	8.30	43.90	46.10	5.00
L.A.	50.00	41.40	17.30	52.70	70.50	33.80	40.30	35.50	11.80	41.70	47.60	14.20
E.E.C.	33.10	29.20	11.90	64.70	55.00	15.00	30.20	34.60	14.40	29.90	31.90	6.80
D.B.D.	62.10	50.70	18.30	75.40	59.50	21.10	50.20	40.10	20.00	45.50	38.10	16.30
F.G.L.	32.00	29.80	7.00	49.00	55.90	14.20	28.60	33.30	16.10	44.30	46.80	5.70
A.L.M.	31.90	33.10	3.80	54.40	38.00	30.10	28.80	30.80	6.90	49.30	31.50	36.30
S.G.	38.90	36.50	6.20	52.30	35.20	32.80	31.60	29.00	8.20	51.20	31.70	38.00
M.A.F.	35.00	32.00	8.57	51.50	46.00	10.68	30.00	31.00	3.30	40.10	37.40	6.73
Mean	37.32	33.81	15.28	52.91	47.85	20.87	29.82	29.46	16.12	39.15	36.93	16.07

Legend: NO: non-operated shoulder, O: operated shoulder

normal side ($p = 0.0005$), 0.4 cm on average, which constitutes a deficit of 19%. Even when patients are evaluated in different groups, this difference is also significant. For patients who were operated on the dominant side, the deficit presented was 13.31% ($p = 0.02$) and 30% for those who were operated on the non-dominant side ($p = 0.004$).

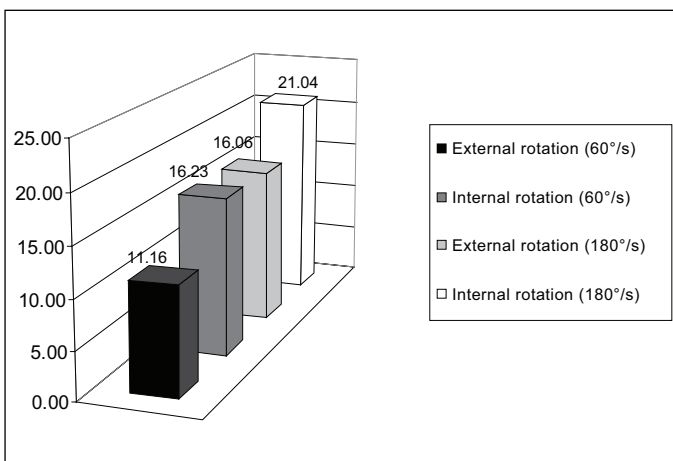


Figure 4 – Percentage of peak torque deficit in patients operated on the non-dominant side.

The cross-sectional area of the subscapularis is also significantly reduced when compared with the normal side ($p = 0.0005$), 1.7^{cm²} on average, which constitutes a difference of 23%. For patients who were operated on the dominant side, the deficit was found to be 14.15% ($p = 0.005$), while for the cases in which the non-dominant side was operated, the difference in

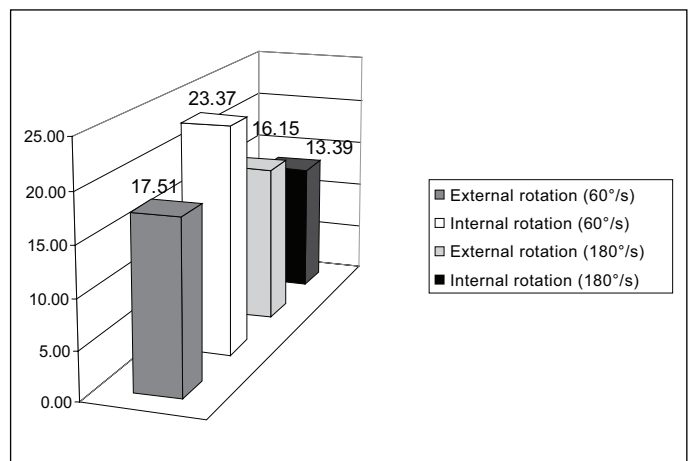


Figure 5 – Percentage of peak torque deficit in patients operated on the dominant side.

area was 36.51% ($p = 0.00005$).

The assessment of fatty degeneration showed that 46.7% had grade 1, and 33% had no fatty degeneration. When the patients are evaluated in separate groups, in the cases where the dominant side corresponds to the operated limb, only grade 0 (33%) and grade 1 (67%) were observed. In patients who were operated on the non-dominant side, 33% did not show any degeneration. However, degeneration in grades 2 (33%) and 3 (17%) were observed in this group.

Using the Rowe and UCLA scoring systems, we observed excellent and good results in most patients, averaging 88 and 31.6 points, respectively (Table 1).

DISCUSSION

Open surgery in which the labrum and the inferior glenohumeral ligament are restored is still considered by many authors to be the treatment of choice to stabilize the shoulder. However, open surgery may restrict mobility and strength, and can evolve into secondary osteoarthritis⁽⁹⁾.

Sachs *et al.* evaluated the role of the subscapularis muscle after open surgery and found that 77% of patients had normal function of the subscapularis and at least 80% strength compared to the opposite side. All patients had a negative belly-press test⁽¹⁵⁾.

Comparing the strength between patients operated by open surgery and arthroscopy, Hiemstra *et al.*⁽¹⁶⁾ found no statistically significant differences in isokinetic strength for internal and external rotation at angular velocities of 60 and 180°/s.

In our study, statistically significant differences in peak torque were found for the operated and non-operated sides at a speed of 60°/s in both external and internal rotation. However, for 180°/s, no difference was observed. This may be due to the greater strength required in the test at a slower speed. For patients who were operated on the non-dominant side, the differences between the two angular velocities were significant, and where the operated side is the dominant side, the decreases were insignificant. This is probably because the dominant side is the side that is most used and recovers more adequately.

We also observed in our study that the difference between the peak torque deficits for the external and internal rotation at 60°/s was significant, with the internal rotation deficit predominating. For the speed of 180°/s, the difference between the deficits was not significant. However, when comparing only patients that were operated on the non-dominant side, we observed that the largest deficit is related to internal rotation to 180°/s, while for the group of patients operated on the dominant side, the largest deficit was found for the internal rotation at 60°/s.

Table 3 – Evaluation of MRI images.

Patient	Operated side	Dominant side	Thickness (cm)			Cross-section (cm ²)			Goutallier
			O	NO	Deficit (%)	O	NO	Deficit (%)	
M.A.F.	R	R	1.40	1.90	26.32	5.60	7.20	22.22	1
L.L.F.	R	R	1.30	1.90	31.58	5.20	7.40	29.73	1
F.G.L.	R	R	1.30	1.10	-18.18	5.50	5.60	1.25	1
J.S.D.	R	R	1.40	1.20	-16.67	5.40	5.05	-6.53	1
M.G.	R	R	1.40	1.60	12.50	3.60	4.15	13.25	0
M.A.S.	R	R	0.90	0.90	0.00	4.70	4.80	2.08	0
P.R.O.	R	R	1.30	1.90	31.58	5.50	7.40	25.68	1
A.G.	R	R	1.40	1.90	26.32	5.80	7.20	19.44	0
D.B.D.	R	R	1.40	1.90	26.32	5.90	7.25	18.62	1
S.G.	L	R	1.80	2.20	18.18	5.85	8.95	34.64	0
C.P.	L	R	1.00	2.10	52.38	4.55	7.80	41.67	1
A.C.G.	L	R	1.10	1.90	42.11	4.80	6.90	30.96	2
A.F.	L	R	1.30	2.00	35.00	5.70	8.80	34.77	3
J.A.C.	L	R	1.40	1.60	12.50	3.35	6.10	44.99	2
P.R.	L	R	1.70	2.10	19.05	5.90	8.60	31.39	0
Mean					19.93			22.94	

Legend: R: right, L: left; NO: non-operated shoulder, O: operated shoulder.

The results of our study may have been affected by several factors, since the isokinetic strength testing was performed with the aid of a dynamometer. Thus, the reliability of the test depends on the accuracy of the dynamometer, the reproducibility of the measured parameters, the type of protocol applied, subjective factors, and the motivation of the patient.

The MRI allowed us to verify that the thickness of the subscapularis in the operated shoulder is significantly inferior than the normal side, even when patients are assessed in separate groups (dominant and non-dominant side operated). The difference was 19%, a result similar to that obtained in the studies of Tuoheti *et al.*⁽¹⁷⁾ (18.7%). In assessing the cross-sectional area of the subscapularis, a significant reduction in the operated shoulder was also observed, with a deficit of 23%. Tuoheti *et al.*⁽¹⁷⁾ found a 29% deficit in their study.

The assessment of fatty degeneration showed that most patients had good results, and that only in those

with the non-dominant side operated was degeneration observed in grades 2 and 3.

The results presented in this paper could be more representative if a greater number of the 96 patients asked to attend the evaluation had attended. Only 20 patients participated in the study and the others did not attend due to distance and financial impossibility.

CONCLUSION

Open surgery in which the labrum and the inferior glenohumeral ligament are restored is still considered by many authors to be the treatment of choice to stabilize the shoulder. However, open surgery may limit strength, which was a statistically significant finding in our study. However, we found trends toward improved outcomes in patients operated on their dominant side. The MRI also showed no significant reduction in the thickness and cross-sectional area of the subscapularis tendon, leading to varying degrees of hypotrophy.

REFERENCES

1. Neer CS. Cirurgia do ombro. Rio de Janeiro: Revinter; 1995.
2. Lech O. Fundamentos em cirurgia do ombro: ortopedia e reabilitação. Rio de Janeiro: Revinter; 2005.
3. Piluski P. Instabilidade e luxação: conceitos básicos. In: Lech O. Fundamentos em cirurgia do ombro: ortopedia e reabilitação. 2a. ed. Rio de Janeiro: Revinter; 2005. p 395-400.
4. Lech O, Ranzzi A, Bordin F, Faggion M, Zillmer V, Piluski P. Membro superior: abordagem fisioterapêutica das patologias ortopédicas. Rio de Janeiro: Revinter; 2005.
5. Rockwood CA Jr, Matsen FA 3rd, Wirth MA, Lippitt SA. The shoulder. Philadelphia: Saunders; 2004.
6. Snyder SJ. Shoulder arthroscopy. New York: McGraw-Hill; 2002.
7. Lech O, Freitas J R, Piluski P, Severo A. Luxação recidivante do ombro: do papiro de Edwin Smith à capsuloplastia térmica. Rev Bras Ortop. 2005;40(11/12):625-37.
8. Tjoumakaris FP, Abboud J, Hasan SA. Arthroscopic and open Bankart repairs provide similar outcomes. Clin Orthop Relat Res. 2006;(446):227-32.
9. Hobby J, Griffin D, Dunbar, M, Boileau, P. Is arthroscopic surgery for stabilization of chronic shoulder instability as effective as open surgery? A systematic review and meta-analysis of 62 studies including 3044 arthroscopic operations. J Bone Joint Surg Br. 2007;89(9):1188-96.
10. Rhee YG, Lim CT, Cho NS. Muscle strength after anterior shoulder stabilization: arthroscopic versus open Bankart repair. Am J Sports Med. 2007;35(11):1859-64.
11. Cahalan TD, Johnson ME, Chao YS. Shoulder strength analysis using the Cybex II isokinetic dynamometer. Clin Orthop Relat Res. 1991;(271):249-57.
12. Scheibel M, Nikulka C, Schroeder RJ. Structural integrity and clinical function of the subscapularis musculotendinous unit after arthroscopic and open shoulder stabilization. Am J Sports Med. 2007;35(7):1153-61.
13. Zanetti M, Gerber C, Hodler J. Quantitative assessment of the muscles of the rotator cuff with magnetic resonance imaging. Invest Radiol. 1998;33(3):163-70.
14. Steinbach LS. Magnetic resonance imaging of glenohumeral joint instability. Sem Musculoskelet Radiol. 2005;9(1):44-55.
15. Sachs RA, Williams B, Stone ML, Paxton L, Kuney M. Open Bankart repair: correlation of results with postoperative subscapularis function. Am J Sports Med. 2005;33(10):1458-62.
16. Hiemstra LA, Sasyniuk TM, Mohtadi NG, Hollinshead RM. Open versus arthroscopic shoulder stabilization for recurrent traumatic anterior shoulder instability: a comparison of strength and endurance deficits. [Anais]. In: 10th International Congress of Shoulder and Elbow Surgery (ICSS). Sauípe, Brasil; 2007.
17. Tuoheti Y, Itoi E, Minagawa H, Wakabayashi I, Kobayashi M, Okada K, *et al.* Quantitative assessment of thinning of the subscapularis tendon in recurrent anterior dislocation of the shoulder by use of magnetic resonance imaging. J Shoulder Elbow Surg. 2005;14(1):11-5.