

Spontaneous Cerebrospinal Fluid Otorrhea from a Persistent Tympanomeningeal Fissure Presenting as Recurrent Serous Otitis Media

Arman Zakaryan¹ Lars Poulsen² Camilla Hollander³ Kåre Fugleholm²

¹ Department of Neurosurgery, Yerevan State Medical University, Armenia

² Department of Neurosurgery, Copenhagen University Hospital, Rigshospital, Copenhagen, Denmark

³ Department of Otorhinolaryngology - Head and Neck Surgery, Copenhagen University Hospital, Rigshospital, Copenhagen, Denmark

Address for correspondence Arman N. Zakaryan, MD, PhD,

Department of Neurosurgery, Yerevan State Medical University, 55/6 Tsarav aghbyuri street, apartment 29, Yerevan-0052, Armenia (e-mail: armzak@gmail.com).

J Neurol Surg Rep 2015;76:e117–e119.

Abstract

Keywords

- cerebrospinal fluid leak
- spontaneous cerebrospinal fluid otorrhea
- patent tympanomeningeal (Hyrtl) fissure
- recurrent serous otitis media
- retrosigmoid approach

We describe spontaneous cerebrospinal fluid (CSF) otorrhea through a patent tympanomeningeal (Hyrtl) fissure presenting as recurrent serous otitis media. The CSF leak was observed when a drain was placed through the tympanic membrane by an otologist. The diagnosis was then confirmed by computed tomography and magnetic resonance imaging, and the patient underwent a successful surgical treatment via a retrosigmoid approach. We describe the case and review causes of spontaneous CSF rhinorrhea/otorrhea.

Introduction

Cerebrospinal fluid (CSF) leak is a medical condition in which an unusual connection between the subarachnoid space and extracranial structures occurs. We summarize the etiopathogenic causes of the cranial CSF leaks in ►Fig. 1. Because the risk of meningitis and other complications related to CSF leak is high, this condition is potentially life threatening. Watery discharge from the nose or ear requires a thorough examination and the exclusion of CSF fistulas as the cause.

Case Report

A 57-year-old man, with previous mild bilateral hearing impairment and recurrent left-sided serous otitis media for

1 year, presented with a headache and general malaise. The patient experienced a classical whiplash injury 3 years before but never had a significant head injury. There were no signs of meningitis and no neurologic deficits. The patient had severe otoliquorrhea through a drain tube placed through the tympanic membrane previously by an otologist to treat the serous otitis. The fluid tested positive for β -2 transferrin. The drain tube was removed after which the patient developed rhinoliquorrhea. High-resolution computed tomography (CT) and magnetic resonance imaging (MRI) demonstrated a defect in the left temporal bone between the jugular foramen and meatus acusticus, likely a patent tympanomeningeal (Hyrtl) fissure, connecting the subarachnoid space of the posterior cranial fossa with the middle ear (►Figs. 2, 3, and 4). There was no other associated pathology, in particular no

received

June 17, 2014

accepted

January 22, 2015

published online

May 15, 2015

DOI <http://dx.doi.org/>

10.1055/s-0035-1549220.

ISSN 2193-6366.

© 2015 Georg Thieme Verlag KG

Stuttgart · New York

License terms



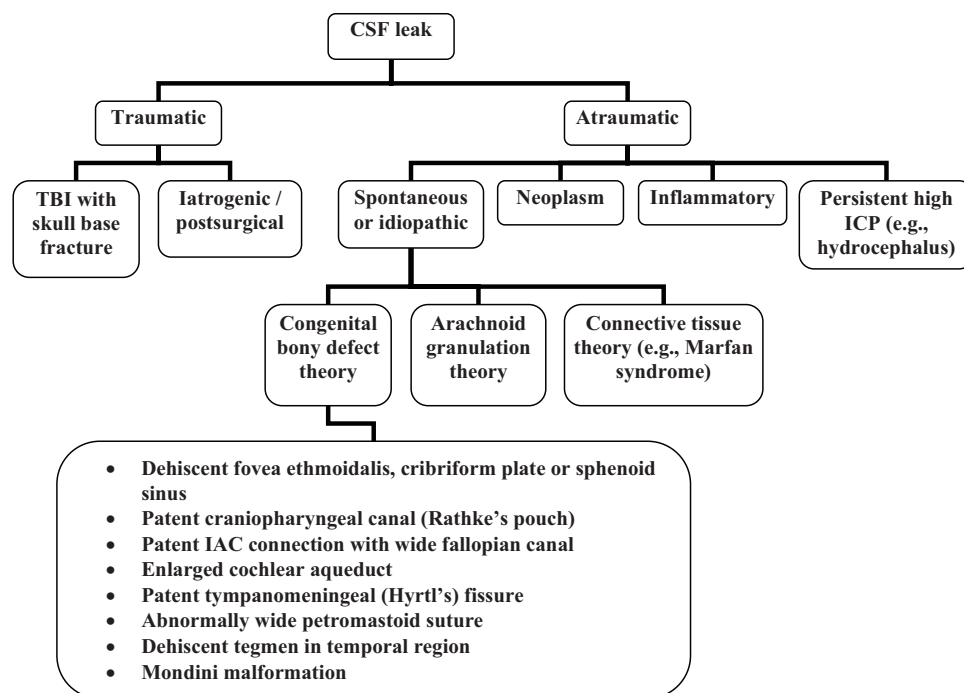


Fig. 1 Schematic representation of the etiopathogenic classification of the cranial cerebrospinal fluid leaks.

epidermoid, tumor, or bone cyst. A retrosigmoid approach with blockage of the bone defect by bone wax followed by a free fascia flap and DuraSeal (Covidien, Mansfield, Massachusetts, United States) was performed. Following this, the patient had no further CSF leak and his headache disappeared.

Discussion

Spontaneous CSF otorrhea is uncommon, and sometimes the exact cause is difficult to establish. The manifesting signs are not specific and usually characterized by a range of various

clinical symptoms of intracranial hypotension (e.g., headache, dizziness and vertigo, double vision, nausea and vomiting, fatigue, a metallic taste in the mouth, myoclonus, tinnitus, tingling in the limbs, facial numbness or weakness). Even worse, such patients may present with recurrent unilateral otitis complicated with meningitis. The diversity of presenting symptoms and relatively rare occurrence of a spontaneous CSF leak make a late diagnosis more likely.

To the best of our knowledge, only three articles have been published in the searchable literature indicating the Hyrtl fissure as a source of spontaneous CSF otorrhea.¹⁻³ The tympanomeningeal (Hyrtl) fissure provides direct and

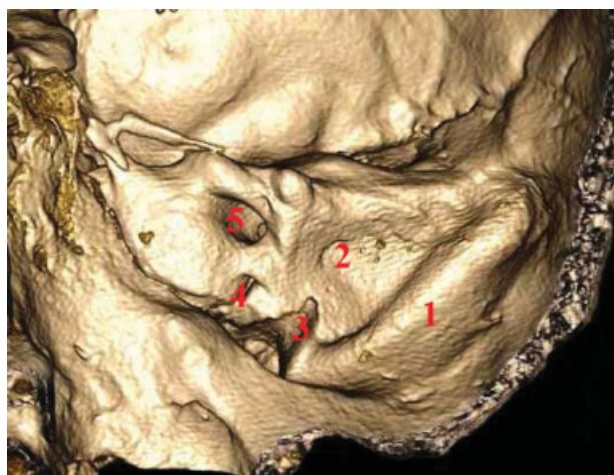


Fig. 2 Three-dimensional reconstruction of the left petrous bone computed tomography. 1, sinus sigmoideus; 2, ductus endolymphaticus; 3, foramen jugularis; 4, Hyrtl fissure; 5, meatus acusticus internus.

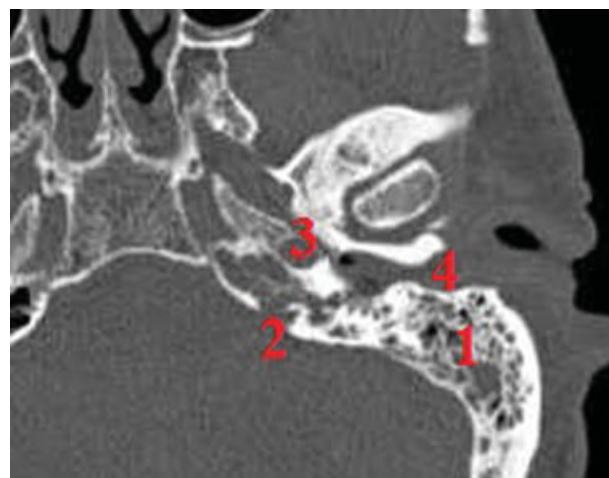


Fig. 3 Computed tomography of the left petrous bone. 1, mastoid aircells; 2, Hyrtl fissure; 3, carotid foramen; 4, meatus acusticus externus.

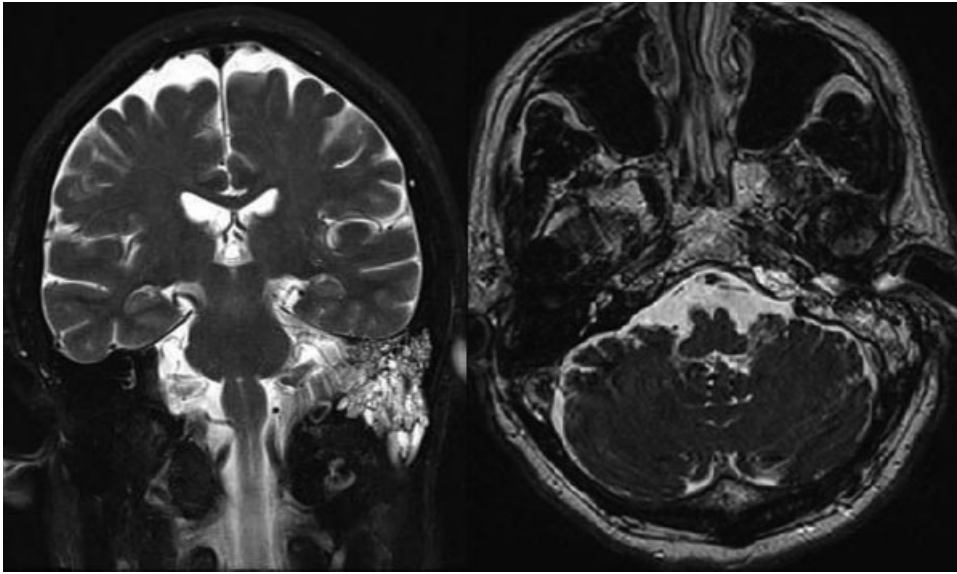


Fig. 4 Magnetic resonance imaging showing a left temporal bone filled with cerebrospinal fluid.

functional communication between the round window (middle ear) and posterior cranial fossa in the fetus of 16 to 18 weeks of gestation. Normally this communication is obliterated on a ~ 24-week-old fetus due to progressive ossification. Incomplete ossification results in a patent tympanomeningeal (Hyrtl) fissure, a rare anatomical variant.¹⁻³

In this case the retrosigmoid approach was chosen to address the fistula directly at the dural level. This could have been achieved with a transmastoid approach as well, although with much less room to maneuver. We did not think that the transtympanic approach was a good option because we have little experience with it.

Conclusion

Cranial spontaneous CSF fistula is a rare condition, but the potential life-threatening complications justify MRI and CT of

patients with recurrent watery discharge from the ear or nose, to identify the source of a possible CSF fistula.

Acknowledgments

We thank the Medtronic Corporation for the financial support of Arman Zakaryan.

References

- 1 Gacek RR, Leipzig B. Congenital cerebrospinal otorrhea. *Ann Otol Rhinol Laryngol* 1979;88(3 Pt 1):358-365
- 2 Rich PM, Graham J, Phelps PD. Hyrtl's fissure. *Otol Neurotol* 2002; 23(4):476-482
- 3 Jégoux F, Malard O, Gayet-Delacroix M, Bordure P, Legent F, Beauvillain de Montreuil C. Hyrtl's fissure: a case of spontaneous cerebrospinal fluid otorrhea. *AJNR Am J Neuroradiol* 2005;26(4): 963-966