

# Clinical response to oral tofacitinib in pediatric patients with alopecia areata



Soundos Youssef, MD,<sup>a</sup> and Lindsey A. Bordone, MD<sup>b</sup>

**Key words:** alopecia areata; JAK inhibitor; Janus kinase inhibitor; oral tofacitinib; pediatric population; treatment efficacy.

## INTRODUCTION

Alopecia areata (AA) is an autoimmune disease characterized by cytotoxic T cell–driven inflammation targeting hair follicles<sup>1,2</sup> and causing non-scarring hair loss. AA is associated with the overexpression of proinflammatory cytokines acting via Janus kinase (JAK)/signal transducers and activators of transcription signaling pathway.<sup>1</sup> AA disproportionately affects youth<sup>3</sup> and carries a significant psychosocial burden.<sup>4</sup> While a myriad of treatments has been used for AA with varying success, there is no cure. Oral tofacitinib is a JAK3 inhibitor with established efficacy and tolerability in adult AA<sup>5</sup> but not yet in pediatric AA. It is approved for juvenile idiopathic arthropathy (extended oligoarthritis, rheumatoid factor–positive or–negative polyarthritis, systemic juvenile idiopathic arthropathy without active systemic features) in patients as young as 2 years of age, with an acceptable safety profile.<sup>6</sup> Baricitinib (JAK1 and JAK2 inhibitor) was recently Food and Drug Administration–approved for moderate-to-severe adult AA.<sup>7</sup> We herein retrospectively report 10 chart-reviewed pediatric AA cases seen in the Columbia dermatology clinic and prescribed oral tofacitinib (Table 1, Fig 1). As necessary precautions are required with JAK inhibitors (JAKis),<sup>8</sup> baseline and follow-up laboratory testing (complete metabolic panel, glucose, complete blood count, tuberculosis screening, and lipid panel in those without a recent baseline) was

### Abbreviation used:

AA:	alopecia areata
AM:	ante meridiem
AT:	alopecia totalis
AU:	alopecia universalis
Fig:	Figure
ILS:	intralesional steroid
JAKi:	Janus kinase inhibitor
PM:	post meridiem
SALT:	Severity of Alopecia Tool

performed. Patients were followed up for 2 years after hair regrowth to evaluate for relapse after dose tapering. Consent was obtained to use patient photographs (Fig 2).

## CASES

### Case 1

A 12-year-old boy presented for a 6-year history of patchy AA. He failed intralesional steroid (ILS) injections and topical clobetasol gel. On physical exam, the Severity of Alopecia Tool (SALT) score was 40%. He was prescribed 5 mg oral tofacitinib twice a day. After 1 month of treatment (electively taken once daily), he experienced full hair regrowth without side effects.

### Case 2

A 13-year-old boy presented for a few month-history of alopecia universalis (AU). He had tried ILS,

From the Postdoctoral Research Fellow, Department of Dermatology, Columbia University Irving Medical Center, New York, New York<sup>a</sup>; and Department of Dermatology, Columbia University Irving Medical Center, New York, New York.<sup>b</sup>

Funding sources: None.

IRB approval status: Reviewed and approved by Columbia University's Human Research Protection Office IRB; Protocol # IRB-AAU1635.

Consent for publication: Consent for the publication of patient photographs and medical information was provided by the authors at the time of article submission to the journal, and both the patient and parents gave consent for photographs and medical information to be published in print and online

and with the understanding that this information may be publicly available.

Correspondence to: Lindsey A. Bordone, MD, Department of Dermatology, Columbia University Irving Medical Center, 161 Fort Washington Avenue, New York, NY 10032. E-mail: [lab87@cumc.columbia.edu](mailto:lab87@cumc.columbia.edu).

JAAD Case Reports 2023;31:83-8.

2352-5126

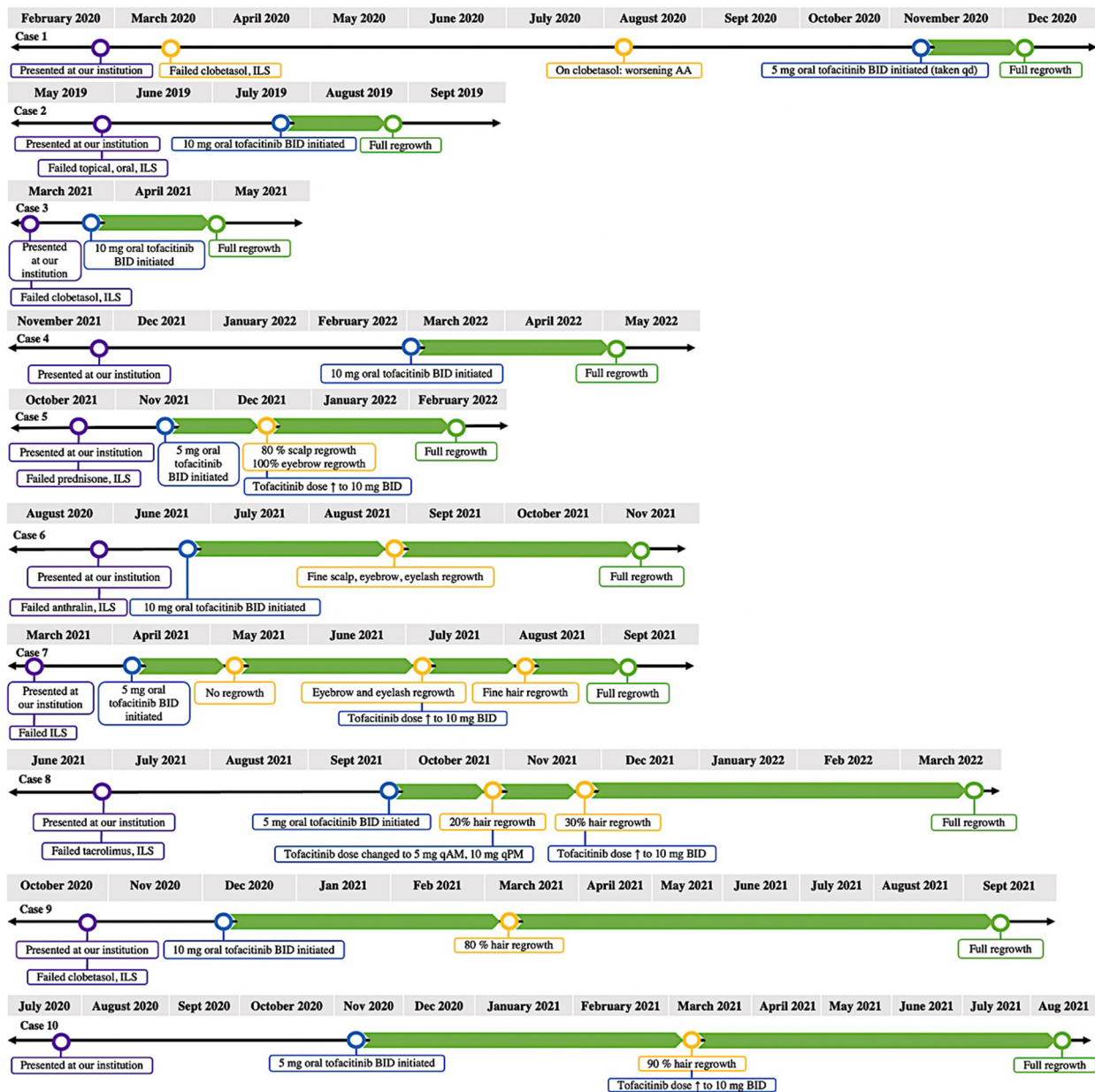
© 2022 by the American Academy of Dermatology, Inc. Published by Elsevier, Inc. This is an open access article under the CC BY-NC-ND license (<http://creativecommons.org/licenses/by-nc-nd/4.0/>).

<https://doi.org/10.1016/j.jidcr.2022.08.024>

**Table I.** Patient demographics and history at presentation, previously attempted treatments, tofacitinib treatment course and duration

Case	Sex	Age (yrs)	Medical history	AA subtype	Baseline SALT score (%)	Previous therapies	Tofacitinib Tx course				Tx duration (mo)
							After (mo)	Dose (mg twice a day)	Follow-up SALT score (%)	% change in the SALT score (% regrowth)	
1	Boy	12	None	Patchy	40	Topical and ILS	1	5 (once daily)	0	100	1
2	Boy	13	None	AU	100	Topical, oral, ILS	1	10	0	100	1
3	Girl	13	AD	Patchy	60	Topical and ILS	1	10	0	100	1
4	Boy	13	None	AU	100	None	2	10	0	100	2
5	Girl	10	None	Patchy	50	Oral and ILS	1	5	20	60	3
							2	10	0	100	
6	Boy	15	Hashimoto's	AU	90	ILS, anthralin	2	10	80	11.1	4.5
							2.5	10	0	100	
7	Boy	16	None	Patchy	50	ILS	1	5	50	0	5
							2	5	50	0	
							1	10	40	11.1	
							1	10	0	100	
8	Girl	7	None	AT	100	Tacrolimus ointment, ILS	1	5	80	20	6
							1	5 (qAM), 10 (qPM)	70	30	
							4	10	0	100	
							3	10	20	77.7	
9	Girl	12	Celiac	Ophiasis	90	Topical and ILS	6	10	0	100	9
							4	5	10	89.5	
10	Girl	12	None	Patchy	95	None	4	5	10	89.5	9
							5	10	0	100	

AA, Alopecia areata; AD, atopic dermatitis; AM, ante meridiem; AT, alopecia totalis; AU, alopecia universalis; ILS, intralesional steroids; PM, post meridiem; q, every; SALT, Severity of Alopecia Tool; Tx, treatment.

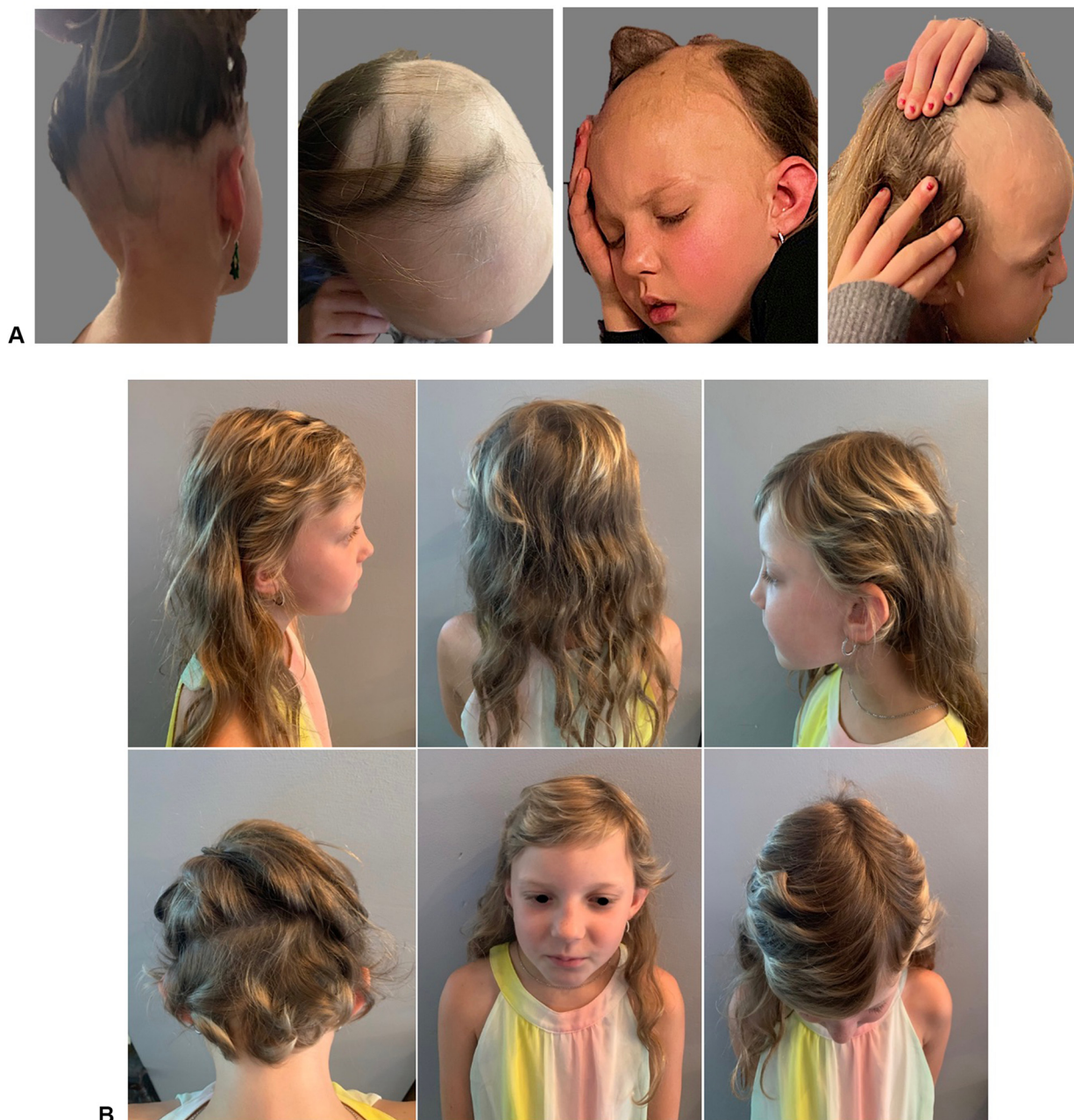

**Fig 1.** Patient timelines showing dates of initial presentation at our institution, therapies tried, oral tofacitinib initiation, and treatment response. ↑, Increased; AA, alopecia areata; AM, ante meridiem; Aug, August; Dec, December; ILS, intralesional steroids; Nov, November; q, every; Sept, September.

topical, and oral steroids without response. SALT score was 100%. He had positive scalp hair pull test, intact eyebrows and eyelashes, pitting nails, and patchy hair loss across bilateral arms and legs. He was therefore put on 10 mg oral tofacitinib BID. The patient presented after one month of treatment with full regrowth and no side effects other than mild facial acne.

### Case 3

A 13-year-old girl with atopic dermatitis presented for a 1-year history of rapid hair shedding unresponsive to topical steroids or ILS. SALT score was 60% and right eyelashes were substantially affected. After one month of well tolerated 10 mg oral tofacitinib BID, she experienced full hair regrowth.



**Fig 2.** Photographs shared with consent of case 3 before (A) and after (B) 1 month of 10 mg of oral tofacitinib twice daily.

#### Case 4

A 13-year-old boy presented for a few months of functionally impairing AU. The SALT score was 80%. He had over 50% eyelash and eyebrow loss with severe eye irritation, no hair on arms, axillae, or legs, and significant nail pitting. He was therefore prescribed 10 mg oral tofacitinib twice a day. Two months later, he exhibited full regrowth without complaints.

#### Case 5

A 10-year-old girl presented for worsening patchy AA dating back to months prior to presentation. Prednisone and ILS were unsuccessful. Upon examination, the SALT score was 50% with eyebrow and eyelash involvement. After 1 month of 5 mg oral tofacitinib twice a day, she had regrown her eyebrows and coronal patches, achieving a 20% SALT score (ophiasis). The dose was hence doubled

(10 mg twice a day). After 2 months, she experienced complete regrowth without adverse events.

#### Case 6

A 15-year-old boy with Hashimoto's thyroiditis presented with a 1-year history of AU. He tried ILS and anthralin without amelioration. He reported severe eye irritation due to eyebrow and eyelash loss. On physical exam, the SALT score was 90%; alopecia barbae and patchy hair loss over bilateral arms were noted. After 2 months of 10 mg oral tofacitinib twice a day, the SALT score was down to 80% with some eyelash regrowth. After 2 and a half months of well-tolerated therapy, he presented with full hair regrowth.

#### Case 7

A 16-year-old boy presented for intermittent alopecia totalis (AT) that started before the age of 10 years. His condition was refractory to ILS and involved his eyebrows. The SALT score was 50%. He presented after 1 month of 5 mg oral tofacitinib twice a day with persistent scalp and left medial eyebrow patches of hair loss. After 2 months, he only regrew his eyebrows and eyelashes. The patient's tofacitinib dose was thus increased to 10 mg twice a day. The following month, he started to regrow fine scalp hair. One month later, he presented with full regrowth and no complaints.

#### Case 8

A 7-year-old girl presented for AA that started a few months ago (Fig 2, A) along her occipital hairline with gradual worsening to AT. She was applying tacrolimus ointment without improvement. She couldn't tolerate ILS given the large area of involvement. She reported eyelash loss that had mostly regrown. The mother was unsure if the patient grew body hair prior to disease onset. SALT score was 100%. The patient was initially put on 5 mg oral tofacitinib BID for one month with minor regrowth. She was henceforth prescribed 5 mg in the morning (AM), 10 mg in the evening (PM) for a month. She presented with a SALT score of 70% and normal eyebrows and eyelashes. She was subsequently put on 10 mg BID and returned after four months with full regrowth (Fig 2, B) and no side effects.

#### Case 9

A 12-year-old girl with celiac disease presented for deteriorating AA that first appeared at the age of 4 years. She reported losing patches of eyebrows and eyelashes with severe chronic ocular inflammation. She tried clobetasol and ILS without response. On examination, the SALT score was 90% (ophiasis

pattern) and arms and legs were hairless. After 3 months on 10 mg oral tofacitinib twice a day, the SALT score was reduced to 20%. She achieved full regrowth after 6 months without side effects.

#### Case 10

A 12-year-old treatment-naïve girl presented for a 1-year history of severe patchy AA. The SALT score was 95%. After 4 months on 5 mg oral tofacitinib twice a day, the SALT score was reduced to 10% (ophiasis). After 5 months on 10 mg oral tofacitinib twice a day, she achieved full regrowth and was doing well.

### DISCUSSION

Oral tofacitinib has been gaining momentum among JAKis for the treatment of adult AA.<sup>9</sup> Studies investigating its use for pediatric AA are scarce. Craiglow et al reported positive outcomes with 5 mg oral tofacitinib twice a day for pediatric AA.<sup>10</sup>

Our patient population was equally distributed with respect to sex but substantially varied in terms of AA onset (as early as the age of 4 years, latest onset at the age of 14 years), disease subtype (5/10 patchy AA, 1/10 AT, 1/10 ophiasis, 3/10 AU) and severity (SALT scores ranging from 40% to 100%), and eyebrow (6/10) and eyelash involvement (7/10). Moreover, 3 of 10 had a concomitant autoimmune disease (eczema, Hashimoto's thyroiditis, celiac) known to be associated with AA.<sup>11</sup> There was no family history of AA or other autoimmune diseases. Prior attempted treatments included topical steroids (4/10), oral steroids (2/10), ILS (8/10), anthralin (1/10), and tacrolimus ointment (1/10). Two patients were treatment naïve. One patient responded to a dose of 5 mg once daily. Four patients had their dose tapered up from 5 to 10 mg twice a day due to incomplete response, 1 of whom was bridged with 5 mg in the AM and 10 mg in the PM prior to the 10 mg twice a day dose step-up. Remaining 5 patients were on 10 mg twice a day from the start. Tofacitinib was tapered off for all after achieving full hair regrowth without any relapse.

Jerjen et al proved tolerability and clinical improvement with oral tofacitinib in preadolescents with AA.<sup>12</sup> Likewise, all of our 10 patients achieved full response with variable treatment duration. Our findings are also supported by a recent pediatric case series where 8 of 11 patients experienced hair regrowth on oral tofacitinib (5-10 mg twice a day) without any adverse events.<sup>13</sup> Similarly, none of our patients developed adverse events or laboratory abnormalities on follow-up testing. One case developed mild facial acne which subsided at the end of the treatment course. Patients with depression and

social anxiety reported improvement after tofacitinib therapy.

A case series found topical tofacitinib to be a reasonable adjunct (second-line) treatment for pediatric AA in whom systemic therapies are contraindicated.<sup>14</sup> This was supported by a case report of localized AA (eyelashes), whose authors concluded that while topical JAKis spare patients the side effects of systemic therapies, they are impractical and unlikely to achieve adequate hair regrowth in extensive AA.<sup>15</sup>

Our case series emphasizes the safety and efficacy of off-label oral tofacitinib in pediatric AA patients, regardless of age, presence of other autoimmune diseases, disease duration, subtype, or severity. The higher dose (10 mg twice a day) could explain the quick and full response achieved by all patients. Limitations include small sample size, retrospective nature, lack of the control group, and short follow-up period, which precludes long-term data extrapolation. As such, larger, randomized, controlled trials comparing tofacitinib to other JAKis (eg, baricitinib) are needed to fill the knowledge gap in pediatric literature. Our results are promising and pave the way for the determination of the safe and effective dose of oral tofacitinib for long-term pediatric AA management.

#### Conflicts of interest

None disclosed.

#### REFERENCES

- Pratt CH, King LE Jr, Messenger AG, Christiano AM, Sundberg JP. Alopecia areata. *Nat Rev Dis Primers*. 2017;3:17011. <https://doi.org/10.1038/nrdp.2017.11>
- Dressel D, Brütt CH, Manfras B, et al. Alopecia areata but not androgenetic alopecia is characterized by a restricted and oligoclonal T-cell receptor-repertoire among infiltrating lymphocytes. *J Cutan Pathol*. 1997;24(3):164-168. <https://doi.org/10.1111/j.1600-0560.1997.tb01571.x>
- Kyriakis KP, Paltatzidou K, Kosma E, Sofouri E, Tadros A, Rachioti E. Alopecia areata prevalence by gender and age. *J Eur Acad Dermatol Venereol*. 2009;23(5):572-573. <https://doi.org/10.1111/j.1468-3083.2008.02956.x>
- Vélez-Muñiz RDC, Peralta-Pedrero ML, Jurado-Santa Cruz F, Morales-Sánchez MA. Psychological profile and quality of life of patients with alopecia areata. *Skin Appendage Disord*. 2019;5(5):293-298. <https://doi.org/10.1159/000497166>
- Ibrahim O, Bayart CB, Hogan S, Piliang M, Bergfeld WF. Treatment of alopecia areata with tofacitinib. *JAMA Dermatol*. 2017;153(6):600-602. <https://doi.org/10.1001/jamadermatol.2017.0001>
- Ruperto N, Brunner HI, Synoverska O, et al. Tofacitinib in juvenile idiopathic arthritis: a double-blind, placebo-controlled, withdrawal phase 3 randomised trial. *Lancet*. 2021;398(10315):1984-1996. [https://doi.org/10.1016/S0140-6736\(21\)01255-1](https://doi.org/10.1016/S0140-6736(21)01255-1)
- King B, Ohyama M, Kwon O, et al, BRAVE-AA Investigators. Two phase 3 trials of baricitinib for alopecia areata. *N Engl J Med*. 2022;386(18):1687-1699. <https://doi.org/10.1056/NEJMoa2110343>
- United States Food and Drug Administration. FDA requires warnings about increased risk of serious heart-related events, cancer, blood clots, and death for JAK inhibitors that treat certain chronic inflammatory conditions. Accessed July 18, 2022. <https://www.fda.gov/drugs/drug-safety-and-availability/fda-requires-warnings-about-increased-risk-serious-heart-related-events-cancer-blood-clots-and-death>
- Hogan S, Wang S, Ibrahim O, Piliang M, Bergfeld W. Long-term treatment with tofacitinib in severe alopecia areata: an update. *J Clin Aesthet Dermatol*. 2019;12(6):12-14.
- Craiglow BG, King BA. Tofacitinib for the treatment of alopecia areata in preadolescent children. *J Am Acad Dermatol*. 2019;80(2):568-570. <https://doi.org/10.1016/j.jaad.2018.08.041>
- Huang KP, Mullangi S, Guo Y, Qureshi AA. Autoimmune, atopic, and mental health comorbid conditions associated with alopecia areata in the United States [published correction appears in *JAMA Dermatol*. 2014 Jun;150(6):674]. *JAMA Dermatol*. 2013;149(7):789-794. <https://doi.org/10.1001/jamadermatol.2013.3049>
- Jerjen R, Meah N, Trindade de Carvalho L, Wall D, Eisman S, Sinclair R. Treatment of alopecia areata in pre-adolescent children with oral tofacitinib: a retrospective study. *Pediatr Dermatol*. 2021;38(1):103-108. <https://doi.org/10.1111/pde.14422>
- Kibbie J, Kines K, Norris D, Dunnick CA. Oral tofacitinib for the treatment of alopecia areata in pediatric patients. *Pediatr Dermatol*. 2022;39(1):31-34. <https://doi.org/10.1111/pde.14855>
- Putterman E, Castelo-Soccio L. Topical 2% tofacitinib for children with alopecia areata, alopecia totalis, and alopecia universalis. *J Am Acad Dermatol*. 2018;78(6):1207-1209.e1. <https://doi.org/10.1016/j.jaad.2018.02.031>
- Craiglow BG. Topical tofacitinib solution for the treatment of alopecia areata affecting eyelashes. *JAAD Case Rep*. 2018;4(10):988-989. <https://doi.org/10.1016/j.jdc.2018.07.018>