

## The dilemma: scleroderma renal crisis vs lupus nephritis in a patient with mixed connective tissue disorder

Nicola Jackson, Shion Betty, James Appiah-Pippim, Yolín Bueno and Sana Makhdumi

Department of Internal Medicine, Piedmont Athens Regional Hospital, Athens, Georgia, USA

### ABSTRACT

#### Introduction

Mixed connective tissue disorder (MCTD) is a rare connective tissue disorder characterized by features of systemic lupus erythematosus, dermatomyositis, systemic sclerosis, and rheumatoid arthritis. MCTD is associated with an elevated antibody titer to U1 small nuclear ribonucleoprotein.

#### Case description:

A 49-year-old man presented to the emergency department for evaluation of worsening shortness of breath with associated bilateral hand pain and swelling associated with morning stiffness which was initially thought to be related to systemic lupus erythematosus (SLE). He was also found to have a positive autoantibody, and he was later diagnosed with MCTD complicated by scleroderma renal crisis.

#### Conclusion

MCTD is a rare connective tissue disorder with overlapping features of SLE, dermatomyositis, systemic sclerosis, and rheumatoid arthritis. The diagnosis of MCTD requires a high index of suspicion and careful workup. Immunosuppressive therapy is the mainstay of treatment that improves patient outcomes.

### ARTICLE HISTORY

Received 21 April 2021  
Accepted 17 September 2021

### KEYWORDS

Systemic lupus erythematosus; dermatomyositis; systemic sclerosis; Kasukawa diagnostic criteria; mixed connective tissue disorders

## 1. Introduction

Mixed connective tissue disorder (MCTD) is an autoimmune syndrome presenting with features of systemic lupus erythematosus (SLE), dermatomyositis, systemic sclerosis, and rheumatoid arthritis associated with elevated antibody titers to U1 small nuclear ribonucleoprotein. The incidence of MCTD is 1.9 per 100,000, and is higher in females. One of the life-threatening complications of MCTD is

Scleroderma renal crisis (SRC). SRC is characterized by acute onset of renal failure, usually in the setting of moderate to severe hypertension. SRC in patients with MCTD is rare, with only a few cases documented worldwide. We herein discuss a case of a 49-year-old man with MCTD complicated by SRC.

## 2. Case description

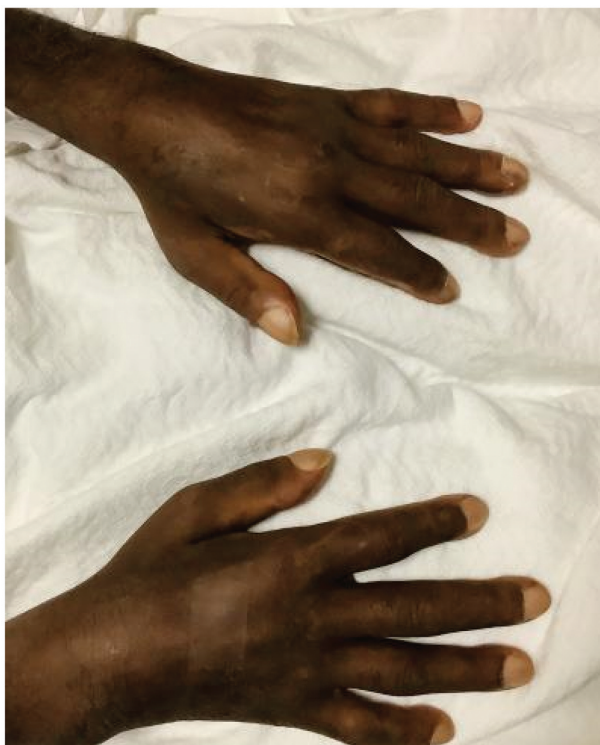A 49-year-old man presented to the emergency department for evaluation of worsening shortness of breath. Seven weeks before the presentation he was seen by a rheumatologist for bilateral hand pain and swelling associated with morning stiffness thought to be related to systemic lupus erythematosus (SLE).

Medical history is significant for SLE, Raynaud's phenomenon, and erectile dysfunction diagnosed 1 year ago. Medications include prednisone, pantoprazole, and methotrexate.

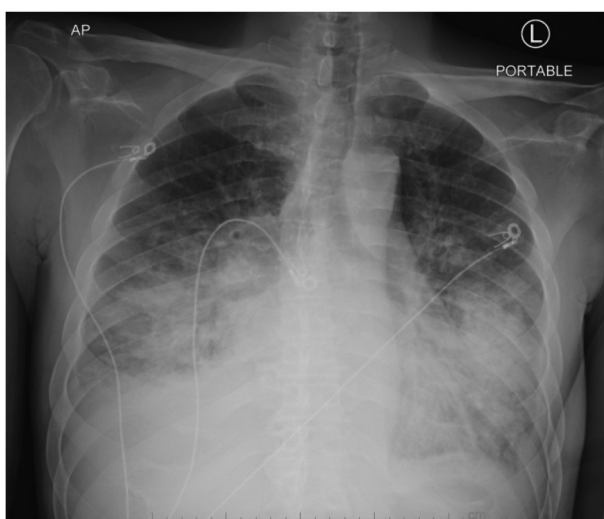
External records revealed positive ANA-titer >1:1280, positive Anti-Smith, Scl-70, and RNP antibodies. However, his DS DNA, SSA/SSB, anticentromere, anti-histone, anti-CCP, and RF were all negative. CT of the chest, abdomen, and pelvis were unremarkable 1 year ago. An echocardiogram at that

time showed EF of 55–60% with normal diastolic function. Of note 3 weeks before presentation, his creatinine and GFR were within normal limits.

In the emergency department, blood pressure was 166/119 mmHg, heart rate 130. He was breathing at 23 breaths per minute and saturating at 86% on room air. Physical examination was remarkable for moderate respiratory distress, with bibasilar crackles in the lungs and 1+ bilateral pedal edema. Motor strength 4/5 in all his extremities. Hands examination revealed clubbing, see [Figure 1](#).



**Figure 1.** Bilateral soft tissue swelling of the hands with loss of skin crease and clubbing of the fingers.



**Figure 2.** Chest X-ray above shows central vascular prominence with abnormal alveolar opacities in the mid and lower lungs bilaterally in addition to small effusions.

Laboratory analysis revealed hemoglobin 9.0, sodium 132, creatinine 3.96, GFR 20, BNP 4172. ABG: pH: 7.52, pCO<sub>2</sub>: 29.4, pO<sub>2</sub>: 58 HCO<sub>3</sub>: 23.8. Urinalysis showed 6 RBC. Chest X-ray demonstrated bilateral opacities, see [Figure 2](#).

He was admitted to the ICU for closer monitoring of his acute hypoxemic respiratory failure. Further workup in the hospital revealed elevated dsDNA, with normal C3/C4 complements and cryoglobulin. HIV and ANCA tests were negative.

Echocardiogram showed LVEF is 25% with grade III diastolic dysfunction, moderate mitral regurgitation, and severe pulmonary hypertension with RA pressure 8 mmHg and RVSP (TR) 71.0 mmHg.

CT scan of the chest revealed bilateral ground-glass opacities as shown below in [Figure 3](#).

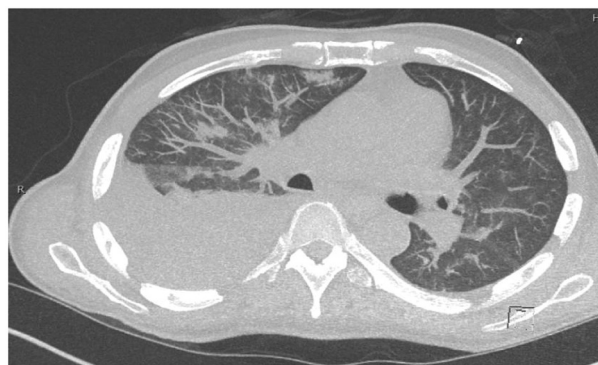Given his clinical picture with worsening renal failure, a diagnosis of lupus nephritis vs scleroderma renal crisis was considered. Nephrology and rheumatology teams were consulted, and a kidney biopsy was obtained. Also, RNA polymerase 3 antibodies were ordered at this time.

### 3. Discussion

Mixed connective tissue disorder (MCTD) also known as Sharp's syndrome was initially defined in 1972 [1]. MCTD presents with overlapping features of systemic lupus erythematosus, dermatomyositis, systemic sclerosis, and rheumatoid arthritis associated with elevated antibody titers to U1 small nuclear ribonucleoprotein [2–4]. The incidence of MCTD is 1.9 per 100,000 with higher incidence in females [5].

Currently, there are four diagnostic criteria used to diagnosed MCTD. Kasukawa diagnostic criteria were utilized for this patient, and it is currently one of the most widely used criteria [6].

[Table 1](#) Outlining the Kasukawa diagnostic criteria is shown above [6]. Based on the Kasukawa diagnostic criteria, a patient would be diagnosed with MCTD if they have  $\geq 1$  common symptom, positive anti-RNP antibodies, and  $\geq 1$  finding from each of  $\geq 2$  disease



**Figure 3.** High-resolution CT chest above showing diffuse ground-glass opacity in the lungs and bilateral pleural effusion.

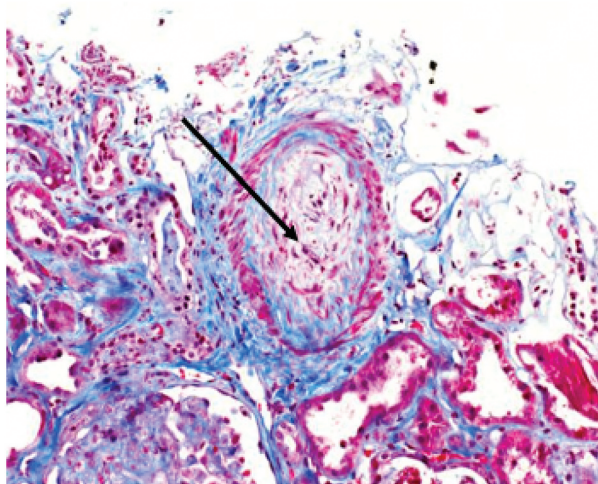
**Table 1.** Outlines the Kasukawa diagnostic criteria.

Common symptoms	1. Raynaud phenomenon 2. Swollen fingers or hands
Antibodies to U1 RNP	1. Positive
Mixed findings	1. Systemic lupus erythematosus like findings <ul style="list-style-type: none"> <li>● Polyarthritits</li> <li>● Lymphadenopathy</li> <li>● Facial erythema</li> <li>● Pericarditis or pleuritis</li> <li>● Leukopenia or thrombocytopenia</li> </ul> 2. Systemic sclerosis-like findings: <ul style="list-style-type: none"> <li>● Sclerodactyly</li> <li>● Pulmonary fibrosis, restrictive pattern on pulmonary function tests, or reduced DLCO</li> <li>● Hypomotility or esophageal dilation</li> </ul> 3. Polymyositis-like symptoms: <ul style="list-style-type: none"> <li>● Muscle weakness</li> <li>● Raised serum creatine kinase levels</li> <li>● Myogenic pattern on electromyography</li> </ul>

categories (systemic lupus erythematosus, systemic sclerosis, or polymyositis)[6].

Our patient fulfilled both common symptoms including Raynaud phenomenon and swollen hands; he also had positive antibodies to U1 RNP; and mixed findings of polyarthritits, sclerodactyly, and muscle weakness. On day 5 of admission, he was started on hemodialysis. A broad differential diagnosis for acute kidney injury was entertained. These included membranous/mesangial glomerulonephritis, scleroderma renal crisis, immune complex-mediated nephritis, and interstitial nephropathy. However, in the end his renal biopsy with findings of thrombotic microangiopathy was suggestive of scleroderma renal crisis, see Figures 4 [7]. Additionally, the patient had positive titers for RNA polymerase III was 28 (high).

Renal complications occur in approximately 25% of patients with MCTD[8]. The pathogenesis of scleroderma renal crisis (SRC) is not well understood[9]. It is thought



**Figure 4.** Reveals an occluded arteriole.

to be related damage to the endothelial of the renal vasculature, along with activation of the renin-angiotensin-aldosterone system[9]. While lupus nephritis is the result of a type-III hypersensitivity reaction[10]. Both lupus nephritis and SRC can present with proteinuria and hematuria [9,10]. However, lupus nephritis can also present with polyuria, nocturia, and foamy urine[10]. On the other hand, SRC presents with moderate to severe hypertension associated with oligo-anuric acute renal failure[9].

Our patient was initially being treated with high doses of prednisone which was later tapered. He was started on captopril. Unfortunately, he remained on dialysis with no signs of renal recovery 1 year later. SRC in patients with mixed connective tissue disorder is rare with a few cases documented worldwide with some patients becoming dialysis-dependent[11,12]. Precipitating factors for SRC include cardiac events, new-onset anemia, and high-medium dose of steroids [12,13]. This patient presented to the ED with acute decompensated heart failure and chronic use of prednisone of 20 mg daily, both of which could have been precipitating factors. The management of lupus nephritis differs from the management of SRC. SRC is managed with angiotensin-converting enzyme inhibitors (ACEIs) since activation of the renin-angiotensin-aldosterone system is a critical component of the pathogenesis of the disease[9]. Steroids are avoided in SRC due to increase the likelihood of worse outcomes [14]. In contrast, the management of lupus nephritis includes immunosuppressive therapy and steroids depending on the stage of the disease[10].

## Disclosure statement

No potential conflict of interest was reported by the author (s).

## References

- [1] Sharp GC, Irvin WS, Tan EM, et al. Mixed connective tissue disease—an apparently distinct rheumatic disease syndrome associated with a specific antibody to an extractable nuclear antigen (ENA). *Am J Med.* 1972Feb;52(2):148–159. PMID: 4621694.
- [2] Bennett RM. Overlap syndromes. In: *Textbook of rheumatology*. 8th ed. Philadelphia: WB Saunders Co; 2009. p. 1381.
- [3] Gunnarsson R, Hetlevik SO, Lilleby V, et al. Mixed connective tissue disease. *Best Pract Res Clin Rheumatol.* 2016Feb;30(1):95–111. Epub 2016 Apr 12. PMID: 27421219.
- [4] Sapkota B, Al Khalili Y. Mixed connective tissue disease. [Updated 2021 Jan 3]. In: *StatPearls* [Internet]. Treasure Island (FL): StatPearls Publishing; 2021 Jan. Available from: <https://www.ncbi.nlm.nih.gov/books/NBK542198/>
- [5] Ungrasert P, Crowson CS, Chowdhary VR, et al., *Epidemiology of Mixed Connective Tissue Disease,*

- 1985-2014: A Population-Based Study. *Arthritis Care Res (Hoboken)*. 2016;68(12):1843–1848.
- [6] Rutkowska-Sak L, Gietka P. Clinical features and outcome of mixed connective tissue disease in developmental age - observational study from one center. *Reumatologia*. 2019;57(6):315–319. Epub 2019 Dec 31. PMID: 32226164; PMCID: PMC7091480.
- [7] Batal I, Domsic RT, Shafer A, et al. Renal biopsy findings predicting outcome in scleroderma renal crisis. *Hum Pathol*. 2009Mar;40(3):332–340. Epub 2008 Oct 29. PMID: 18973923.
- [8] Kitridou RC, Akmal M, and Turkel SB, et al. Renal involvement in mixed connective tissue disease: a longitudinal clinicopathologic study. *Semin Arthritis Rheum*. 1986Nov;16(2):135–145 doi:. PMID: 3563525.
- [9] Vaidya PN, Basyal B, Finnigan NA. Scleroderma and renal crisis. [Updated 2020 Jul 11]. In: StatPearls [Internet]. Treasure Island (FL): StatPearls Publishing; 2021 Jan. Available from: <https://www.ncbi.nlm.nih.gov/books/NBK482424/>
- [10] Musa R, Brent LH, Qurie A. Lupus Nephritis. [Updated 2020 Aug 15]. In: StatPearls [Internet]. Treasure Island (FL): StatPearls Publishing; 2021 Jan. Available from: <https://www.ncbi.nlm.nih.gov/books/NBK499817/>
- [11] Vij M, Agrawal V, Jain M. Scleroderma renal crisis in a case of mixed connective tissue disease. *Saudi J Kidney Dis Transpl*. 2014 Jul;25(4):844–8.
- [12] Cheta J, Rijhwani S, Rust H. Scleroderma renal crisis in mixed connective tissue disease with full renal recovery within 3 months: a case report with expanding treatment modalities to treat each clinical sign as an independent entity. *J Investig Med High Impact Case Rep*. 2017;5(4):2324709617734012. Published 2017 Oct 10.
- [13] Lynch BM, Stern EP, Ong V, et al. UK Scleroderma Study Group (UKSSG) guidelines on the diagnosis and management of scleroderma renal crisis. *Clin Exp Rheumatol*. 2016 Sep-Oct;34 Suppl 100(5):106–109. Epub 2016 Sep 29. PMID: 27749244.
- [14] Trang G, Steele R, Baron M, et al. Corticosteroids and the risk of scleroderma renal crisis: a systematic review. *Rheumatol Int*. 2012Mar;32(3):645–653. Epub 2010 Dec 4. PMID: 21132302.