

Temporal Evolution of Myocardial Hemorrhage and Edema in Patients After Acute ST-Segment Elevation Myocardial Infarction: Pathophysiological Insights and Clinical Implications

David Carrick, MRCP; Caroline Haig, PhD; Nadeem Ahmed, MBChB; Samuli Rauhalammi, MSc; Guillaume Clerfond, MD; Jaclyn Carberry, BMedSci; Ify Mordi, MRCP; Margaret McEntegart, MRCP; Mark C. Petrie, MRCP; Hany Eteiba, FRCP; Stuart Hood, FRCP; Stuart Watkins, FRCP; M. Mitchell Lindsay, FRCP; Ahmed Mahrous, PhD; Paul Welsh, PhD; Naveed Sattar, PhD; Ian Ford, PhD; Keith G. Oldroyd, FRCP; Aleksandra Radjenovic, PhD; Colin Berry, FRCP

Background—The time course and relationships of myocardial hemorrhage and edema in patients after acute ST-segment elevation myocardial infarction (STEMI) are uncertain.

Methods and Results—Patients with ST-segment elevation myocardial infarction treated by primary percutaneous coronary intervention underwent cardiac magnetic resonance imaging on 4 occasions: at 4 to 12 hours, 3 days, 10 days, and 7 months after reperfusion. Myocardial edema (native T2) and hemorrhage (T2*) were measured in regions of interest in remote and injured myocardium. Myocardial hemorrhage was taken to represent a hypointense infarct core with a T2* value <20 ms. Thirty patients with ST-segment elevation myocardial infarction (mean age 54 years; 25 [83%] male) gave informed consent. Myocardial hemorrhage occurred in 7 (23%), 13 (43%), 11 (33%), and 4 (13%) patients at 4 to 12 hours, 3 days, 10 days, and 7 months, respectively, consistent with a unimodal pattern. The corresponding median amounts of myocardial hemorrhage (percentage of left ventricular mass) during the first 10 days after myocardial infarction were 2.7% (interquartile range [IQR] 0.0–5.6%), 7.0% (IQR 4.9–7.5%), and 4.1% (IQR 2.6–5.5%; $P<0.001$). Similar unimodal temporal patterns were observed for myocardial edema (percentage of left ventricular mass) in all patients ($P=0.001$) and for infarct zone edema (T2, in ms: 62.1 [SD 2.9], 64.4 [SD 4.9], 65.9 [SD 5.3]; $P<0.001$) in patients without myocardial hemorrhage. Alternatively, in patients with myocardial hemorrhage, infarct zone edema was reduced at day 3 (T2, in ms: 51.8 [SD 4.6]; $P<0.001$), depicting a bimodal pattern. Left ventricular end-diastolic volume increased from baseline to 7 months in patients with myocardial hemorrhage ($P=0.001$) but not in patients without hemorrhage ($P=0.377$).

Conclusions—The temporal evolutions of myocardial hemorrhage and edema are unimodal, whereas infarct zone edema (T2 value) has a bimodal pattern. Myocardial hemorrhage is prognostically important and represents a target for therapeutic interventions that are designed to preserve vascular integrity following coronary reperfusion.

Clinical Trial Registration—URL: <https://clinicaltrials.gov/>. Unique identifier: NCT02072850. (*J Am Heart Assoc.* 2016;5:e002834 doi: 10.1161/JAHA.115.002834)

Key Words: magnetic resonance imaging • myocardial edema • myocardial hemorrhage • myocardial infarction • pathophysiology • reperfusion injury

In acute ST-segment elevation myocardial infarction (STEMI), myocardial hemorrhage is a complication that is associated with the duration of ischemia and reperfusion^{1–4} and that is an adverse prognostic factor in the longer term.^{5–8} Myocardial

hemorrhage is potentially a therapeutic target for novel interventions; however, the temporal evolution of myocardial hemorrhage and its association with other myocardial infarction (MI) pathologies early after MI are incompletely understood.

From the BHF Glasgow Cardiovascular Research Centre, Institute of Cardiovascular and Medical Sciences (D.C., N.A., S.R., G.C., J.C., I.M., M.C.P., P.W., N.S., K.G.O., A.R., C.B.) and Robertson Center for Biostatistics (C.H., I.F.), University of Glasgow, UK; West of Scotland Heart and Lung Center, Golden Jubilee National Hospital, Glasgow, UK (D.C., M.M., M.C.P., H.E., S.H., S.W., M.M.L., A.M., K.G.O., C.B.).

Accompanying Data S1, S2, Tables S1 through S4 and Figures S1 through S6 are available at <http://jaha.ahajournals.org/content/5/2/e002834/suppl/DC1>

Correspondence to: Colin Berry, FRCP, BHF Glasgow Cardiovascular Research Center, Institute of Cardiovascular and Medical Sciences, 126 University Place, University of Glasgow, Glasgow G12 8TA, UK. E-mail: colin.berry@glasgow.ac.uk

Received December 10, 2015; accepted January 8, 2016.

© 2016 The Authors. Published on behalf of the American Heart Association, Inc., by Wiley Blackwell. This is an open access article under the terms of the Creative Commons Attribution-NonCommercial License, which permits use, distribution and reproduction in any medium, provided the original work is properly cited and is not used for commercial purposes.

Myocardial edema is a consequence of ischemia and infarction and has functional importance because edema impairs myocyte contractility.⁹ The extent of myocardial edema revealed by T2-weighted cardiac magnetic resonance (CMR) imaging correlates with the transmural extent of infarction.^{10,11} For myocardial edema to be taken as a retrospective marker of the area at risk,^{12,13} its initial size should be stable. Dall'Armelfina et al¹⁴ reported that the extent of edema was maximal within the first 5 to 7 days after MI but then decreased in size subsequently. Recently, Fernández-Jiménez et al^{15,16} assessed myocardial edema in a swine model of MI (with or without reperfusion) at 2 hours, 24 hours, 4 days, or 7 days (n=5 per group) using CMR and quantification of myocardial water content by postmortem tissue desiccation. They observed bimodal peaks in transverse relaxation times (T2, in ms) reflecting myocardial water content at 2 hours and 7 days after reperfusion and an intervening decrease in myocardial water content at 24 hours. They concluded that myocardial edema was not stable and that the bimodal accumulation of edema was attributed to reperfusion initially and then to inflammatory cell infiltration.¹⁶

Tissue hemorrhage is typically characterized by an acute primary phase¹⁶ and then potentially by secondary hemorrhagic transformation in the subacute phase hours or days later.^{17,18} Deoxyhemoglobin has paramagnetic effects that enable myocardial hemorrhage to be detected using T2- and T2*-weighted CMR (T2* relaxation refers to the decay of transverse magnetization seen with gradient-echo sequences).^{19,20} Because myocardial hemorrhage is very common in swine after 40 minutes of ischemia,²⁰ the observations by Fernández-Jiménez et al¹⁵ could be explained by myocardial hemorrhage; however, the time course and relationships between myocardial edema and hemorrhage early after MI in patients after STEMI are uncertain.

We hypothesized (1) that myocardial hemorrhage evolves progressively after acute STEMI, with incident hemorrhage occurring in some patients immediately after reperfusion, followed by a secondary phase of progressive hemorrhage; (2) that T2 and T2* relaxation times (in ms) within the infarct zone exhibit similar temporal changes when measured at serial time points after MI; and (3) that temporal changes in edema, reflected by the T2 relaxation time (in ms), and its bimodal pattern are inversely associated with the amount of hemorrhage. Our study was designed to provide novel and clinically relevant insights into the temporal evolution of myocardial hemorrhage and edema immediately after reperfusion and in the longer term after MI.

Methods

Study Population and STEMI Management

To examine these hypotheses, we performed a comprehensive longitudinal CMR study of myocardial hemorrhage and

edema in a cohort of reperfused patients after STEMI treated by emergency percutaneous coronary intervention in a single regional cardiac center between November 3, 2011, and September 18, 2012. Thirty STEMI patients provided written informed consent. The study was approved by the institutional review board of West of Scotland Research Ethics Committee (National Research Ethics Service reference 10-S0703-28).

Acute STEMI management followed contemporary guidelines^{21,22} (Data S1). The study was publically registered (ClinicalTrials.gov identifier NCT02072850).

CMR Acquisition

CMR was performed on 4 occasions (4–12 hours and ≈3 days, 10 days, and 7 months) after reperfusion using a Siemens Magnetom Avanto 1.5T scanner with a 12-element phased array cardiac surface coil.^{23,24} The imaging protocol^{25,26} included cine CMR with steady-state free precession for imaging cardiac anatomy and left ventricular mass and function, T2* mapping for specifically imaging myocardial hemorrhage based on dephasing of T2* relaxation times, T2 mapping^{27,28} for imaging myocardial edema based on tissue water content and mobility, and contrast-enhanced phase-sensitive inversion-recovery pulse sequences²⁹ for imaging infarct scar and microvascular obstruction. CMR acquisition is described in detail in Data S1.

CMR Analyses

The images were analyzed on a Siemens workstation by observers with at least 3 years of CMR experience (N.A., D.C., I.M., S.R., G.C.) (Data S1).

Quantitative assessments of myocardial edema (T2) and myocardial hemorrhage (T2): standardized measurements in myocardial regions of interest*

Left ventricular contours were delineated with computer-assisted planimetry on the raw T2* image and the last corresponding T2 raw image, with echo time of 55 ms^{30,31} (Data S1). T2 values from an age-matched healthy population were taken to represent baseline values (Data S1).

Myocardial hemorrhage

Myocardial hemorrhage was scored visually using T2* CMR maps. Myocardial hemorrhage was visually defined as a hypointense area in the center (ie, core) of the edematous zone with a mean T2* value of at least 2 SD below the T2* value at the periphery of the edematous zone and, on average, measuring <20 ms, with a minimum area of 1% left ventricular mass.^{32–35} Myocardial hemorrhage was described as percentage of left ventricular mass.

Infarct definition and size

The myocardial mass of late gadolinium (in g) was quantified using computer-assisted planimetry (Data S1).^{23,36}

Myocardial edema

The territory of myocardial edema was defined as left ventricular myocardium with pixel values (T2) >2 SD from remote myocardium.^{13,14,37–40}

Myocardial salvage

Myocardial salvage was calculated by subtraction of percentage of infarct size from percentage of area at risk.^{13,40} The myocardial salvage index was calculated by dividing the myocardial salvage area by the initial area at risk.

Adverse remodeling

Adverse remodeling was defined as an increase in left ventricular end-diastolic volume $\geq 20\%$ at 7 months from baseline.⁴¹

Electrocardiogram

A 12-lead electrocardiogram was obtained before coronary reperfusion and 60 minutes afterward (Data S1).

Biochemical Assessment of Infarct Size

Troponin T was measured (Elecsys Troponin T; Roche) as a biochemical measure of infarct size. The highly sensitive assay reaches a level of detection of 5 pg/mL and achieves <10% variation at 14 pg/mL, corresponding to the 99th percentile of a reference population. A blood sample was routinely obtained 12 to 24 hours after hospital admission, typically between 7 and 9 AM.

Statistical Analyses

Differences between independent groups were assessed using *t* tests, Mann–Whitney tests, or Fisher exact tests, as appropriate. Changes over time were assessed using generalized linear mixed-effects models with time and hemorrhage as fixed effects and participant identifier as the only random effect. These models were fitted as full factorial models, with the interaction being removed only when not significant. Post hoc multiple comparisons were performed with Tukey adjustment. Random-effects models were used to compute inter- and intrarater reliability measures (intraclass correlation coefficient) for the reliability of remote zone, infarct zone, and infarct core edema (T2) and myocardial hemorrhage (T2*) values measured independently by 2 observers in 20 patients selected randomly from the cohort. All statistical analyses

were carried out using R version 2.15.1 (R Foundation for Statistical Computing) or SAS version 9.3 (SAS Institute) or later versions of these programs. $P > 0.05$ indicated the absence of evidence for a statistically significant effect.

Results

Thirty STEMI patients (mean age 54 years, 83% male) (Table 1) treated by primary percutaneous coronary intervention gave informed consent and underwent serial CMR at 1.5 T on 4 occasions (Figure 1). The CMR examinations were performed (mean \pm SD) 8.6 \pm 3.1 hours, 2.9 \pm 1.5 days, 9.6 \pm 2.3 days, and 213 \pm 27 days following primary percutaneous coronary intervention (Table 2). Evaluable myocardial edema (T2) and hemorrhage (T2*) data were available in 117 (98%) and 102 (85%) CMR scans, respectively. Information on vital status was available in all of the participants. The mean myocardial T2 value obtained from 50 healthy volunteers (mean age 54 years [SD 13 years], 26 [52%] male) was 49.5 ms (SD 2.5 ms).

The size of infarction as revealed by the troponin concentration was greater in patients with myocardial hemorrhage compared with patients without myocardial hemorrhage (Table 1).

Temporal Evolution of Myocardial Hemorrhage Following Ischemia–Reperfusion

Thirteen (43%) patients developed myocardial hemorrhage by day 3. Overall, myocardial hemorrhage occurred in 7 (23%), 13 (43%), 11 (33%), and 4 (13%) patients at 4 to 12 hours, 3 days, 10 days and 7 months, respectively (Table 2). Clinical case examples are shown in Figure 2. In patients with myocardial hemorrhage, the amount of hemorrhage (percentage of left ventricular mass) increased progressively from 4 to 12 hours to a peak at 3 days ($P = 0.0041$) and then decreased progressively at 10 days and 7 months ($P < 0.05$) (Table 2 and Figure 3). The opposite pattern was seen with myocardial hemorrhage (T2* core values) with a nadir at day 3 versus 4 to 12 hours ($P < 0.001$) and an increase between day 10 and 7 months ($P = 0.055$) (Table 3).

Temporal Evolution of Myocardial Edema

The extent of myocardial edema (percentage of left ventricular mass) increased from the initial CMR scan 4 to 12 hours after MI to a maximum 3 days after MI and then reduced at 10 days and 7 months after MI (Table 2). The extent of edema (percentage of left ventricular mass) was associated with time from reperfusion (Table 2; Figure S1). Specifically, edema was less at day 10 versus day 3 in patients with or without myocardial hemorrhage ($P < 0.001$ for interaction). In

Table 1. Clinical and Angiographic Characteristics of the 30 Patients in the Longitudinal Clinical Study

Characteristics*	All Patients n=30	No Myocardial Hemorrhage (T2* Core Negative) n=17 (57%)	Myocardial Hemorrhage (T2* Core Positive) n=13 (43%)	P Value
Clinical				
Age, y	54 (10)	55 (9)	53 (11)	0.602
Male sex, n (%)	25 (83)	15 (88)	10 (77)	0.628
BMI, kg/m ²	28 (5)	29 (4)	27 (5)	0.257
History				
Hypertension, n (%)	8 (27)	5 (29)	3 (23)	1.000
Current smoking, n (%)	21 (70)	11 (65)	10 (77)	0.691
Hypercholesterolemia, n (%)	13 (43)	7 (41)	6 (46)	1.000
Diabetes mellitus [†] , n (%)	2 (7)	1 (6)	1 (8)	1.000
Previous angina, n (%)	3 (10)	1 (6)	2 (15)	0.565
Previous myocardial infarction, n (%)	1 (3)	1 (6)	0 (0)	1.000
Previous PCI, n (%)	1 (3)	1 (6)	0 (0)	—
Presenting characteristics				
Heart rate, bpm	77 (17)	75 (19)	81 (14)	0.340
Systolic blood pressure, mm Hg	141 (26)	139 (33)	143 (16)	0.712
Diastolic blood pressure, mm Hg	84 (12)	83 (13)	86 (11)	0.472
Time from symptom onset to reperfusion, min, median (IQR)	156 (112–243)	161 (118–206)	137 (112–274)	0.837
Ventricular fibrillation [‡] , n (%)	1 (3)	1 (6)	0 (0)	1.000
Heart failure, Killip class at presentation, n (%)				
I	22 (74)	13 (76)	9 (69)	0.811
II	7 (23)	4 (24)	3 (23)	
III/IV	1 (3)	0 (0)	1 (8)	
Electrocardiogram				
ST-segment elevation resolution after PCI, n (%)				
Complete, ≥70%	15 (50)	1 (6)	1 (8)	1.000
Partial, 30% to <70%	13 (43)	7 (41)	6 (46)	
None, ≤30%	2 (7)	9 (53)	6 (46)	
Number of diseased arteries[§], n (%)				
1	14 (47)	10 (58)	4 (31)	0.298
2	11 (37)	5 (29)	6 (46)	
3	5 (17)	2 (12)	3 (23)	
Culprit artery, n (%)				
LM	0 (0)	0 (0)	0 (0)	0.112
LAD	9 (30)	4 (24)	5 (38)	
LCX	10 (33)	4 (24)	6 (46)	
RCA	11 (37)	9 (53)	2 (15)	
TIMI coronary flow grade before PCI, n (%)				
0/1	24 (80)	12 (71)	12 (92)	0.196
2/3	6 (20)	5 (29)	1 (8)	

Continued

Table 1. Continued

Characteristics*	All Patients n=30	No Myocardial Hemorrhage (T2* Core Negative) n=17 (57%)	Myocardial Hemorrhage (T2* Core Positive) n=13 (43%)	P Value
TIMI coronary flow grade after PCI, n (%)				
0/1	0 (0)	0 (0)	0 (0)	1.000
2	2 (7)	1 (6)	1 (8)	
3	28 (93)	16 (94)	12 (92)	
Medical therapy				
ACEI or ARB	30 (100)	17 (100)	13 (100)	—
Beta blocker	30 (100)	17 (100)	13 (100)	—
Initial blood results on admission				
Neutrophil count, $\times 10^9$ L	10.1 (3.1)	9.3 (3.0)	11.3 (3.0)	0.083
NT-proBNP, pg/mL, median (IQR)	588 (306–1541)	529 (301–1254)	864 (655–1637)	0.841
Troponin T, ng/L, median (IQR)	3136 (1710–6608)	1804 (1126–3427)	6598 (5244–11 190)	0.001

ACEI indicates angiotensin-converting enzyme inhibitor; ARB, angiotensin receptor blocker; BMI, body mass index; bpm, beats per minute; IQR, interquartile range; LAD, left anterior descending; LCX, left circumflex; LM, left main; NT-proBNP indicates N-terminal pro-brain natriuretic peptide; PCI, percutaneous coronary intervention; RCA, right coronary artery; TIMI, Thrombolysis in Myocardial Infarction.

*Data are reported as mean (SD), median (IQR), or N (%) as appropriate.

†Diabetes mellitus was defined as a history of diet-controlled or treated diabetes.

‡Successfully electrically cardioverted ventricular fibrillation at presentation or during emergency PCI procedure.

§Multivessel coronary artery disease was defined according to the number of stenoses of at least 50% of the reference vessel diameter, by visual assessment and whether or not there was left main stem involvement.

addition, the end-diastolic wall thickness measured in the infarct zone decreased over time ($P<0.001$) (Table S1).

Temporal Evolution of Infarct Size, Myocardial Salvage in Relation to Hemorrhage Status

Infarct size reduced with time from MI onset, and although the absolute reduction in infarct size was greater in patients with hemorrhage compared with patients without hemorrhage (Table 2), the relative reduction was similar. Myocardial salvage was associated with the timing of the CMR, and the amount of salvageable myocardium was less in the patients with hemorrhage than in patients without hemorrhage (Table 2).

Temporal Evolution of Myocardial Edema and Myocardial Hemorrhage

With regard to infarct zone edema (T2 values), when study participants were grouped according to the presence or absence of myocardial hemorrhage, a bimodal pattern was observed. In patients with myocardial hemorrhage, a bimodal time course in edema (T2 values) was observed within the edematous zone ($P<0.001$ for interaction) and the infarct core ($P=0.0083$ for interaction) (Table 3, Figure 3). In contrast, this pattern differed in patients without myocardial hemorrhage in whom T2 values increased progressively up to 10 days after

MI ($P=0.042$). By 7 months, edema (T2) had reduced in both groups; however, in patients with myocardial hemorrhage, edema (T2) remained higher in the infarct zone compared with T2 values in the remote zone ($P=0.001$) and those of healthy volunteers ($P<0.001$). They also tended to be higher than edema (T2 values) in the infarct zone of patients without hemorrhage ($P=0.059$) (Table 3). These observations imply that the temporal changes in edema and hemorrhage are correlated.

T2 in the myocardial remote zone increased over time in patients both with and without myocardial hemorrhage ($P<0.001$ for interaction) but to a greater extent in patients with hemorrhage (Table 2).

Intra- and interobserver agreement of T2 and T2* measurements

Myocardial edema (T2 values) and myocardial hemorrhage (T2* values) in regions of interest in remote zones, injured zones, and infarct core in a subgroup of 20 randomly chosen patients were measured independently by 2 observers (Figures S1–S6). The intraclass correlation coefficients for reliability of infarct zone T2*, infarct core T2*, infarct zone T2, and infarct core T2 were 0.75 (95% CI 0.47–0.89), 0.90 (95% CI 0.77–0.96), 0.89 (95% CI 0.74–0.95), and 0.86 (95% CI 0.68–0.94; all $P<0.001$), respectively. Bland-Altman plots showed no evidence of bias (Figures S1–S6).

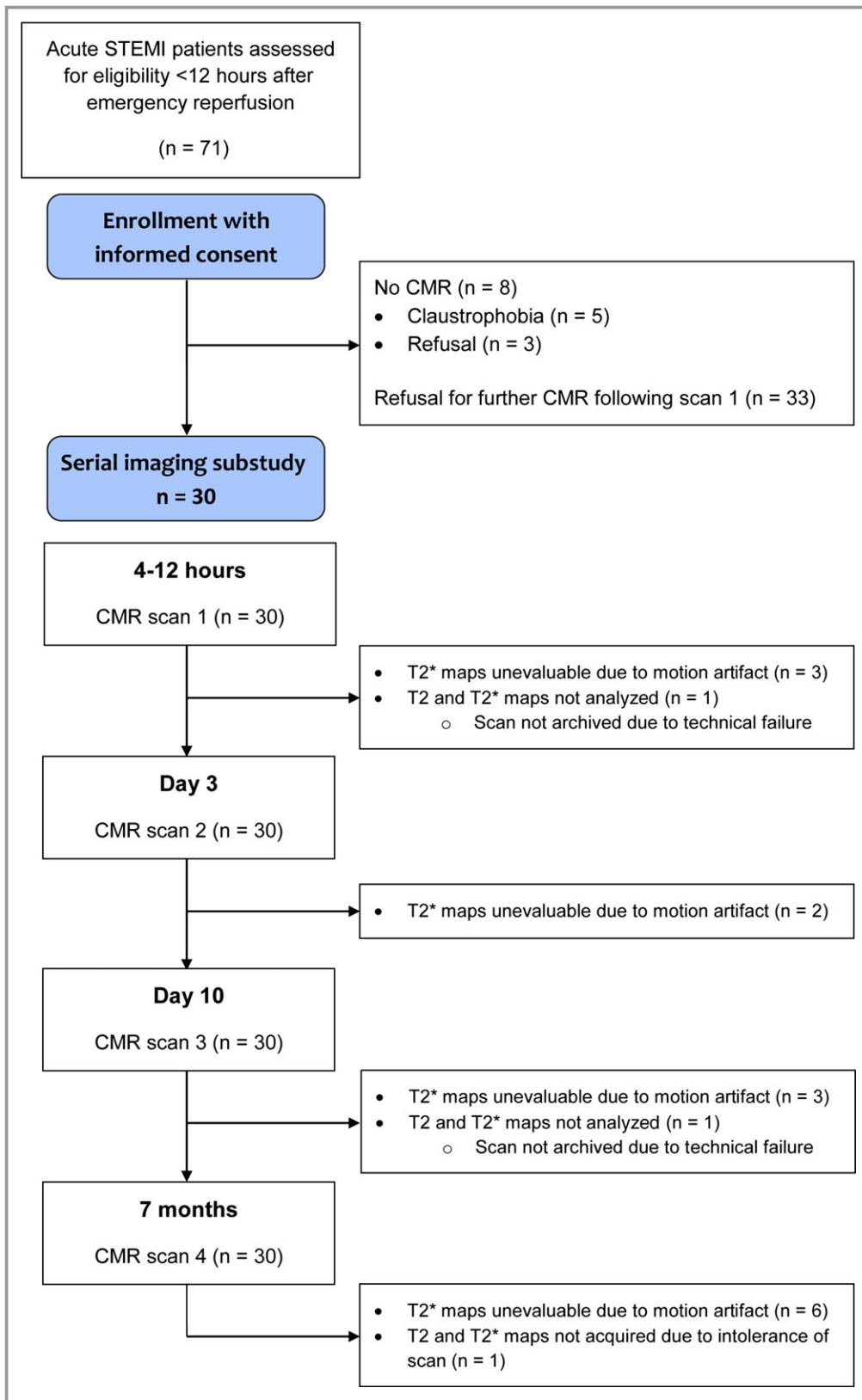


Figure 1. Study flow diagram. CMR indicates cardiac magnetic resonance; STEMI, ST-segment elevation myocardial infarction.

Table 2. Comparison of CMR Findings in Patients With Versus Without Myocardial Hemorrhage (Day 3)

Myocardial Hemorrhage	4 to 12 Hours		3 Days		10 Days		7 Months		P Value*		
	Yes	No	Yes	No	Yes	No	Yes	No	All	Yes	No
LV ejection fraction, %	50 (7)	54 (10)	52 (8)	58 (8)	56 (9)	61 (7)	55 (8)	62 (7)	<0.001	<0.001	<0.001
LV end-diastolic volume, mL	160 (36)	160 (31)	163 (33)	161 (30)	169 (35)	160 (31)	176 (35)	154 (31)	0.698	0.001	0.377
Myocardial edema, % LV mass	39 (9)	31 (9)	44 (8)	35 (13)	36 (9)	28 (13)	—	—	<0.001	<0.001	0.029
Infarct size, % LV mass	29 (13)	12 (8)	30 (12)	12 (7)	22 (9)	9 (5)	22 (9)	8 (4)	<0.001	<0.001	<0.001
Myocardial salvage, % LV mass, median (IQR)	5 (5, 15)	16 (11, 28)	11 (8, 20)	22 (14, 27)	13 (8, 16)	17 (12, 25)	23 (16, 27)	25 (16, 34)	<0.001	<0.001	0.003
Microvascular obstruction, n (%)	13 (100)	5 (29)	13 (100)	4 (24)	9 (69)	1 (6)	0 (0)	0 (0)			
T2 map hypointense core, n (%)	7 (54)	12 (71)	13 (100)	5 (29)	10 (77)	4 (24)	1 (8)	0			
Myocardial hemorrhage, n (%)	7 (54)	0 (0)	13 (100)	0 (0)	11 (85)	0 (0)	4 (31)	0 (0)			
Myocardial hemorrhage, % LV mass, median (IQR)	2.7 (0.0–5.6)	0	7.0 (4.9–7.5)	0	4.1 (2.6– 5.5)	0	0 (0– 0)	—	—	<0.001	—

CMR scans were obtained <12 hours, 3 days, 10 days, and 7 months after reperfusion. The *P* values for the interaction for the effects of time and hemorrhage in linear mixed-effects models are reported in the footnote. Missing data: Overall, 3, 2, 3, and 6 patients did not undergo evaluation of T2* at 4 to 12 hours, day 3, day 10, and 7 months, respectively. In addition, 1 patient did not undergo T2 analysis at 4 to 12 hours, day 10, or 7 months. At day 3, the presence of hemorrhage could be visually classified in all participants; however, T2* measurements (in ms) were affected by motion artifact and could not be reliably analyzed in all participants. The presence of myocardial hemorrhage is maximal at day 3, and the occurrence of infarct pathology at other time points is expressed as a proportion of those with (n=13) or without (n=17) myocardial hemorrhage on day 3. One patient did not have a T2 edema imaging map at 4 to 12 hours, day 10, or 7 months. Continuous data are expressed as mean (SD) except for myocardial salvage and myocardial hemorrhage, which are summarized as median (interquartile range). T2 hypointense core was delineated using T2 mapping. Five patients had no evidence of a T2* hypointense core at 4 to 12 hours and subsequently developed a T2* core on day 3. One patient's scan was not evaluable at 4 to 12 hours because of motion artifact, but there was evidence of T2* core on day 3. CMR indicates cardiac magnetic resonance; IQR, interquartile range; LV, left ventricular.

*Generalized linear mixed-effects models for the effects of hemorrhage and time point were used to obtain *P* values. *P* values are not presented for categorical data because the model is not supported for this function. Interactions were observed for LV ejection fraction ($P<0.001$), LV end-diastolic volume ($P=0.022$), myocardial edema ($P<0.001$), infarct size ($P<0.001$), and myocardial salvage ($P<0.0001$).

Temporal Relationships Between Intramyocardial Hemorrhage and Left Ventricular Outcomes From <12 Hours to 7 Months After Reperfusion

Left ventricular mass decreased from 140 ± 26 g at 3 days after MI to 119 ± 26 g at 7 months after MI ($P=0.003$). By 7 months after MI, left ventricular ejection fraction tended to increase ($56\pm 9\%$ versus $59\pm 8\%$, $P=0.061$), and infarct size (percentage of left ventricular mass) tended to be smaller ($20\pm 13\%$ versus $14\pm 10\%$; $P=0.10$).

At 3 days after MI, compared with patients without hemorrhage, patients with hemorrhage had a greater amount of myocardial edema (percentage of left ventricular mass $44\pm 8\%$ versus $35\pm 13\%$; $P=0.007$) and a lower left ventricular ejection fraction ($52\pm 8\%$ versus $58\pm 8\%$; $P=0.042$) (Table 2). Left ventricular ejection fraction increased in both groups

across the time points (Table 2); however, there was an interaction between ejection fraction and myocardial hemorrhage status ($P<0.001$), and there was less improvement in ejection fraction in patients with myocardial hemorrhage compared with those patients without myocardial hemorrhage.

Left ventricular end-diastolic volume increased over time in patients with myocardial hemorrhage ($P=0.001$) (Table 2). In contrast, left ventricular end-diastolic volume reduced over time in patients without hemorrhage (Table 2). Left ventricular end-diastolic volume was greater at 7 months versus 4 to 12 hours after MI in patients with hemorrhage compared with patients without hemorrhage ($P=0.0133$). At day 3 after MI, infarct size was greater in patients with hemorrhage compared with patients without hemorrhage ($P<0.001$) (Table 2).

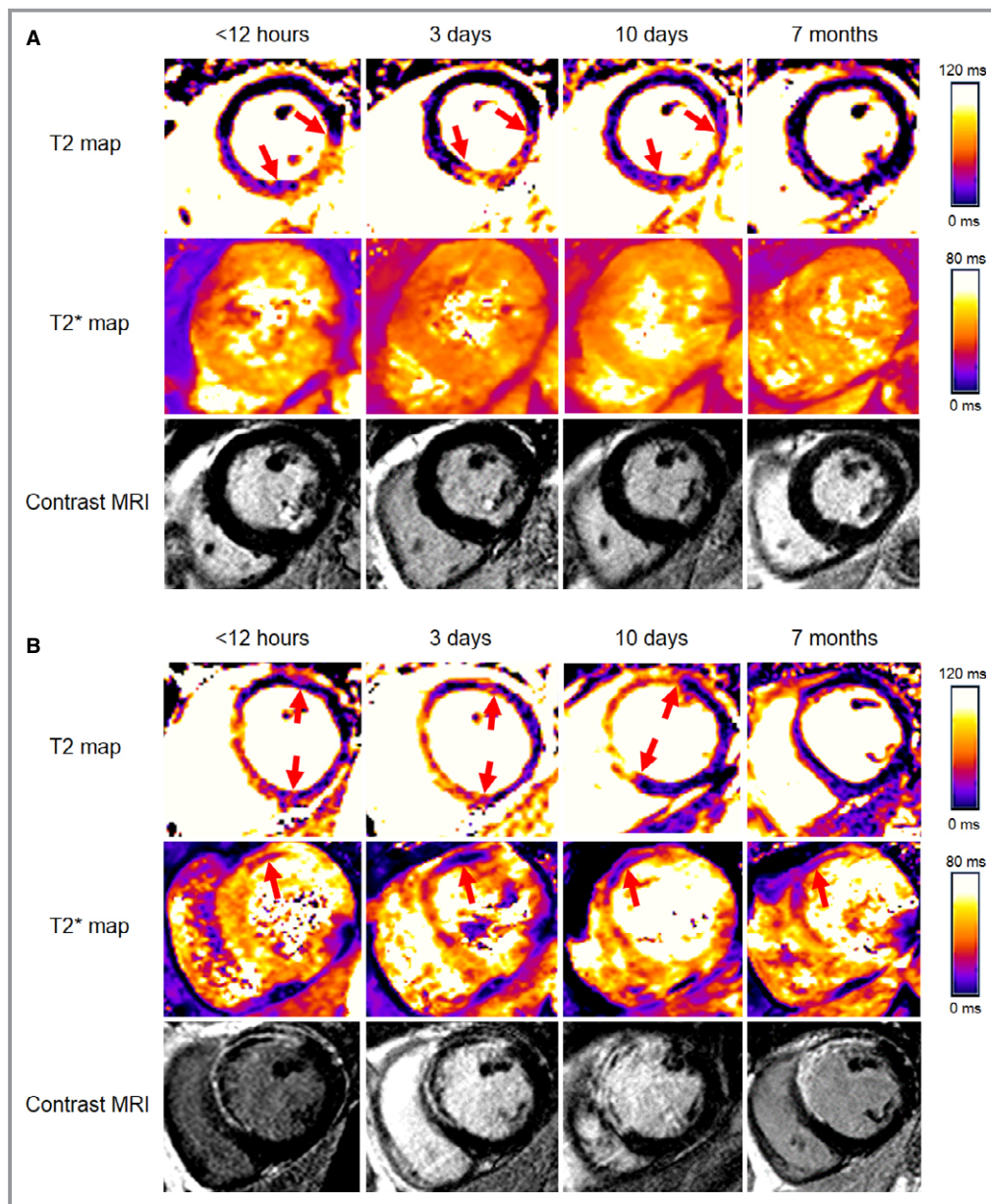


Figure 2. Cardiac magnetic resonance T2 mapping, T2* mapping, and contrast-enhanced images at 4 time points after reperfusion from patients without (A) and with (B) myocardial hemorrhage, following emergency percutaneous coronary intervention (Data S2). MRI indicates magnetic resonance imaging.

T2* Relaxation Times in the Myocardial Remote Zones and in Healthy Volunteers

T2* values in the remote zone did not change over time ($P=0.361$ for patients with myocardial hemorrhage; $P=0.876$ for patients without hemorrhage), and these values were similar to T2* values in healthy controls (supplementary file). At 7 months, in patients with myocardial hemorrhage at 3 days after MI, T2* values in the infarct zone remained reduced compared with the remote zone, whereas in patients without hemorrhage, T2* values in the

infarct zone were similar to T2* values in the remote zone (Table 3).

Discussion

We undertook the first longitudinal clinical study of myocardial hemorrhage involving serial contrast-enhanced CMR on 4 occasions in patients after STEMI. For the first time, the temporal evolution of myocardial infarct pathologies was assessed acutely from within 12 hours of reperfusion to 6 months after STEMI.

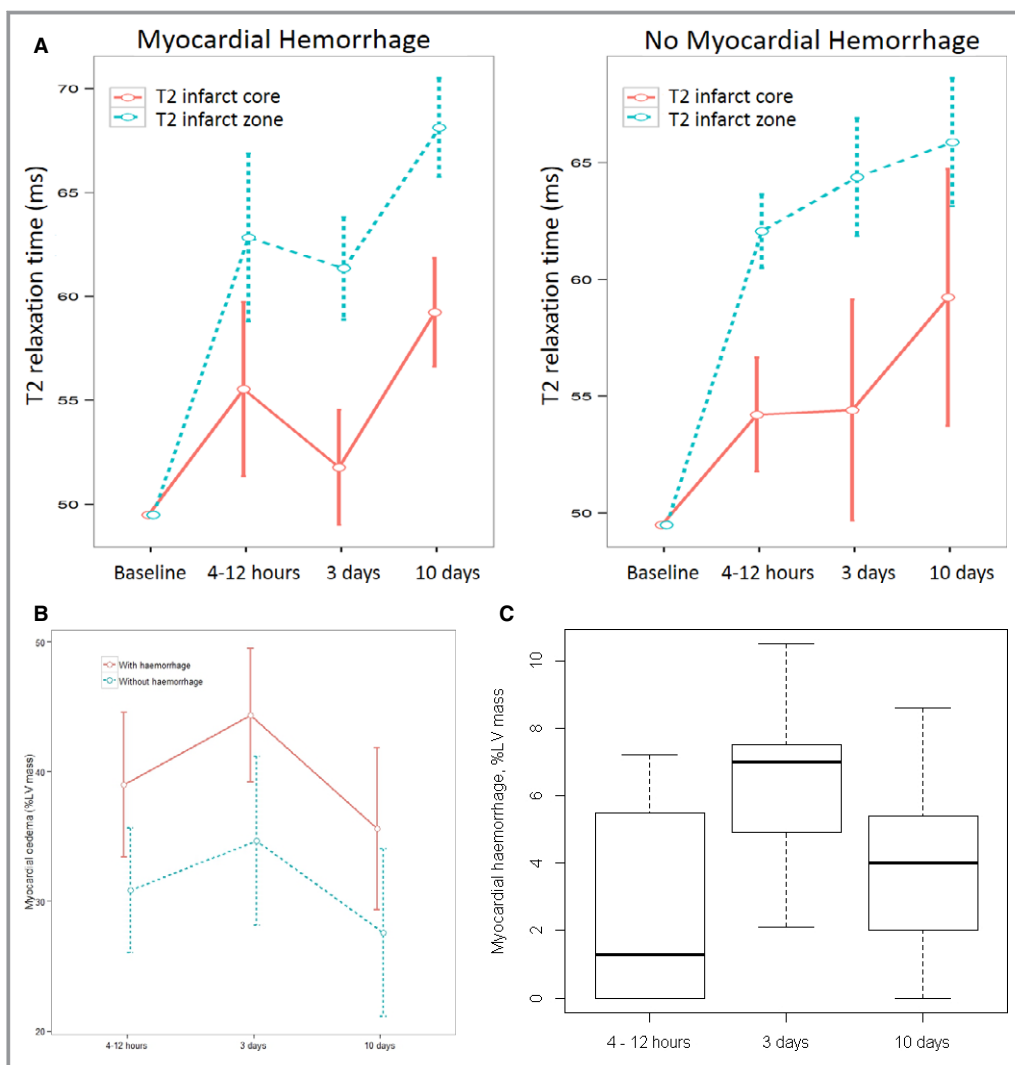


Figure 3. A, Time course of myocardial edema, reflected by T2 relaxation times (in ms) in patients with ST-segment elevation myocardial infarction with or without myocardial hemorrhage during the first 10 days after ischemia–reperfusion (Data S2). Edema (T2 values) evolved with a bimodal time course in patients with myocardial hemorrhage but with a unimodal time course in patients without hemorrhage. The red continuous red line links edema T2 relaxation times in the infarct core. The interrupted blue line links edema T2 relaxation times in the infarct zone. Because cardiac magnetic resonance scans were not obtained before reperfusion, the baseline mean T2 values are imputed T2 values at the midventricular level obtained from age-matched healthy volunteers. B, The amount of myocardial edema (% LV mass) evolved with a unimodal time course to a maximum on day 3. C, Amount of myocardial hemorrhage in the subgroup of patients with hemorrhage. In a linear mixed-effects model, the amount of myocardial hemorrhage across the time points of assessment was not associated with infarct size ($P=1.0$). %LV mass indicates percentage of left ventricular mass.

Our study had several main findings. First, the overall incidence of myocardial hemorrhage was 43%. Second, approximately one-quarter of the patients had evidence of myocardial hemorrhage 4 to 12 hours after MI, and hemorrhage detection increased progressively, with 20% of new cases at 3 days compared to 4 to 12 hours, and hematoma persisted at 10 days and 7 months in 11 (37%) and 4 (13%) patients, respectively. Third, myocardial edema (T2 values) evolves with a

bimodal time course in patients with myocardial hemorrhage but with a unimodal time course in patients without myocardial hemorrhage (Table 2). Fourth, T2* within the hemorrhagic core followed a similar pattern to T2, with a nadir in both on day 3. Fifth, during the first 10 days after reperfusion, myocardial edema (T2 values) within the infarct zone and hypointense core had a bimodal distribution in patients with myocardial hemorrhage, whereas myocardial edema had a unimodal progressive

Table 3. Myocardial Edema and Myocardial Hemorrhage in the Ischemic and Remote Zones for the Serial Imaging Subset (n=30) at 4 Successive Time Points After Reperfusion, Stratified by the Presence or Absence of Myocardial Hemorrhage on Day 3

Timing of MRI	4–12 Hours n=30		3 Days n=30		10 Days n=30		7 Months n=30					
	Yes	No	Yes	No	Yes	No	Yes	No	All	Yes	No	
IMH (Day 3)*												
T2* infarct zone, ms	29.2 (5.8)	37.7 (3.3)	26.6 (4.8)	39.6 (3.5)	28.6 (3.3)	37.0 (4.3)	29.2 (4.0)	32.7 (2.0)	0.018	0.095	<0.001	
T2* infarct core, ms	17.8 (6.0)	—	14.1 (4.1)	—	16.7 (5.9)	—	18.9 (6.2)	—	—	<0.001	—	
T2* remote zone, ms	31.9 (2.0)	32.4 (1.8)	32.9 (1.9)	32.3 (2.0)	32.6 (1.6)	32.0 (1.3)	32.4 (2.3)	32.3 (1.6)	0.478	0.361	0.876	
T2 infarct zone, ms	62.8 (6.7)	62.1 (2.9)	61.4 (4.1)	64.4 (4.9)	68.1 (3.7)	65.9 (5.3)	54.0 (2.8)	52.0 (3.2)	<0.001	<0.001	<0.001	
T2 infarct core, ms	55.5 (6.9)	54.2 (2.6)	51.8 (4.6)	54.4 (4.5)	59.2 (3.6)	59.2 (4.4)	—	—	<0.001	0.008	0.057	
T2 remote zone, ms	48.5 (2.5)	48.5 (2.0)	49.3 (1.7)	48.7 (2.1)	50.5 (2.4)	49.2 (2.1)	50.3 (1.6)	50.0 (1.4)	<0.001	0.002	0.003	

Myocardial edema is shown as T2 relaxation times (in ms), and myocardial hemorrhage is shown as T2* relaxation times (in ms). The T2* infarct core values are given for only those patients that had a T2* hypointense core to measure (n=7 at <12 hours, n=13 at day 3, n=11 at day 10 and n=4 at 7 months). IMH indicates intramyocardial hemorrhage; MRI, magnetic resonance imaging.

*Generalized linear mixed-effects models for the effects of hemorrhage and time point were used to obtain *P* values. *P* values are not presented for categorical data because the model is not supported for this function. Interactions in a model were observed for T2* infarct zone (in ms; *P*<0.001), T2* core (in ms; *P*<0.001), T2 infarct zone (in ms; *P*<0.001), T2 core (in ms; *P*=0.0083), T2 remote zone (in ms; *P*<0.001), and remote zone wall thickness (in cm; *P*<0.001).

increase in patients without myocardial hemorrhage. Sixth, changes in edema (T2 values) were inversely related to the occurrence and extent of hemorrhage. Seventh, myocardial hemorrhage was associated with sustained reductions in left ventricular ejection fraction and adverse left ventricular remodeling from baseline to 7 months.

Based on these observations, we concluded that myocardial hemorrhage increases progressively after reperfusion, with a primary hyperacute phase <12 hours after MI culminating in a peak 3 days later. The temporal changes in myocardial edema, reflected by T2 relaxation times, are inversely associated with myocardial hemorrhage. Our results provide further evidence that myocardial hemorrhage is an adverse prognostic complication after MI, but the interval between days 1 and 3—potentially a phase of secondary hemorrhage—suggests that a therapeutic window may exist in which to prevent hemorrhage should targeted therapies become available in the future.

Our clinical data provided new insights into experimental observations of the time course of myocardial edema by Fernández-Jiménez et al.^{15,16} They described a bimodal pattern of myocardial edema with peaks of percentage myocardial water content and myocardial edema (T2 values) acutely at 2 hours after reperfusion and 7 days later, associated with an intervening decrease in myocardial water content at 24 hours. They concluded that myocardial edema occurred in 2 waves, the first occurring abruptly after reperfusion and a second “deferred wave of edema” appearing progressively in relation to inflammation and healing.¹⁵ There could be alternative explanations for the “second wavefront of edema,” including (1) a reduction in infarct tissue mass and a relative increase in percentage water or (2) an increase in the wet weight of tissue due to progressive

myocardial hemorrhage or hemorrhagic transformation.^{17,18} Our analysis supports the latter. Oxidative denaturation of hemoglobin evolves over 1 to 3 days,¹⁹ and the product, deoxyhemoglobin, has paramagnetic effects that destroy T2 signal (ie, the relaxation time becomes shorter). Our results are consistent with concomitant oxidative denaturation and paramagnetic destruction of the T2 signal within the infarct core, as noted in earlier preclinical³² and clinical⁴² observations. Consequently, the peak in myocardial hemorrhage that we observed 3 days after MI likely explains the reductions in colocalized reduction in T2 values at this time point, giving the false impression that edema is also reduced. In other words, the T2 signal associated with water content and mobility is reduced by the paramagnetic effects of deoxyhemoglobin, but—distinct from this magnetic resonance phenomenon—tissue water content (edema) may be unchanged. Our observations provide an alternative explanation for the bimodal distribution in T2 values that was observed by Fernández-Jiménez et al.¹⁵ In contrast, we observed that the amount of myocardial edema had a unimodal evolution regardless of the presence or absence of hemorrhage.

The apparent progression of myocardial hemorrhage over time in some patients is consistent with hemorrhagic transformation after tissue infarction, which is especially relevant to reperfused STEMI patients who have been treated with antithrombotic therapies.^{17,19}

Based on morphological² and functional studies,⁴³ microvascular obstruction may have structural and functional components,⁴⁴ reflecting irreversible (ie, endothelial disruption) and reversible (eg, microvascular spasm, extrinsic edema) components. Myocardial hemorrhage reflects the aggregation and extravasation of erythrocytes^{4,20,45} and is a manifestation of severe microvascular injury. On CMR at day

3, 5 patients without evidence of hemorrhage on T2* imaging had hypointense cores on T2 maps and microvascular obstruction on contrast imaging. The mean T2 core value for these patients was greater than that for patients with hemorrhage (54.5 ± 4.5 versus 51.8 ± 4.6 ms; $P=0.268$). The hypointense core on T2 maps in the absence of hemorrhage likely represents a reduction in the amount of tissue water within the infarct core related to obstructed capillary flow, consistent with microvascular obstruction (Table 2; Figure 3).²⁸ The observation that the mean T2 core value is lower in patients with hemorrhage is consistent with the additional effect of paramagnetic depletion of the T2 signal.

Our results have important clinical implications. First, the results provide new insights into the experimental concepts proposed by Fernández-Jiménez et al^{15,16} and Kim et al.¹¹ Our results confirmed that the extent of edema is not stable and that the occurrence and temporal evolution of myocardial hemorrhage influences other infarct characteristics such as edema and microvascular obstruction, as revealed by edema (T2-weighted) and contrast-enhanced CMR, respectively. Second, our results should be helpful for planning the timing of CMR imaging after MI for clinical and research purposes and indicate that the extent of edema and size of infarction decrease after 3 days. Third, our results provide further information on the adverse prognostic associations between myocardial hemorrhage and reductions in left ventricular systolic function and adverse left ventricular remodeling,^{5,7,46,47} and thus draw attention to the pathophysiological importance of this complication. Finally, our results confirm that infarct pathologies evolve progressively after MI and thus may be amenable to targeted preventative therapeutic interventions. Robbers et al⁴⁵ proposed that myocardial hemorrhage was the final consequence of severe microvascular thrombosis and that therapeutic interventions that restored microvascular perfusion might, in turn, prevent myocardial hemorrhage. Observations in the current study (Table 2; Figure 3) and by Robbers et al⁴⁵ and Payne et al²⁰ also support the notion that red blood cells may be “trapped” in the microcirculation of the culprit coronary artery, reflecting a contributing cause and/or consequence of microvascular obstruction. Degradation of these red cells may also contribute to local paramagnetic effects. Conceivably, intracoronary thrombolysis administered early after reperfusion and before stent implantation might reduce coronary thrombus burden and distal clot embolization, lyse microvascular thrombi, and restore microvascular perfusion early after MI. We are examining this hypothesis in a randomized, double-blind, placebo-controlled, parallel group trial of low-dose adjunctive alteplase during primary percutaneous coronary intervention (T-TIME, ClinicalTrials.gov identifier NCT02257294).

Limitations

We do not have pathological validation of our imaging results. Preclinical studies enable pathological validation^{15,32}; however, the corollary is a stepped reduction in sample size and statistical power when histopathology is undertaken ($n=20$ at 2 hours after MI versus $n=5$ at 7 days after MI¹⁵). The sample size in our cohort was preserved across all time points, and although the study population was limited in size ($n=30$), the statistical power was preserved by paired ($n=4$) assessments within the same participant and 100% follow-up of all participants. In our study, CMR was not performed on day 2, so a nadir in edema cannot be ruled out. Although CMR was not possible before STEMI, we think it is reasonable to believe that no hemorrhage was present in the STEMI patients before the event, implying a “zero baseline,” because remote T2 and T2* values in STEMI patients were similar to those measured in healthy persons. We acknowledge that the differences in edema (T2) and hemorrhage (T2*) are within the interobserver range of values and that our findings do not confirm causality. We also acknowledge that, expectedly, less deoxyhemoglobin will be present in the hyperacute phase (<24 hours after reperfusion, when oxyhemoglobin is the predominant form of hemoglobin) compared with the postacute phase (days 1 to <3), and that a possible explanation for the increase in the extent of the hypointense core on T2* CMR mapping is an increase in deoxyhemoglobin content within the hematoma.⁴⁸ Further research is warranted.

Conclusion

Myocardial hemorrhage peaked at day 3 after MI in reperfused STEMI patients, and that explains the reduction in T2 values and the bimodal pattern. Myocardial edema has a unimodal time course.

Acknowledgments

We thank the patients who participated in this study and the staff in the Cardiology and Radiology Departments. We thank Peter Weale and Patrick Revell (Siemens Healthcare, UK).

Sources of Funding

This research was supported by the British Heart Foundation Grant (Project Grant PG/11/2/28474), the National Health Service, the Chief Scientist Office, and Medical Research Scotland. Professor Berry was supported by a Senior Fellowship from the Scottish Funding Council.

Disclosures

This project was supported by a collaboration with Siemens Healthcare. Authors have a research agreement with Siemens Healthcare for MRI work-in-progress pulse sequences.

References

- Betgem RP, de Waard GA, Nijveldt R, Beek AM, Escaned J, van Royen N. Intramyocardial haemorrhage after acute myocardial infarction. *Nat Rev Cardiol*. 2015;12:156–167.
- Kloner RA, Ganote CE, Jennings RB. The “no-reflow” phenomenon after temporary coronary occlusion in the dog. *J Clin Invest*. 1974;54:1496–1508.
- Jaffe R, Charron T, Puley G, Dick A, Strauss BH. Microvascular obstruction and the no-reflow phenomenon after percutaneous coronary intervention. *Circulation*. 2008;117:3152–3156.
- Higginson LA, White F, Heggtveit HA, Sanders TM, Bloor CM, Covell JW. Determinants of myocardial hemorrhage after coronary reperfusion in the anesthetized dog. *Circulation*. 1982;65:62–69.
- Ganame J, Messalli G, Dymarkowski S, Rademakers FE, Desmet W, Van de Werf F, Bogaert J. Impact of myocardial haemorrhage on left ventricular function and remodelling in patients with reperfused acute myocardial infarction. *Eur Heart J*. 2009;30:1440–1449.
- Amabile N, Jacquier A, Shuhab A, Gaudart J, Bartoli JM, Paganelli F, Moulin G. Incidence, predictors, and prognostic value of intramyocardial hemorrhage lesions in ST elevation myocardial infarction. *Catheter Cardiovasc Interv*. 2012;79:1101–1108.
- Eitel I, Kubusch K, Strohm O, Desch S, Mikami Y, de Waha S, Gutberlet M, Schuler G, Friedrich MG, Thiele H. Prognostic value and determinants of a hypointense infarct core in T2-weighted cardiac magnetic resonance in acute reperfused ST-elevation-myocardial infarction. *Circ Cardiovasc Imaging*. 2011;4:354–362.
- Husser O, Monmeneu JV, Sanchis J, Nunez J, Lopez-Lereu MP, Bonanad C, Chaustre F, Gomez C, Bosch MJ, Hinarejos R, Chorro FJ, Rieggier GA, Llacer A, Bodi V. Cardiovascular magnetic resonance-derived intramyocardial hemorrhage after STEMI: influence on long-term prognosis, adverse left ventricular remodeling and relationship with microvascular obstruction. *Int J Cardiol*. 2013;167:2047–2054.
- Bragadeesh T, Jayaweera AR, Pascotto M, Micari A, Le DE, Kramer CM, Epstein FH, Kaul S. Post-ischaemic myocardial dysfunction (stunning) results from myofibrillar oedema. *Heart*. 2008;94:166–171.
- Heusch P, Nensa F, Heusch G. Is MRI really the gold standard for the quantification of salvage from myocardial infarction? *Circ Res*. 2015;117:222–224.
- Kim HW, Van Assche L, Jennings RB, Wince WB, Jensen CJ, Rehwald WG, Wendell DC, Bhatti L, Spatz DM, Parker MA, Jenista ER, Klem I, Crowley AL, Chen EL, Judd RM, Kim RJ. Relationship of T2-weighted MRI myocardial hyperintensity and the ischemic area-at-risk. *Circ Res*. 2015;117:254–265.
- Aletras AH, Tilak GS, Natanzon A, Hsu LY, Gonzalez FM, Hoyt RF Jr, Arai AE. Retrospective determination of the area at risk for reperfused acute myocardial infarction with T2-weighted cardiac magnetic resonance imaging: histopathological and displacement encoding with stimulated echoes (DENSE) functional validations. *Circulation*. 2006;113:1865–1870.
- Berry C, Kellman P, Mancini C, Chen MY, Bandettini WP, Lowrey T, Hsu LY, Aletras AH, Arai AE. Magnetic resonance imaging delineates the ischemic area at risk and myocardial salvage in patients with acute myocardial infarction. *Circ Cardiovasc Imaging*. 2010;3:527–535.
- Dall’Armellina E, Karia N, Lindsay AC, Karamitsos TD, Ferreira V, Robson MD, Kellman P, Francis JM, Forfar C, Prendergast BD, Banning AP, Channon KM, Kharbanda RK, Neubauer S, Choudhury RP. Dynamic changes of edema and late gadolinium enhancement after acute myocardial infarction and their relationship to functional recovery and salvage index. *Circ Cardiovasc Imaging*. 2011;4:228–236.
- Fernandez-Jimenez R, Sanchez-Gonzalez J, Agüero J, Garcia-Prieto J, Lopez-Martin GJ, Garcia-Ruiz JM, Molina-Iracheta A, Rossello X, Fernandez-Friera L, Pizarro G, Garcia-Alvarez A, Dall’Armellina E, Macaya C, Choudhury RP, Fuster V, Ibanez B. Myocardial edema after ischemia/reperfusion is not stable and follows a bimodal pattern: imaging and histological tissue characterization. *J Am Coll Cardiol*. 2015;65:315–323.
- Fernandez-Jimenez R, Garcia-Prieto J, Sanchez-Gonzalez J, Agüero J, Lopez-Martin GJ, Galan-Arriola C, Molina-Iracheta A, Doohan R, Fuster V, Ibanez B. Pathophysiology underlying the bimodal edema phenomenon after myocardial ischemia/reperfusion. *J Am Coll Cardiol*. 2015;66:816–828.
- Fishbein MC, Y-Rit J, Lando U, Kanmatsuse K, Mercier JC, Ganz W. The relationship of vascular injury and myocardial hemorrhage to necrosis after reperfusion. *Circulation*. 1980;62:1274–1279.
- Alvarez-Sabin J, Maisterra O, Santamarina E, Kase CS. Factors influencing haemorrhagic transformation in ischaemic stroke. *Lancet Neurol*. 2013;12:689–705.
- Anzalone N, Scotti R, Riva R. Neuroradiological differential diagnosis of cerebral intraparenchymal hemorrhage. *J Neurol Sci*. 2004;25(suppl 1):S3–S5.
- Payne AR, Berry C, Kellman P, Anderson R, Hsu LY, Chen MY, McPhaden AR, Watkins S, Schenke W, Wright V, Lederman RJ, Aletras AH, Arai AE. Bright-blood T(2)-weighted MRI has high diagnostic accuracy for myocardial hemorrhage in myocardial infarction: a preclinical validation study in swine. *Circ Cardiovasc Imaging*. 2011;4:738–745.
- Windecker S, Kolh P, Alfonso F, Collet JP, Cremer J, Falk V, Filippatos G, Hamm C, Head SJ, Juni P, Kappetein AP, Kastrati A, Knuuti J, Landmesser U, Laufer G, Neumann FJ, Richter DJ, Schauerte P, Sousa Uva M, Stefanini GG, Taggart DP, Torracca L, Valgimigli M, Wijns W, Witkowski A. 2014 ESC/EACTS guidelines on myocardial revascularization: the Task Force on Myocardial Revascularization of the European Society of Cardiology (ESC) and the European Association for Cardio-Thoracic Surgery (EACTS). Developed with the special contribution of the European Association of Percutaneous Cardiovascular Interventions (EAPCI). *Eur Heart J*. 2014;35:2541–2619.
- Steg PG, James SK, Atar D, Badano LP, Blomstrom-Lundqvist C, Borger MA, Di Mario C, Dickstein K, Ducrocq G, Fernandez-Aviles F, Gershlick AH, Giannuzzi P, Halvorsen S, Huber K, Juni P, Kastrati A, Knuuti J, Lenzen MJ, Mahaffey KW, Valgimigli M, van ‘t Hof A, Widimsky P, Zahger D. ESC guidelines for the management of acute myocardial infarction in patients presenting with ST-segment elevation. *Eur Heart J*. 2012;33:2569–2619.
- Kramer CM, Barkhausen J, Flamm SD, Kim RJ, Nagel E. Standardized cardiovascular magnetic resonance (CMR) protocols 2013 update. *J Cardiovasc Magn Reson*. 2013;15:91.
- Moon JC, Messroghli DR, Kellman P, Piechnik SK, Robson MD, Ugander M, Gatehouse PD, Arai AE, Friedrich MG, Neubauer S, Schulz-Menger J, Schelbert EB; Society for Cardiovascular Magnetic Resonance I and Cardiovascular Magnetic Resonance Working Group of the European Society of C. Myocardial T1 mapping and extracellular volume quantification: a Society for Cardiovascular Magnetic Resonance (SCMR) and CMR Working Group of the European Society of Cardiology consensus statement. *J Cardiovasc Magn Reson*. 2013;15:92.
- Carrick D, Haig C, Rauhalammi S, Ahmed N, Mordi I, McEntegart M, Petrie MC, Eteiba H, Hood S, Watkins S, Lindsay M, Mahrous A, Ford I, Tzemos N, Sattar N, Welsh P, Radjenovic A, Oldroyd KG, Berry C. Prognostic significance of infarct core pathology revealed by quantitative non-contrast in comparison with contrast cardiac magnetic resonance imaging in reperfused ST-elevation myocardial infarction survivors. *Eur Heart J*. 2015;doi:10.1093/eurheartj/ehv372 [Epub ahead of print].
- Carrick D, Haig C, Rauhalammi S, Ahmed N, Mordi I, McEntegart M, Petrie MC, Eteiba H, Lindsay M, Watkins S, Hood S, Davie A, Mahrous A, Ford I, Tzemos N, Sattar N, Welsh P, Radjenovic A, Ford I, Oldroyd KG, Berry C. Pathophysiology of LV remodeling in survivors of STEMI: inflammation, remote myocardium, and prognosis. *JACC Cardiovasc Imaging*. 2015;8:779–789.
- Giri S, Chung YC, Merchant A, Mihai G, Rajagopalan S, Raman SV, Simonetti OP. T2 quantification for improved detection of myocardial edema. *J Cardiovasc Magn Reson*. 2009;11:56.
- Verhaert D, Thavendiranathan P, Giri S, Mihai G, Rajagopalan S, Simonetti OP, Raman SV. Direct T2 quantification of myocardial edema in acute ischemic injury. *JACC Cardiovasc Imaging*. 2011;4:269–278.
- Kellman P, Arai AE, McVeigh ER, Aletras AH. Phase-sensitive inversion recovery for detecting myocardial infarction using gadolinium-delayed hyper-enhancement. *Magn Reson Med*. 2002;47:372–383.
- Wassmuth R, Prothmann M, Utz W, Dieringer M, von Knobelsdorff-Brenkenhoff F, Greiser A, Schulz-Menger J. Variability and homogeneity of cardiovascular magnetic resonance myocardial T2-mapping in volunteers compared to patients with edema. *J Cardiovasc Magn Reson*. 2013;15:27.
- Cerqueira MD, Weissman NJ, Dilsizian V, Jacobs AK, Kaul S, Laskey WK, Pennell DJ, Rumberger JA, Ryan T, Verani MS. Standardized myocardial segmentation and nomenclature for tomographic imaging of the heart. A statement for healthcare professionals from the Cardiac Imaging Committee of the Council on Clinical Cardiology of the American Heart Association. *Circulation*. 2002;105:539–542.
- Ghugre NR, Ramanan V, Pop M, Yang Y, Barry J, Qiang B, Connelly KA, Dick AJ, Wright GA. Quantitative tracking of edema, hemorrhage, and microvascular obstruction in subacute myocardial infarction in a porcine model by MRI. *Magn Reson Med*. 2011;66:1129–1141.
- Kandler D, Lucke C, Grothoff M, Andres C, Lehmkuhl L, Nitzsche S, Riese F, Mende M, de Waha S, Desch S, Lurz P, Eitel I, Gutberlet M. The relation

- between hypointense core, microvascular obstruction and intramyocardial haemorrhage in acute reperfused myocardial infarction assessed by cardiac magnetic resonance imaging. *Eur Radiol*. 2014;24:3277–3288.
34. O'Regan DP, Ariff B, Neuwirth C, Tan Y, Durighel G, Cook SA. Assessment of severe reperfusion injury with T2* cardiac MRI in patients with acute myocardial infarction. *Heart*. 2010;96:1885–1891.
 35. Anderson LJ, Holden S, Davis B, Prescott E, Charrier CC, Bunce NH, Firmin DN, Wonke B, Porter J, Walker JM, Pennell DJ. Cardiovascular T2-star (T2*) magnetic resonance for the early diagnosis of myocardial iron overload. *Eur Heart J*. 2001;22:2171–2179.
 36. Flett AS, Hasleton J, Cook C, Hausenloy D, Quarta G, Ariti C, Muthurangu V, Moon JC. Evaluation of techniques for the quantification of myocardial scar of differing etiology using cardiac magnetic resonance. *JACC Cardiovasc Imaging*. 2011;4:150–156.
 37. Eitel I, Desch S, Fuernau G, Hildebrand L, Gutberlet M, Schuler G, Thiele H. Prognostic significance and determinants of myocardial salvage assessed by cardiovascular magnetic resonance in acute reperfused myocardial infarction. *J Am Coll Cardiol*. 2010;55:2470–2479.
 38. Ugander M, Bagi PS, Oki AJ, Chen B, Hsu LY, Aletras AH, Shah S, Greiser A, Kellman P, Arai AE. Myocardial edema as detected by pre-contrast T1 and T2 CMR delineates area at risk associated with acute myocardial infarction. *JACC Cardiovasc Imaging*. 2012;5:596–603.
 39. Payne AR, Casey M, McClure J, McGeoch R, Murphy A, Woodward R, Saul A, Bi X, Zuehlsdorff S, Oldroyd KG, Tzemos N, Berry C. Bright-blood T2-weighted MRI has higher diagnostic accuracy than dark-blood short tau inversion recovery MRI for detection of acute myocardial infarction and for assessment of the ischemic area at risk and myocardial salvage. *Circ Cardiovasc Imaging*. 2011;4:210–219.
 40. Payne AR, Berry C, Doolin O, McEntegart M, Petrie MC, Lindsay MM, Hood S, Carrick D, Tzemos N, Weale P, McComb C, Foster J, Ford I, Oldroyd KG. Microvascular resistance predicts myocardial salvage and infarct characteristics in ST-elevation myocardial infarction. *J Am Heart Assoc*. 2012;1:e002246 doi: 10.1161/JAHA.112.002246.
 41. van Kranenburg M, Magro M, Thiele H, de Waha S, Eitel I, Cochet A, Cottin Y, Atar D, Buser P, Wu E, Lee D, Bodi V, Klug G, Metzler B, Delewi R, Bernhardt P, Rottbauer W, Boersma E, Zijlstra F, van Geuns RJ. Prognostic value of microvascular obstruction and infarct size, as measured by CMR in STEMI patients. *JACC Cardiovasc Imaging*. 2014;7:930–939.
 42. Zia MI, Ghugre NR, Connelly KA, Strauss BH, Sparkes JD, Dick AJ, Wright GA. Characterizing myocardial edema and hemorrhage using quantitative T2 and T2* mapping at multiple time intervals post ST-segment elevation myocardial infarction. *Circ Cardiovasc Imaging*. 2012;5:566–572.
 43. Wilson RF, Laxson DD, Lesser JR, White CW. Intense microvascular constriction after angioplasty of acute thrombotic coronary arterial lesions. *Lancet*. 1989;1:807–811.
 44. Galiuto L. Optimal therapeutic strategies in the setting of post-infarct no reflow: the need for a pathogenetic classification. *Heart*. 2004;90:123–125.
 45. Robbers LF, Eerenberg ES, Teunissen PF, Jansen MF, Hollander MR, Horrevoets AJ, Knaapen P, Nijveldt R, Heymans MW, Levi MM, van Rossum AC, Niessen HW, Marcu CB, Beek AM, van Royen N. Magnetic resonance imaging-defined areas of microvascular obstruction after acute myocardial infarction represent microvascular destruction and haemorrhage. *Eur Heart J*. 2013;34:2346–2353.
 46. Beek AM, Nijveldt R, van Rossum AC. Intramyocardial hemorrhage and microvascular obstruction after primary percutaneous coronary intervention. *Int J Cardiovasc Imaging*. 2010;26:49–55.
 47. Kidambi A, Mather AN, Motwani M, Swoboda P, Uddin A, Greenwood JP, Plein S. The effect of microvascular obstruction and intramyocardial hemorrhage on contractile recovery in reperfused myocardial infarction: insights from cardiovascular magnetic resonance. *J Cardiovasc Magn Reson*. 2013;15:58.
 48. Bradley WG Jr. MR appearance of hemorrhage in the brain. *Radiology*. 1993;189:15–26.