

# Dislodgement and gastrointestinal tract penetration of bone cement used for spinal reconstruction after lumbosacral vertebral tumor excision

## A case report

Masateru Nagae, MD, PhD<sup>a</sup>, Yasuo Mikami, MD, PhD<sup>b</sup>, Kentaro Mizuno, MD, PhD<sup>a</sup>, Tomohisa Harada, MD, PhD<sup>c</sup>, Takumi Ikeda, MD, PhD<sup>b</sup>, Hitoshi Tonomura, MD, PhD<sup>a</sup>, Ryota Takatori, MD, PhD<sup>a</sup>, Hiroyoshi Fujiwara, MD, PhD<sup>a,\*</sup>, Toshikazu Kubo, MD, PhD<sup>a</sup>

### Abstract

**Introduction:** Polymethylmethacrylate (PMMA) cement is useful for spinal reconstruction, but can cause complications including new vertebral fractures, neurological disorders and pulmonary embolism. We report a case in PMMA cement used for spinal reconstruction after tumor curettage dislodged and penetrated the gastrointestinal tract.

**Diagnoses:** The patient was diagnosed with a retroperitoneal extragonadal germ cell tumor at age 27 years. After chemotherapy and tumor resection, the tumor remained. It gradually increased in size and infiltrated lumbosacral vertebrae, causing him to present at age 35 years with increased low back pain. Image findings showed bone destruction in the vertebral bodies accompanied by neoplastic lesions. The left and right common iliac arteries and inferior vena cava were enclosed in the tumor on the anterior side of the vertebral bodies. Lumbosacral bone tumor due to direct extragonadal germ cell tumor infiltration was diagnosed. A 2-step operation was planned; first, fixation of the posterior side of the vertebral bodies, followed by tumor resection using an anterior transperitoneal approach, and spinal reconstruction using PMMA cement. After surgery, the PMMA cement gradually dislodged towards the anterior side and, 2 years 9 months after surgery, it had penetrated the retroperitoneum. The patient subsequently developed nausea and abdominal pain and was readmitted to hospital. The diagnosis was intestinal blockage with dislodged PMMA cement, and an operation was performed to remove the cement present in the small intestine. There was strong intra-abdominal adhesion, the peritoneum between the vertebral bodies and intestine could not be identified, and no additional treatment for vertebral body defects could be performed. After surgery, gastrointestinal symptoms resolved.

**Conclusion:** Although this was a rare case, when using bone cement for vertebral body reconstruction, the way of anchoring for the cement must be thoroughly planned to assure no cement dislodgement can occur.

**Abbreviations:** AFP = alpha-fetoprotein, LDH = lactate dehydrogenase, PMMA = polymethylmethacrylate.

**Keywords:** dislodgement, gastrointestinal tract penetration, lumbosacral vertebral body tumor resection, polymethylmethacrylate cement, spinal reconstruction

## 1. Introduction

The usefulness of polymethylmethacrylate (PMMA) cement for vertebral body reconstruction after resection of a vertebral body

Editor: Nicandro Figueiredo.

The authors have no conflicts of interest to declare.

<sup>a</sup> Department of Orthopaedics, <sup>b</sup> Department of Rehabilitation Medicine, Graduate School of Medical Science, Kyoto Prefectural University of Medicine, Kyoto, Japan, <sup>c</sup> Department of Spinal Surgery, Rakuwakai Marutamachi Hospital, Kyoto, Japan.

\* Correspondence: Hiroyoshi Fujiwara, 465 Kajii-cho, Kamigyo-ku, Kyoto 602-8566, Japan (e-mail: ffwr@koto.kpu-m.ac.jp).

Copyright © 2016 the Author(s). Published by Wolters Kluwer Health, Inc. All rights reserved.

This is an open access article distributed under the terms of the Creative Commons Attribution-Non Commercial-No Derivatives License 4.0 (CCBY-NC-ND), where it is permissible to download and share the work provided it is properly cited. The work cannot be changed in any way or used commercially without permission from the journal.

Medicine (2016) 95:42(e5178)

Received: 4 September 2015 / Received in final form: 24 September 2016 /

Accepted: 28 September 2016

<http://dx.doi.org/10.1097/MD.0000000000005178>

tumor or for vertebroplasty to treat vertebral body tumors or osteoporotic vertebral body fractures has been reported.<sup>[1-4]</sup> There have also been many reports of complications occurring when PMMA cement is used.<sup>[5-17]</sup> The aim of this report is to describe a case of PMMA cement dislodged from vertebral bodies after tumor resection and vertebral reconstruction using PMMA cement followed by penetration of the cement into the gastrointestinal tract causing blockage.

## 2. Method

This is a case report, and informed consent was obtained from the patient and his wife.

## 3. Case report

### 3.1. Case

35-year-old male.

### 3.2. Chief complaint

Low back pain.

### 3.3. Past medical history

Nothing of note.

### 3.4. Family history

Nothing of note.

### 3.5. Current medical history

At the age of 27 years, he was diagnosed with a retroperitoneal tumor (extragonadal germ cell tumor). After chemotherapy, the tumor was resected, but strong adhesion between the tumor and surrounding tissue made it impossible to resect the entire tumor. The remaining tumor gradually increased in size and infiltrated lumbosacral vertebrae. Chemotherapy and radiotherapy were given to treat the remaining tumor, but low back pain gradually increased and the patient visited our department at the age of 35 years.

### 3.6. Physical findings and neurological findings

Other than strong low back pain, no neurological abnormalities were observed.

### 3.7. Blood biochemistry findings

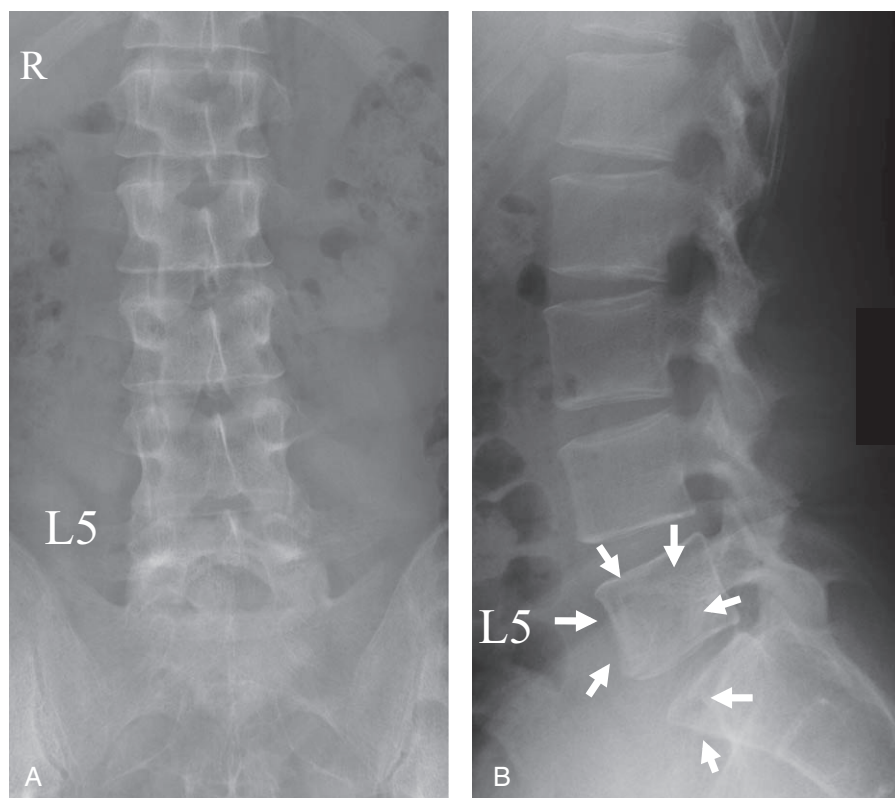
At the time of his first examination at our hospital, alpha-fetoprotein (AFP) was 205.7 ng/mL and lactate dehydrogenase (LDH) was a high 1495 U/L, but human chorionic gonadotropin was normal at 0.4 mIU/mL. After undergoing chemotherapy and radiotherapy, AFP, LDH, and human chorionic gonadotropin

values were all normal. The C-reactive protein value was 0.3 mg/dL, erythrocyte sedimentation rate was 3.00 mm/h and no inflammatory reaction was observed.

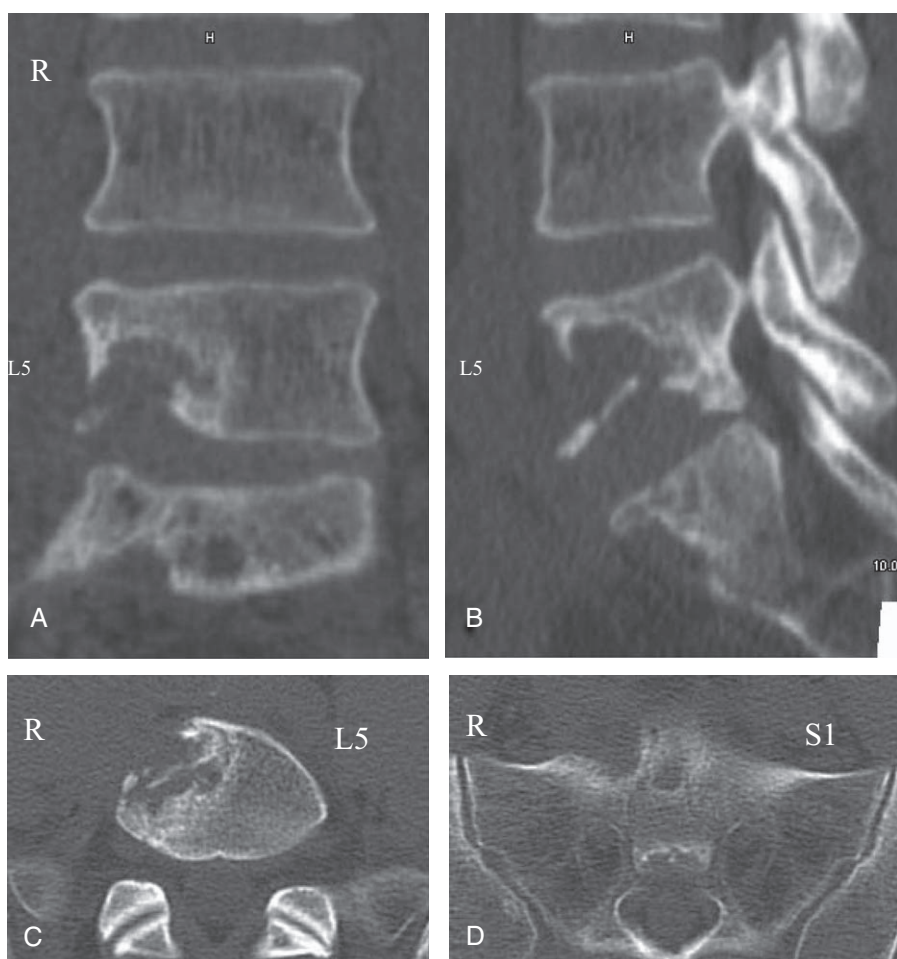
### 3.8. Image findings

Plain radiographs (Fig. 1) and computed tomography images (Fig. 2) showed bone destruction from L5 to S1. Magnetic resonance imaging with T1 weighted images showed iso signal intensity, T2 weighted images showed speckling with high intensity, and neoplastic lesions were observed with gadolinium contrast imaging. The left and right common iliac arteries and inferior vena cava were enclosed in the tumor on the anterior side of the vertebral bodies. The infiltration of tumor to vertebral bodies was observed (Fig. 3).

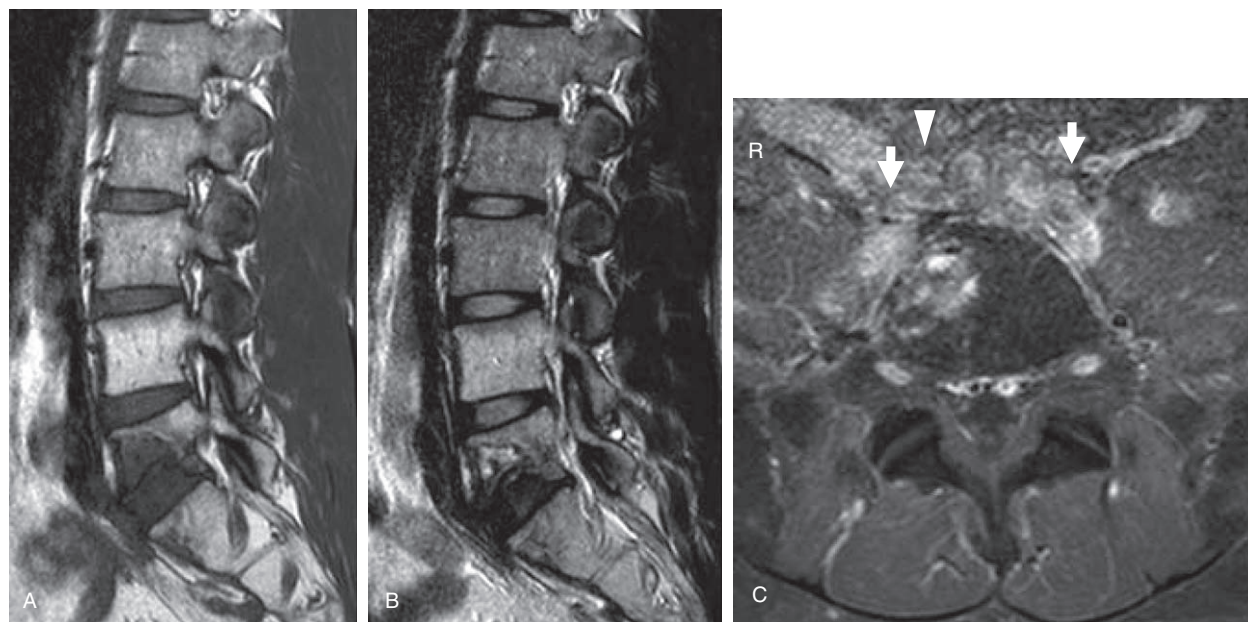
The diagnosis in this case was lumbosacral bone tumor due to direct extragonadal germ cell tumor infiltration. A 2-step operation was planned, with the first operation performed using instrumentation to fix the posterior side of the vertebral bodies (L3–S2). Two weeks later, using an anterior transperitoneal approach, the tumor was resected and the defect of vertebral bodies L5 to S1 was reconstructed directly in the operative field using PMMA cement (Fig. 4). We used PMMA cement that was not loaded with antibiotics because of the primary nature of the reconstructive surgery without evidence of infection. The retroperitoneal tumor was resected by a urologist, but there was strong adhesion between the tumor and left and right common iliac arteries. It was necessary to resect both the common iliac arteries, and a vascular surgeon replaced them with artificial vessels. During surgery, some damage to the left ureter also occurred and had to be repaired.



**Figure 1.** Preoperative frontal (A) and lateral (B) plain radiograph findings. Arrows in lateral image indicate translucency.

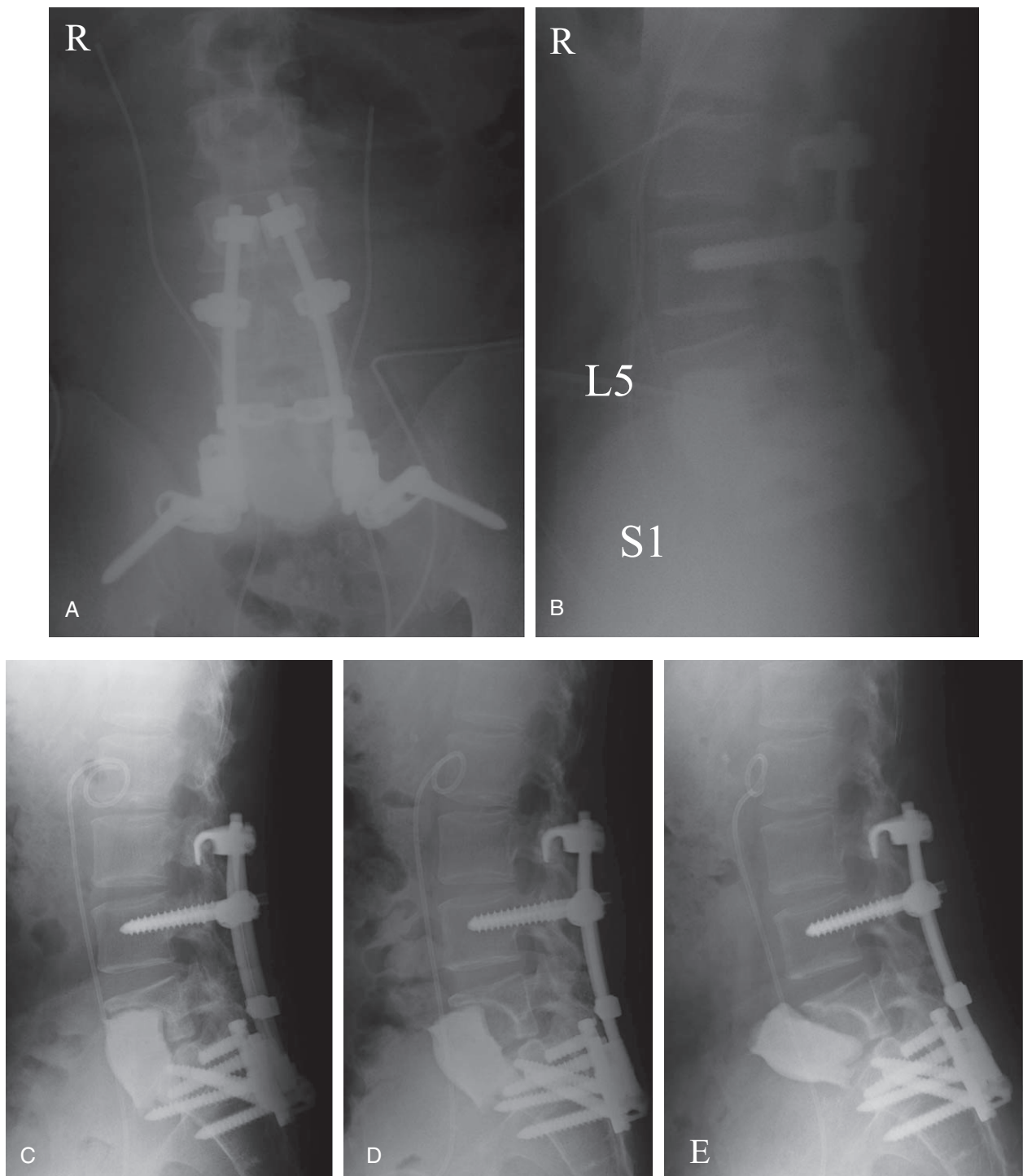


**Figure 2.** Preoperative coronal (A), sagittal (B), and axial (C, D) CT findings. L5 and S1 vertebral bone destruction can be seen. CT=computed tomography.



**Figure 3.** Preoperative T1 weighted (A), T2 weighted (B), and gadolinium contrast (C) MRI findings. Arrows indicate left/right common iliac arteries. Arrowhead indicates the inferior vena cava. A tumor can be seen at L5 and S1. The left/right common iliac artery and inferior vena cava are surrounded by the tumor. MRI= magnetic resonance imaging.





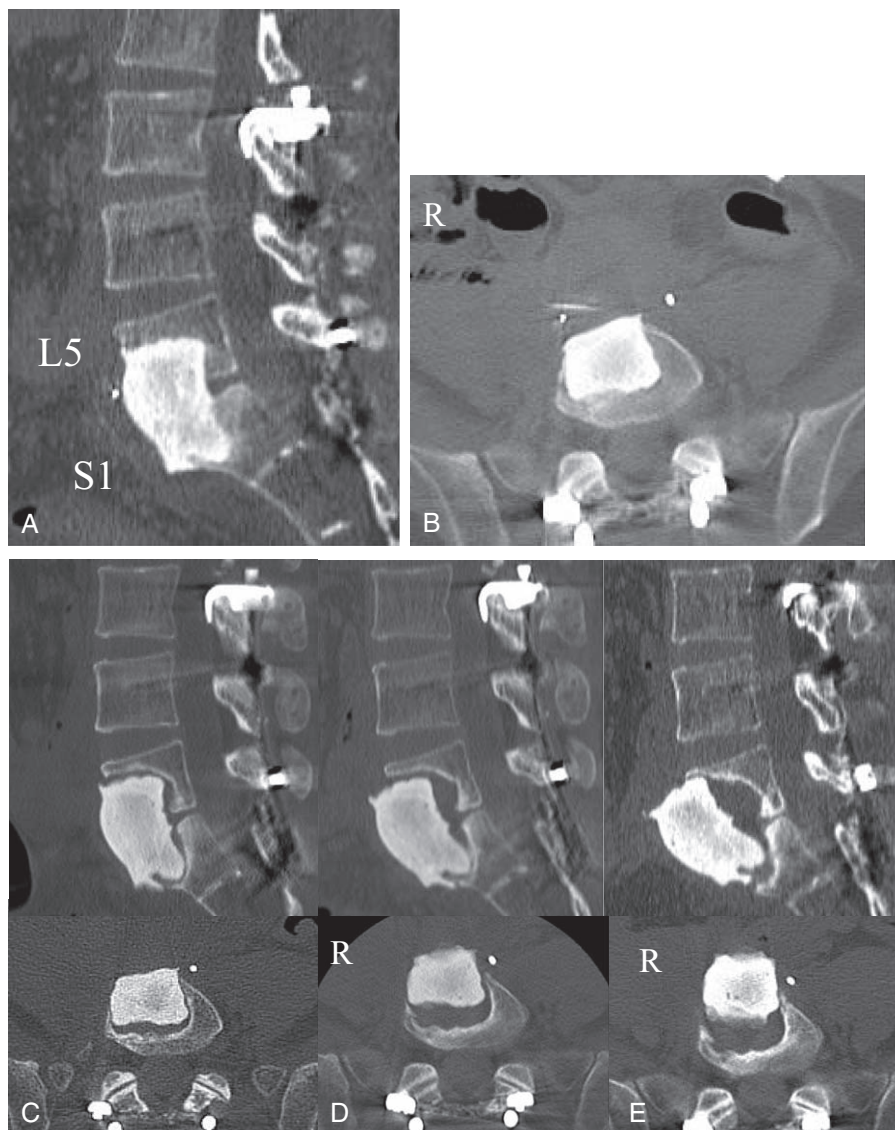
**Figure 4.** Postoperative plain radiographs. After posterior lumbosacral fixation, the tumor was resected and PMMA cement was used for vertebral body reconstruction. Plain radiographs show immediate postoperative (A, B) and postoperative 7 months (C), 27 months (D), and 33 months (E). Over time, the PMMA cement can be seen to move in an anterior direction, and 33 months after surgery, it had dislodged into the retroperitoneum. PMMA = polymethylmethacrylate.

### 3.9. Postoperative course

After surgery, the patient developed aspiration pneumonia, there was urine leakage from the damaged part of the ureter, and deep infection and sepsis developed. Bacterial tests detected *Klebsiella* in blood, methicillin-resistant *Staphylococcus aureus* in urine and *Enterococcus* at the wound site. A vascular surgeon removed the artificial vessels and performed an axillary-femoral artery bypass.

The deep infection and sepsis were successfully treated with antibiotics and no post-infection recurrence was observed. No recurrence of the tumor was observed during the postoperative course.

At postoperative month 7, plain radiographs and computed tomography images showed hypertranslucency of bone surrounding the PMMA cement used to reconstruct the vertebral bodies. Subsequently, PMMA cement was observed to gradually



**Figure 5.** CT findings at postoperative 7 days (A, B), 7 months (C), 24 months (D), and 30 months (E). At postoperative 7 months, CT image showed hypertranslucency of bone surrounding the PMMA cement used to reconstruct the vertebral bodies. Over time, the PMMA cement can be seen to move in an anterior direction. CT=computed tomography.

migrate in an anterior direction and, 2 years 9 months after surgery, dislodged cement was observed to have penetrated the retroperitoneum (Figs. 4 and 5). Magnetic resonance imaging also showed anterior migration of PMMA cement over time and findings at postoperative year 2 suggested adhesion of the dislodged cement to the intestinal tract. The presence of dislodged PMMA cement in the intestinal tract was strongly suspected (Fig. 6). No posterior lumbosacral instrumental looseness or breakage was observed.

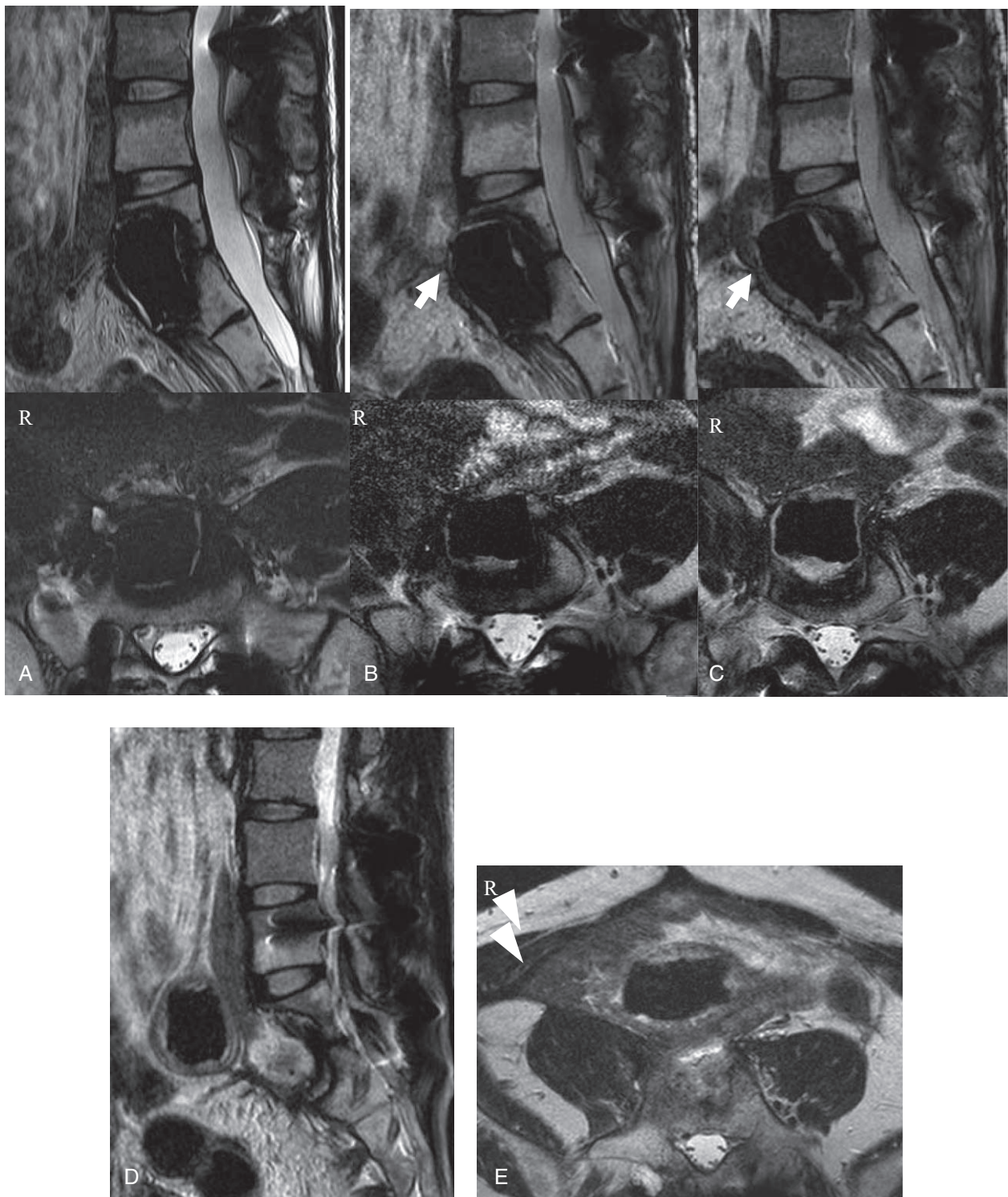
The patient developed nausea and abdominal pain and was readmitted to the hospital. Plain radiographs revealed intestinal gas niveau shadows. From contrast enema images, intestinal blockage with PMMA cement was strongly suspected (Fig. 7). Intestinal blockage due to dislodged PMMA cement was diagnosed, and a gastroenterological surgeon operated to remove the cement using the transperitoneal approach. PMMA cement was palpable in the small intestine, and an incision was made at the same location to remove it (Fig. 8). There was

strong intra-abdominal adhesion, the peritoneum between the vertebral bodies and intestine could not be identified, and it was not possible to perform additional treatment for vertebral body defects. After surgery, the gastrointestinal symptoms resolved. No abdominal symptoms were observed 3 years after removal of the cement and blood tests and image findings showed no evidence of a recurrence of tumor or infection. Image findings also showed no evidence of posterior instrumental looseness or breakage (Fig. 9).

#### 4. Discussion

PMMA cement is often used as prosthetic material to compensate for bone loss after resection of limb bone tumors. In the field of spinal surgery, the use of PMMA cement for percutaneous vertebroplasty in the treatment of vertebral angioma was reported in 1987 by Galibert et al.<sup>[3]</sup> Since then, PMMA cement has been widely used for vertebral body reconstruction along with metal cages following resection of spinal tumors and for

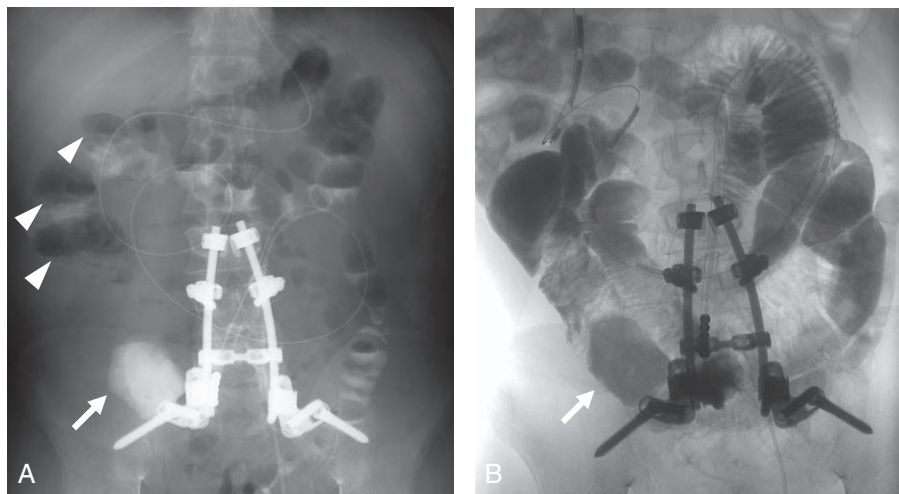




**Figure 6.** MR image findings at postoperative 15 months (A), 24 months (B), 30 months (C), and 34 months (D, E). Arrows indicate suspected adhesion between the migrated PMMA cement and the intestinal tract. Arrowheads indicate dislodged PMMA cement. The presence of PMMA cement in the intestinal tract was suspected. PMMA=polydimethylmethacrylate.

vertebroplasty to treat vertebral fractures.<sup>[1,2,4]</sup> The advantages of PMMA cement include its ability to match the shape of and fill areas of bone defect, the cytotoxic effect on tumor cells that can be expected due to the heat of polymerization during hardening, and its high mechanical strength after hardening.<sup>[18,19]</sup> In the case we examined here, PMMA cement was used directly in the defect of

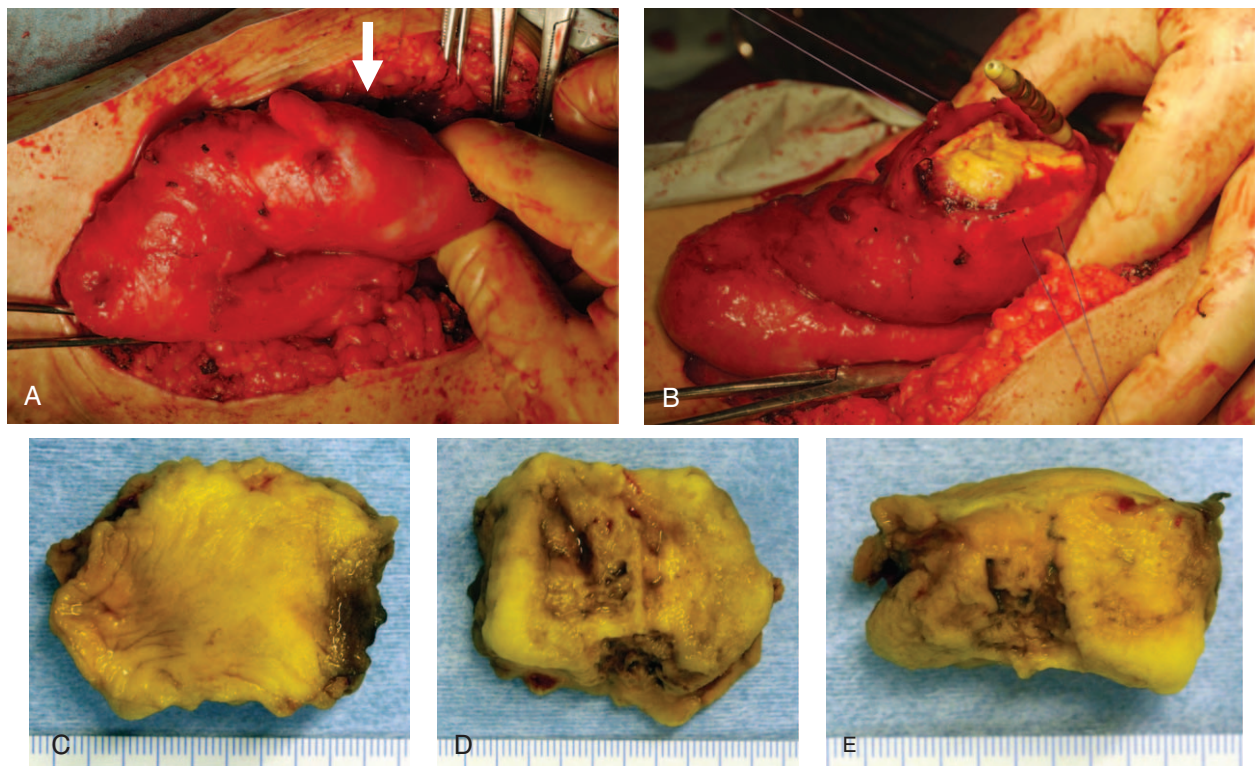
vertebral bodies for both purposes with reconstruction of anterior spinal column and the cytotoxic effect on tumor cells after the resection of tumor. However, it has been reported that, since PMMA cement is mechanically stronger than bone tissue, there is a risk of fracture of reconstructed or adjacent vertebral bodies.<sup>[12,13,20]</sup> There have also been reports of neurological



**Figure 7.** Plain radiograph (A) and contrast enema image (B). Arrowheads indicate niveau images. Arrows indicate dislodged PMMA cement. PMMA cement was suspected to have caused a blockage. PMMA=polydimethylmethacrylate.

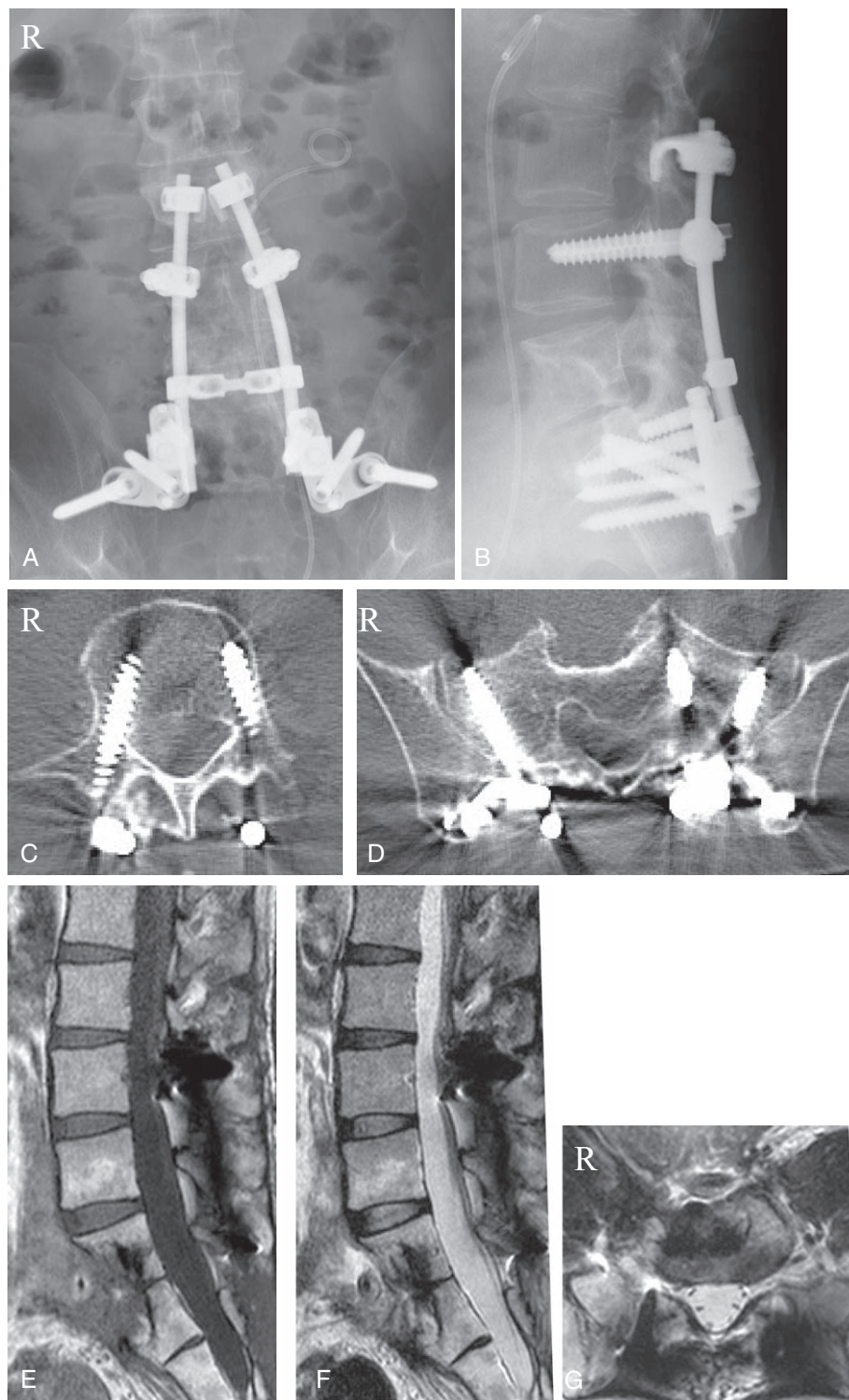symptoms developing due to the leakage and extravasation of cement from vertebral bodies,<sup>[5,15-17]</sup> and the serious complications of pulmonary embolism or cardiac tamponade in the percutaneous vertebroplasty.<sup>[6-9]</sup> For this case, taking into consideration its previously mentioned advantages, PMMA cement was used directly in the defect of vertebral bodies following tumor curettage using an anterior transperitoneal approach. Dislodgement of the cement could have occurred because, even though posterior instrumentation fixation was

used, the fixation force between the L5 and S1 vertebral bodies was insufficient, resulting in persistent mobility in that region. Cement could also have become dislodged due to the influence of postoperative deep infection and the destruction of bone tissue around the cement. Since normal postoperative tumor marker values were maintained and no progression of bone destruction was observed after cement dislodgement, the possibility that dislodgement due to local recurrence of the tumor is unlikely. There have been reports of cases requiring removal of PMMA



**Figure 8.** Findings at the time of PMMA cement removal (A, B). PMMA cement palpable in the small intestine (arrow) (A). An incision was made in the small intestine and the PMMA cement was removed (B). Findings of removed PMMA cement (smallest scale marks are 1 mm) (C, D, E). PMMA=polydimethylmethacrylate.





**Figure 9.** Findings at 3 years after removal of the PMMA cement (A, B, C, D, E, F, G). The frontal (A) and lateral (B) plain radiograph findings. CT findings at the level of L4 (C) and S1 (D). The T1 weighted (E) and T2 weighted (F, G) MR image findings. No evidence of a recurrence of tumor, infection, or posterior instrumental loosening or breakage was observed in all images. CT=computed tomography.

cement that has dislodged from the anterior spine.<sup>[10,14]</sup> This is the first report of dislodged PMMA cement penetrating the alimentary canal. Fujibayashi et al<sup>[21]</sup> reported a case of anterior cervical fixation in which the plate and screws penetrated the esophagus due to insufficient instrumentation fixation and traction on the alimentary canal resulting from postoperative

infection and scar tissue. Furthermore, it has been known that the adhesion of tissues occur after radiotherapy. In the case we examined here, dislodgement of cement and penetration of the intestinal tract could have been due to the lack of mechanical stability of the reconstructed part and the formation and adhesion of scar tissue in the intestines and around the cement



as the result of multiple abdominal operations using the transperitoneal approach, radiotherapy, and postoperative deep infection. It is thought that scar tissue reduced the mobility of the intestinal tract and that there was adhesion of cement and surrounding scar tissue to the intestinal tract, resulting in dislodgement of cement into the intestinal tract, causing a blockage. We concluded that the way of vertebral reconstruction after tumor resection should be selected in consideration of the property of the tumor, mechanical stability and vascularity of the reconstruction area, and the risk of infection, and that the way of anchoring the cement must be thoroughly planned when there is a need to use cement. In this case, we should have performed anchoring for the cement more strongly in the primary reconstructive surgery, and should have used a vascularized bone strut if it was possible to approach the vertebral body in the cement removal surgery, because the patient developed deep infection after the primary reconstructive surgery.

## 5. Conclusions

This was a rare case of PMMA cement dislodged into the intestinal tract and caused a blockage after its use in vertebral reconstruction following resection of a lumbosacral bone tumor using an anterior transperitoneal approach. When using bone cement to reconstruct vertebral bodies, the way of anchoring for the cement must be thoroughly planned to assure there is no dislodgement of cement.

## References

- [1] Eleraky M, Papanastassiou I, Tran ND, et al. Comparison of polymethylmethacrylate versus expandable cage in anterior vertebral column reconstruction after posterior extracavity corpectomy in lumbar and thoraco-lumbar metastatic spine tumors. *Eur Spine J* 2011;20:1363–70.
- [2] Rajpal S, Hwang R, Mroz T, et al. Comparing vertebral body reconstruction implants for the treatment of thoracic and lumbar metastatic spinal tumors: a consecutive case series of 37 patients. *J Spinal Disord Tech* 2012;25:85–91.
- [3] Galibert P, Deramond H, Rosat P, et al. [Preliminary note on the treatment of vertebral angioma by percutaneous acrylic vertebroplasty]. *Neurochirurgie* 1987;33:166–8.
- [4] Barr JD, Barr MS, Lemley TJ, et al. Percutaneous vertebroplasty for pain relief and spinal stabilization. *Spine* 2000;25:923–8.
- [5] Harrington KD. Major neurological complications following percutaneous vertebroplasty with polymethylmethacrylate: a case report. *J Bone Joint Surg Am* 2001;83-A:1070–3.
- [6] Padovani B, Kasriel O, Brunner P, et al. Pulmonary embolism caused by acrylic cement: a rare complication of percutaneous vertebroplasty. *AJNR Am J Neuroradiol* 1999;20:375–7.
- [7] Abdul-Jalil Y, Bartels J, Alberti O, et al. Delayed presentation of pulmonary polymethylmethacrylate emboli after percutaneous vertebroplasty. *Spine* 2007;32:E589–93.
- [8] Togawa D, Bauer TW, Lieberman IH, et al. Histologic evaluation of human vertebral bodies after vertebral augmentation with polymethyl methacrylate. *Spine* 2003;28:1521–7.
- [9] Tran I, Gerckens U, Remig J, et al. First report of a life-threatening cardiac complication after percutaneous balloon kyphoplasty. *Spine* 2013;38:E316–8.
- [10] Tsai TT, Chen WJ, Lai PL, et al. Polymethylmethacrylate cement dislodgment following percutaneous vertebroplasty: a case report. *Spine* 2003;28:E457–60.
- [11] Hamburger C, Festenberg FV, Uhl E. Ventral discectomy with pmma interbody fusion for cervical disc disease: long-term results in 249 patients. *Spine* 2001;26:249–55.
- [12] Lee MJ, Dumonski M, Cahill P, et al. Percutaneous treatment of vertebral compression fractures: a meta-analysis of complications. *Spine* 2009;34:1228–32.
- [13] Grafe IA, Baier M, Noldge G, et al. Calcium-phosphate and polymethylmethacrylate cement in long-term outcome after kyphoplasty of painful osteoporotic vertebral fractures. *Spine* 2008;33:1284–90.
- [14] Lin WC, Lee CH, Chen SH, et al. Unusual presentation of infected vertebroplasty with delayed cement dislodgment in an immunocompromised patient: case report and review of literature. *Cardiovasc Intervent Radiol* 2008;31(Suppl 2):S231–5.
- [15] Bhide RP, Barman A, Varghese SM, et al. A rare presentation of subacute progressive ascending myelopathy secondary to cement leakage in percutaneous vertebroplasty. *Am J Phys Med Rehabil* 2014;93:431–6.
- [16] Teng MM, Cheng H, Ho DM, et al. Intraspinous leakage of bone cement after vertebroplasty: a report of 3 cases. *AJNR Am J Neuroradiol* 2006;27:224–9.
- [17] Lee BJ, Lee SR, Yoo TY. Paraplegia as a complication of percutaneous vertebroplasty with polymethylmethacrylate: a case report. *Spine* 2002;27:E419–22.
- [18] Weill A, Chiras J, Simon JM, et al. Spinal metastases: indications for and results of percutaneous injection of acrylic surgical cement. *Radiology* 1996;199:241–7.
- [19] San Millan Ruiz D, Burkhardt K, Jean B, et al. Pathology findings with acrylic implants. *Bone* 1999;25(2 Suppl):85S–90S.
- [20] Polikeit A, Nolte LP, Ferguson SJ. The effect of cement augmentation on the load transfer in an osteoporotic functional spinal unit: finite-element analysis. *Spine* 2003;28:991–6.
- [21] Fujibayashi S, Shikata J, Kamiya N, et al. Missing anterior cervical plate and screws: a case report. *Spine* 2000;25:2258–61.