



# Iatrogenic peripheral nerve injury: a guide to management for the orthopaedic limb surgeon

Timothy Bage  
Dominic M. Power

- Nerves may be inadvertently injured during trauma surgery due to distorted anatomy, traction applied to a limb, soft tissue retraction, by power tools, instrumentation and from compartment syndrome. Elective orthopaedic surgery has additional risks of joint dislocation for arthroplasty surgery, limb lengthening, thermal injury from cement and direct injury from peripheral nerve blocks.
- The true incidence is unknown, and many cases are diagnosed as neurapraxia with the expectation of a full and timely recovery without the need for intervention. The incorrect assignation of a neurapraxia diagnosis may delay treatment for a higher grade of injury and in addition fails to recognize that a diagnosis of neurapraxia should be made with caution and a commitment to regular clinical review. Untreated, a neurapraxia can deteriorate and result in axonopathy. The failure to promptly diagnose such a nerve injury and instigate treatment may result in further deterioration and expose the clinician to medicolegal challenge.
- The focus of this review is to raise awareness of iatrogenic peripheral nerve injuries in orthopaedic limb surgery, the importance of regular clinical examination, the role of investigations, timing and nature of interventions and also to provide a guide to when onward referral to a specialist peripheral nerve injury unit is recommended.

**Keywords:** iatrogenic; nerve injury; orthopaedic surgery

Cite this article: *EFORT Open Rev* 2021;6:607-617.

DOI: 10.1302/2058-5241.6.200123

## Introduction

Estimates suggest that between 8% and 25.4% of all peripheral nerve injuries (PNI) may be as a direct response of medical intervention.<sup>1,2</sup> Orthopaedics is the surgical sub-specialty that is associated with the highest rates of iatrogenic injury to peripheral nerves, reflecting the nature of injury and disease in the axial skeleton and

limbs, the surgical proximity to the nerves and the techniques involved in surgical reconstruction.<sup>3</sup>

Nerve injuries may be devastating for patients and can result in sensory loss, paralysis and pain. Deficits may be permanent with severe functional, psychological and socioeconomic implications for their victims.<sup>2,4</sup> When a nerve injury is the direct result of a surgical intervention, there is a secondary impact on the clinician which is often overlooked. There may be medicolegal ramifications and a loss of confidence with a sense of guilt, termed the second victim phenomenon.<sup>5,6</sup>

As such, it is the purpose of this article to highlight the key principles of recognition and management for iatrogenic peripheral nerve injuries of the limbs – iatrogenic injuries of spinal surgery are not within the scope of this paper. This review will consider why orthopaedics is so frequently associated with these injuries, why these injuries are commonly mismanaged and will discuss methods of reconstruction.

Early recognition of a peripheral nerve injury is essential.<sup>7</sup> Prompt and appropriate intervention may prevent further deterioration, reduce the risk of neuropathic pain sensitization and improve the chance of a meaningful recovery for a mixed or motor nerve. Repeated, thorough clinical examination is the key to diagnosis.<sup>7</sup> Orthopaedic surgeons must possess a detailed knowledge of musculoskeletal and neurovascular anatomy,<sup>7</sup> the pathophysiology of nerve injury, have procedural training for a particular intervention as well as technical skill. An understanding of specific procedural profiles, potential injury mechanisms, common anatomical sites and risk-reduction strategies help to avoid injury.

A failure to adequately examine a patient pre-operatively, particularly in the setting of trauma surgery, may lead to false accusations of a peri-operative injury. The incorrect assertion that a peri-operative nerve injury is a low-grade neurapraxia due to inadequate clinical assessment may delay the required intervention, negatively impact the final outcome, deepen clinician–patient mistrust and increase the potential for litigation. Prompt

recognition, acknowledgement, mitigation and an apology are key steps in maintaining trust. In complex cases requiring reconstruction or in cases where there is the potential for breakdown of the clinician–patient relationship, onward referral to a specialist peripheral nerve injury unit (PNIU) is recommended. The assessment is specialist, independent and non-judgemental. The patient will be reassured that the referring orthopaedic surgeon has the patient's recovery as the primary objective and there is reassurance for the patient that these injuries are both common and treatable. There is necessary transparency and objectivity by removing the surgeon responsible for the injury from the subsequent decision-making process regarding the need for further surgical intervention, when there may be unconscious bias that affects judgement. However, the primary clinician must not be marginalized. An open tripartite relationship with clear communication is key and in the best interests of all. Patients typically feel vulnerable, anxious, frustrated, angry and scared. Recognizing that these feelings are normal and supporting patients on their journey to recovery is essential. Blame and accusations of malpractice are not helpful, create conflict, negatively impact communication and may delay future referrals. It is rare that a clinician–patient relationship is unsalvageable. In such cases a second opinion from a sub-specialty orthopaedic colleague can support the primary clinician, the peripheral nerve injury specialist and the patient.

The nerve specialist will help to determine the site of injury, the pathophysiological grade of injury and the need for exploration.<sup>5</sup> Surgical exploration is sometimes required to provide an accurate diagnosis and prognosis. There is limited diagnostic utility in electrophysiological studies and in imaging studies. The primary clinician commonly diagnoses a neurapraxia, anticipating a full and timely recovery. They may be disinclined to recommend surgery when the indication is based on opinion rather than objective neurophysiological and imaging evidence of an injury, or when concerned about an unnecessary procedure and the risk of introducing infection to a recently implanted arthroplasty or fracture implant. The exploration should be planned after communication with the primary surgeon because in some situations there is a requirement for revision of the fixation or arthroplasty in order to improve the potential for recovery in the affected nerve.

### Orthopaedic trauma surgery

Nerve injuries are an inevitable consequence of trauma. Closed injuries may result in traction with axonal rupture or rupture of the nerve sheath, nerves may be lacerated by bone fragments or compressed from joint dislocations, limb malalignment or haematoma. Penetrating wounds

may directly injure the peripheral nerves. The orthopaedic surgeon must recognize these injuries at presentation to guide prompt and appropriate intervention and avoid the mislabelling as a peri-operative iatrogenic injury. Examination may be challenging due to intoxication, reduced consciousness, poor compliance, pain, splint or cast immobilization of the injured limb and operational issues. A thorough examination should be documented in the medical record and communicated to the treating team. The patient should be informed of any abnormal findings, the implications for rehabilitation and the prognosis. Early diagnosis of a nerve injury may alter the management plan. Nerves may require exploration, decompression and associated fractures may be stabilized, even when there is potential for spontaneous fracture healing without operative stabilization. The operating surgeon must examine the patient and determine the site and grade of nerve injury prior to surgery. Failure to adhere to these simple guidelines may result in mislabelling traumatic nerve injuries as iatrogenic, failure to explore and decompress a critically injured nerve and missing an opportunity for management of the fracture and the nerve in the same procedure. A high-grade radial nerve rupture can be debrided and primarily repaired after acute shortening the humerus at the level of a diaphyseal fracture, thereby avoiding the need for a later exploration and nerve graft.

Trauma surgery poses a specific risk of iatrogenic nerve injury. Anatomy is distorted due to fracture malalignment, haematoma, bleeding and associated soft tissue injuries. Normal soft tissue planes are disrupted and the typical inter-nervous approach to a bone or joint widely practised in orthopaedic surgery may not be possible due to soft tissue disruption. In the polytrauma patient requiring damage limitation stabilization surgery, utilizing second-line approaches so that concomitant limb injuries can be managed concurrently can generate a risk of nerve injury due to limited access and surgeon unfamiliarity. The surgeon may use traction to overcome limb shortening and to restore alignment in preparation for fixation.<sup>3,8,9</sup> Indirect injury results, typically with a disruption of the axons with preservation of the nerve sheath continuity. Direct nerve injury may from the use of intra-operative positioning, tourniquets, the surgical approach, mistaken anatomy,<sup>11</sup> from diathermy burns, entrapment within fracture at the time of reduction, retraction, power tools, misplaced metalwork, from external fixation pins and wires. Minimally invasive procedures add a further level of risk by not allowing for any direct visualization of the surrounding structures.<sup>2,9</sup> Post-operative injury may occur from tight dressings or splints, pressure from a haematoma or compartment syndrome.<sup>6</sup>

A classification framework for iatrogenic peripheral nerve injuries has been proposed, which can be summarized as such:<sup>8</sup>

- Type 1 iatrogenic peripheral nerve injury: This is when the nerve injured was not the target of treatment – for example through operating in close proximity to the nerve or inexperience/poor technique.
- Type 2 iatrogenic peripheral nerve injury: This type of injury is when the nerve injured was the target of the therapy/procedure. An example of this would be an iatrogenic injury during nerve decompression such as carpal tunnel release.
- Type 3 iatrogenic peripheral nerve injury: Type 3 injury occurs when the nerve is damaged when it was a target for the repair of a different nerve – such as during nerve harvest for grafting.

As such, the majority of iatrogenic peripheral nerve injuries sustained during orthopaedic trauma surgery would be classified at Type 1.

### Orthopaedic elective surgery

Operating in a more controlled environment, procedural familiarity and using well defined anatomical planes reduce the risks of iatrogenic PNI. Small cutaneous nerves are at risk during skin incisions. Anomalous anatomy, bleeding and complex operations can contribute to the risk profile for deeply placed mixed nerve trunks. Elective surgery using minimally invasive approaches risks injury to nerves at the ends of the incision where retraction is greatest and visibility most reduced. Osteotomies risk transection injury to a nerve passing posterior to the bone. Orthopaedic techniques utilize retractors posterior to bone to protect neurovascular structures; however, unseen, they may crush a nerve or be positioned too deeply in the wound, leaving the nerve between the retractor and the saw blade or drill.

Arthroplasty surgery requires joint traction and joint dislocation. Unless properly mobilized, nerves may be under excessive tension. Lengthy procedures increase the risk of traction, compression and vascular injury to the nerve. Complex arthroplasty for joint dysplasia may require restoration of length and alignment, creating neo-tension on a neurovascular bundle. Malpositioned implants can directly compress or distort a nearby nerve. Sciatic nerve compromise is associated with over sizing of the acetabular component, excessive retroversion and lengthening of the lower limb. An anomalous peroneal component traversing the piriformis may be tethered and, due to its reduced calibre, may be more vulnerable than the tibial component, perhaps explaining the more severe involvement of the peroneal component in cases of arthroplasty-associated iatrogenic sciatic nerve injury.

The use of bone cement with an exothermic polymerization reaction can pose a risk of direct thermal injury when uncontained or used in proximity to a nerve. Correction of

severe valgus deformity at the knee can expose the common peroneal nerve to traction injury and compression against the fibula neck within the peroneal tunnel.

Arthroscopic surgery involves a risk to cutaneous nerves during portal placement. Joint penetration with power shavers may risk injury to nerves lying in close proximity to the capsule. A temporary loss of view due to bleeding or disruption of irrigation fluids increases the risk. More complex soft tissue stabilization procedures are now possible using these minimally invasive arthroscopically assisted techniques. The peroneal nerve is at risk during repair of posterior tears in the lateral meniscus, the saphenous nerve for a medial meniscus, the posterior interosseous nerve for lateral elbow release and the brachial plexus for arthroscopic Laterjet procedures. The unfamiliarity of the surgeon, the learning curve and the risk of distorting normal anatomy increase the risk of PNI.

Spinal surgery is a particularly high-risk sub-specialty, reflected in the high indemnity fees for clinicians. The spinal cord and the exiting nerve roots are both vulnerable to injury. Direct injury may occur during laminectomy and lateral decompression of the root beneath the facet joint or traction of nerve roots during disc removal. Injury from a pedicle screw breaching the cortex and over correction of deformity are rare but severe complications. Table 1 describes some of the common injury mechanisms and Table 2 the high-risk procedures for PNI in orthopaedic surgery.

### Anaesthesia for orthopaedic surgery and peripheral nerve injury

The use of neuromuscular blockade will remove the warning twitch from excessive retraction on a nerve, direct injury or cautery in close proximity. The use of peri-operative

**Table 1. Iatrogenic peripheral nerve injury mechanisms in orthopaedic surgery**

---

Drill-bits can penetrate or avulse nerves, especially when the course of the nerve runs unsighted behind the segment of bone being operated upon.
Wires can tether nerves reducing physiological glide.
Implants can impinge peripheral nerves.
Thermal injury may follow electrocautery and polymerization of bone cement.
Retraction of nerves, especially for prolonged periods, causes compression damage.
Sutures and bone fragments can cause nerve compression or tether.
Haematoma may compress nerves.
Nerves can be entrapped within fractures.
External fixation pins can cause direct injury.
Lengthening of bones by arthroplasty can cause stretch injury.
Dislocation for joint surgery or traction for fracture/dislocation reduction can cause nerve entrapment, compression or traction.
Positioning without thought to limb protection in theatre can cause stretch or compression injury.
Cutaneous nerves can be injured with arthroscopy portals and with skin incisions.
Nerve blocks can cause direct nerve trauma, compression, bleeding, intra-neural injection toxicity to nerve.
Spinal surgery can compromise nerve roots.

---

**Table 2.** Common iatrogenic peripheral nerve injuries in orthopaedics

	Nerve	Risk procedures	Risk-reduction techniques
<b>UPPER LIMB</b>	<b>Brachial plexus</b> (Predominantly C5/6 trunks, upper trunk, lateral cord, suprascapular, supraclavicular)	Clavicle fixation esp. delayed	Early reduction (< 48 hrs) of displaced clavicle fractures. <sup>24</sup>
	<b>Axillary</b>	Proximal humerus ORIF	Pass proximal humerus plate deep to axillary nerve to allow visualization above. <sup>2</sup>
		Shoulder manipulation for dislocation	Assess fully for neurological deficit prior to reduction. Perform reduction within 12 hrs of injury. <sup>25</sup>
		Scapular ORIF	The use of inter-muscular windows in the Judet approach. <sup>26</sup>
	<b>Radial</b>	Shoulder stabilization	
		Humeral shaft ORIF	Exposure and protection of nerve throughout ORIF. <sup>2</sup> Variety of exposures provided by posterior approaches. Observe lateral fixation 'safe zone'. Place pins less than 100 mm from lateral epicondyle and as posterior as possible. <sup>27</sup>
	<b>Superficial sensory branch of radial</b>	Distal radius ORIF	Avoid transverse incisions in the anatomical snuffbox between 2.5 and 3.9 cm from Lister's tubercle. <sup>11,28</sup>
		DeQuervain's release	Literature divided though most suggest longitudinal incision techniques safer. <sup>29</sup>
	<b>Ulnar</b>	K-wire fixation of supracondylar humerus fractures	Direct visualization of ulnar nerve during insertion and removal of K-wires/metalwork. <sup>2</sup>
		Elbow arthroscopy	
	<b>Dorsal branch of ulnar nerve</b>	Ulnar head fixation	Ulnar late placement between 10 and 12 o'clock on the right wrist and 12 and 2 o'clock on the left in relation to the ulnar styloid. <sup>30</sup>
		Wrist arthroscopy	Avoid setting 6U portal under traction with arm passively pronated. <sup>31</sup>
	<b>Median</b>	K-wire fixation of supracondylar humerus fractures	Placement of medial wire through mini-medial approach. <sup>32,33</sup>
		Carpal tunnel release	Expertise knowledge of anatomy, normal variants and optimal skin incisions. <sup>1</sup>
<b>Palmar branch of median</b>	Volar plate fixation of distal radius	Knowledge of relevant anatomy and variants. Careful placements of retractors. <sup>34</sup>	
<b>Musculocutaneous</b>	Latarjet procedure	A protocol to reduce peri-operative nerve stretch has been suggested. <sup>35</sup>	
<b>Posterior inter-osseous</b>	Proximal radius ORIF Biceps reattachment Elbow arthroscopy	Boyd approach by subperiosteal elevation of supinator protects the nerve.	
<b>LOWER LIMB</b>	<b>Sciatic</b>	Total hip replacement (posterior approach)	Correct identification of high-risk (hip dysplasia, revisions) patients. Caution during joint manoeuvres to avoid excessive strain. Attention to drill-bit depth.
	<b>Femoral</b>	Total hip replacement (anterior approach)	
	<b>Common peroneal</b>	Lateral meniscal repair	Use inside techniques.
		Total Knee Replacement	Identify and protect nerves if outside assisted sutures required
	<b>Tibial</b>	Total Knee Replacement	
		Knee arthroscopy	Oblique or transverse portal incisions with the knee in flexion. <sup>2</sup>
	<b>Infrapatellar br. of saphenous</b>	Hamstring tendon harvest	Attempt to palpate on passive flexion of 4th toe – identify for planning portal incisions. <sup>2</sup>
		Ankle arthroscopy	Safe incision 12 mm posterior to anterolateral border of fibula at 100 mm proximal to the tip to 10 mm posterior to the anterolateral border at 5 cm proximal to the tip. <sup>36</sup>
	<b>Superficial peroneal</b>	Distal fibula ORIF	Cautious stab incisions and adequate exposure of nerve during procedure. <sup>37</sup>
			Higher risk of injury if sinus tarsi approach used within 6 days of injury. <sup>38</sup>
<b>Sural</b>	Percutaneous Achilles tendon repair Calcaneus ORIF	A mid-medial incision at the junction of plantar and dorsal skin. <sup>39</sup>	
<b>Medial dorsal cutaneous</b>	Hallux valgus correction		

regional anaesthetic (RA) nerve blocks does not remove the stimulation response as long as the segment blocked is proximal and remote to the site of surgery. The risk with RA nerve blocks of direct nerve injury is low, and although estimated at 1:10,000, our own experience is that the rate of a prolonged conduction block or intra-neural injection is higher.<sup>9</sup> The use of ultrasound and nerve stimulation

reduce the risk of injury. Awake blockade, prior to general anaesthesia is recommended, although less commonly practiced due to patient discomfort. The primary risk from RA is the failure to diagnose a nerve injury in the immediate post-operative period due to either masking of the nerve injury by the RA or, more commonly, to wrongly ascribing a paralysis to the effects of the RA block and not

considering a PNI diagnosis. Most RA blocks should wear off fully between 12 and 24 hours. Persistence of a deficit beyond this period, especially with the development of neuropathic pain, should serve to warn the surgical team of a potential peri-operative PNI.

## Pathophysiology of peripheral nerve injury

Seddon defined three classes of PNI: neurapraxia (transient conduction block), axonotmesis (loss of axon with some preservation of nerve sheath continuity) and neurotmesis (an anatomical or complete functional division of the nerve and sheath).<sup>11</sup> Severe sheath disruption with no spontaneous recovery and formation of neuroma in continuity is a functional neurotmesis. Wallerian degeneration is a feature in axonotmesis and neurotmesis injury with a common mixed injury defined by features of both neurapraxia and axonotmesis, such that some early recovery is seen by approximately three months and then further recovery defined by axonal regeneration along the distal nerve stump.

Understanding of the variable outcomes from axonotmetic injuries was expanded through the Sunderland classification.<sup>12</sup> Less severe injury to the connective tissue components of the nerve sheath result in more rapid and complete regeneration. More severe sheath disruption with perineurium involvement led to no functional recovery and an effective neuroma in continuity.

Lundborg and Dahlin<sup>13</sup> and others have further defined the pathoanatomy of the neurapraxic injury, using the term conduction block to explain the integrity of the axon with a physiological block to conduction. Higher grades of neurapraxia are seen when there is damage to the myelin sheath. This type of injury is termed prolonged conduction block (PCB) and will preferentially affect the large

diameter myelinated alpha nerve fibres responsible for fast pain, temperature, light touch and motor function. Smaller calibre unmyelinated axons will continue to function and so in such cases there is preservation of the vasomotor and sudomotor autonomic function with some preservation of slow pain C fibre conduction.<sup>14</sup> Recovery of full conduction in the PCB injury requires absorption and regeneration of the myelin sheath and takes around three months, at which point full functional recovery is to be expected (Table 3).

## Clinical assessment after peripheral nerve injury

Repeated clinical assessment is key to the diagnosis of a PNI in terms of anatomical location and pathophysiological severity. The diagnosis should be suspected with unexplained sensory loss and/or motor paralysis in the distribution of a peripheral nerve following a surgical intervention. Neuropathic pain is the hallmark of axonal damage with Wallerian degeneration and in such a situation it is erroneous to use the term neurapraxia, which implies a physical and functional nerve cell continuity with a conduction block. Many neurapraxic injuries will recover spontaneously and, as a consequence, the false use of this term will usually lead to underestimation of the severity of the injury, result in complacency and delay referral for definitive treatment. Some cases of neurapraxia may fail to recover spontaneously or may even deteriorate due to a persisting poor nerve environment. Surgery can be beneficial in such cases where repeated clinical assessment detects a persistence or deterioration of the deficit. Due to the poor understanding of the term and the incorrect assumption that neurapraxia does not require action, we would recommend the term is dropped from common

**Table 3.** Classification of peripheral nerve injuries

	Pathology	Clinical signs	Neurophysiology findings <sup>16</sup>	Recovery potential
<b>Neuropraxia</b>	Conduction block only	Paraesthesia Preservation of sudomotor and vasomotor function	<b>NCS:</b> CMAP and SNAP show focal conduction block at site of lesion, but preserved distally. Persists until recovery. <b>EMG:</b> +/- fibrillations, reduced motor unit action potentials	Full, spontaneous within 3 months.
<b>Axonotmesis</b>	Division of axons with Wallerian degeneration Connective tissue remains intact	Dysesthesia  Allodynia Neuropathic pain Advancing Tinel's sign Loss of vasomotor and sudomotor function resulting in dry and red skin with loss of sweating	<b>NCS:</b> Loss of CMAP and SNAP by 2 weeks <b>EMG:</b> Fibrillations (10–30 days for full development)	Dependent on status of supporting structures. May be good, spontaneous at a rate of 0–3mm/day depending on severity. May require surgery.
<b>Neurotmesis</b>	Complete division of nerve	Neuropathic pain  Paralysis Anaesthesia Loss of vasomotor and sudomotor function resulting in dry and red skin with loss of sweating	<b>NCS:</b> Loss of CMAP and SNAP by 2 weeks <b>EMG:</b> Fibrillations (10–30 days for full development)	None without surgical intervention.

Note. Nerve Conduction Studies (NCS), Compound Muscle Action Potential (CMAP), Sensory Nerve Action Potential (SNAP), Electromyography (EMG), .

usage and replaced with the term PCB when there is no evidence of axon degeneration on clinical examination.

Axonal discontinuity with Wallerian degeneration distal to the site of injury is a feature of mixed, axonopathic and neurotmetic injuries. In such cases pain is common. There is usually a positive Tinel's sign. This is elicited by gently tapping over the nerve at the site of suspected injury. Dysaesthesia and paraesthesia are experienced in the cutaneous territory of the sensory or mixed nerve under test. In a case of suspected neurapraxia, development of a positive Tinel's sign should lead to questioning the original diagnosis or could represent a deterioration of a previous conduction block injury due to a persistence of the injuring environment. During the follow-up period after a PNI, tapping from distal to proximal along the course of a nerve can demonstrate evidence of more than one point of Tinel's, indicating a nerve that is recovering. The distance between the Tinel's points and the time elapsed will provide a rough guide to the regeneration rate, and therefore the severity of the injury. A Sunderland grade 4 and 5 injury will demonstrate no progression of the Tinel's sign. A grade 3 injury will progress at no more than 1 mm per day. However, a Sunderland grade 2 or a low-grade Seddon axonotmesis may regenerate at 2–3 mm per day. Satisfactory and sustained regeneration in the setting of mild or resolving neuropathic pain can be monitored. A slowing of Tinel's sign progression, increasing pain or diagnostic uncertainty are indications for exploration. Hyperalgesia and allodynia are common symptoms that can suggest partial nerve transection.<sup>15</sup>

When there is dry skin with erythema in the cutaneous territory of an injured sensory or mixed nerve, there is disruption of the small unmyelinated autonomic sudomotor and vasomotor fibres. Developing these objective signs should warn the clinician that a prior PCB/neurapraxia diagnosis should be reconsidered. These signs provide objective evidence of at least an axonotmesis injury and possible a neurotmesis injury. This test can be useful in patients who are unable to communicate, such as those on critical care. Resolution of the autonomic dysfunction usually predates useful motor and sensory recovery due to the fast rate of regeneration in these fibre sub-types. In a mixed grade of injury there may be some preservation of function within a nerve trunk or early resolution of the PCB component. At three months the extent of the axonotmetic injury will be apparent. There are barriers to clinical examination including casts, splints and recent surgical wounds. Despite these it is still possible to gain useful information with a measured and systematic approach to examination.

## Review of records

An important role for the clinician faced with a potential diagnosis of an iatrogenic injury to a peripheral nerve is to

review all pertinent medical records. These should include the indications for surgery, the pre-operative condition, the operation records, anaesthetic records, post-operative inpatient and outpatient records, therapy reports, pain specialist reports and any investigations including radiology and neurophysiology. Typically, there will be a clear temporal relationship to the surgical intervention. The grade and experience of the operator should be noted as well as any intra-operative difficulties. The progression of the PNI from the time of surgery should be established to determine improvement, deterioration or persistence of the deficit.

## Investigations for peripheral nerve injury

### *Imaging*

Adequacy of fixation and any protruding metalwork on radiological imaging should be noted, and further imaging requested if indicated. In the setting of arthroplasty, the position of the implant and any alteration of limb length or alignment should be noted.

Imaging of the nerve is seldom helpful. High-resolution ultrasound is capable of demonstrating preserved fascicular structure and revealing cross-section diameter and nerve glide in superficially placed nerves. The investigation is readily available, cheap and non-invasive. It is not subject to significant signal distortion from metalwork. Early assessment may be limited due to the surgical wound and local pain. Interpretation of the findings is subject to local availability of experience and expertise. Magnetic resonance imaging (MRI) neurography shows promise, however, proximity to implants may limit its utility.<sup>16</sup> One of the key roles of imaging is to exclude a haematoma that may be compressing neurovascular structures, however, in our experience, surgical inspection of the site of suspected injury is often required and investigations may sometimes delay surgery which is otherwise indicated.

### *Neurophysiology*

Neurophysiological studies include nerve conduction studies (NCS) and electromyography (EMG). They have important roles in localizing a PNI and determining the severity of injury. They may be used to monitor spontaneous recovery or the response to treatment. A guide to the interpretation of the electrophysiological studies is shown in Table 3. The current teaching suggests erroneously that EMG is best performed 6–8 weeks after surgery, and certainly not before 7–10 days since falsely reassuring results may occur due to the fact that Wallerian degeneration has not yet completed.<sup>2,15,17</sup> Early EMG as soon as the nerve injury is identified may be normal; however, a repeated study at two weeks demonstrating a deterioration with no volitional activity, a reduction in Sensory Nerve Action Potential (SNAP) and Compound Muscle Action Potential (CMAP) with muscle fibrillation is diagnostic of

axonopathy and the injury is at best a mixed injury with some axonotmesis or at worst a neurotmesis.<sup>17</sup> Early intervention can then be advised rather than the current teaching where abnormal NCS and EMG findings at 6–8 weeks typically result in further studies at 3–4 months, delaying referral and warranted intervention. A further assumption is that the injury happened at the time of surgery. This may indeed be the case; however, an initial neurapraxic/PCB injury can, if untreated, deepen with axonopathy and Wallerian degeneration. Recognizing that this is a possibility and repeating the clinical assessment, documenting neuropathic pain, looking for dry skin and erythema plus the development of a Tinel's sign are more useful than neurophysiology studies which may provide some false reassurance in the setting of a mixed nerve injury. The role of EMG studies for monitoring recovery after a PNI is undisputed. Acute denervation with increased insertional activity, positive sharp waves and fibrillation will be replaced by polyphasia and large motor units following reinnervation. The presence of fibrillation potentials defines a muscle still receptive to functional reconstruction of the nerve.<sup>2</sup>

### Decision-making after iatrogenic PNI

The patient should be informed of the possibility of a PNI as soon as it is suspected. Specific interventions can be immediately implemented including loosening casts and circumferential dressings. The BOAST 5 guidelines have been written to assist the orthopaedic surgeon in the management of the suspected PNI. The guidelines are clear, however, that investigations should never delay early intervention if indicated.<sup>6</sup> More often the need for surgical exploration is less clear and, rather than risk delay, in such cases an opinion can be sought from one of the regional centres specialized in the management of PNI. Early referral removes the pressure of decision-making regarding intervention from the primary clinician. However, it is our experience that discussing the case in detail and, if co-located, offering to undertake the exploration as a combined case, avoids undermining the patient's confidence in their treating clinician and fosters an openness and dialogue that results in prompt early referral of future patients with suspected iatrogenic PNI.

When a decision is made that there is no urgent need for re-exploration, perhaps in the absence of severe neuropathic pain, some evidence of at least partial nerve continuity or a recovering lesion, the PNI specialist who makes that judgment is mandated to perform a regular close clinical follow-up of the patient, perhaps initially at bi-weekly intervals. This enables further discussion of the diagnosis and implications with the patient, establishes deterioration or recovery early and enables the timing of any intervention to be optimized, for instance when a

wound has healed sufficiently to minimize the risk of secondary infection at the site of the orthopaedic implant.

### Communication

It is important that the referrer provides as much information as possible to assist the PNI specialist in their assessment of the patient. A copy of the operation notes should be provided with a description of any nerve injury if identified. The type and manufacturer of any implants should be provided in case of need for removal or replacement. Anaesthetic records are necessary to assess the impact of any anaesthetic agents or regional blocks, as previously mentioned, as well as helping to identify any immediate post-operative pain issues in the recovery room. Should any imaging or neurophysiology have been undertaken prior to referral to the peripheral nerve service, then this should be included also as they may shed light on the site of the lesion and provide some aid in pre-operative planning.

Honest and effective communication with the patient is essential. The General Medical Council and Royal College of Surgeons guidance is very clear on the matter of 'duty of candour'<sup>18</sup> and clearly explaining the possibility of iatrogenicity to the patient, and the steps that will be taken to rectify it, is imperative. There is also mounting evidence to suggest that an honest and apologetic approach to medical mistakes makes patients less likely to seek legal advice for complaints.<sup>12</sup>

In the post-operative setting, unexplained severe pain may result in mistrust between the patient and the surgeon. A failure to consider a nerve injury, even to a small cutaneous nerve, leaves the surgeon frustrated and suspicious of malingering behaviour on the part of the patient, while the patient feels that their concerns are not being listened to. Examining the patient is essential and if doubt persists, seek an opinion from a PNI unit where the clinicians are experienced in the management of such cases.

### Surgical interventions after peripheral nerve injury

There is on occasion an intra-operative recognition of an iatrogenic nerve injury. Discussion with the regional PNI unit at this stage is helpful. In specific circumstances a change to the operative plan can facilitate management of the nerve injury. Shortening of a fracture of the humerus can facilitate debridement and direct repair of a radial nerve. Transposing the ulnar nerve at the elbow may reduce the tension across an acute ulnar nerve repair. When a peripheral nerve surgeon is not available, tacking the cut edge of the nerve epineurium with a 4-0 non-absorbable monofilament coloured suture is recommended. This allows ready identification during re-exploration but minimizes the risk of further nerve injury.

In the setting of a suspected iatrogenic PNI identified during the post-operative period, the decision to operate should be based on the clinical findings. The first role of surgery is to achieve a diagnosis for the nerve with a suspected injury. Early diagnosis of a nerve transection enables definitive reconstruction to be performed. However, in the majority of cases, there is a continuity of the nerve sheath at the site of suspected injury. Intra-operative neurophysiology can determine whether there is any axonal continuity across this site. The challenge is to determine the prognosis for the nerve and an early exploration may pre-date the formation of a neuroma in continuity and it is likely that the lesion will be given the benefit of the doubt and subsequently monitored. Confirming the site and extent of injury removes some uncertainty and, in the setting of failure of progression, re-exploration can be contemplated as required. It is this uncertainty that creates a challenge in defining a key parameter for exploration for any nerve injury. When there is neuropathic pain and the nerve may be tethered or compressed, the risks of exploration are low and the environment for the nerve can be improved. The peripheral nerve injury specialist is best positioned to perform this assessment as they will be responsible for the subsequent management of the injury.

The surgical exploration is aimed at identifying the site and severity of the nerve injury. The nerve can be decompressed if compressed by haematoma, a displaced fracture fragment, fascia or callus. When a joint is dislocated or a limb misaligned, the surgical reduction will restore anatomical alignment protecting the nerve from further injury (Table 4). Neurolysis involves freeing a tethered or constricted nerve from scar. In the setting of neuropathic pain, with exacerbation on passive motion (neurostenalgia) or with pseudoparalysis, neurolysis can result in dramatic functional and symptom improvement. Adjunctive nerve wrapping may improve the local vascularity and minimize the risk of recurrent scar tether. Resurfacing with autologous fasciocutaneous flaps is helpful when the soft tissues are poor and when the injured nerve is superficial and sensitized. Autologous adipofascial flaps, synthetic bioresorbable polymer and collagen wraps are useful adjuncts for a peripheral nerve surgeon.

**Table 4. Indications for surgery in suspected peripheral nerve injury**

Indications for surgery in suspected peripheral nerve injury
Diagnosis
Decompression
Displaced fracture fragments
Delayed reduction of dislocation
Deterioration under observation
Delay in recovery
Develops dry skin
Debilitating nerve pain
Doubt

When an injury is identified with a nerve transection, partial nerve division or a neuroma in continuity, some form of reconstruction is required. In the majority of cases this will necessitate excision of the neuroma to healthy proximal and distal fascicle stumps and bridging the consequent gap with nerve graft. Rarely, direct repair can be performed; however, any tension at the repair site may result in further intra-fascicular fibrosis and a barrier to successful axon regeneration. The options for nerve grafting are autologous reversed sensory nerve or processed nerve acellular allograft. The use of autologous graft creates another site of deficit at the donor site and potentially a risk of painful neuroma formation at the proximally transected nerve. The sural nerve is used for large mixed nerve reconstruction and a series of cables can be used to build up the nerve due to the diameter mismatch. These can be sutured into place with 9-0 nylon and supported with fibrin glue. Decellularized allograft is an attractive alternative solution and requires no immunosuppression. There is no donor deficit, however, there is considerable expense involved. The evidence to support nerve allograft is more limited in mixed nerve reconstruction than for small peripheral sensory nerve reconstruction, where in gaps of up to 50 mm the efficacy is similar to the results of autologous grafting. When an operation is for pain management and functional motor restoration is planned using nerve or tendon transfers, the allograft technique is attractive due to no risk of secondary site neuropathic pain sensitization. The uncertain efficacy should be discussed in detail with the patient and a specialist PNI surgeon is well-placed to advise on management options.

Nerve transfer surgery involves reinnervation of the distal nerve stump of an important nerve close to its target using an expendable nerve branch or fascicle from another nerve in the vicinity of the target. The reconstruction is distal to the site of injury. The technique is used in the setting of proximal injuries with important far distal targets where the time available for regeneration is unlikely to restore motor axon continuity within the critical six-to-nine-month window. It may also offer a salvage solution when a patient is referred late, a proximal reconstruction has failed or when anticipated recovery has not occurred.

Tendon transfers can be considered as an alternative method of paralysis reconstruction, particularly when the injury is diagnosed late, beyond the normal window for successful reinnervation. Surgery on the nerve may still be useful to define the injury, for the management of neuropathic pain, and to release any scar that may be contributing to a prolonged conduction block in otherwise intact fascicles.

Small cutaneous neuromas from a surgical incision can result in intense pain for patients. Often these cases present late, and pain is already centrally mapped. There may be over-response to examination, avoidance behaviour



and marginal hypersensitivity around the site of injury. Diagnostic nerve blocks under ultrasound guidance are useful in defining the injured nerve and the potential for a successful surgical intervention.

Clinical photography is recommended to document the site and nature of any PNI identified intra-operatively as well as any reconstruction. The images are useful to describe the injury and prognosis for the patient, help in later follow-up clinics where recovery is expected over months or years, are useful for the primary surgeon to understand and learn from the injury and are helpful in future medicolegal matters. The operation record should clearly explain the location, extent and interventions for any nerve injury. The site of injury relative to fixed bony landmark helps to monitor post-operative Tinel's sign progression.

### Pain management

Neuropathic pain management is challenging. Due to limited efficacy in this setting, patients often are prescribed increasingly high doses of opioid medications, often developing intolerable side effects with minimal benefit. Severe pain should alert the clinician to a possible nerve that is deteriorating due to persistence of the injuring mechanism and the potential need for surgical intervention. The most important aspect of pain management is to gain the patient's trust, explain in simple terms the mechanism of pain generation, the treatment options and the prognosis. Neuropathic pain chronicity erodes resilience and can remove patients from their normal support structures through financial and relationship strain and self-isolation. With poor sleep patterns, nocturnal tricyclic antidepressants are useful. Neuromodulator therapy can be commenced and titrated to balance efficacy with symptom tolerance. These medications need to be continued for at three months following a neurolysis or until successful reinnervation after a nerve reconstruction. Mirror therapy is helpful in modulating limb pain and local physical desensitization and neuromodulation can improve sensitivity and evoked pain from a neuroma. Psychological support is helpful and cognitive therapies, mindfulness techniques and meditation may be introduced in receptive patients. Encouraging a graduated return to normal social and recreational activities is key to providing distraction from the current situation with relief from pain, albeit temporary. Reinstating support networks, counselling and improved sleep are essential to improving resilience. Local anaesthetic nerve blocks are useful to diagnose the source of pain prior to surgery. Admission to hospital for a regional nerve block with an indwelling nerve catheter for a few days is helpful in providing temporary relief and review of the pain management support package in extreme cases. Nerve catheters

placed intra-operatively should be considered in all surgical interventions.

### Rehabilitation

Following a nerve injury, pain and paralysis preclude useful functional movement. Joint stiffness follows. There may be autonomic disturbance with red, dry and trophic skin, limb swelling and avoidance behaviour due to contact pain, allodynia and dysaesthesia. Fatigue and sleep disturbance are common. Longstanding injuries are associated with anxiety and depression. The sufferer may experience feelings of anger and frustration. The rehabilitation team in the PNI unit have experience managing these symptoms. They are well-positioned to educate the patient, provide reassurance and commence therapies to mitigate the effects of the nerve injury and, when necessary, prepare for surgery. In cases requiring reconstruction, the anticipated recovery may take months. The therapy team will support the patient on this journey, tailoring the treatment as the patient progresses.

### Why are peripheral nerve injuries referred late?

Peripheral nerve injuries are very often referred late.<sup>19,20</sup> Not only does delay in diagnosis decrease the likelihood that a surgical repair can be undertaken, it also increases the likelihood of litigation.<sup>21</sup> Previous literature has shown that lower limb iatrogenic peripheral nerve injuries are more likely to present later than those of the upper limb.<sup>20</sup> Though the reason for this is unclear, it may be suggestive of higher patient tolerance of lower limb specific deficits.<sup>20</sup> No surgeon intentionally injures a nerve, and frequently the hopeful diagnosis of a neurapraxia that later proves to be erroneous is a common theme in the setting of late referral. A failure to examine the patient, particularly in the setting of unexplained paralysis and neuropathic pain is inexcusable. Over reliance on neurophysiology studies and a lack of understanding of the interpretation thereof, may lead to false reassurance. If in doubt, referral to a PNI centre is advised where an independent assessment may be made and appropriate advice and intervention provided. Paradoxically, the impact of concerns of medicolegal implications for being a cause of under-reporting and delay in referral cannot be excluded.<sup>19</sup>

### Guidelines

The British Orthopaedic Association has provided comprehensive guidance for the management of peripheral nerve injuries, first in 2011,<sup>2</sup> and then summarized in 2012 in the form of Standards for Trauma – BOAST 5.<sup>22</sup> These guidelines are clear that accurate and repeated

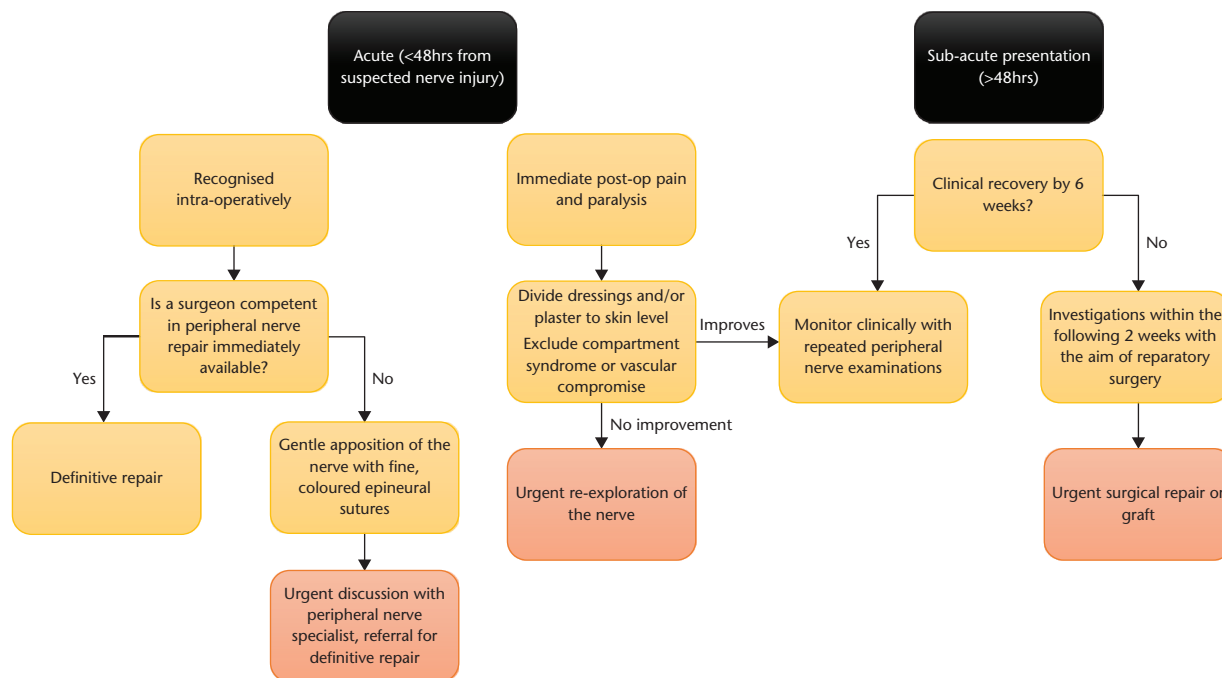


Fig. 1 Iatrogenic peripheral nerve management algorithm.

peripheral nerve history and examination is performed both pre-operatively and throughout follow-up.<sup>15,22,23</sup> It is notable, however, that in the immediate post-operative period difficulties in diagnosing motor or sensory deficits are common. Regional anaesthetic blocks, intoxication, casts and splints can all make clinical examination extremely difficult or unreliable. Nonetheless, surgeons do not always examine the patient for peripheral nerve injury following the procedure, or following an examination they may inappropriately label disproportionate pain as post-surgical. This is true even much later down the line when a diagnosis of complex regional pain syndrome is assigned to the pain condition, and the patient referred to pain specialists, when in fact a nerve injury may define it.<sup>19</sup> It is also the experience of this centre and others<sup>23</sup> that many potential nerve injuries do not get referred as there is a commonplace belief that peripheral nerve injuries will improve over time without specialist intervention. Furthermore, when faced with a possible peri-operative nerve injury, surgeons may request investigations in the false hope of defining the injury site and severity.

### Conclusion

There is a misconception that all iatrogenic injuries are preventable. Increasingly complex reconstruction possibilities for trauma or disease in the musculoskeletal system will potentially result in greater numbers of PNI cases requiring assessment and management in specialist units. Risk reduction can be affected through knowledge

and skills acquisition as a part of orthopaedic training. Understanding the types of injuries that are associated with specific interventions, early recognition of a suspected nerve injury and the process of investigation and management are critical. As such the term neurapraxia must only be used when there is no evidence of a degenerative nerve lesion, and necessitates close monitoring to avoid the risk of deterioration under observation. Neurophysiology testing can be helpful but must not delay intervention that may be indicated clinically. Maintaining the clinician–patient relationship is a core objective. The RAMA principles provide a guide to management for the clinician: Recognize, Acknowledge, Mitigate and Apologise. The management of PNI requires specific expertise and prompt referral to a regional unit is recommended. The authors include a proposed management algorithm (Figure 1) to this effect.

#### AUTHOR INFORMATION

The Peripheral Nerve Injury Service, Queen Elizabeth Hospital Birmingham, Birmingham, UK.

Correspondence should be sent to: Timothy G. Bage, The Peripheral Nerve Injury Service, 6th Floor, Nuffield House, Mindelsohn Way, Edgbaston, Birmingham, West Midlands, UK, B15 2WB.

Email: tim.bage@hotmail.co.uk

#### ICMJE CONFLICT OF INTEREST STATEMENT

The authors declare no conflict of interest relevant to this work.

## FUNDING STATEMENT

No benefits in any form have been received or will be received from a commercial party related directly or indirectly to the subject of this article.

## OPEN ACCESS

© 2021 The author(s)

This article is distributed under the terms of the Creative Commons Attribution-Non Commercial 4.0 International (CC BY-NC 4.0) licence (<https://creativecommons.org/licenses/by-nc/4.0/>) which permits non-commercial use, reproduction and distribution of the work without further permission provided the original work is attributed.

## REFERENCES

- Kretschmer T, Heinen CW, Antoniadis G, Richter HP, König RW.** Iatrogenic nerve injuries. *Neurosurg Clin N Am* 2009;20:73–90, vii.
- British Orthopaedic Association.** The management of nerve injuries: a guide to good practice, 2011. [http://www.nerveinjury.co.uk/wp-content/uploads/The-Management-of-Nerve-Injuries-the-blue-book\\_\\_BOA-2011.pdf](http://www.nerveinjury.co.uk/wp-content/uploads/The-Management-of-Nerve-Injuries-the-blue-book__BOA-2011.pdf) (date last accessed: 21 July 2020).
- Lefebvre R, Russo F, Navo P, Stevanovic M.** Characteristics of iatrogenic nerve injury from orthopedic surgery correlate with time to subspecialty presentation. *Plast Reconstr Surg Glob Open* 2020;8:e2678.
- Dahlin LB, Wiberg M.** Nerve injuries of the upper extremity and hand. *EFORT Open Rev* 2017;2:158–170.
- Pulos N, Shin EH, Spinner RJ, Shin AY.** Management of iatrogenic nerve injuries. *J Am Acad Orthop Surg* 2019;27:e838–e848.
- Ross A.** Medico-legal aspects of peripheral nerve injury. *Bone & Joint* 360 2017;6.
- Rasulić L, Savić A, Vitošević F, et al.** Iatrogenic peripheral nerve injuries – surgical treatment and outcome: 10 years' experience. *World Neurosurg* 2017;103:841–851.e6.
- Carter J, Pisquiy J, Polmear M, Khalifa R, Gonzalez G.** A new classification of iatrogenic peripheral nerve injuries. *Biol Med (Aligarh)* 2020;12:464.
- Yim G, Lin Z, Shirley C, Isherwood P, Power D.** The late diagnosis of nerve injuries following interscalene block and shoulder surgery. *J Musculoskelet Surg Res* 2019;3:141–145.
- Akinleye SD, Garofolo-Gonzalez G, Culbertson MD, Choueka J.** Iatrogenic injuries in percutaneous pinning techniques for fifth metacarpal neck fractures. *Hand (N Y)* 2019;14:386–392.
- Seddon HJ.** Three types of nerve injury. *Brain* 1943;66:237–288.
- Robbenolt JK.** Apologies and medical error. *Clin Orthop Relat Res* 2009;467:376–382.
- Lundborg G, Dahlin LB.** Anatomy, function, and pathophysiology of peripheral nerves and nerve compression. *Hand Clin* 1996;12:185–193.
- Soh J, Hill J, Power D.** Iatrogenic nerve injuries in orthopaedics. *J Musculoskelet Surg Res* 2019;3:9.
- Pulos N, Shin EH, Spinner RJ, Shin AY.** Management of iatrogenic nerve injuries. *J Am Acad Orthop Surg* 2019;27:e838–e848.
- Midha R, Grochmal J.** Surgery for nerve injury: current and future perspectives. 2019;130:675–685.
- Robinson LR.** Traumatic injury to peripheral nerves. *Muscle Nerve* 2000;23:863–873.
- General Medical Council.** Openness and honesty when things go wrong: the professional duty of candour, 2015. <https://www.gmc-uk.org/ethical-guidance/ethical-guidance-for-doctors/candour—openness-and-honesty-when-things-go-wrong/the-professional-duty-of-candour> (date last accessed: 25 October 2020).
- Khan R, Birch R.** Iatrogenic injuries of peripheral nerves. *J Bone Joint Surg Br* 2001;83:1145–1148.
- NICE.** Burns and scalds, 2017. <https://cks.nice.org.uk/burns-and-scalds#scenario> (date last accessed: 25 October 2020).
- Omar NB, Ditty BJ, Rozzelle CJ.** *Medicolegal aspects of peripheral nerve injury: nerves and nerve injuries*. 2. Cambridge MA: Academic Press, 2015:707–708.
- British Orthopaedic Association.** BOAST 5: peripheral nerve injury. *Standards for trauma*, 2012. <https://www.boa.ac.uk/resources/boast-5-pdf.html> (date last accessed: 09 October 2020).
- Antoniadis G, Kretschmer T, Pedro MT, König RW, Heinen CPG, Richter H-P.** Iatrogenic nerve injuries: prevalence, diagnosis and treatment. *Deutsches Ärzteblatt Int* 2014;18:111(16):273–279.
- Jeyaseelan L, Singh VK, Ghosh S, Sinisi M, Fox M.** Iatrogenic brachial plexus injury: a complication of delayed fixation of clavicle fractures. *Bone Joint J* 2013;95-B:106–110.
- Avis D, Power D.** Axillary nerve injury associated with glenohumeral dislocation: a review and algorithm for management. *EFORT Open Rev* 2018;3:70–77.
- Obremsky WT, Lyman JR.** A modified Judet approach to the scapula. *J Orthop Trauma* 2004;18:696–699.
- Paterson A, Wiid A, Navsa N, Bosman M.** The safe zone for placement of external fixation on the distal humerus: a cadaveric study. *Orthop Proc* 2014;96-B:52.
- Samarakoon LB, Lakmal KC, Thillainathan S, Bataduwaarachchi VR, Anthony DJ, Jayasekara RW.** Anatomical relations of the superficial sensory branches of the radial nerve: a cadaveric study with clinical implications. *Patient Saf Surg* 2011;5:28.
- Gundes H, Tosun B.** Longitudinal incision in surgical release of De Quervain disease. *Tech Hand Up Extrem Surg* 2005;9:149–152.
- Hazel A, Nemeth N, Bindra R.** Anatomic considerations for plating of the distal ulna. *J Wrist Surg* 2015;4:188–193.
- Esplugas M, Lluch A, Garcia-Elias M, Llusà-Pérez M.** How to avoid ulnar nerve injury when setting the 6U wrist arthroscopy portal. *J Wrist Surg* 2014;3:128–131.
- Martin AR, Gittings DJ, Levin LS, Donegan DJ, Gray BL.** Acute radial nerve repair with humeral shaft shortening and fixation following a closed humeral shaft fracture: a case report. *JBJS Case Connect* 2018;8:e109.
- Barlas K, George B, Hashmi F, Bagga T.** Open medial placement of Kirschner wires for supracondylar humeral fractures in children. *J Orthop Surg (Hong Kong)* 2006;14:53–57.
- Samson D, Power DM.** Iatrogenic injuries of the palmar branch of the median nerve following volar plate fixation of the distal radius. *J Hand Surg Asian Pac Vol* 2017;22:343–349.
- Woodmass JM, Welp KM, Chang MJ, Borque KA, Wagner ER, Warner JJP.** A reduction in the rate of nerve injury after Latarjet: a before-after study after neuromonitoring. *J Shoulder Elbow Surg* 2018;27:2153–2158.
- Huene DB, Bunnell WP.** Operative anatomy of nerves encountered in the lateral approach to the distal part of the fibula. *J Bone Joint Surg Am* 1995;77:1021–1024.
- Majewski M, Rohrbach M, Czaja S, Ochsner P.** Avoiding sural nerve injuries during percutaneous Achilles tendon repair. *Am J Sports Med* 2006;34:793–798.
- Li S.** Wound and sural nerve complications of the sinus tarsi approach for calcaneus fractures. *Foot Ankle Int* 2018;39:1106–1112.
- Solan MC, Lemon M, Bendall SP.** The surgical anatomy of the dorsomedial cutaneous nerve of the hallux. *J Bone Joint Surg Br* 2001;83:250–252.