



Overlooked Role of Histopathology in Evaluations for Occupational/Environmental Exposures

To the Editor:

We read with interest the article by Culver and colleagues (1) describing the relevance, use, and attributes of idiopathic pulmonary fibrosis (IPF) patient registries and the subsequent correspondence by Nett and colleagues (2), who rightly point out the added importance of collecting environmental and occupational exposure data. In addition to acknowledging the utility of such data collection, Culver and Kim, in their reply (3) to Nett and colleagues, also emphasize the hurdles in the evaluation of a proper environmental/occupational history.

On the basis of our environmental pathology experience, we want to bring up the importance of histologic evaluation in independently supplementing and confirming the environmental/occupational investigation in cases of interstitial lung disease in general and IPF in particular. Light microscopic evaluation and characterization of dust burden is an easy and underused tool in the hands of pathologists, whose reports can highlight the presence of dust that differs from background dust accumulation in lungs. Currently, there is no requirement (or even mention) of these minimal additional observations that pathologists can record in the American Thoracic Society/European Respiratory Society guidelines for diagnosis of IPF (4), which suggest only doing an iron stain when there is a positive history of asbestos exposure and ruling out obvious pneumoconiosis. We have seen many lung tissues over the years in which an evident environmental/occupational etiology has been considered neither by the clinician nor by the pathologist, hence misclassifying cases as “idiopathic” (i.e., IPF).

We propose at least minimal criteria for dust characterization for pathologists to follow in their evaluation of biopsies in which IPF is within the differential diagnosis:

1. Examine iron-stained sections in every case to search for asbestos bodies. Asbestosis is still frequently underdiagnosed by pathologists.
2. Record the examination of the lung tissue sections using bright-field and adequate polarized light microscopy, describing the presence, abundance, and types of dust particles observed by light microscopy (e.g., silica, silicates, iron oxides, and welding type fumes). It is important to point out that current digital pathology slide imaging platforms do not routinely support polarized light imaging, so microscopic examination of actual glass slides must be included in any optimal pathologic review.

Such specific light microscopic evaluation and descriptions can assist the clinician in considering further exposure history investigation and additional testing of the patient and tissues. It is not currently

practical to routinely require further analysis, such as by electron microscopy/microanalysis, but such analyses can often reveal evidence of yet additional exposure to materials such as metals and fibers, which are not recognized routinely by light microscopy.

The percentage of cases with tissue biopsies in the registries as noted (1) was low (13–35%). We presume that these were cases with a difficult diagnosis, and further analysis (as outlined above) would be extremely valuable. In every case, identifiable exposures may not be causative; however, in routine diagnosis as well as in patient registries, we believe this is information that would be readily available for further exploration/correlation. If reinforced by the clinicians, reporting dust burden could become a standard of care in lung tissue histopathology. Searching for information about potential etiology is fundamental to the goal of primary prevention. ■

Author disclosures are available with the text of this letter at www.atsjournals.org.

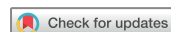Soma Sanyal, M.D.
Judith A. Crawford, C.I.H., Ph.D.
Jerrold L. Abraham, M.D.*
SUNY Upstate Medical University
Syracuse, New York

*Corresponding author (e-mail: abrahamj@upstate.edu).

References

1. Culver DA, Behr J, Belperio JA, Corte TJ, de Andrade JA, Flaherty KR, et al. Patient registries in idiopathic pulmonary fibrosis. *Am J Respir Crit Care Med* 2019;200:160–167.
2. Nett RJ, Wood JM, Blackley DJ. Collecting occupational exposure data would strengthen idiopathic pulmonary fibrosis registries [letter]. *Am J Respir Crit Care Med* 2020;201:495–496.
3. Culver DA, Kim H. Reply to Nett et al.: collecting occupational exposure data would strengthen idiopathic pulmonary fibrosis registries [letter]. *Am J Respir Crit Care Med* 2020;201:496–497.
4. Raghu G, Remy-Jardin M, Myers JL, Richeldi L, Ryerson CJ, Lederer DJ, et al.; American Thoracic Society, European Respiratory Society, Japanese Respiratory Society, and Latin American Thoracic Society. Diagnosis of idiopathic pulmonary fibrosis: an official ATS/ERS/JRS/ALAT clinical practice guideline. *Am J Respir Crit Care Med* 2018;198:e44–e68.

Copyright © 2020 by the American Thoracic Society



Reply to Sanyal et al.



From the Authors:

We agree with Dr. Sanyal and colleagues that a careful histologic evaluation of biopsy specimens, when available, is a key aspect of accurately parsing the causes of interstitial fibrosis, and in cases of idiopathic pulmonary fibrosis (IPF) it may also identify

Ⓒ This article is open access and distributed under the terms of the Creative Commons Attribution Non-Commercial No Derivatives License 4.0 (<http://creativecommons.org/licenses/by-nc-nd/4.0/>). For commercial usage and reprints, please contact Diane Gern (dgern@thoracic.org).

Originally Published in Press as DOI: 10.1164/rccm.201911-2195LE on March 2, 2020

Ⓒ This article is open access and distributed under the terms of the Creative Commons Attribution Non-Commercial No Derivatives License 4.0 (<http://creativecommons.org/licenses/by-nc-nd/4.0/>). For commercial usage and reprints, please contact Diane Gern (dgern@thoracic.org).

Originally Published in Press as DOI: 10.1164/rccm.202002-0367LE on March 2, 2020

environmental exposures that can contribute to progression. Such an evaluation, ideally, would entail close collaboration among pathologists and other members of the interstitial lung disease team to provide context and clinical relevance to the histologic features (1, 2). However, based on the available data, we believe that the authors' suggestion to perform routine iron staining and polarized light microscopy in cases of typical IPF is excessive. We do agree with the authors that a research effort to characterize dust burden/particulates in the lungs of patients with IPF would be potentially informative and very welcome.

It has previously been emphasized that pathologic findings supporting occupational/environmental exposures cannot always distinguish between occupational lung diseases and other forms of pulmonary fibrosis (3). For detection of asbestos bodies, standard evaluation with hematoxylin and eosin appears to be adequate (4, 5), although iron staining can occasionally help reveal asbestos bodies that might have been missed on routine hematoxylin-and-eosin staining. It is well established that the mere finding of asbestos bodies in the lung is insufficient for a pathologic diagnosis of asbestosis. The detection of asbestos bodies only raises more vexing questions for the pathologist, including whether significant interstitial fibrosis is present, whether the fibrosis is present in the appropriate distribution for a diagnosis of asbestosis, whether usual interstitial pneumonia (UIP)-pattern fibrosis should be labeled as asbestosis, and whether UIP in an asbestos-exposed individual represents concurrent IPF or atypical asbestosis. With regard to the last question, some experts in occupational lung disease have suggested that UIP-pattern fibrosis should not be regarded as genuine asbestosis, irrespective of the status of asbestos biomarkers (6). This suggestion—based on an analysis of four asbestos-exposed cohorts in the United Kingdom—challenges the dogma that using iron stains to detect asbestos bodies is a worthwhile exercise in histologic UIP. In contrast to Sanyal and colleagues's claim that asbestosis is underdiagnosed by pathologists, it suggests that asbestosis may have been historically *overdiagnosed* by pathologists, especially in patients with histologic evidence of UIP-pattern fibrosis.

Routine use of polarized light microscopy for identification of crystalline silica is appealing, but there are no data of which we are aware that demonstrate incremental diagnostic sensitivity for silicosis compared with expected findings on light microscopy (e.g., silicotic nodules, dust macules, and diffuse fibrosis without fibroblast foci). Because background dust accumulation occurs in most normal lungs, the more biologically relevant question is not whether *any* dust particles (including birefringent silica/silicate particles) are present but whether these particles are significantly in excess of the amount expected in normal lungs, and whether they are associated with a tissue response that would be expected in a true pneumoconiosis (nodules, inflammation, fibrosis, etc.). In this regard, at present, polarized light microscopy should be used at the discretion of the pathologist when histologic features on routine hematoxylin-and-eosin-stained slides suggest the possibility of a pneumoconiosis. Whether finding incidental silica/silicate particles in patients with IPF is of value for diagnosis or clinical care is an open question, especially considering that ongoing dust exposure is already recognized as a contributor to IPF progression. Obtaining a clinical history, as suggested by experts (2), remains the best tool for identifying ongoing significant dust exposure.

We doubt that a detailed proscriptive rubric for pathologic reports in interstitial lung disease is necessary or even advisable. Although the histopathologic criteria for calling features of UIP and other key entities

in the differential diagnosis (e.g., lymphocytic bronchiolitis in hypersensitivity pneumonitis) are commonly discussed, they have not been precisely defined. Thus, there is poor agreement among lung pathologists for calling these specific histologic patterns (7). In addition, the suggestion that routine templating of reports should include an environmental assessment risks turning the pathology report into a checklist devoid of context and interpretation, which is an unfortunate trend in radiology reports. It is our opinion that descriptive pathology reports are more likely to provide useful information for clinicians. We acknowledge that some cases of pneumoconiosis are missed by pathologists (as well as clinicians and radiologists), but we are not aware of any evidence that mandatory checklists, stains, or polarizing lenses will prevent these mistakes.

In summary, we agree with the general suggestion that more careful evaluations of occupational/environmental exposures are needed (8). We think this is best accomplished in the setting of a research effort that includes the appropriate control groups rather than by adhering to a proscriptive standard that may be time consuming, unwieldy, and unevenly interpreted, and may also lead to false reassurance or even misclassification by clinicians. ■

Author disclosures are available with the text of this letter at www.atsjournals.org.

Daniel A. Culver, D.O.*
Sanjay Mukhopadhyay, M.D.
Cleveland Clinic
Cleveland, Ohio

Jurgen Behr, M.D.
University of Munich
Munich, Germany
and
Asklepios Fachkliniken München-Gauting
Munich, Germany

Hyun Kim, M.D.
University of Minnesota
Minneapolis, Minnesota

*Corresponding author (e-mail: culverd@ccf.org).

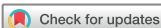References

- Churg A, Wright JL, Ryerson CJ. Pathologic separation of chronic hypersensitivity pneumonitis from fibrotic connective tissue disease-associated interstitial lung disease. *Am J Surg Pathol* 2017;41:1403–1409.
- Raghu G, Remy-Jardin M, Myers JL, Richeldi L, Ryerson CJ, Lederer DJ, et al.; American Thoracic Society, European Respiratory Society, Japanese Respiratory Society, and Latin American Thoracic Society. Diagnosis of idiopathic pulmonary fibrosis: an official ATS/ERS/JRS/ALAT clinical practice guideline. *Am J Respir Crit Care Med* 2018;198:e44–e68.
- Honma K, Abraham JL, Chiyotani K, De Vuyst P, Dumortier P, Gibbs AR, et al. Proposed criteria for mixed-dust pneumoconiosis: definition, descriptions, and guidelines for pathologic diagnosis and clinical correlation. *Hum Pathol* 2004;35:1515–1523.
- Holden J, Churg A. Asbestos bodies and the diagnosis of asbestosis in chrysotile workers. *Environ Res* 1986;39:232–236.
- Gaensler EA, Jederlinic PJ, Churg A. Idiopathic pulmonary fibrosis in asbestos-exposed workers. *Am Rev Respir Dis* 1991;144:689–696.
- Attanoos RL, Alchami FS, Pooley FD, Gibbs AR. Usual interstitial pneumonia in asbestos-exposed cohorts - concurrent idiopathic pulmonary fibrosis or atypical asbestosis? *Histopathology* 2016;69:492–498.
- Thomeer M, Demedts M, Behr J, Buhl R, Costabel U, Flower CD, et al.; Idiopathic Pulmonary Fibrosis International Group Exploring

N-Acetylcysteine I Annual (IFIGENIA) study group. Multidisciplinary interobserver agreement in the diagnosis of idiopathic pulmonary fibrosis. *Eur Respir J* 2008;31:585–591.

8. Culver DA, Behr J, Belperio JA, Corte TJ, de Andrade JA, Flaherty KR, *et al.* Patient registries in idiopathic pulmonary fibrosis. *Am J Respir Crit Care Med* 2019;200:160–167.

Copyright © 2020 by the American Thoracic Society



Controlled Chamber Studies Showed Protective Effect of Nonsteroidal Antiinflammatory Drugs against Ozone Exposure: The Stage Was Set for Broader Epidemiologic Investigation

To the Editor:

I read with interest the recent article by Gao and colleagues (1) titled, “Nonsteroidal Antiinflammatory Drugs Modify the Effect of Short-Term Air Pollution on Lung Function,” which examined the role of nonsteroidal antiinflammatory drugs (NSAIDs) in particulate matter (PM)-induced changes in lung function in the Normative Aging Study cohort. In the DISCUSSION section, the authors state, “To the best of our knowledge, this is the first study on the subclinical preventive effects of NSAIDs against the adverse effects of air pollution on lung function.” I respectfully submit to the authors that, with regard to examining the potential role that NSAIDs play in modifying respiratory effects of air pollution exposure, that stage had already been set, albeit not using epidemiologic studies, but rather using controlled human chamber exposure studies. For example, Alexis and colleagues (2) examined the pretreatment effect of the NSAID indomethacin in both individuals with asthma and healthy individuals exposed for 2 hours to 400-ppb ozone (not PM). That study reported that indomethacin significantly attenuated ozone-induced decreases in FVC and FEV₁ in healthy subjects but not subjects with asthma; furthermore, there was a marked attenuation of ozone-induced decrements in forced expiratory flow (FEF) at 75% of the FVC and FEF at 60% of the FVC based on partial flow volume curves in subjects with asthma but not in healthy subjects. Alexis and colleagues concluded that cyclooxygenase metabolites of the arachidonic acid pathway, such as prostaglandin F_{2α}, contribute to restrictive changes in healthy individuals and obstructive small airway changes in individuals with asthma. Other studies by Schelegle and colleagues (3), Eschenbacher and colleagues (4), Ying and colleagues (5), and Hazucha and colleagues (6) also used indomethacin (or similar NSAIDs), not only to implicate the involvement of cyclooxygenase metabolites as a potential mechanism of response in air pollution (ozone)-induced spirometric responses but also to demonstrate NSAIDs’ mitigating effect on lung function decrement after ozone exposure. In particular, Hazucha and colleagues (6) showed that the NSAID ibuprofen blunted the ozone-induced decrease in FEV₁ (7% vs. 17%) and caused a concomitant inhibition of increases in respiratory tract prostaglandin E₂ and thromboxane B₂ concentrations.

Ⓒ This article is open access and distributed under the terms of the Creative Commons Attribution Non-Commercial No Derivatives License 4.0 (<http://creativecommons.org/licenses/by-nc-nd/4.0/>). For commercial usage and reprints, please contact Diane Gern (dgern@thoracic.org).

Originally Published in Press as DOI: 10.1164/rccm.202002-0237LE on March 3, 2020

The study by Gao and colleagues, together with previous controlled chamber studies with ozone, expands the potential beneficial role of NSAIDs as protectors against both gaseous and PM-induced health effects, the latter involving fine PM (PM_{2.5}) and black carbon, at ambient concentrations. The strengths of the study by Gao and colleagues lie in its use of a large epidemiologic data set (3,220 medical visits of 1,078 white participants between 1995 and 2012 with available data of lung function, PM exposures, and NSAID use), strong statistical modeling (time-varying linear mixed-effects regression with random participant-specific intercepts), and the inclusion of nongaseous air pollutants PM_{2.5} (μg/m³) and black carbon (μg/m³). ■

Author disclosures are available with the text of this letter at www.atsjournals.org.

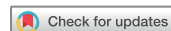
Neil E. Alexis, Ph.D.*
University of North Carolina at Chapel Hill
Chapel Hill, North Carolina

*Corresponding author (e-mail: neil_alexis@med.unc.edu).

References

- Gao X, Coull B, Lin X, Vokonas P, Schwartz J, Baccarelli AA. Nonsteroidal antiinflammatory drugs modify the effect of short-term air pollution on lung function [letter]. *Am J Respir Crit Care Med* 2020;201:374–378.
- Alexis N, Urch B, Tarlo S, Corey P, Pengelly D, O’Byrne P, *et al.* Cyclooxygenase metabolites play a different role in ozone-induced pulmonary function decline in asthmatics compared to normals. *Inhal Toxicol* 2000;12:1205–1224.
- Schelegle ES, Adams WC, Siefkin AD. Indomethacin pretreatment reduces ozone-induced pulmonary function decrements in human subjects. *Am Rev Respir Dis* 1987;136:1350–1354.
- Eschenbacher WC, Ying RC, Kreit JW, Gross KB. Ozone-induced lung function changes in normal and asthmatic subjects and the effect of indomethacin. In: Schneider T, Lee SD, Wolters GJR, Grant LD, editors. *Studies in environmental science: atmospheric ozone research and its policy implications*. Vol. 35. Amsterdam: Elsevier; 1989. pp. 493–499.
- Ying RL, Gross KB, Terzo TS, Eschenbacher WL. Indomethacin does not inhibit the ozone-induced increase in bronchial responsiveness in human subjects. *Am Rev Respir Dis* 1990;142:817–821.
- Hazucha MJ, Madden M, Pape G, Becker S, Devlin R, Koren HS, *et al.* Effects of cyclo-oxygenase inhibition on ozone-induced respiratory inflammation and lung function changes. *Eur J Appl Physiol Occup Physiol* 1996;73:17–27.

Copyright © 2020 by the American Thoracic Society



Reply to Alexis

From the Authors:

We appreciate the valuable opinion shared by Dr. Neil E. Alexis on our article on the modifying effect by nonsteroidal antiinflammatory

Ⓒ This article is open access and distributed under the terms of the Creative Commons Attribution Non-Commercial No Derivatives License 4.0 (<http://creativecommons.org/licenses/by-nc-nd/4.0/>). For commercial usage and reprints, please contact Diane Gern (dgern@thoracic.org).

Originally Published in Press as DOI: 10.1164/rccm.202002-0385LE on March 3, 2020