

Treatment of Vasodilator-resistant Mixed Connective Tissue Disease-associated Pulmonary Arterial Hypertension with Glucocorticoid and Cyclophosphamide

Eri Sugawara, Masaru Kato, Ryo Hisada, Kenji Oku, Toshiyuki Bohgaki, Tetsuya Horita, Shinsuke Yasuda and Tatsuya Atsumi

Abstract

Pulmonary arterial hypertension (PAH) associated with systemic lupus erythematosus (SLE) or mixed connective tissue disease (MCTD), in contrast to other types of PAH, may respond to immunosuppressive therapy. Most PAH cases with an immunosuppressant response were in the early stages of the disease (WHO functional class III or less). The present case was a 34-year-old woman with MCTD-associated PAH (WHO functional class IV) who was resistant to a combination of three vasodilators. Afterwards, she was treated with glucocorticoid and cyclophosphamide. This case suggested the potential benefit of immunosuppressants in patients with severe MCTD-associated PAH.

Key words: pulmonary arterial hypertension, mixed connective tissue disease, glucocorticoid, intravenous cyclophosphamide

(Intern Med 56: 445-448, 2017)

(DOI: 10.2169/internalmedicine.56.7668)

Introduction

Pulmonary arterial hypertension (PAH) is of clinical significance in connective tissue disease because of its high mortality. Early but not late stage of PAH associated with systemic lupus erythematosus (SLE) or mixed connective tissue disease (MCTD) has been shown to respond to immunosuppressive therapy. We herein present a case of MCTD-associated PAH progressing to WHO functional class IV despite intensive medication with vasodilators, who was treated with glucocorticoid plus intravenous cyclophosphamide (IVCY).

Case Report

A 34-year-old Japanese woman had a diagnosis of MCTD with the presence of Raynaud's phenomenon, pancytopenia, elevated plasma creatinine kinase, and antibodies against U1-ribonucleoprotein in 2005 and received 10 mg of prednisolone daily. Pulmonary arterial systolic pressure estimated

by echocardiography was slightly elevated (48 mmHg) in 2006. She felt progressive shortness of breath on physical effort in 2011. Pulmonary arterial hypertension was diagnosed with 74 mmHg of mean pulmonary arterial pressure (mPAP) evaluated by right heart catheterization (RHC) in 2012. Cyclophosphamide-based immunosuppressive therapy was proposed but refused because of possible early menopausal symptoms. Treatment with 250 mg/day of bosentan and 120 µg/day of beraprost was initiated. However, in January 2014, her dyspnea deteriorated (WHO functional class IV), and she was admitted to our hospital.

A physical examination showed low systemic blood pressure (89/61 mmHg), tachycardia (104/min), low blood oxygen level (percutaneous oxygen saturation (SpO₂) 95%), jugular venous distension, and severe systemic edema. Coarse crackles and loud pulmonic valve closure sounds were detected. She was unable to undergo the 6-minute walk test due to severe dyspnea. Laboratory examinations showed elevated plasma brain natriuretic peptide (BNP) level (929.4 pg/mL), hypoxemia (PaO₂ 62.5 mmHg, PaCO₂ 27.1 mmHg), and the presence of antibodies against U1-

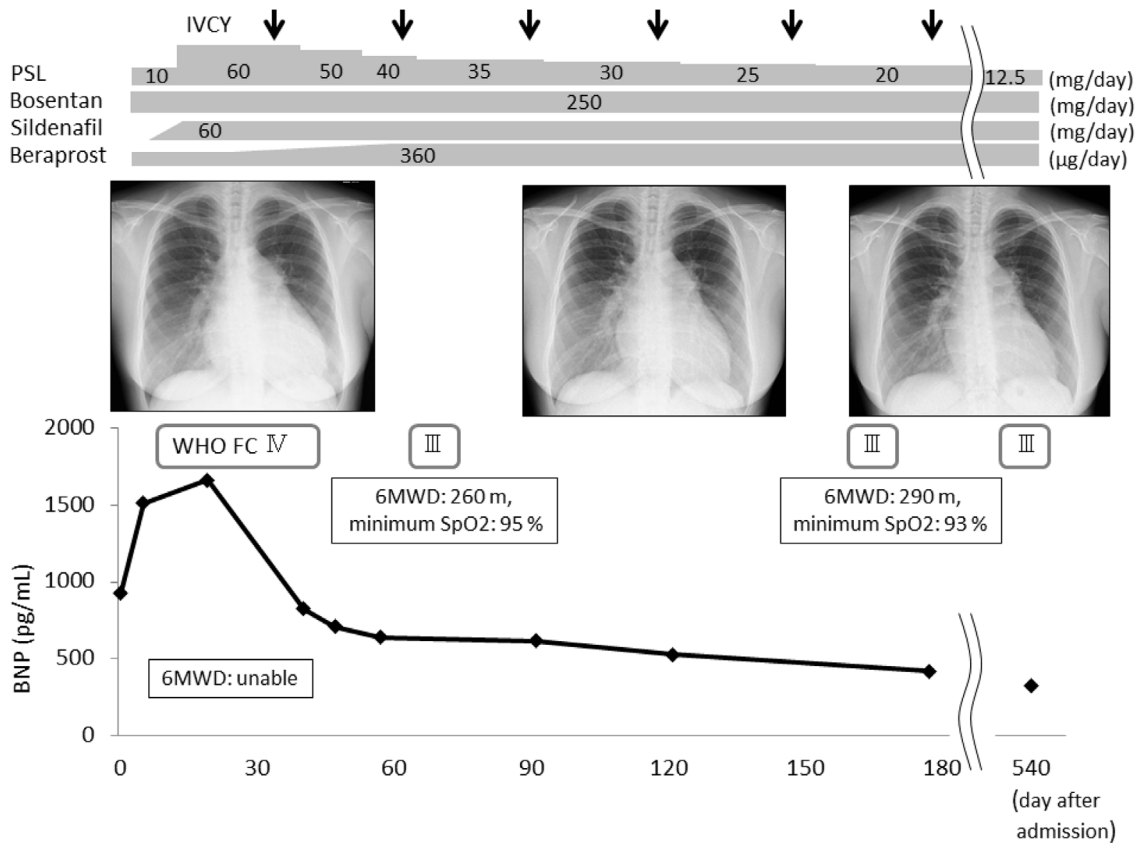


Figure. The clinical course of the patient. BNP: brain natriuretic peptide, FC: functional class, IVCY: intravenous cyclophosphamide, PSL: prednisolone, 6MWD: 6-minute walking distance

Table. Hemodynamics of the Patient.

Duration after admission (months)	-24	0	6	18
PAP (s/d/m) (mmHg)	119/45/74	105/50/65	85/38/53	95/40/53
PAWP (mmHg)	16	12	11	8
CO (CI) (L/min)	4.06/2.37	2.74/1.69	3.01/1.83	3.02/1.86
PVR (dyne·sec·cm ⁻⁵)	-	1,547	1,116	1,192
ePASP (mmHg)	50	117	89	75
TAPSE (mm)	-	16	16	15
RAD/RVDd (mm)	-	55/48	52/37	44.8/54.5

CI: cardiac index, CO: cardiac output, d: diastolic, ePASP: estimated pulmonary arterial systolic pressure, m: mean, PAP: pulmonary arterial pressure, PAWP: pulmonary arterial wedge pressure, PVR: pulmonary vascular resistance, RAD: right atrial diameter, RVDd: right ventricular end-diastolic diameter, s: systolic, TAPSE: tricuspid annular plane systolic excursion

ribonucleoprotein (97.9 U/mL) as well as antinuclear antibodies (1:640, speckled pattern). A chest X-ray showed enlarged pulmonary arteries and cardiomegaly (Figure). Electrocardiogram showed P wave elevation in the V1-V2 leads. RHC demonstrated elevated mPAP (65 mmHg) with normal pulmonary arterial wedge pressure (12 mmHg), high pulmonary vascular resistance (1,547 dyne·sec·cm⁻⁵), and decreased cardiac output (cardiac index 1.69 L/min/m²). A ventilation/

perfusion scan showed no signs of pulmonary thromboembolism. No signs of chronic obstructive pulmonary disease or interstitial lung diseases were found with computed tomography. Her dyspnea was therefore considered to be due to MCTD-associated PAH which was refractory to bosentan and beraprost therapy.

In addition to supportive therapy with oxygen supplementation and diuretics (40 mg/day of furosemide), initiation of 60 mg/day of sildenafil as well as gradual increment in the dose of beraprost was chosen as an additional treatment. However, her dyspnea remained unchanged, and her plasma BNP level increased. IVCY (750 mg/m², every 4 weeks) was initiated, and the dose of prednisolone was increased to 60 mg daily. Her dyspnea then ameliorated, and she became able to undergo the 6-minute walk test (260 m, minimum SpO₂ 95 %). Her plasma BNP level also decreased after the initiation of IVCY (Figure). Six months after the admission, a follow-up RHC revealed improved mPAP (65 to 53 mmHg), pulmonary vascular resistance (1,547 to 1,116 dyne·sec·cm⁻⁵), and cardiac index (1.69 to 1.83 L/min/m²) (Table). Since she remained stable but did not obtain further improvements 18 months after the admission (Table), we consider parenteral prostanoids or lung transplantation as a subsequent treatment.

Discussion

SLE- or MCTD-associated PAH, in contrast to other forms of PAH, has been shown to respond to immunosuppressive therapy (1, 2); however, its clinical indication remains to be determined. In a retrospective study with 23 SLE- or MCTD-associated PAH patients performed by Jais et al. (3), all responders to IVCY were in WHO functional class III or less. Furthermore, the cardiac index was significantly higher in responders than in nonresponders. Considering these results, immunosuppressive therapy was recommended for patients with less severe PAH in WHO functional class III or less and with a cardiac index of 3.1 L/min/m² or more. In another observational cohort study comprising 13 patients with connective tissue disease-associated PAH (4), no patients in WHO functional class IV received immunosuppressive therapy.

In contrast to these previous reports, our case responded to treatment with glucocorticoid and IVCY despite WHO functional class IV PAH, a markedly decreased cardiac index, and refractoriness to combined vasodilators. Currently there are two previous case reports of SLE- or MCTD-associated WHO functional class IV PAH successfully treated with glucocorticoid and IVCY in conjunction with up-front triple combination therapy comprising intravenous prostacyclin analogue, endothelin receptor antagonist, and phosphodiesterase type 5 inhibitor (5, 6). Our case, particularly with regard to the refractoriness to combined vasodilation, further supports the efficacy of immunosuppressive therapy for severe PAH associated with SLE or MCTD.

Another aspect of this case is that intervention with immunosuppressive therapy would have been more effective had it been initiated earlier. A patient refusing IVCY at the diagnosis might result in the progression of PAH. Although PAH is characterized by pulmonary vasculopathy, the symptoms and survival are determined by the right ventricle's ability to adapt to afterloads. From this point of view, the assessment of the right heart function-including hemodynamics, exercise capacity, plasma BNP level, and echocardiography-is critical for evaluating the efficacy of treatment and the prognosis of PAH (7). Despite the response to immunosuppressive therapy, our case was still in WHO functional class III and had a decreased cardiac index, reduced 6-minute walk distance, elevated plasma BNP level, and echocardiographic abnormalities 18 months after admission. Considering these factors, this case was still at high risk of disease progression, and further treatment, such as parenteral prostanoids and lung transplantation, needed to be considered to improve these parameters to the level expected in WHO functional class II or less (7).

The regimen of IVCY for SLE- or MCTD-associated PAH also remains to be established. In previous studies and case reports, the dose, interval, and duration of IVCY for SLE- or MCTD-associated PAH were 500 to 1,000 mg/m² per pulse, monthly in most cases, and 3 to 12 months, re-

spectively (1, 3-5, 8-17).

Late relapse is another problem in immunosuppressive therapy for SLE- or MCTD-associated PAH, with a reported occurrence in 25% to 40% of patients receiving glucocorticoid and/or IVCY during glucocorticoid tapering or several months after the last pulse of IVCY (2, 3, 18). Our case remained stable for at least 1 year since the last pulse of IVCY with 12.5 mg/day of prednisolone without any other immunosuppressive medications.

Pathological changes occurring in PAH include remodeling of arterioles, vascular smooth muscle hypertrophy, adventitial and neointimal proliferation, *in situ* thrombosis, and plexiform lesions (19, 20). In addition to these pathological changes, pulmonary fibrosis, vasculitis of the pulmonary artery to vein, and anti-endothelial cell antibodies are observed in MCTD-associated PAH (21). The pathological diversity of MCTD-associated PAH may reflect the clinical response to either or both vasodilators and immunosuppressive therapy.

The present case report suggests the potential efficacy of immunosuppressive therapy for patients with MCTD-associated PAH, even if they have severe dyspnea, exercise intolerance, or cardiac dysfunction.

The authors state that they have no Conflict of Interest (COI).

References

1. Sanchez O, Sitbon O, Jais X, Simonneau G, Humbert M. Immunosuppressive therapy in connective tissue diseases-associated pulmonary arterial hypertension. *Chest* **130**: 182-189, 2006.
2. Kato M, Kataoka H, Odani T, et al. The short-term role of corticosteroid therapy for pulmonary arterial hypertension associated with connective tissue diseases: report of five cases and a literature review. *Lupus* **20**: 1047-1056, 2011.
3. Jais X, Launay D, Yaici A, et al. Immunosuppressive therapy in lupus- and mixed connective tissue disease-associated pulmonary arterial hypertension: a retrospective analysis of twenty-three cases. *Arthritis Rheum* **58**: 521-531, 2008.
4. Miyamichi-Yamamoto S, Fukumoto Y, Sugimura K, et al. Intensive immunosuppressive therapy improves pulmonary hemodynamics and long-term prognosis in patients with pulmonary arterial hypertension associated with connective tissue disease. *Circ J* **75**: 2668-2674, 2011.
5. Sitbon O, Bertoletti L. Connective tissue disease associated with pulmonary arterial hypertension: management of a patient with severe haemodynamic impairment. *Eur Respir Rev* **23**: 505-509, 2014.
6. Olsson KM, Palazzini M. Challenges in pulmonary hypertension: managing the unexpected. *Eur Respir Rev* **24**: 674-681, 2015.
7. Galie N, Humbert M, Vachiery JL, et al. 2015 ESC/ERS Guidelines for the diagnosis and treatment of pulmonary hypertension: The Joint Task Force for the Diagnosis and Treatment of Pulmonary Hypertension of the European Society of Cardiology (ESC) and the European Respiratory Society (ERS): Endorsed by: Association for European Paediatric and Congenital Cardiology (AEPC), International Society for Heart and Lung Transplantation (ISHLT). *Eur Heart J* **37**: 67-119, 2016.
8. Gonzalez-Lopez L, Cardona-Munoz EG, Celis A, et al. Therapy with intermittent pulse cyclophosphamide for pulmonary hypertension associated with systemic lupus erythematosus. *Lupus* **13**: 105-

- 112, 2004.
9. Groen H, Bootsma H, Postma DS, Kallenberg CG. Primary pulmonary hypertension in a patient with systemic lupus erythematosus: partial improvement with cyclophosphamide. *The Journal of rheumatology* **20**: 1055-1057, 1993.
 10. Karmochkine M, Wechsler B, Godeau P, Brenot F, Jagot JL, Simonneau G. Improvement of severe pulmonary hypertension in a patient with SLE. *Ann Rheum Dis* **55**: 561-562, 1996.
 11. Tam LS, Li EK. Successful treatment with immunosuppression, anticoagulation and vasodilator therapy of pulmonary hypertension in SLE associated with secondary antiphospholipid syndrome. *Lupus* **7**: 495-497, 1998.
 12. Yamaguchi T, Ohshima S, Tanaka T, et al. Renal crisis due to intimal hyperplasia in a patient with mixed connective tissue disease (MCTD) accompanied by pulmonary hypertension. *Intern Med* **40**: 1250-1253, 2001.
 13. Kato M, Sato S, Suzuki M, et al. A case of mixed connective tissue disease successfully treated for hemophagocytic syndrome with intermittent intravenous injection of cyclophosphamide. *Nihon Rinsho Meneki Gakkai Kaishi* **27**: 345-349, 2004 (in Japanese, Abstract in English).
 14. Vegh J, Soos G, Csipo I, et al. Pulmonary arterial hypertension in mixed connective tissue disease: successful treatment with Iloprost. *Rheumatol Int* **26**: 264-269, 2006.
 15. Ueda Y, Takahashi Y, Yamashita H, Kaneko H, Mimori A. Successful bosentan therapy in a case of pulmonary arterial hypertension developed during immunosuppressive therapy for lupus nephritis. *Nihon Rinsho Men'eki Gakkai kaishi* **34**: 99-104, 2011.
 16. Okura Y, Takezaki S, Yamazaki Y, Yamada M, Kobayashi I, Ariga T. Rapid progression to pulmonary arterial hypertension crisis associated with mixed connective tissue disease in an 11-year-old girl. *Eur J Pediatr* **172**: 1263-1265, 2013.
 17. Watanabe R, Fujii H, Shirai T, et al. Successful use of intensive immunosuppressive therapy for treating simultaneously occurring cerebral lesions and pulmonary arterial hypertension in a patient with systemic lupus erythematosus. *Intern Med* **53**: 627-631, 2014.
 18. Tanaka E, Harigai M, Tanaka M, Kawaguchi Y, Hara M, Kamatani N. Pulmonary hypertension in systemic lupus erythematosus: evaluation of clinical characteristics and response to immunosuppressive treatment. *J Rheumatol* **29**: 282-287, 2002.
 19. Hassoun PM, Mouthon L, Barbera JA, et al. Inflammation, growth factors, and pulmonary vascular remodeling. *J Am Coll Cardiol* **54** (1 Suppl): S10-S19, 2009.
 20. Rabinovitch M. Molecular pathogenesis of pulmonary arterial hypertension. *J Clin Invest* **122**: 4306-4313, 2012.
 21. Sasaki N, Kamataki A, Sawai T. A histopathological study of pulmonary hypertension in connective tissue disease. *Allergol Int* **60**: 411-417, 2011.

The Internal Medicine is an Open Access article distributed under the Creative Commons Attribution-NonCommercial-NoDerivatives 4.0 International License. To view the details of this license, please visit (<https://creativecommons.org/licenses/by-nc-nd/4.0/>).