

WHAT IS THE BEST RADIOGRAPHIC VIEW FOR “DIE PUNCH” DISTAL RADIUS FRACTURES? A CADAVER MODEL STUDY

Diego Figueira Falcochio¹, Bruno Eiras Crepaldi², Christiano Augusto Trindade², Antonio Carlos da Costa³, Ivan Chakkour⁴

ABSTRACT

Objective: the aim of this study is try to show the best view for distal radius fractures so called *die-punch* fractures. **Methods:** There has been used a human cadaver radius bone from the Salvador Arena Tissue Bank. This bone was cleaned up after removing the soft tissues and osteotomies created displaced lunate fossa fractures of 0, 1, 2, 3 and 5 mm. We have fixed this fragment with adhesive tape. Then the joint deviation were significantly increased with step-offs of 1 mm. Radiographs were then taken into 5 different positions: postero-anterior view, lateral view, oblique views and tangencial view for each of the devia-

tions. The resulting lunate fossa depression in each X-ray film was analyzed by the AutoCAD 2010[®] software. **Results:** The tangencial view was the best one to see the 1mm and 3mm bone degrees and the second one view to see the 2mm and 5 mm degrees. The pronated oblique view was the best to see the 2mm degrees and the oblique supinated view wasn't able to see the degrees between 1 and 2mm.

Conclusion: The tangencial view was the best one to see the 1mm and 3mm bone degrees and the second one view to see the 2mm and 5 mm degrees.

Keywords - Radius Fractures/radiography; Radius Fractures/surgery; Cadaver

INTRODUCTION

Fractures of the distal extremity of the radius account for approximately a sixth of the fracture of the human body. With greater exposure to high-energy trauma in large cities, and increasing life expectancy among the population, the number of intra-articular fractures has increased in the same proportion⁽¹⁾.

The semilunar fossa is a common component in radial fractures, and may be the only component affected. This lesion pattern results from axial loads, which cause the semilunar to collide with its fossa, thereby fragmenting it, and this is known as a die-punch fracture.

Studies on fractures of the distal region of the radius with long follow-ups have correlated the functional result with maintenance of the anatomical parameters, and have cited that one of the factors giving

a poor prognosis is modification of the joint congruence, in which joint steps of 1 or 2 mm would lead to symptomatic arthrosis in a large percentage of the patients⁽²⁾.

Given the great difficulty in making pre and intra-operative evaluations on this fragment, there has been much study on this subject. Computed tomography evaluation before the operation is the gold standard⁽³⁾. However, intra and postoperative evaluation is made difficult because of the presence of plates, external fixators and metal wires.

It has been demonstrated that the tangencial incidence of the dorsal edge of the radius (75° with the plane of the table, with maximum flexion of the wrist) provides an excellent view of the dorsal surface of the radius during the operation, thus assisting in controlling the size of the screw, in order to avoid tendon lesions (Figure 1)⁽⁴⁾.

1 - Assistant physician of the Hand Surgery and Microsurgery Group, Irmandade da Santa Casa de Misericórdia de São Paulo – São Paulo, SP, Brazil.

2 - Resident physician of the orthopedics and traumatology service of the Irmandade da Santa Casa de Misericórdia de São Paulo – São Paulo, SP, Brazil.

3 - Resident physician of the orthopedics and traumatology service of the Irmandade da Santa Casa de Misericórdia de São Paulo – São Paulo, SP, Brazil.

4 - Doctor and Head of the Hand Surgery and Microsurgery Group, Irmandade da Santa Casa de Misericórdia de São Paulo – São Paulo, SP, Brazil.

5 - Doctor and Senior Consultant of the Hand Surgery and Microsurgery Group, Irmandade da Santa Casa de Misericórdia de São Paulo – São Paulo, SP, Brazil.

Work carried out in the Orthopedics and Traumatology Department of the Irmandade da Santa Casa de Misericórdia de São Paulo, SP. Correspondence: Bruno Eiras Crepaldi

Rua Pedro Doll 531 ap 81 Santana, São Paulo. CEP 02404-001 E-mail: brunoecrepaldi@yahoo.com.br

Received for publication: 04/19/2011, accepted for publication: 07/19/2011

The authors declare that there was no conflict of interest in conducting this work

This article is available online in Portuguese and English at the websites: www.rbo.org.br and www.scielo.br/rbort

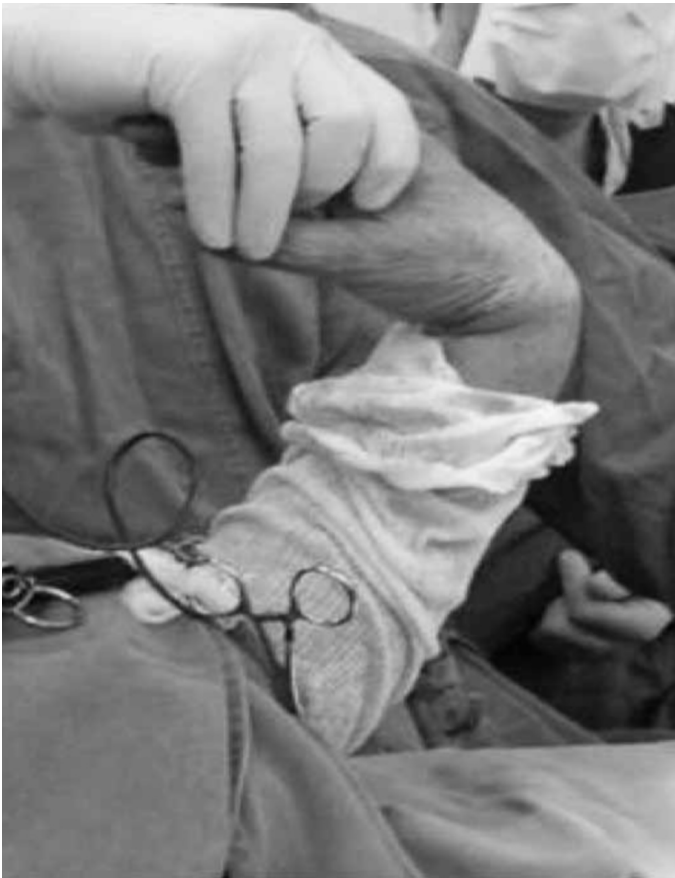

Figure 1 – Tangential view with the forearm at 75° to the plane of the table, wrist at maximum flexion and ampulla perpendicular to the table.

Based on that study⁽⁴⁾, we developed a cadaver study in which the aim was to demonstrate what the best view would be for assessing the deviation of the dorsal edge of the radius in die-punch fractures.

MATERIAL AND METHODS

A frozen cadaver radius without signs of previous trauma or deformity was used to conduct this study. It came from the “Salvador Arena” Tissue Bank of the Department of Orthopedics and Traumatology, Hospital Irmandade da Santa Casa de Misericórdia de São Paulo. After cleaning and removal of the soft tissue, osteotomy was performed using an oscillating microsaw and a hammer and chisel, on the dorsal face of the semilunar fossa, as far as 4 cm proximally to the joint. A metaphyseal bone failure of around 3 cm was made, leaving the distal fragment with only 1 cm, containing the joint surface (Figure 2).

This fragment was positioned with joint steps of 1, 2, 3 and 5 mm, using colorless adhesive tape, such that this would interfere as little as possible with the real and radiographic viewing. The steps were mea-

sured using digital calipers (Tools Club Ferramentas Ltda®) (Figure 3).

The specimen was studied radiographically using the following views: front, lateral, oblique semi-pronated (OSP), oblique semi-supinated (OSS) and tangential to the dorsal edge, at 75° with the plane of the table (Figure 4).

The radiographic images were photographed and subsequently analyzed using the AutoCAD 2010® software, through which the joint steps were measured (Figure 5).

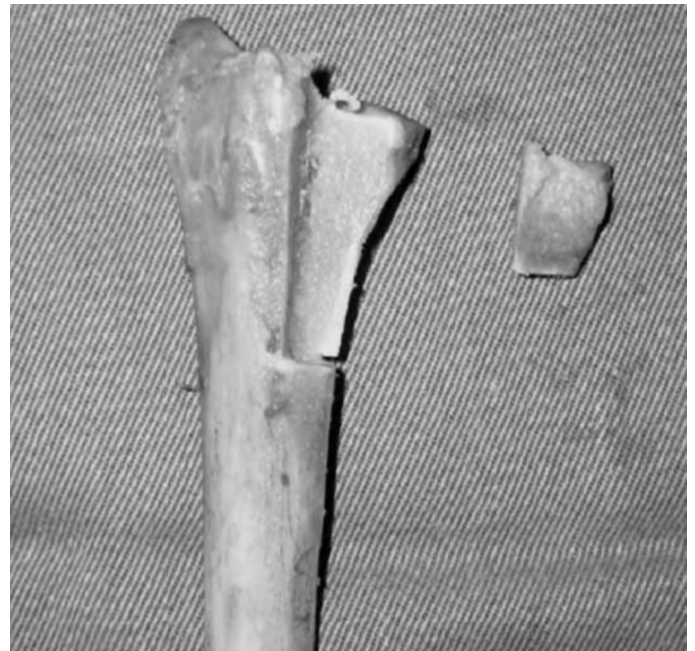

Figure 2 – Photograph of the dorsal face of the distal region of the radius, demonstrating the bone failure and the distal fragment that separated.

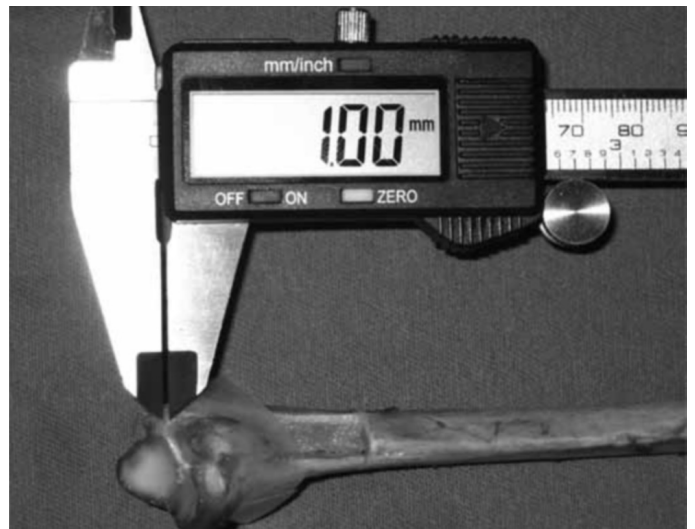

Figure 3 – Joint step of 1 mm, measured using digital calipers, and bone fragment fixed with colorless adhesive tape.

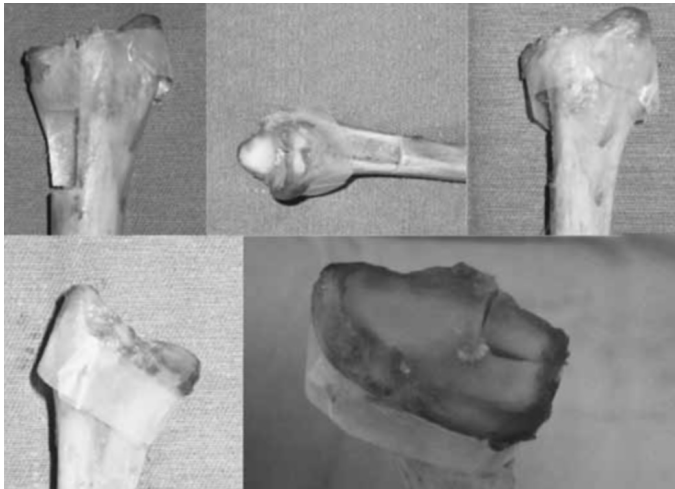


Figure 4 – Position of the radius during radiographs in the following views: (A) front; (B) lateral; (C); OSP; (D) OSS; and (E) tangential.

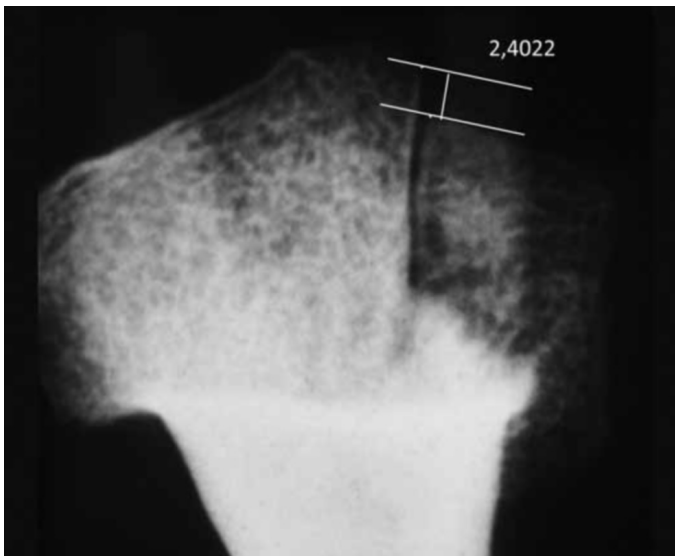


Figure 5 – Deviation of 3 mm in tangential view, with respective measurements using the AutoCAD 2010® software.

RESULTS

The joint steps measured were reported in Table 1 and Figure 6. When no step was seen on the radiograph, it was represented as 0. The radiographs, with all the deviations and all the views, are grouped in Figure 7.

DISCUSSION

Because of the great difficulty in evaluating joint deviations in the dorsal-ulnar fragment during and after the operation, and because a good view of the dorsal surface of the radius is achieved tangentially⁽⁴⁾, it was decided to compare the capacity to perceive joint deviations of this fragment with different radio-

Table 1. Observations in millimeters of the radiographic representation of each joint step produced through osteotomy, according to the front, lateral, OSP, OSS and tangential views.

| Deviation | 1 mm | 2 mm | 3 mm | 5 mm |
|------------|--------|--------|--------|--------|
| Front | 0.1123 | 0.3466 | 1.5908 | 3.4341 |
| Lateral | 0.5123 | 0.6803 | 1.3366 | 4.0232 |
| OSP | 1.4998 | 2.0053 | 2.2259 | 2.9209 |
| OSS | 0 | 0 | 2.2782 | 4.7878 |
| Tangential | 1.5246 | 1.8076 | 2.4022 | 4.9646 |

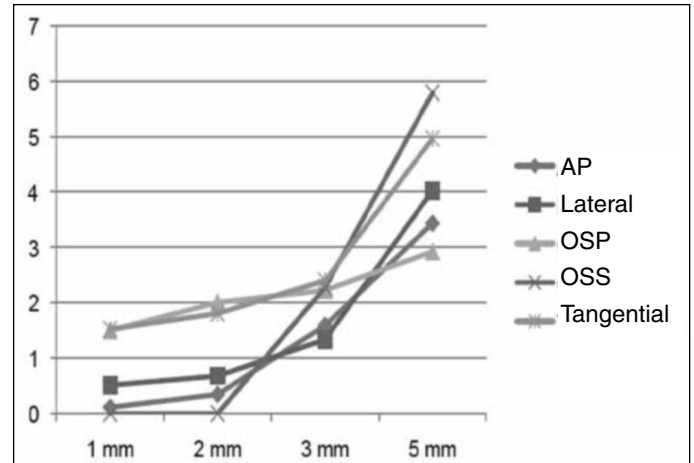


Figure 6 – Amount of the joint step on the x-axis and its radiographic representation, according to view, on the y-axis. Dentro da figura: AP, Lateral, OSP, OSS, Tangential.

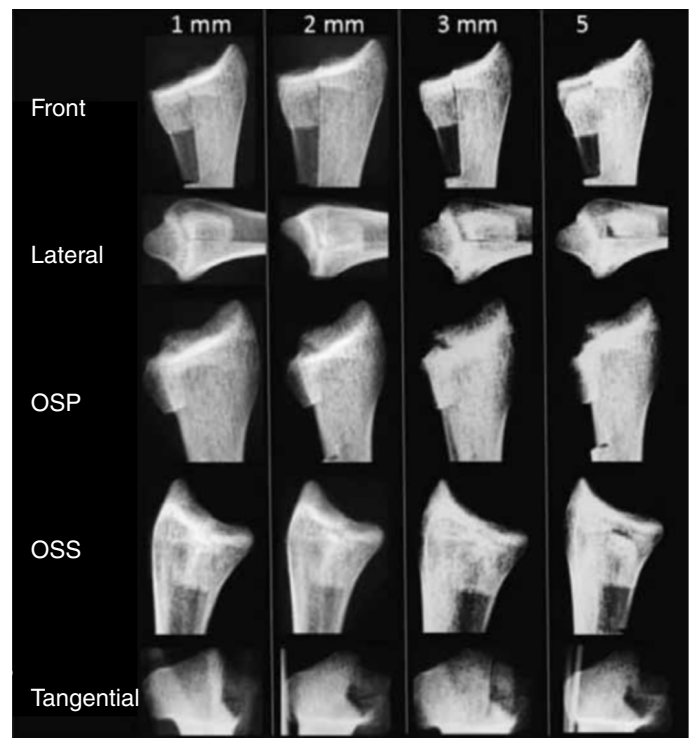


Figure 7 – Radiographs with joint steps of 1, 2, 3 and 5 mm in the front, lateral, OSP, OSS and tangential views.

graphic views, with the aims of better prevention and avoidance of symptomatic arthrosis and biomechanical alterations to the carpus.

In fact, as demonstrated by Cole et al⁽³⁾, computed tomography is the gold standard examination for diagnosing intra-articular fractures of the distal region of the radius, in order to assess the deviations and the number and size of the fragments. It is a good tool for attempting to avoid symptomatic arthrosis and biomechanical alterations to the carpus⁽⁵⁾. Nonetheless, despite the possibility of using it during the operation, the use of implant materials made of metal alloys hinders image formation in tomography. This leaves radioscopy and radiography as the methods for evaluating the reduction and fixation.

With regard to the best view for such evaluations, and in addition to the conventional views, Lundy et al⁽⁶⁾ advocated the lateral view at an elevation of around 22° (joint profile of the radius) in order to assess the subsidence within the joint. This would help to diminish the error in measuring the intra-articular deviation. Moreover, Lee et al⁽⁷⁾ demonstrated that the “discontinuity” of the line of the radial and ulnar cortical bone, in millimeters, in oblique view, was the best way of assessing rotational deviations.

In our study, it was seen that with a 1 mm deviation, the joint step was best observed in tangential view, followed by OSP. With a deviation of 2 mm, the best view was OSP, followed by tangential. For deviations of 3 mm, it was observed that the tangen-

tial view was again superior to OSS. Lastly, with a deviation of 5 mm, the step was seen best using OSS followed by the tangential view. In our study, it was not possible to view joint deviations of 1 or 2 mm in OSS view.

The tangential view presented the greatest constancy in evaluation the joint step of the dorsal-ulnar fragment, given that there was a relatively proportional increase in the viewing of the deviation as the joint step was increased.

The OSS view was not shown to be of interest for evaluating smaller deviations (1 and 2 mm), while OSP was not among the best views for evaluating the greatest deviation (5 mm), as demonstrated in Figure 6.

Thus, if evaluation of the tangential view is added to the front, lateral, OSS and OSP views, the accuracy of analyses on reduction and fixation of dorsal-ulnar fragments can be improved, given the constancy of perception of the joint steps.

In surgical practice, there will be greater difficulty in observing the step in tangential view, because of the overlapping of the carpal bones, which hinder the view. However, the oblique and lateral views will also be hindered by the presence of the ulna.

CONCLUSION

In the model studied, the tangential incidence was best for evaluating joint steps of 1 mm and 3 mm and second best when steps of 2 mm and 5 mm were produced.

REFERENCES

1. Ilyas AM, Jupiter JB. Distal radius fractures--classification of treatment and indications for surgery. *Hand Clin.* 2010;26(1):37-42.
2. Pruitt DL, Gilula LA, Manske PR, Vannier MW. Computed tomography scanning with image reconstruction in evaluation of distal radius fractures. *J Hand Surg Am.* 1994;19(5):720-7.
3. Cole RJ, Bindra RR, Evanoff BA, Gilula LA, Yamaguchi K, Gelberman RH. Radiographic evaluation of osseous displacement following intra-articular fractures of the distal radius: reliability of plain radiography versus computed tomography. *J Hand Surg Am.* 1997;22(5):792-800.
4. Pinheiro Júnior M, Costa AC, Chakkour I. Qual a melhor incidência radiográfica para avaliar a proeminência dos parafusos na face dorsal do rádio? Estudo cadavérico. In: *Anais do 29º Congresso Brasileiro de Cirurgia da Mão.* São Paulo: Sociedade Brasileira de Cirurgia da Mão; 2009.
5. Batra S, Gupta A. The effect of fracture-related factors on the functional outcome at 1 year in distal radius fractures. *Injury.* 2002;33(6):499-502.
6. Lundy DW, Quisling SG, Lourie GM, Feiner CM, Lins RE. Tilted lateral radiographs in the evaluation of intra-articular distal radius fractures. *J Hand Surg Am.* 1999;24(2):249-56.
7. Lee SK, Shin R, Zingman A, Loona J, Posner MA. Correlation of malrotation deformity in distal radius fractures with radiographic analysis: cadaveric study. *J Hand Surg Am.* 2010;35(2):228-32.