JOURNAL OF NEUROSURGERY:
Case Lessons

J Neurosurg Case Lessons 10(23): CASE25653, 2025
DOI: 10.3171/CASE25653

A rare anatomical variant of the relationship between a branch of the superior cerebellar artery and the rootlets of the trochlear nerve: illustrative case

Michał Mordarski,[1] Kacper Bąk,[1] Jędrzej Bartoszcze,[1] Tomasz Iskra, MD, PhD,[1] Sanjib K. Ghosh, MD,[2] Shusaku Noro, MD,[3] and Jerzy A. Walocha, MD, PhD[1]

[1]Department of Anatomy, Jagiellonian University Medical College, Kraków, Poland; [2]All India Institute of Medical Sciences Patna, Bihar, India; and [3]Department of Neurosurgery, Nakamura Memorial Hospital, Sapporo, Japan

BACKGROUND The superior cerebellar artery (SCA) typically has the most consistent course of the infratentorial branches; however, variations do occur. Originating near the basilar artery (BA) bifurcation, the SCA proceeds to its pontomesencephalic segment, where it may contact the trochlear nerve (cranial nerve [CN] IV) or its rootlets emerging dorsally from the brainstem.

OBSERVATIONS During routine dissection, a previously undescribed SCA variation was identified. The left SCA arose as a single trunk from the BA and divided into the rostral trunk (RoTr) and caudal trunk. The RoTr then bifurcated into the medial hemispheric artery (inferior branch) and vermian artery (superior branch). The superior branch of the RoTr gave rise to the precerebellar artery, which coursed 3.2 mm before passing between two trochlear nerve rootlets in the rootlet exit zone.

LESSONS Understanding complex anatomical variations of the SCA and its relationship to CN IV is crucial for accurate diagnosis of the trochlear nerve dysfunction and for effective surgical planning. A thorough understanding of these variations enables physicians to anticipate potential challenges and adapt their approach accordingly. Intraoperative identification of unexpected vascular patterns underscores the importance of the surgeon's knowledge of anatomical variability, which may significantly impact both safety and surgical strategy.

https://thejns.org/doi/abs/10.3171/CASE25653

KEYWORDS trochlear nerve; rootlets; superior cerebellar artery; superior oblique myokymia; microvascular decompression; case report

It is estimated that vision provides the most nonverbal information,[1] so it is crucial to have proper eye movement and coordination, for which, among others, the fourth cranial nerve (CN IV) is responsible. It is made of somatoefferent fibers innervating the contralateral superior oblique muscle (SO). However, some studies have indicated the possibility of fusion with few sympathetic fibers and a small number of sensory fibers from the trigeminal nerve (CN V).[2] Any pressure applied to CN IV, by tumor, aneurysm, or even artery, can affect its function and, as a result, fail to send impulses to the SO.[2]

CN IV can be generally divided into five segments: brainstem, cistern (subarachnoid), tentorium, cavernous sinus, and orbit.[3] The origin of approximately 2100 axons can be found in the trochlear nuclei located in the midbrain at the level of the inferior colliculus, caudal to the oculomotor nucleus and ventral to the sylvian duct.[4] CN IV exits the dorsal side of the brainstem inferior to the inferior colliculus, emerging as a variable number of rootlets (ranging from 1 to 6).[3] The trochlear nerve courses anterolaterally around the lateral aspect of the midbrain, then passes forward to enter the cavernous sinus running within its lateral wall. Then CN IV traverses the superior orbital fissure at its superomedial part outside the annulus of Zinn (common annulus tendineus) and ends innervating the SO.[5]

As previously mentioned, CN IV pathologies can be caused, among other things, by an arterial pressure, in some cases originating from the superior cerebellar artery (SCA), and manifest itself as superior oblique myokymia (SOM).[6] The SCA arises near the bifurcation of the basilar artery (BA), extends to the pontomesencephalic junction, and encircles the brainstem running through the cerebellomesencephalic fissure.[7] The SCA primarily supplies the superior (upper) portions of the cerebellum, including the cerebellar hemispheres and the vermis. Additionally, the SCA supplies parts of the midbrain, including the tectum and superior cerebellar peduncles.[7,8] Despite being considered one of the most consistent infratentorial branches, exceptions occur and are well described.[7,9,10] Most conflicts with the SCA are related to the trigeminal nerve, rarely to the trochlear nerve.[11] The tentorial

ABBREVIATIONS BA = basilar artery; CN = cranial nerve; MVD = microvascular decompression; PTFE = polytetrafluoroethylene; REZ = root exit zone; RoTr = rostral trunk; SCA = superior cerebellar artery; SO = superior oblique muscle; SOM = superior oblique myokymia; Ø = diameter.

INCLUDE WHEN CITING Published December 8, 2025; DOI: 10.3171/CASE25653.
SUBMITTED August 22, 2025. **ACCEPTED** October 3, 2025.
© 2025 The authors, CC BY-NC-ND 4.0 (http://creativecommons.org/licenses/by-nc-nd/4.0/)

segment of CN IV passes above the midportion of the lateral pontomesencephalic artery's segment, and even with close neurovascular location, the dorsal surface of the nerve usually is free from the SCA branches.[8] However, given that variation is a rule rather than an exception, there is a possibility of contact and neurovascular cross-compression.[12]

The aim of this study was to present the variation in the relationship between the trochlear nerve and the SCA, where a branch of the artery runs between nerve rootlets and touches them in the root exit zone (REZ), which has not been described by other authors.[3] This knowledge may be crucial in diagnosing trochlear nerve dysfunctions or during surgical correction of SOM using microvascular decompression (MVD) techniques.

Illustrative Case

During a routine dissection performed for teaching and research purposes at the Department of Anatomy, Jagiellonian University Medical College, Kraków,[13] a branch of the SCA running between the rootlets of the trochlear nerve was found. The subject of the dissection was the cadaver of a man who was 93 years of age at death.

The left SCA arose as the single trunk from the BA at 26.4 mm along its course. The diameter (Ø) of the left SCA measured 1.5 mm, and that of the BA measured 4.2 mm; the total length of the BA was 29.7 mm. At 10.4 mm along its trajectory, the SCA gave rise to the marginal artery (Ø 1 mm). At 29.9 mm from its point of origin, the SCA divided into the rostral trunk (RoTr) (Ø 1.3 mm) and the caudal trunk (CaTr) (Ø 0,8 mm). After 10.2 mm, the RoTr divided into two branches: medial hemispheric artery (inferior branch) (Ø 0.9 mm) and vermian artery (superior branch) (Ø 0.9 mm) (Fig. 1). At 2.5 mm from its point of origin, the superior branch of the RoTr gave rise to the precerebellar artery (Ø 0.2 mm), which after 3.2 mm ran between two rootlets of the trochlear nerve (Fig. 2A). The length of the medial rootlet (Ø 0.1 mm) was 2.6 mm, and that of the lateral rootlet (Ø 0.4 mm) was 2.2 mm. The rootlets merged to form a single bundle of the trochlear nerve (Ø 0.5 mm) that turned anterolaterally directly on the division of the RoTr (Fig. 2B), exerting significant tension on CN IV.

Methods

Dissection and examination were performed using a neurosurgical microscope (Leica M500-N, Leica Microsystems). All measurements were carried out with the help of a digital caliper (Lux-Tools) with a precision of 0.02 mm. Each measurement was performed three times and was repeated by two independent investigators. The mean value was subsequently calculated and rounded to one decimal place. Every stage of this work was carried out in accordance with the requirements of the Declaration of Helsinki. The donor of the body signed a donation certificate. The cadaver was routinely fixed in 5% formalin solution.

Informed Consent

The necessary informed consent was obtained in this study.

Discussion

Observations

The close relationship of the trochlear nerve and the SCA along their course has been well described in the literature, and various possible variants, based on the part of CN IV that is compressed or the structure causing compression, have been reported.

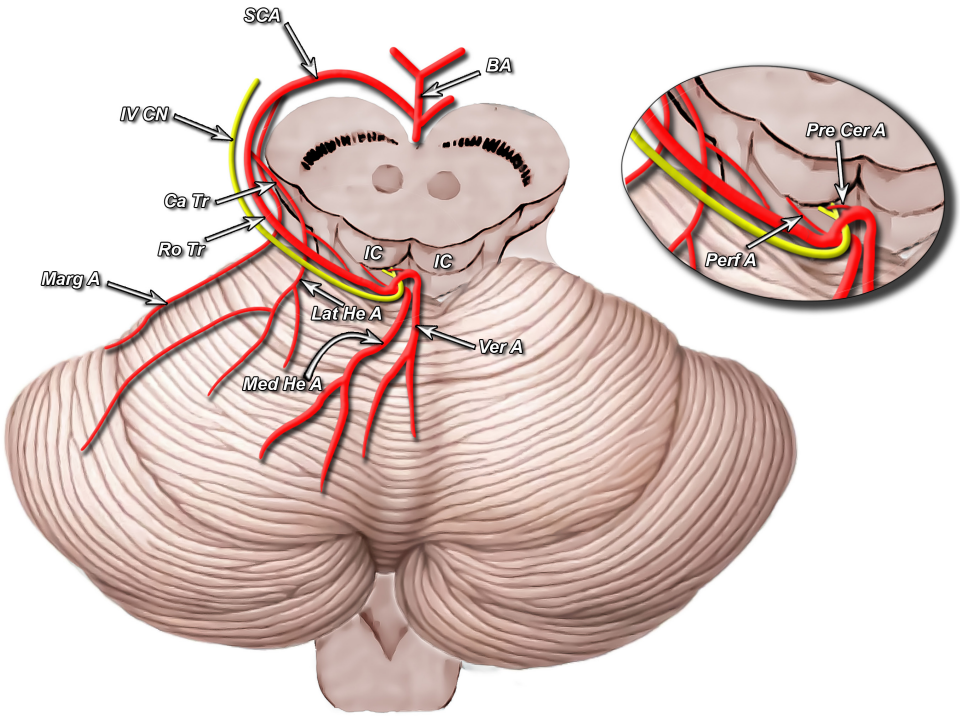

FIG. 1. Schematic view of the branching pattern of the SCA and its relationship with CN IV. Ca Tr = caudal trunk; IC = inferior colliculus; Lat He A = lateral hemispheric artery; Marg A = marginal artery; Med He A = medial hemispheric artery; Perf A = perforating artery; Pre Cer A = precerebellar artery; Ro Tr = rostral trunk; Ve A = vermian artery.

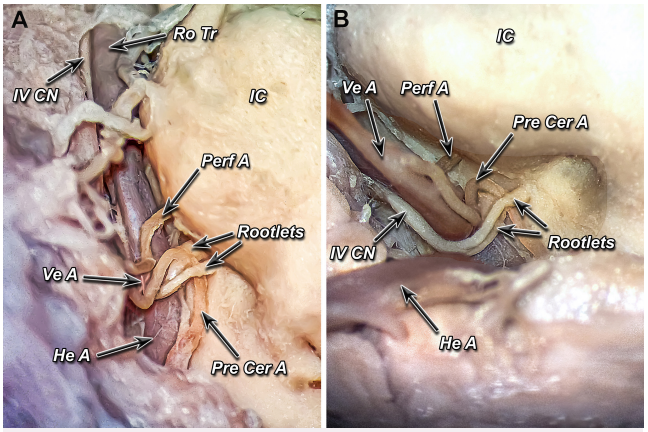

FIG. 2. Posteromedial view of the trochlear nerve (CN IV) REZ. **A:** The precerebellar artery (Pre Cer A) passes between the rootlets of CN IV. **B:** The trochlear nerve changes its course directly at the bifurcation of the rostral trunk (Ro Tr) of the SCA. He A = hemispheric artery; IC = inferior colliculus; Perf A = perforating artery; Ve A = vermian artery.

In 2002, Yousry et al.[14] identified arterial nerve-vessel contact in 8 of 57 trochlear nerves (14.04%). In 2 specimens (3.51%), contact was detected at the REZ, and in 6 specimens (10.53%), at a distance of 1 mm from the REZ. Other researchers noticed that the trochlear nerve can be found compressed between the brainstem and the artery or pinched between the branches of the SCA.[8,15–24] A case in which the trochlear nerve was jammed between two branches of the RoTr has been previously described;[8] however, in the anatomical variation presented in this article, the superior branch of the RoTr that encloses the trochlear nerve gives rise to a perforating branch that runs directly between two rootlets of CN IV.

Close contact of vessels and nerves may lead to the cross-compression of these anatomical structures, which can cause pathological changes, for example, hyperactive dysfunction of the nucleus, pressure-induced demyelination, ectopic generation of ephaptic impulse transmissions along the affected nerve, and reduced blood flow—disturbance of the intraneural microcirculation.[25] Stretching, displacement, and/or neurovascular compression of the trochlear nerve can have clinical consequences such as SOM, trochlear nerve palsy, neurovascular compression syndrome, and consecutive spasms. In cases of the SOM in which a direct compression of the trochlear nerve by the artery (mainly branches of the SCA) is identified on MRI and MRA, a neurosurgical MVD may be considered.[6] MVD is a procedure in which the trochlear nerve is dissected free and the artery is transposed far from the nerve. Intraoperatively, the REZ of the trochlear nerve is a critical area that must always be inspected. However, if the surgeon is unaware that the nerve may consist of multiple rootlets rather than a single one,[3] there is a real risk of missing the true site of compression. To prevent further contact, Teflon (polytetrafluoroethylene [PTFE]) grafts with fibrin glue are commonly used;[6] however, muscle autografts or artificial dura mater can also be used.[20,22] In all the cases found in the literature, MVD of the trochlear nerve resulted in the immediate resolution (Table 1). In only 1 of the 11 cases described in this report was partial return of the symptoms reported.[22]

During the MVD procedures for other cranial nerves, nonabsorbable materials (PTFE, polyurethane, expanded PTFE, and silk thread) and absorbable materials (fibrin glue, cellulose, gelatin, and collagen) are widely used in combination or alone.[26–28] Ethyl cyanoacrylate was reported to be harmful in the neurosurgical field (it has been suggested that cyanoacrylate induces necrosis of the vascular wall with giant cell infiltration and destruction of the smooth muscle cell layer);[26] however, the use of cyanoacrylate as an adhesive in MVD procedures has been recently reported.[29,30] In cases in which PTFE and expanded PTFE were used, the highest rate of adverse events was reported (it is believed that these associations are related to the operative procedure, which requires a relatively complicated technique, and are not affected directly by the kind of implemented materials); nevertheless, Teflon is used in most of the cases.[26] Moreover, it was observed in the case of the trigeminal nerve that interposition (positioning the prosthesis in contact with the nerve) with any material may result in adhesion of the implant to the affected nerve and cause recurrence of the symptoms.[26,31,32]

The MVD procedures on the intraneural vessels have been described in cases involving the trigeminal nerve and the facial and intermediate nerves.[33–40] Depending on the type of offending vessel and its size, a few methods of MVD treatment have been reported. After visualization of the nerve, dissection, and mobilization of the arteries, the offending vessel is reshaped to avoid compression of the nerve, if possible, and then wrapped in Teflon (hot dog method) and/or anchored away from the point of compression and the REZ.[33–38] If an intraneural offending vein is present, coagulating and cutting methods are preferred.[34,39,40]

No other description of the branch of the SCA that runs between the rootlets of the trochlear nerve was found in the literature.[3] That course of the artery can exert a lot of pressure on CN IV, risking damage to the rootlets during MVD, and may make it impossible to retract away the artery for the placement of the synthetic material or autograft used in the other cases to decompress the nerve.[15–17,19–24] However, if the anatomical variant we described were to become symptomatic and require surgical treatment, our approach would be to carefully dissect between the trochlear nerve and the SCA, and then consider mobilizing the SCA toward the peripheral side of the nerve. Since the SCA may have perforating branches, it is essential to carefully evaluate their presence before proceeding.

Limitations

The presented case report is not without limitations. As it was a cadaveric study, no information about the patient's clinical condition is available.

Lessons

This anatomical configuration is extremely difficult to visualize on MRI or MRA,[41,42] which makes incorporating it into preoperative planning a significant challenge. For this reason, when an unexpected vascular arrangement is encountered intraoperatively, the surgeon's understanding of such anatomical variations can have a decisive impact on both the safety of the procedure and the chosen surgical strategy.[21] Importantly, this perspective is significant not only for neurosurgeons but also for neuro-ophthalmologists, neurologists, and physiologists. The anatomical diversity and potential functions of the trochlear nerve may prompt a reevaluation of ocular motor physiology and the broader networks of the CNS.

Acknowledgments

We sincerely thank those who donated their bodies to science so that anatomical research could be performed. Results from such research can potentially improve patient care and increase mankind's overall

TABLE 1. Case reports of neurosurgical MVD for SOM

Authors & Year	Age (yrs)	Sex	Side	Disease Duration (yrs)	Pre-MVD Tx	Offending Vessel	Approach	Material Used	Result	FU Period (mos)	Complications	Location 1*	Location 2†
Samii et al., 1998[15]	50	M	Rt	>17	CBZ, PHT, VPA, PRM, BTX	Small artery	Lat suboccipital retrosigmoid	Teflon pads	Complete resolution	22	Trochlear nerve palsy w/ diplopia on downgaze for 5 mos	REZ	Ventral
Hashimoto et al., 2004[16]	49	M	Lt	8	CBZ, BAC	SCA branch	Retrosigmoid	Teflon pads	Complete resolution	12	Trochlear nerve palsy for 3 mos	REZ	Dorsal
Mikami et al., 2005[17]	67	M	Lt	>11	CBZ, PHT, BAC	SCA branch	Occipital interhemispheric transtentorial	Teflon felt	Complete resolution	18	—	REZ	Ventral
Asaoka et al., 2008[18]	46	M	Rt	6	NA	SCA branch	Paramedian supracerebellar	NA	Complete resolution	NA	NA	REZ	NA
Fam et al., 2014[19]	47	M	Rt	6	CBZ, GBP, BAC, timolol eye drops	SCA branch	Retrosigmoid	Teflon pads	Complete resolution	12	—	REZ	Dorsal‡
Kawasaki et al., 2019[20]	77	F	Lt	2	—	SCA branch	Lat supracerebellar	Artificial dura mater (Gore-Tex)	Complete resolution	24	Trochlear nerve palsy for 2 wks	REZ	Ventral & dorsal‡
Noro et al., 2022[21]	37	M	Lt	4	CBZ, GBP	SCA branch	Lat supracerebellar infratentorial	Teflon felt	Complete resolution	24	Trochlear nerve palsy w/ diplopia on downgaze for 9 mos	REZ	Ventral & dorsal
Noro et al., 2022[21]	56	M	Rt	3	CBZ, GBP, BAC, timolol eye drops	SCA branch	Lat supracerebellar infratentorial	Teflon felt	Complete resolution	17	—	REZ	Ventral
Jabarkheel et al., 2024[22]	51	F	Rt	Several§	BAC, timolol, GBP	SCA branch	Endoscopic lat supracerebellar infratentorial	Nuchal muscle autograft	Complete resolution¶	12	—	REZ	Dorsal
Vignolles-Jeong et al., 2025[23]	40	F	Rt	<1	—	SCA branch	Endoscopic supracerebellar infratentorial	Teflon pledgets	Complete resolution	6	Trochlear nerve palsy for 6 mos	REZ	NA
Noro et al., 2025[24]	46	M	Lt	6	CBZ	SCA branch	Lat supracerebellar infratentorial	Teflon felt	Complete resolution	22	Trochlear nerve palsy w/ diplopia on downgaze for 9 mos	Peripheral	Wrapped around nerve

BAC = baclofen; BTX = botulinum toxin; CBZ = carbamazepine; FU = follow-up; GBP = gabapentin; NA = not available; PHT = phenytoin; PRM = primidone; Tx = treatment; VPA = valproic acid; — = no pre-MVD treatment/no complications.

* Location of compression of the nerve.

† Location of compressing artery in relation to the nerve.

‡ Location was not directly stated in these articles; data were pulled from another article in which the description was given (Noro et al., 2022).[21]

§ Disease duration not specified by author.

¶ At the 2-month follow-up, there was complete resolution of the SOM symptoms. At the 12-month follow-up, the patient reported a 50% return of the preoperative symptoms.

knowledge. Therefore, these donors and their families deserve our highest gratitude. We also acknowledge Jacenty Urbaniak from the Anatomy Department of the Jagiellonian University Medical College for his excellent technical assistance during the preparation of the figures used in this report.

References

1. Pease AP. *The Definitive Book of Body Language*. Orion Publishing Group; 2005.
2. Kim SY, Motlagh M, Naqvi IA. Neuroanatomy, cranial nerve 4 (trochlear). In: *StatPearls*. StatPearls Publishing; 2023.
3. Bąk K, Mordarski M, Iskra T, et al. Variations in the number of rootlets of the trochlear nerve. *Ann Anat*. 2025;262:152700.
4. Kline LB, Demer JL, Vaphiades MS, Tavakoli M. Disorders of the fourth cranial nerve. *J Neuroophthalmol*. 2021;41(2):176-193.
5. Freddi TAL. The trochlear nerve: anatomy and pathology. *Semin Ultrasound CT MR*. 2022;43(5):400-402.
6. Tandon A, Oliveira C. Superior oblique myokymia, a review. *Curr Opin Ophthalmol*. 2019;30(6):472-475.
7. Dagcinar A, Kaya AH, Pirzirenli ME, et al. The superior cerebellar artery: anatomic study with review. *Neurosurg Q*. 2007;17(3): 235-240.
8. Rusu MC, Vrapciu AD, Pătraşcu JM. Variable relations of the trochlear nerve with the pontomesencephalic segment of the superior cerebellar artery. *Surg Radiol Anat*. 2015;37(5):555-559.
9. Rhoton AL Jr. The cerebellar arteries. *Neurosurgery*. 2000;47(3) (suppl):S29-S68.
10. Błaszczyk M, Dziedzic M, Stachera B, et al. The anatomy of the superior cerebellar artery: a detailed analysis. *Folia Morphol (Warsz)*. 2025.
11. Ballesteros-Acuña L, Gómez-Torres F, Estupiñán HY. Morphologic characterization of the superior cerebellar artery. A direct anatomic study. *Transl Res Anat*. 2021;25:100150.
12. Snow EL. Variation is the rule: insights about translational research on anatomical variations. *Transl Res Anat*. 2024;37:100333.
13. Wysiadecki G, Varga I, Klejbor I, et al. Reporting anatomical variations: should unified standards and protocol (checklist) for anatomical studies and case reports be established? *Transl Res Anat*. 2024; 35:100284.
14. Yousry I, Moriggl B, Dieterich M, Naidich TP, Schmid UD, Yousry TA. MR anatomy of the proximal cisternal segment of the trochlear nerve: neurovascular relationships and landmarks. *Radiology*. 2002;223(1):31-38.
15. Samii M, Rosahl SK, Carvalho GA, Krzizok T. Microvascular decompression for superior oblique myokymia: first experience. Case report. *J Neurosurg*. 1998;89(6):1020-1024.
16. Hashimoto M, Ohtsuka K, Suzuki Y, Minamida Y, Houkin K. Superior oblique myokymia caused by vascular compression. *J Neuroophthalmol*. 2004;24(3):237-239.
17. Mikami T, Minamida Y, Ohtsuka K, Houkin K. Resolution of superior oblique myokymia following microvascular decompression of trochlear nerve. *Acta Neurochir (Wien)*. 2005;147(9):1005-1006.
18. Asaoka K, Terasaka S, Suzuki Y. Microvascular decompression for superior oblique myokymia: case report and review of the literature. *Skull Base*. 2008;18(S 01).
19. Fam MD, Scott C, Forster A, Kamel MH. Microvascular decompression for superior oblique myokymia: case report. *Br J Neurosurg*. 2014;28(4):552-555.
20. Kawasaki T, Fujitsu K, Ichikawa T, et al. Superior oblique myokymia: a case report of surgical treatment, review of the literature, and consideration of surgical approach. *World Neurosurg*. 2019; 131:197-199.
21. Noro S, Seo Y, Honjo K, et al. Lateral supracerebellar infratentorial approach for superior oblique myokymia: a case series. *Oper Neurosurg*. 2022;22(3):101-105.
22. Jabarkheel R, Tomlinson S, Borja AJ, Ajmera S, Miranda SP, Lee JYK. Fully endoscopic microvascular decompression of the trochlear nerve for treatment of medically refractory superior oblique myokymia: technical case instruction and operative video. *Oper Neurosurg*. 2024;29(1):135-138.
23. Vignolles-Jeong J, Finger G, Damante M, Weber MD, Wu KC, Prevedello DM. Trochlear nerve decompression by endoscopic suboccipital supracerebellar infratentorial approach: a technical note: 2-dimensional operative video. *Oper Neurosurg*. 2025;29(3): 434-439.
24. Noro S, Asayama B, Saiki S, et al. Superior oblique myokymia caused by vascular compression in the peripheral trochlear nerve: a case report. *Neurosurg Pract*. 2025;6(2):e00132.
25. Marinković S, Gibo H, Zelić O, Nikodijević I. The neurovascular relationships and the blood supply of the trochlear nerve: surgical anatomy of its cisternal segment. *Neurosurgery*. 1996;38(1): 161-169.
26. Hasegawa M, Hatayama T, Kondo A, et al. Prosthesis used in microvascular decompressions: a multicenter survey in Japan focusing on adverse events. *World Neurosurg*. 2019;130: e251-e258.
27. Park JS, Ahn YH. Glossopharyngeal neuralgia. *J Korean Neurosurg Soc*. 2023;66(1):12-23.
28. Peng W, Zhao R, Guan F, et al. Fully endoscopic microvascular decompression for the treatment of hemifacial spasm, trigeminal neuralgia, and glossopharyngeal neuralgia: a retrospective study. *BMC Surg*. 2023;23(1):331.
29. Kanazawa R, Uchida T, Higashida T, Watanabe S, Takahashi Y, Yamazaki K. Use of n-butyl-2-cyanoacrylate for microvascular decompression in a Jehovah's Witness patient. *Br J Neurosurg*. 2024; 38(6):1479-1482.
30. Zheng WJ, He R, Zhang X, et al. Glue-transposition technique for hemifacial spasm involving vertebrobasilar dolichoectasia: a comparative study and literature review. *Neurosurg Rev*. 2025;48(1): 495.
31. Sindou M, Leston JM, Decullier E, Chapuis F. Microvascular decompression for trigeminal neuralgia: the importance of a non-compressive technique—Kaplan-Meier analysis in a consecutive series of 330 patients. *Neurosurgery*. 2008;63(4)(suppl 2):341-50.
32. Matsushima T, Yamaguchi T, Inoue TK, Matsukado K, Fukui M. Recurrent trigeminal neuralgia after microvascular decompression using an interposing technique. Teflon felt adhesion and the sling retraction technique. *Acta Neurochir (Wien)*. 2000;142(5):557-561.
33. Wakuta N, Abe H, Nonaka M, Higashi T, Ueba T, Inoue T. Management of trigeminal neuralgia caused by an intraneural spiral trigeminocerebellar artery: a case report. *J Neurol Surg Rep*. 2015;76(1): e59-e61.
34. Zheng X, Feng B, Hong W, et al. Management of intraneural vessels during microvascular decompression surgery for trigeminal neuralgia. *World Neurosurg*. 2012;77(5-6):771-774.
35. Takano Y, Tanaka Y, Kaneoka A, Imamura M, Tamura K, Maehara T. A case of hemifacial spasm caused by penetration of the anterior inferior cerebellar artery between the facial nerve and the nervus intermedius. *NMC Case Rep J*. 2024;11:371-375.
36. Shen Z, Yu F, Xue F, Wang Y, Kwok SC, Yin J. Treatment strategies for different types of intraneural offending vessels in microvascular decompression surgery for trigeminal neuralgia: an analytic report of 58 cases. *Neurosurgery*. 2022;90(5):562-568.
37. Jito J, Nozaki K. Trigeminal neuralgia attributable to intraneural trigeminocerebellar artery: case report and review of the literature. *World Neurosurg*. 2016;88:687.e7-687.e11.
38. Goto Y, Inoue T. Surgical management of the trigeminocerebellar artery in microvascular decompression for trigeminal neuralgia. *Oper Neurosurg*. 2020;19(4):E379-E384.
39. Helbig GM, Callahan JD, Cohen-Gadol AA. Variant intraneural vein-trigeminal nerve relationships: an observation during

microvascular decompression surgery for trigeminal neuralgia. *Neurosurgery*. 2009;65(5):958-61.
40. Kanayama S, Shono N, Inoue M. The visualization of intraneural venous compression in trigeminal neuralgia by using advanced three-dimensional computer graphics: an illustrative case report. *Cureus*. 2024;16(4):e57935.
41. Kumar T, Virador GM, Brahmbhatt P, et al. High-resolution 7T MR imaging of the trochlear nerve. *AJNR Am J Neuroradiol*. 2023; 44(2):186-191.
42. Noro S, Asayama B, Nakamura H. Microvascular decompression surgery: advances and expansion of strategy and techniques. Springer Nature Singapore; 2025:201-209.

Disclosures
The authors report no conflict of interest concerning the materials or methods used in this study or the findings specified in this paper.

Author Contributions
Conception and design: Bąk, Mordarski, Bartoszcze, Ghosh, Walocha. Acquisition of data: Mordarski, Ghosh. Analysis and interpretation of data: Mordarski, Bartoszcze, Ghosh, Noro. Drafting the article: Bąk, Mordarski, Bartoszcze, Iskra, Ghosh. Critically revising the article: Ghosh, Noro, Walocha. Reviewed submitted version of manuscript: Bąk, Iskra, Ghosh, Noro. Approved the final version of the manuscript on behalf of all authors: Bąk. Administrative/technical/material support: Ghosh.

Correspondence
Kacper Bąk: Jagiellonian University Medical College, Kraków, Poland. bak.kacper@icloud.com.