



King Saud University

Saudi Pharmaceutical Journal

www.ksu.edu.sa  
www.sciencedirect.com



## CASE REPORT

# Toxic keratitis after use of wrongly labeled non-ophthalmic medication



Mohammad A. Al-Amry <sup>a,\*</sup>, Nada Al-Abdan <sup>b</sup>, Saleh A. AL-Othaimen <sup>a</sup>

<sup>a</sup> Anterior Segment Division, King Khaled Eye Specialist Hospital, Riyadh, Saudi Arabia

<sup>b</sup> Pharmacy Division, King Khaled Eye Specialist Hospital, Riyadh, Saudi Arabia

Received 30 March 2015; accepted 18 June 2015

Available online 25 June 2015

## KEYWORDS

Toxic;  
Keratitis;  
Wrong;  
Label;  
Pharmacy;  
Drug dispensing

**Abstract** We present a 24-year-old female with trauma to her right eye. The patient was prescribed topical Tobramycin-dexamethasone eye drops but the pharmacy dispensed diclofenac diethyl amine ointment. The patient presented to the emergency room with lid edema, conjunctival injection and a corneal epithelial defect and toxic keratitis. The patient was successfully managed with copious irrigation, bandage contact lens and topical antibiotic therapy.

© 2015 The Authors. Production and hosting by Elsevier B.V. on behalf of King Saud University. This is an open access article under the CC BY-NC-ND license (<http://creativecommons.org/licenses/by-nc-nd/4.0/>).

## 1. Introduction

The ocular toxicity secondary to topical medications is common after use of anti-glaucoma medications, topical anesthetics and to lesser extent topical antibiotics (Al-Ghadeer, 2010; Chen et al., 2004; Vingesh et al., 2015). Nonsteroidal anti-inflammatory drugs (NSAID) also can cause severe ocular surface complications (Mian et al., 2006).

Systemic medications can cause ocular depositions and toxicity, and the Amiodarone is the classical drug which can reach the eye through the tear film and limbal vessels and results in

corneal whorle-like lines called vortex keratopathy (Turk et al., 2015).

Error of medication treatment process can occur at any stage which includes prescription, transcription and/or administration. However, most commonly, medication error occurs during the prescribing stage and it involves incorrect name, wrong strength and/or frequency of medication (Alsulami and Conroy, 2013 April; Kundsens et al., 2007; Berdot et al., 2012). The errors mostly occurred during the process of transcription and labeling of the medication (Kundsens et al., 2007) generally are not long lasting effects (Mansouri et al., 2013).

We present a case of toxic keratitis after use of wrongly labeled medication at a general hospital.

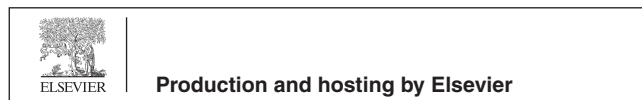
## 2. Case report

A 24-year-old female presented to the emergency room at King Khalid Eye Specialist Hospital (KKESH) complaining of trauma to her right eye after her son's finger contacted the eye. This resulted in a corneal epithelial defect, and she had visited an ophthalmologist elsewhere, who had prescribed topical Tobramycin-dexamethasone combination eye drops to be

\* Corresponding author at: Anterior Segment Division, King Khaled Eye Specialist Hospital, PO Box 7191, Riyadh 11462, Saudi Arabia.

E-mail address: [mamry@kkesh.med.sa](mailto:mamry@kkesh.med.sa) (M.A. Al-Amry).

Peer review under responsibility of King Saud University.



instilled three times a day into the right eye. However, the pharmacist dispensed an ointment after which she developed more redness, pain and, tearing after instilling it into her affected eye on two occasions only. She stopped using the ointment after she discovered that it was (diclofenac diethylamine) skin ointment. The patient's medical history was unremarkable. Visual acuity was 20/20 in both eyes, and the right eye had mild lid swelling, conjunctival injection and corneal epithelial defect with surrounding corneal haze (Fig. 1). The anterior chamber was quiet and the rest of the anterior segment as well as the posterior segment was unremarkable. Left eye examination was normal.

Copious eye irrigation was performed in the emergency room. Her right eye was managed by applying a bandage contact lens and topical antibiotic drops (Ofloxacin 0.3% ophthalmic solution) were prescribed 4 times per day for a week. At last follow-up (one month) the corneal defect in the right eye had completely healed without any significant clinical sequelae. The patient started on Fluorometholone 0.1% eye drops every 6 h for two weeks after which it was slowly tapered down with topical antibiotics.

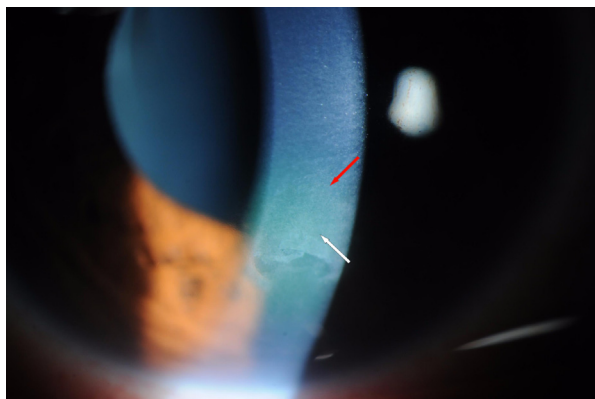
The ointment that the patient had originally instilled in the eye was diclofenac diethylamine 1.16% (which is equivalent to ophthalmic diclofenac sodium 1%) in a 50 g emulsion tube that is usually prescribed to relieve pain, reduce swelling and combat inflammation. Diclofenac diethylamine 1.16% is marketed under the trade name Tabiflex (Tabuk Pharmaceutical Manufacturing Co., Tabuk, Saudi Arabia) (Fig. 2a).

### 3. Discussion

The ocular toxicity secondary to topical medications has been heavily discussed but it is concerned to the ophthalmic preparations such as glaucoma medications, topical anesthetics and to lesser extent topical antibiotics (Al-Ghadeer, 2010; Chen et al., 2004; Vingesh et al., 2015).

Most of these preparations exert its toxic effects through multiple proposed mechanism: directly to create punctate keratopathy, or indirectly by inciting the immune system to create inflammation involving ring shaped stromal infiltration as the case in over use of topical anesthetics and topical nonsteroidal anti-inflammatory drugs NSAID (Chen et al., 2004).

Some of the topical medications can interfere with the migration of the limbal basal epithelial cells especially if



**Figure 1** Slit lamp photograph of the cornea shows an area of corneal epithelial defect with surrounding area of toxic infiltration.

corneal epithelial defects are present causing delayed healing and hence stromal infiltrations.

Ocular toxicity can appear in the form of corneal edema. Vingesh et al. (2015) reported a case of corneal edema after use of moxifloxacin drops used to treat conjunctivitis cause corneal edema with profound drop of vision which cleared after cessation of the drops and return of vision, the proposed mechanism here was that the drug can inhibit the synthesis of collagen iv or damage to the Descemet's membrane and its adjacent endothelial layer causing toxicity appeared as corneal edema.

NSAID can cause upregulations of corneal matrix metalloproteases (MMPs) which will interfere with the corneal epithelial defects healing (Mian et al., 2006).

Systemic medications can cause ocular depositions and toxicity, and the most famous drug is the Amiodarone (anti arrhythmic drug) which can reach the eye through the tear film and limbal vessels and results in powder like deposition of different colors in the corneal basal epithelial and stromal cells under the apex of the cornea appearing as whorle-like lines called vortex keratopathy and causing drug-induced lipidosis (Turk et al., 2015).

Our case had corneal toxicity in the form of delayed healing of the epithelial defect with sick epithelial layer necessitating epithelial debridement associated with moderate stromal infiltrates after wrong application of an analgesic ointment designed for external use.

For our knowledge it is the first report about such incident regionally.

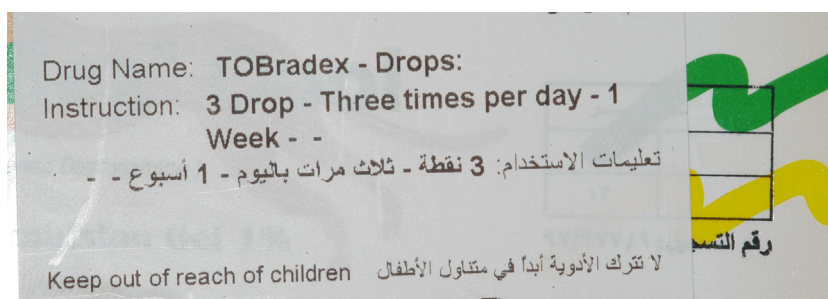
Drug dispensing (medication treatment process) involves three stages: the prescription, the transcription and, finally administration. In the prescription stage the health provider such as a physician will write the medication and through a pharmacist in the transcription stage the medication data will be entered into the pharmacy database and the label is written. Subsequently another pharmacist will double check the medication in the filling substage and finally a third pharmacist will triple check the medication upon release to the patient.

The administration stage is when the patient uses the released medication (Alsulami and Conroy, 2013 April).

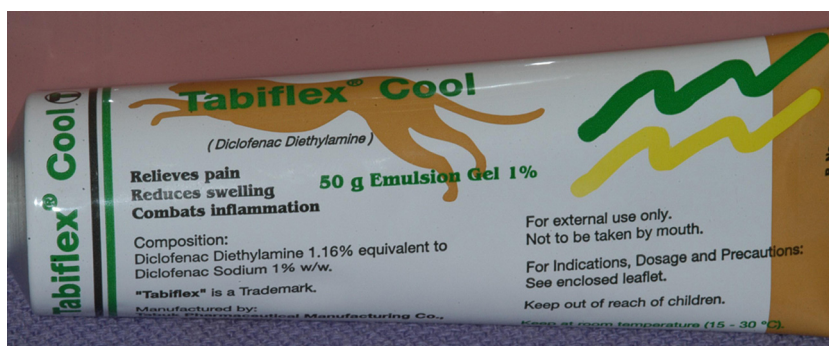Factors that may contribute to dispensing errors include: negligence in correctly identifying the patient or medication, for example, the name and medical record of the patient, name of the drug, its strength, quantity, etc.; unclear physician hand writing and/or incomplete prescription; lack of knowledge and/or focus; limited or no patient counseling; distractions at the work place; heavy workload; medication that looks similar or similar sounding medications; miscommunication between healthcare professionals. (Kundsen et al., 2007; Berdot et al., 2012) The prescribed medication was eye drops (Tobradex) whereas the medication handed over to the patient by the pharmacist was a skin ointment (Tabiflex) to be used externally. The sizes of the eye drops pack, the skin ointment differs and this, at least, should have alerted the pharmacist.

Some studies report the most common reason for dispensing errors is similar sounding medication or medications that appear similar (Kundsen et al., 2007; Berdot et al., 2012). A study of community pharmacies reported that the errors mostly occurred during the process of the transcription and labeling of the medication (Kundsen et al., 2007).

According to the international accreditation standards, health organizations should have a process in place where the medication is reviewed by a pharmacist before dispensing.



**Figure 2a** The label of the correct medication (Tobradex) prescribed by the ophthalmologist affixed on the wrong medication pack (Tabiflex).



**Figure 2b** The tube of the wrongly dispensed pain killer ointment (Tabiflex Cool). Removed from the packaging.

Additionally, 2 or more pharmacy technicians should help in checking the orders before dispensing by the pharmacist (Alsultan et al., 2012).

In the current case, the error seemed to occur during labeling of the medication. The correctly prescribed medication (Tobradex; Alcon Inc., Fort Worth, Tx., USA) was transcribed and written correctly by the junior pharmacist or technician but the wrong label was affixed on the wrong medication (Tabiflex) (Fig. 2b). In this case it occurred because the medication looks similar which is a significant and common cause of medication error (Kundsen et al., 2007; Berdot et al., 2012). Similar to our case, most medication errors do not have long term sequelae (Mansouri et al., 2013). Our patient used 2 doses of the wrong medication and was astute enough to discover it was not the prescribed medication. The early discovery of the error was likely a factor in limiting the duration and severity of symptoms.

The clinical picture in our case could not be definitively attributed to the effect of using the wrong medication because corneal epithelial defect and inflammation are common after trauma to the eye. However the symptoms and defect were resolved quickly to topical steroid drops. The importance of this case report is to highlight the processes for checking medication prescriptions at pharmacies. Additionally, the safety measures in place should be used for every patient as they will mitigate ocular effects and also potentially more fatal systemic effects of medication error. In conclusion errors in medication dispensing and administration may be common but most have no long term effects. However, these quality standards are fundamental at pharmacies to avoid the use and sometimes fatal effects of wrongly administered medications.

## References

- Al-Ghadeer, H.A., 2010. Acute ocular complications from self-administered topical Kermes. *Middle E. Afr. J. Ophthalmol.* 17, 382–384.
- Alsulami, Z., Conroy, S., Choonara, I., 2013 April. Medication errors in the Middle East countries: a systemic review of the literature. *Eur. J. Clin. Pharmacol.* 69 (4), 995–1008.
- Alsultan, M., Khurshid, F., Mayet, A., Al-jedai, A., 2012. Hospital pharmacy practice in Saudi Arabia: dispensing and administration in the Riyadh region. *Saudi Pharm. J.* 20 (4), 307–315.
- Berdot, S., Brigitte, S., Gillaizeau, F., Caruba, T., Prognon, P., Durieux, P., 2012. Evaluation of drug administration errors in a teaching hospital. *BMC Health Serv. Res.* 12, 12–19.
- Chen, H.T., Chen, K.H., Hsu, W.M., 2004. Toxic keratopathy associated with abuse of low-dose anesthetic: a case report. *Cornea* 23, 527–529.
- Kundsen, P., Herborg, H., Mortensen, A., Kundrsen, M., Hellebek, A., 2007. Preventing medication errors in community pharmacy: frequency and seriousness of medication errors. *Qual. Saf. Health Care* 16 (4), 291–296.
- Mansouri, A., Ahmadvand, A., Hadjibabaie, M., Kargar, M., Javadi, M., Gholami, K., 2013. Types and severity of medication errors in Iran: a review of the current literature. *Daru* 21 (1), 49.
- Mian, I.S., Gupta, A., Pineda, R., 2006. Corneal ulceration and perforation with ketorolac tromethamine (Aculr R) use after PRK. *Cornea* 25, 232–234.
- Turk, U., Turk, B.G., Yilmaz, S.G., Tuncer, E., Aliogul, E., Tugrul, D., 2015. Amiodarone-induced multiorgan toxicity with ocular findings on confocal microscopy. *Middle E. Afr. J. Ophthalmol.* 22 (2), 258–260.
- Vingesh, A.P., Srinivasan, R., Karanth, S., 2015. A case report of severe corneal toxicity following 0.5% topical moxifloxacin use. *Case Rep. Ophthalmol.* 6, 63–65.