



Case report

Sclero-conjunctival ischaemia secondary to intra-arterial chemotherapy for retinoblastoma

Lisa McAnena^{a,*}, Zishan Naeem^a, Catriona Duncan^b, Fergus Robertson^b, Mandeep S. Sagoo^{a,c,d}, M. Ashwin Reddy^{a,c}

^a Retinoblastoma Service, Royal London Hospital, Whitechapel Road, Whitechapel, London, E1 1BB, UK

^b Great Ormond Street Hospital for Children, London, UK

^c National Institute for Health Research Biomedical Research Centre at Moorfields Eye Hospital NHS Foundation Trust, 162 City Road, London, EC1V 2PD, UK

^d UCL Institute of Ophthalmology, 11-43 Bath Street, London, EC1V 9EL, UK

ARTICLE INFO

Keywords:

Retinoblastoma
Intra-arterial chemotherapy

ABSTRACT

Purpose: Intra-arterial chemotherapy (IAC), delivered directly to the globe via the internal carotid artery is now an established treatment for retinoblastoma. We report a case of anterior segment ischaemia following treatment with multiple intra-arterial chemotherapy (IAC) infusions.

Observations: A 5 month old female presented with bilateral retinoblastoma and was treated with 12 infusions of IAC. Her right eye was enucleated at diagnosis. After her seventh IAC treatment, she developed ipsilateral sixth and third cranial nerve palsies. After the twelfth IAC, she developed an area of conjunctival and scleral ischaemia between 12 and 3 o'clock meridians in her left eye. However, she maintained visual acuity of LogMAR 0.34.

Conclusions and Importance: The median number of IAC treatments in large studies is three. It is possible that repeated doses of IAC have an accumulative negative effect on the ocular blood supply, risking anterior segment and neurologic sequelae. This case highlights the significant challenge of balancing the salvage of eyes and vision with the potentially significant morbidity associated with IAC.

1. Introduction

We report a case of anterior segment ischaemia following treatment with multiple intra-arterial chemotherapy (IAC) infusions.

2. Case report

A 5 month old white female presented with right leukocoria. She had no significant family history. She was diagnosed with bilateral retinoblastomas, Group E (right eye) and group B (left eye) according to International Intraocular Retinoblastoma Classification1, H1cT3c (Right Eye) H1cT1b (left eye)¹ Genetic analysis revealed a heterozygous *RB1* exon 17 mutation (c.1630delA) The right Group E eye² was enucleated at presentation. Her left eye had five extra-foveal tumours for which she received six cycles of systemic chemotherapy with vincristine, etoposide and carboplatin.

Tumor #1 was close to the optic nerve and relapsed repeatedly despite judicious transpupillary therapy away from the nerve (Fig. 1). It was treated a total of 12 infusions of IAC (4 cycles of 3 injections each at 3 weeks apart). For her first round of treatment, she received 2 doses

each of 3mg melphalan and 0.3mg Topotecan. The final dose was increased to 4mg and topotecan 0.3mg as we use age appropriate doses^{3,4} and she had turned 12 months. This was effective for 2 years and 5 months and there were no complications from the IAC. Tumor#1 relapsed again and this time 5mg melphalan and 1 mg topotecan was used for the 3 injections of the 2nd cycle. A slight ptosis and supra-trochlear rash followed but no other complications ensued. There was a complete response following the second cycle. After 4 months, Tumor #1 relapsed again and as she was 4 years of age, the dose was increased to melphalan 7.5mg and topotecan 1.5mg for her 3rd cycle and she developed lid swelling. Our practice is to give steroid drops for 3 weeks and oral steroids for 5 days tds (100 µg/kg). After the swelling she developed a third and sixth nerve palsy with an increase in the ptosis. The sixth nerve palsy was severe causing a -7 limitation of movement (severe restriction past the midline). Again, a complete response was achieved. There was no neutropenia after chemotherapy. After 5 months, yet again Tumor #1 relapsed and as the maximum dose of melphalan had already been given (for our unit), we opted for carboplatin 30mg and topotecan 1.5mg. After the twelfth IAC, she developed an area of conjunctival and scleral ischaemia between 12 and 3 o'clock

* Corresponding author. 11 Cashelmara, Salthill, Galway, Ireland.

E-mail address: lisa.mcanena@nhs.net (L. McAnena).

<https://doi.org/10.1016/j.ajoc.2020.100611>

Received 30 January 2019; Received in revised form 19 January 2020; Accepted 27 January 2020

Available online 30 January 2020

2451-9936/© 2020 The Authors. Published by Elsevier Inc. This is an open access article under the CC BY-NC-ND license

(<http://creativecommons.org/licenses/by-nc-nd/4.0/>).

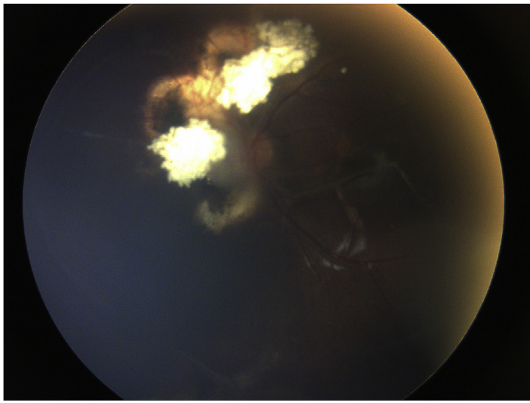


Fig. 1. Relapse of juxtapapillary tumor.

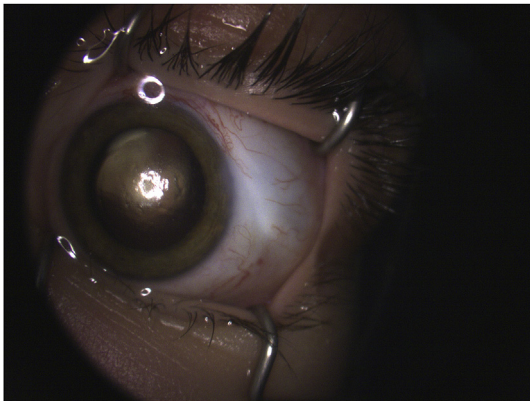


Fig. 2. Focal sclero-conjunctival ischaemia of the left eye.

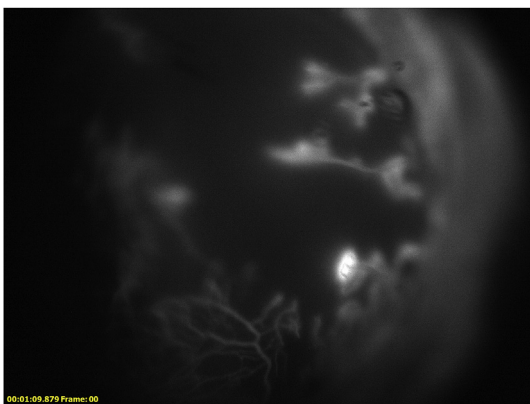


Fig. 3. Anterior fluorescein angiography.

meridians in her left eye (Fig. 2). Fluorescein demonstrated conjunctival ischaemia in this region (Fig. 3). There was no corresponding corneal epithelial abnormality and at 14 months following the onset of this sign (5 years after her initial diagnosis), she is pain free with visual acuity of LogMAR 0.34 with an adjusted head posture to compensate for her ptosis and third and sixth cranial nerve palsies. Tumor #1 has regressed without further relapse. There was no corresponding area of choroidal ischaemia on fluorescein angiography. There has been no scleromalacia or anterior staphyloma. The sixth nerve palsy has improved over 24 months from -7 to -4.5 limitation but the upward limitation remains at -3.5 and downward limitation has improved from -3.5 to -2.5 . There is restriction in all directions when forced duction tests were performed and the eye is enophthalmic. The ptosis has slightly improved but remains after 24 months. She had a dominant

accessory supply from the middle meningeal artery and this was used for the first 9 treatments. Unfortunately, it stenosed off and the smaller ophthalmic artery was used for the last 3 injections.

3. Discussion

Treatment of retinoblastoma has undergone a dramatic evolution over the past three decades; from external beam radiation therapy, now known to cause increased mortality from secondary tumours in patients with germ-line mutations^{5,6} to systemic intravenous chemotherapy (IVC) with focal laser and/or cryotherapy as standard treatment in the 1990s.^{7,8} Intra-arterial chemotherapy, delivered directly to the globe via the internal carotid artery is now an established treatment, used as first-line treatment or second line after systemic chemotherapy^{3,4,9-13}

IAC, along with intravitreal chemotherapy, are now being used both to salvage more eyes as well as retain function, where previously enucleation would have been the only option. However, IAC carries the risk of significant complications. These may include systemic complications such as bradycardia, hypotension, myelosuppression or allergic reactions.^{3,15-17} Local ophthalmic complications are commonly vascular in nature and include retinal or vitreous haemorrhage and retinal or choroidal vascular occlusions, including vein occlusions.^{12,15,16,18-21} Rates of complications secondary to IAC are decreasing, however, as catheterisation techniques are improved¹⁹ and chemotherapy doses are adjusted to patient age.⁴ A median of 3 treatments has been reported in large case series^{12,15,22} and at our own centre.⁴ Tsimpida et al.²³ found a visual loss rate of 42% for refractory retinoblastoma that was treated with IAC. However, by using age-appropriate dosing of melphalan, Reddy et al.⁴ demonstrated no visual loss in patients with healthy foveolae. The potential for visual loss was a major concern as this child was dependent on her only remaining eye for vision and she had a cumulative dose of 47.5 mg of melphalan. Francis et al. determined that a reduction in ERG became statistically significant at a cutoff cumulative dose of 14mg of melphalan, suggesting cumulative doses can have a deleterious effect on the retina. By multivariate analysis, however, they found that neither topotecan nor carboplatin had an effect on the ERG.²³ There have been few studies on the complications of topotecan and carboplatin. It has been shown that like melphalan, these drugs are toxic to the RPE.²⁴ Gobin et al. have shown that 50mg carboplatin can cause massive edema of the peri-ocular structures and possible myositis.³ Our patient had 3 doses of 30mg carboplatin. Daniels et al. have used animal model evidence to show that the doses of melphalan and carboplatin are the most important factors related to complications not catheterisation technique²⁵: indeed this corroborates Reddy et al.'s findings.⁴ As topotecan has rarely been given without agents such as melphalan or carboplatin, it is difficult to tease out the topotecan specific complications of IAC.

We have previously reported anterior segment invasion by the tumor in eyes receiving IAC as salvage.²⁶ Anterior segment ischaemia is an unusual complication of IAC, and, to the best of our knowledge, this case of sclero-conjunctival ischaemia secondary to IAC is unique. This is most likely due to the high number of IAC treatments (12 to date) that have been necessary to salvage this patient's remaining eye. It is possible that repeated doses of IAC have a summative effect on the ocular blood supply, risking anterior segment and neurologic sequelae. .

We would like to highlight that it is very unusual to administer such a large number of IAC infusions and that the rationale in this case was salvage of residual function in an only eye. Despite the significant morbidity from the treatment, this 5 year-old girl has functional vision in her remaining eye, with disease quiescence at most recent follow up (17 months since last treatment aged 6). Close observation will be continued in order to detect any future scleromalacia or anterior staphyloma and possible relapse.

4. Conclusion

This case highlights the significant challenge of balancing the salvage of eyes and vision with the potentially significant morbidity associated with IAC.

Patient consent

Consent to publish the case report was not obtained. This report does not contain any personal information that could lead to the identification of the patient.

Acknowledgements and Disclosures

There was no funding or grant support for this case report. The following authors have no financial disclosures: LM, MS, MR. All authors attest that they meet the current ICMJE criteria for Authorship. There are no further relevant acknowledgements.

Appendix A. Supplementary data

Supplementary data to this article can be found online at <https://doi.org/10.1016/j.ajoc.2020.100611>.

References

- Amin MB, Greene FL, Edge SB, et al. The Eighth Edition AJCC Cancer Staging Manual: continuing to build a bridge from a population-based to a more "personalized" approach to cancer staging. *CA A Cancer J Clin*. 2017;67(2):93–99.
- Linn Murphree A. Intraocular retinoblastoma: the case for a new group classification. *Ophthalmol Clin North Am*. 2005;18(1):41–53 viii.
- Gobin YP, Dunkel LJ, Marr BP, et al. Intra-arterial chemotherapy for the management of retinoblastoma: four-year experience. *Arch Ophthalmol*. 2011;129(6):732–737.
- Reddy MA, Naeem Z, Duncan C, et al. Reduction of severe visual loss and complications following intra-arterial chemotherapy (IAC) for refractory retinoblastoma. *Br J Ophthalmol*. 2017;101(12):1704–1708.
- Wong FL, Boice Jr JD, Abramson DH, et al. Cancer incidence after retinoblastoma. Radiation dose and sarcoma risk. *JAMA*. 1997;278(15):1262–1267.
- Eng C, Li FP, Abramson DH, et al. Mortality from second tumors among long-term survivors of retinoblastoma. *J Natl Cancer Inst*. 1993;85(14):1121–1128.
- Chan HS, Gallie BL, Munier FL, et al. Chemotherapy for retinoblastoma. *Ophthalmol Clin North Am*. 2005;18(1):55–63 viii.
- Ferris 3rd FL, Chew EY. A new era for the treatment of retinoblastoma. *Arch Ophthalmol*. 1996;114(11):1412.
- Peterson EC, Elhamady MS, Quintero-Wolfe S, et al. Selective ophthalmic artery infusion of chemotherapy for advanced intraocular retinoblastoma: initial experience with 17 tumors. *J Neurosurg*. 2011;114(6):1603–1608.
- Muen WJ, Kingston JE, Robertson F, et al. Efficacy and complications of superselective intra-ophthalmic artery melphalan for the treatment of refractory retinoblastoma. *Ophthalmology*. 2012;119(3):611–616.
- Venturi C, Bracco S, Cerase A, et al. Superselective ophthalmic artery infusion of melphalan for intraocular retinoblastoma: preliminary results from 140 treatments. *Acta Ophthalmol*. 2013;91(4):335–342.
- Shields CL, Manjandavida FP, Lally SE, et al. Intra-arterial chemotherapy for retinoblastoma in 70 eyes: outcomes based on the international classification of retinoblastoma. *Ophthalmology*. 2014;121(7):1453–1460.
- Francis JH, Brodie SE, Marr B, et al. Efficacy and toxicity of intravitreal chemotherapy for retinoblastoma: four-year experience. *Ophthalmology*. 2017;124(4):488–495.
- Wang L, Han M, Zhao J, et al. Intra-arterial chemotherapy for unilateral advanced intraocular retinoblastoma: results and short-term complications. *Medicine (Baltim)*. 2018;97(42):e12676.
- Abramson DH, Daniels AB, Marr BP, et al. Intra-arterial chemotherapy (ophthalmic artery chemosurgery) for group D retinoblastoma. *PLoS One*. 2016;11(1):e0146582.
- Requejo F, Marelli J, Ruiz Johnson A, et al. The technique of superselective ophthalmic artery chemotherapy for retinoblastoma: the Garrahan Hospital experience. *Intervent Neuroradiol*. 2018;24(1):93–99.
- Ancona-Lezama D, Dalvin LA, Lucio-Alvarez JA, et al. Ophthalmic vascular events after primary unilateral intra-arterial chemotherapy for retinoblastoma in early and recent eras. *Ophthalmology*. 2018;125(11):1803–1811.
- Dalvin LA, Ancona-Lezama D, Lucio-Alvarez JA, et al. Ophthalmic vascular events in the primary management of advanced intra-ocular retinoblastoma: first 4-year experience from a single institution in Turkey. *Acta Ophthalmol*. 2016;94(7):e644–e651.
- Hua J, Gang S, Yizhou J, et al. Intra-arterial chemotherapy as second-line treatment for advanced retinoblastoma: a 2-year single-center study in China. *J Canc Res Therapeut*. 2018;14(1):106–110.
- Francis JH, Levin AM, Zabor EC, et al. Ten-year experience with ophthalmic artery chemosurgery: ocular and recurrence-free survival. *PLoS One*. 2018;13(5):e0197081.
- Tsimpida M, Thompson DA, Liasis A, et al. Visual outcomes following intra-ophthalmic artery melphalan for patients with refractory retinoblastoma and age appropriate vision. *Br J Ophthalmol*. 2013;97(11):1464–1470.
- Susskind D, Hagemann U, Schrader M, et al. Toxic effects of melphalan, topotecan and carboplatin on retinal pigment epithelial cells. *Acta Ophthalmol*. 2016;94(5):471–478.
- Daniels AB, Froehler MT, Nunnally AH, et al. Rabbit model of intra-arterial chemotherapy toxicity demonstrates retinopathy and vasculopathy related to drug and dose, not procedure or approach. *Invest Ophthalmol Vis Sci*. 2019;60(4):954–964.
- Pavlidou E, Burris C, Thaug C, et al. Anterior segment seeding in eyes with retinoblastoma failing to respond to intraophthalmic artery chemotherapy. *JAMA Ophthalmol*. 2015;133(12):1455–1458.