



Neurological involvement of coronavirus disease 2019: a systematic review

Malik Ghannam¹ · Qasem Alshaer² · Mustafa Al-Chalabi³ · Lara Zakarna⁴ · Jetter Robertson¹ · Georgios Manousakis¹

Received: 17 May 2020 / Revised: 8 June 2020 / Accepted: 10 June 2020 / Published online: 19 June 2020
© Springer-Verlag GmbH Germany, part of Springer Nature 2020

Abstract

Background In December 2019, unexplained cases of pneumonia emerged in Wuhan, China, which were found to be secondary to the novel coronavirus SARS-CoV-2. On March 11, 2020, the WHO declared the Coronavirus Disease 2019 (COVID-2019) outbreak, a pandemic.

Objective To clarify the neurological complications of SARS-CoV-2 infection including the potential mechanisms and therapeutic options.

Methods We conducted a systematic literature search from December 01, 2019 to May 14, 2020 using multiple combinations of keywords from PubMed and Ovid Medline databases according to the Preferred Reporting Items for Systematic Reviews and Meta-Analyses guidelines. We included articles with cases of COVID-19 where neurological involvement was evident.

Results We were able to identify 82 cases of COVID-19 with neurological complications. The mean age was 62.3 years. 37.8% of the patients were women ($n=31$). 48.8% of the patients ($n=40$) had cerebrovascular insults, 28% ($n=23$) had neuromuscular disorders, and 23% of the patients ($n=19$) had encephalitis or encephalopathy.

Conclusions Neurological manifestations of COVID-19 are not rare, especially large vessel stroke, Guillain–Barre syndrome, and meningoencephalitis. Moving forward, further studies are needed to clarify the prevalence of the neurological complications of SARS-CoV-2 infection, investigate their biological backgrounds, and test treatment options. Physicians should be cautious not to overlook other neurological diagnoses that can mimic COVID-19 during the pandemic.

Keywords Neurological complications · SARS-CoV-2 · Pandemic

Electronic supplementary material The online version of this article (<https://doi.org/10.1007/s00415-020-09990-2>) contains supplementary material, which is available to authorized users.

✉ Malik Ghannam
mghannam@umn.edu

✉ Georgios Manousakis
gmanousa@umn.edu

Qasem Alshaer
qalshae@emory.edu

Mustafa Al-Chalabi
Mustafa.Alchalabi@utoledo.edu

Lara Zakarna
lara.zakarneh@gmail.com

Jetter Robertson
robe0518@umn.edu

Introduction

Coronaviruses (CoV) are a family of enveloped, positive-sense, single-stranded RNA viruses that have been described for more than 50 years. Some strains are found to be zoonotic, whereas others may infect humans and transmit

¹ Department of Neurology, University of Minnesota, 516 Delaware St. SE, Minneapolis, MN, USA

² Department of Neurology, Emory University, Atlanta, GA, USA

³ Department of Neurology, University of Toledo, Toledo, OH, USA

⁴ Department of Neuroscience, An-Najah National University, Nablus, Palestine

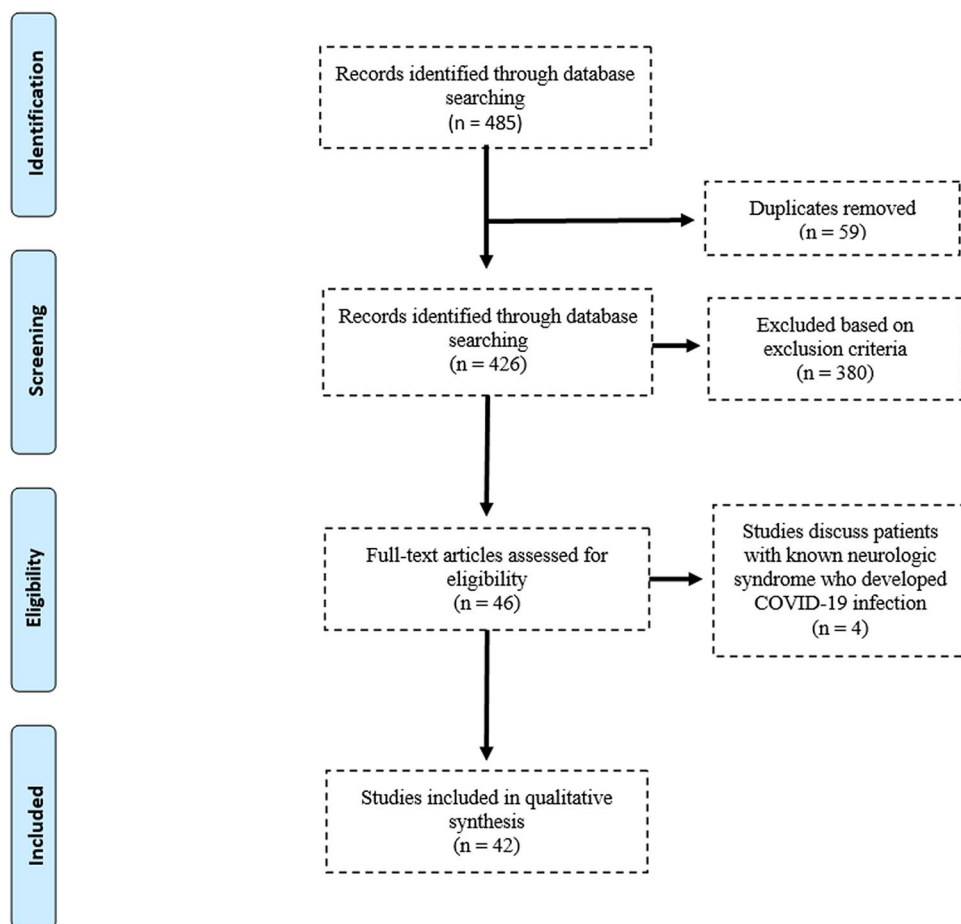
from human-to-human (HCoV) [1]. Multiple strains of Coronavirus are associated with human disease, causing mainly respiratory infections [2]. Of these, SARS-CoV-1, MERS-CoV, HCoV-OC43, and HCoV-229E are associated with neurological complications [3]. Large territory stroke, polyneuropathy, myopathy, seizures, and status epilepticus were reported in patients with SARS-CoV-1 outbreak in 2002/2003 [4, 5]. Intranasal inoculation of the SARS-CoV-1 virus to mice transgenic for the human ACE2 protein led to severe neuronal loss at the brainstem and specifically the respiratory center at the medulla. This was postulated to contribute to the respiratory failure seen in the most severe cases of coronavirus infections, in addition to the primary lung pathology [6]. The full spectrum of COVID-19 is not fully described yet. Some patients may have no clinical symptoms [7, 8], while others might suffer from severe disease and even die. The most commonly recognized symptoms are cough, fever, fatigue, shortness of breath, myalgia, anosmia, and sputum production. Other less-reported symptoms include diarrhea, hemoptysis, and nasal congestion [7, 9]. Growing evidence suggests that SARS-CoV-2 virus has

neuroinvasive potential, like other coronaviruses. Hence, it was only a matter of time before neurological complications were reported, especially stroke, neuromuscular disorders, and meningoencephalitis. The goal of this review is to outline the broad spectrum of the neurological consequences of SARS-CoV-2 infection.

Methods

We conducted a systematic literature search from December 01, 2019 to May 14, 2020 from PubMed and Ovid Medline databases according to Preferred Reporting Items for Systematic Reviews and Meta-Analyses (PRISMA) guidelines [10]. The following search strategy was implemented and these keywords and their synonyms (in the all fields) were combined in each database as follows: (“COVID 19” OR “coronavirus”) AND (“brain” OR “CNS” OR “spinal cord” OR “nerve” OR “neurologic” OR “stroke” OR “cerebrovascular” OR “cerebral vein thrombosis” OR “sinus thrombosis” OR “Intracerebral hemorrhage” OR “hemorrhage” OR

Fig. 1 PRISMA flowchart of the selection of the studies for this review



“myelitis” OR “GBS” OR “Guillain Barre syndrome” OR “neuropathy” OR “radiculopathy” OR “cranial neuropathy” OR “myopathy” OR “myositis” OR “rhabdomyolysis” OR “encephalitis” OR “encephalopathy” OR “meningitis” OR “meningoencephalitis” OR “seizure” OR “convulsion” OR “epilepsy”) [Fig. 1]. We included case series and case reports of COVID-19 with evident neurological symptoms or signs. After exclusion of duplicates, all articles were evaluated through title and abstract screening by three independent reviewers (M.G., Q.A., and G.M.). The same three reviewers performed an accurate reading of all full-text articles assessed for eligibility and performed a collection of data to minimize the risk of bias. In case of disagreement among the investigators regarding the inclusion and exclusion criteria, the senior investigator (G.M.) made the final decision. Articles were included if they met the following inclusion criteria: (i) described patients with neurological signs or symptoms attributed to COVID-19 (e.g., focal neurological deficit or impairment of consciousness); (ii) written in English language; and (iii) published in a peer-reviewed journal. The exclusion criteria were: (i) studies conducted in animals or in vitro models or basic science studies; (ii) patients age less than 18 years; and (iii) conference proceedings, pooled analysis, clinical trials, case control studies, case reports, or case series of anosmia or mental health problems in COVID-19, reviews, and books. We assessed the quality of the included studies using the JBI Critical Appraisal Tool, as shown in supplementary Tables 1 and 2.[11]

For each study, the following descriptive, microbiological, and clinical information was extracted: patient demographic data, SARS-CoV-2 testing from nasal swab and CSF, neurological symptoms and signs and their onset in relation to respiratory or gastrointestinal (GI) symptoms or anosmia or dysgeusia, any neurological investigations and CSF or any other relevant laboratory testing (such as CK, LDH, CRP, D-dimer, lupus anticoagulant, fibrinogen, ganglioside antibodies), neurological diagnosis, occurrence of respiratory failure (defined as need for intubation, abnormal PO₂ in blood gas, or Glasgow Coma Scale score less than or equal 8), treatments administered for the neurological diagnosis, and final outcome. We studied the following outcomes: good, recovering, poor, and deceased. Good outcome was defined as discharge of the patient to home or a quarantine facility, or the use of the following descriptive terms in the study: “no morbidity”, “no worsening” or “discharged well” or “good recovery”. Recovering outcome was defined as discharge of the patient to a rehabilitation facility or use of the following descriptive terms: “began to improve”, “recovering”, or “stayed in the floor”. Poor outcome was defined as continuing deterioration of the patient’s clinical status, need for ICU admission, continued intubation, or use of the following descriptive terms: “poor” or “no improvement after a certain time of treatment”, at the

time of submitting the manuscript. Deceased was defined as reported death within 30 days of COVID-19 diagnosis.

Results

Through the search strategy, we could identify 42 articles about neurological involvement by COVID-19. We were able to identify 82 cases of COVID-19 with neurological complications. The mean age was 62.3 years (22–91). 37.8% of the patients were women ($n=31$) (Table 1). All but two patients had positive nasopharyngeal (NP) or oropharyngeal (OP) SARS-CoV-2 RT-PCR swabs. Only two patients had positive CSF SARS-CoV-2 RT-PCR, one of which showed negative NP swab testing. 48.8% of patients ($n=40$) had cerebrovascular insults (CVIs), 28% ($n=23$) had neuromuscular disorders (NMDs), and 23% ($n=19$) developed CNS complications related to CNS infection or inflammation. 32.9% of patients ($n=27$) were recovering, 18.3% ($n=15$) had good outcomes, 25.6% ($n=21$) had poor outcomes, and 18.3% ($n=15$) died. In 23.2% of patients ($n=19$), the neurologic syndrome was the initial presentation of COVID-19, four of which developed respiratory symptoms 2–8 days after the onset of neurologic syndrome. In two patients, the neurologic syndrome was preceded by 2–3 days of GI symptoms, while in two other patients, it was preceded only by anosmia and dysgeusia (Fig. 2).

Cerebrovascular complications

5% ($n=2$) of the CVIs were due to cerebral vein thrombosis (CVT), 5% ($n=2$) were intracerebral hemorrhages (ICH), 2.5% ($n=1$) were aneurysmal subarachnoid hemorrhage and ICH, and 87.5% ($n=35$) were ischemic stroke. Three out of 35 patients (9%) had cardioembolic stroke, five had small vessel disease stroke (14%), and 27 (77%) had large vessel occlusion (LVO) stroke. 80% ($n=28$) of the ischemic stroke patients had elevated D-dimer levels, 57% ($n=20$) had elevated C-reactive protein, 28.5% ($n=10$) had elevated fibrinogen, and 14.3% ($n=5$) were tested positive for lupus anticoagulant antibodies (Table 2). Out of the 27 LVO stroke patients, seven were under the age of 50, six underwent thrombectomy, four were treated with IV tPA, six with therapeutic low-molecular-weight heparin (LMWH), three with apixaban, four with dual antiplatelets (DAPs), and one with rivaroxaban and DAPs. Six of those patients died. One of the ischemic stroke patients developed hemorrhagic conversion after thrombectomy. The LVO stroke were distributed in the following territories: left middle cerebral artery territory (MCA) ($n=6$), right MCA ($n=6$), left internal carotid artery (ICA) ($n=2$), right ICA ($n=2$), left common carotid artery ($n=1$), basilar artery ($n=1$), left vertebral artery ($n=1$), left posterior cerebral artery (PCA)

Table 1 Chronological summary of patients' hospital course

Author, Year	Patients, Number	Onset of neurologic syndrome, Days ^a	Respiratory failure (0=no, 1=yes)	Treatment	Outcome (0=no, 1=yes)			
					Good	Recovering	Poor	Deceased
Poyiadji et al. 2020 [12]	1	3	NA	IVIG	NA	NA	NA	NA
Moriguchi et al. 2020 [13]	1	9	1	Antimicrobials, steroid	0	0	1	0
Duong et al., Haung et al. 2020 [14, 15]	1	0	0	AEDs, transient antimicrobials	0	1	0	0
Ye et al. 2020 [16]	1	13	1	Antimicrobials	1	0	0	0
Yin et al. 2020 [17]	1	13	0	Antimicrobials	1	0	0	0
Filatov et al. 2020 [18]	1	1	1	AEDs, antimicrobials	0	0	1	0
Wong et al. 2020 [19]	1	12	0	Antimicrobials, gabapentin	1	0	0	0
Zhao et al. 2020 [20] ^b	1	-8	0	IVIG	1	0	0	0
Sedaghat et al. 2020 [21]	1	14	0	IVIG	NA	NA	NA	NA
Virani et al. 2020 [22]	1	10	1	IVIG	0	1	0	0
El-Otmani et al. 2020 [23]	1	3	0	IVIG	0	0	1	0
Alberti et al. 2020 [24]	1	7	1	IVIG	0	0	0	1
Camdessanche et al. 2020 [25]	1	11	1	IVIG	NA	NA	NA	NA
Padroni et al. 2020 [26]	1	24	1	IVIG	0	0	1	0
Scheidl et al. 2020 [27] ^c	1	14	0	IVIG	1	0	0	0
Ottaviani et al. 2020 [28]	1	10	1	IVIG	0	0	1	0
Abdelnour et al. 2020 [29] ^b	1	-7	0	NA	1	0	0	0
Caamaño DS et al. 2020 [30]	1	7	0	Steroid	0	1	0	0
Wei et al. 2020 [31] ^b	1	-7	1	IVIG, steroid, antimicrobials	0	0	0	1
Jin et al. 2020 [32]	1	15	1	IVF	0	1	0	0
Suwanwongse et al. 2020 [33]	1	0	0	IVF	0	1	0	0
Vollono et al. 2020 [34]	1	0	0	AEDs	1	0	0	0
Sohal et al. 2020 [35]	1	3	1	AEDs	0	0	0	1
Zanin et al. 2020 [36] ^c	1	NA	1	AEDs	0	1	0	0
Paniz-Mondolfi et al. 2020 [37] ^d	1	0	1	NA	0	0	0	1
González-Pinto et al. 2020 [38]	1	NA	1	NA	0	0	0	1
Zhou et al. 2020 [39]	1	24	1	DAPs + rivaroxaban	0	1	0	0
Valderrama et al. 2020 [40]	1	7	0	IV tPA + thrombectomy	0	1	0	0
Viguiet et al. 2020 [41]	1	7	0	LMWH	0	1	0	0
Hughes et al. 2020 [42]	1	0	0	LMWH	0	1	0	0
Sharifi-Razavi et al. 2020 [43]	1	3	1	NA	NA	NA	NA	NA
Toscano et al. 2020 [44]	5	7 (2), 10 (2), 5 (1)	1 (3)	IVIG (5), Plex (1)	1 (1)	1 (2)	1 (2)	0
Gutiérrez-Ortiz et al. 2020 [45] ^c	2	5 (1), 3 (1)	0	IVIG (1)	1 (2)	0	0	0

Table 1 (continued)

Author, Year	Patients, Number	Onset of neurologic syndrome, Days ^a	Respiratory failure (0=no, 1=yes)	Treatment	Outcome (0=no, 1=yes)			
					Good	Recovering	Poor	Deceased
Chan et al. 2020 [46]	2	0 (2)	1 (2)	IVF	0	1 (1)	1 (1)	0
Bernard-Valnet et al. 2020 [47]	2	5 (1), 17 (1)	NA	AEDs and transient antimicrobials (2)	1 (2)	0	0	0
Dogan et al. 2020 [48] ^f	6	NA	1 (6)	Plex (6)	0	1 (4)	1 (1)	1 (1)
Avula et al. 2020 [49]. ^e	4	2 (1), 0 (3)	1 (3)	Aspirin + statin (1), no acute treatment (4)	0	1 (1)	0	1 (3)
Al Saiegh et al. 2020 [50]	2	7 (1), 0 (1)	1 (2)	FD stent + EVD (1), thrombectomy (1)	0	1 (2)	0	0
Beyrouiti et al. 2020 [51]. ^b	6	– 2 (1), 8 (1), 10 (1), 15 (2), 24 (1)	1 (3)	DAPs (1), apixaban (1), LMWH (3), IV tPA (2)	0	0	1 (5)	1 (1)
Oxley et al. 2020 [52]	5	0 (3), 7 (1)	NA	Aspirin (2), Apixaban (2), stent (1), DAPs (1), IV tPA (1), thrombectomy (4), hemicraniectomy (1)	1 (1)	1 (3)	1 (1)	0
Tunç et al. 2020 [53]	4	4 (1), 1 (1), 7 (1), 2 (1)	0	DAPs (2), aspirin + low-dose LMWH (2)	1 (2)	2 (2)	0	0
Li et al. 2020 [54]	13	12 (median)	NA	LMHW (2 LVO, 2 CE, 1 CVT). AP (3 SVD, 3 LVO, 1 CE)	0	1 (2)	1 (6)	1 (5; one of them LVO)

AEDs antiepileptic drugs, DAPs dual antiplatelet therapy, AP antiplatelet, EVD external ventricular drain, IVF intravenous fluid, IVIG intravenous immunoglobulin, LMWH low-molecular-weight heparin, NA not applicable, Plex plasmapheresis, RS respiratory symptoms like cough and or shortness of breath, LVO large vessel occlusion, SVD small vessel disease, CE cardioembolic, CVT cerebral vein thrombosis

^aDefined by onset after respiratory or gastrointestinal symptoms or anosmia or dysgeusia, if the onset of neurological presentation (zero) means that it was the initial presentation of SARS-CoV-2 infection

^b8, 7, 7, and 2 days, respectively, after the neurological presentation, the patients developed respiratory symptoms

^cThe patients neurological presentation proceeded by anosmia and dysgeusia; there were no respiratory symptoms

^d5 days after neurological presentation, CXR showed BL lungs densities

^eTwo patients had neurological presentation 3,2 days, respectively; after gastroenterological symptoms, there were no respiratory symptoms

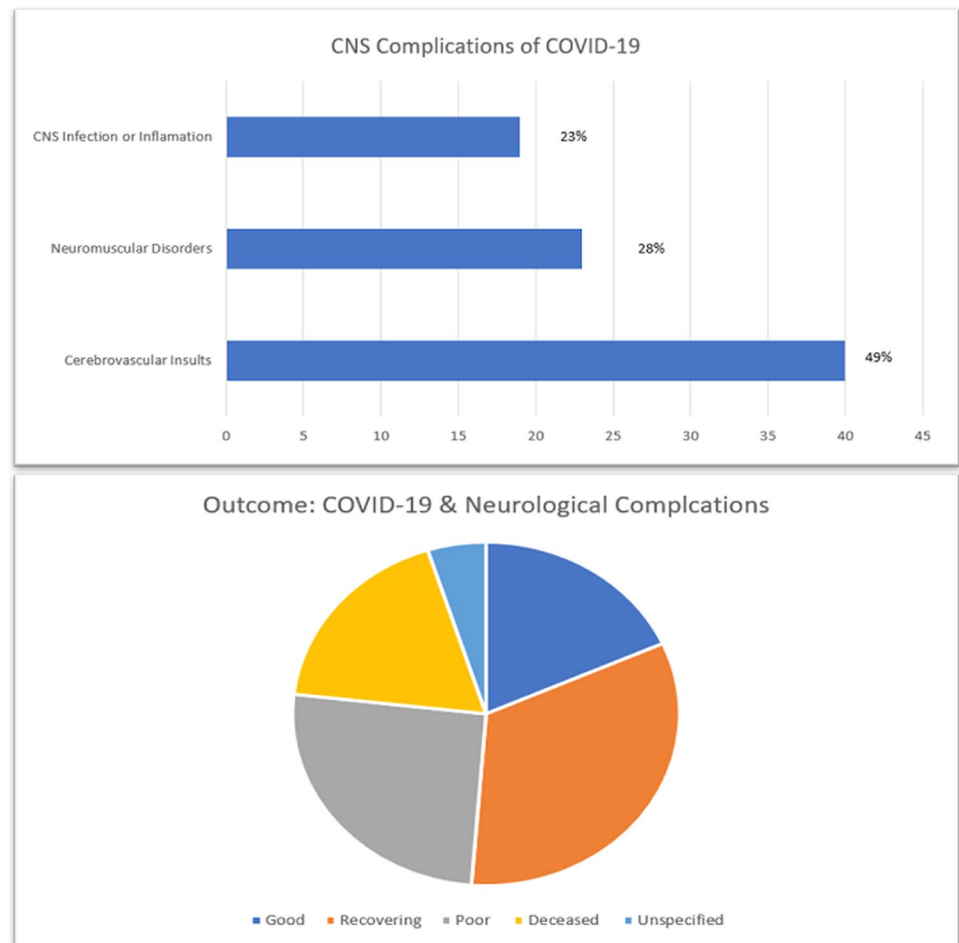
^fPatients regained consciousness after the third cycle (1), second cycle (1), and first cycle (2) of plasmapheresis

($n = 1$), right PCA ($n = 1$), bilateral multiple vascular territory infarcts ($n = 2$), and unspecified ($n = 4$). Stroke with LVO was the presenting manifestation of COVID-19 in eight patients, three of which were under the age of 45 (Table 3).

Neuromuscular complications

17.4% ($n = 4$) of the NMDs patients had rhabdomyolysis, 4.3% ($n = 1$) had polyneuritis cranialis, 4.3% ($n = 1$) had oculomotor nerve palsy, and 73.9% ($n = 17$) had Guillain–Barre syndrome (GBS). Seven out of the seventeen GBS cases had facial weakness, one of which manifested with isolated facial diplegia. In two cases, GBS was the first presentation of SARS-CoV-2 infection, while in 14 other patients, GBS developed 3–24 days after the onset

of flu-like symptoms. One patient presented 2 weeks after anosmia and ageusia without respiratory or GI symptoms. Electrophysiologic studies showed evidence of acute motor and sensory axonal variants (AMSAN) in five patients, mixed axonal and demyelinating patterns in two patients, and demyelinating patterns in six patients. EMG was not performed in four patients, one of which was diagnosed with Miller Fisher syndrome and positive serum GD1b-IgG antibody. CSF studies revealed albuminocytologic dissociation in ten patients, were normal in three patients (protein < 45 mg/dL, WBCs 0–5 cells/ μ l). In one patient, CSF protein and WBCs were 54 mg/dL and 9 cells/ μ L respectively, and CSF was not performed in three patients. 14 out of 17 patients received IVIG, one patient received IVIG and plasmapheresis, one patient

Fig. 2 CNS complications of COVID-19**Table 2** Analysis of D-dimer, C-reactive protein, and fibrinogen levels of ischemic stroke

D-dimer		C-reactive protein		Fibrinogen	
> 500 ng/mL [55]	> 2500 ng/mL [56] ^a	> 10 mg/L [57]	> 41.8 mg/L [58] ^b	> 400 mg/dL [59]	> 583 mg/dL [56] ^a
80% (n = 28)	42.8% (n = 15)	57% (n = 20)	45.7% (n = 16)	28.5% (n = 10)	11.4% (n = 4)

^aAccording to the procoagulant profile characteristics in COVID-19 by Ranucci et al.

^bPatients with C-reactive protein level > 41.8 mg/L are more likely to have severe complications in COVID-19 according to Liu et al.

showed spontaneous recovery, and one patient received prednisone. Six out of the seventeen patients developed respiratory failure, one of which died (Table 4).

CNS infectious or inflammatory complications

We identified 19 cases with confirmed COVID-19 which were suspected to have encephalitis, based on the presence of one of the following criteria: (a) meningeal signs, (b) altered mental status, focal neurological signs, or seizures, without better alternative explanation, or (c) suggestive MRI findings. 68.4% (n = 13) were ultimately diagnosed as

meningoencephalitis, 5.3% (n = 1) as rhombencephalitis, 5.3% (n = 1) as acute necrotizing hemorrhagic encephalopathy, 5.3% (n = 1) as encephalopathy, 10.5% (n = 2) presented with status epilepticus, one of which was focal, and 5.3% (n = 1) had CNS demyelinating lesions. In the 13 meningoencephalitis cases, only four CSF samples revealed lymphocytic pleocytosis, two of which had positive CSF SARS-CoV-2 RT-PCR. Nine patients developed respiratory failure, six received plasmapheresis, and one died. One patient showed postmortem evidence of the presence of viral particles in the neurons and capillary endothelial cells in the frontal lobe (Table 5).

Table 3 Summary of the cerebrovascular complications of COVID-19

Author, year	Age (year), sex	SARS-CoV-2		Neurological presentation	Neurological investigations	Neurological diagnosis	CSF and others
		Nasal swab	CSF				
González-Pinto et al. 2020 [38] ^a	36, F	Pos	NA	Aphasia, right side hemiplegia. She was found down in her apartment	CT and CTA: Occlusion of left ICA, MCA, ACA	Left ICA stroke	CRP 156 mg/L, D-Dimer 7540 ng/mL
Zhou et al. 2020 [39]	75, F	Pos	NA	Left hemiplegia and right hemiparesis	CT: bilateral cerebral infarcts	Right MCA and ACA stroke. Left ACA stroke. Bilateral legs DVTs	CRP: 42.52 mg/L D-dimer > 8000 ng/mL
Valderrama et al. 2020 [40]	52, M	Pos	NA	Right hemiparesis and aphasia. Left gaze, right partial hemianopia, facial weakness	CT: left MCA hyperdense sign CTA: left ICA occlusion CTP: favorable mismatch ratio of 4.1	Left ICA stroke	CRP 11 mg/L, D-dimer > 10,000 ng/mL, Fibrinogen 235 mg/dL
Viguier et al. 2020 [41] ^b	66, M	Pos	NA	Right hemiparesis and aphasia	CT: left frontal hypoattenuation CTA: left CCA intraluminal floating thrombus	Multiple scattered infarcts within left carotid territory CVT	CRP 219 mg/L, D-dimer 2220 ng/mL, fibrinogen 820 mg/dL
Hughes 2020. et al. [42]	59, M	Pos	NA	Right fronto-temporal headache followed by right sided weakness and numbness	CTV: Filling defect in the right sigmoid and transverse sinus		CRP: 20 mg/l, APTT: 19.7, Fibrinogen 490 mg/dL
Sharif-Razavi et al. 2020 [43] ^c	79, M	Pos	NA	Acute loss of consciousness	CT: right hemispheric massive intracerebral hemorrhage with intraventricular and subarachnoid hemorrhage	ICH	CRP 10 mg/L, INR 1, PTT 64 s
Author, year	Mean age (year)	Patients, Number	Male/female, Number	SARS-CoV-2	Neurological presentation	Neurological investigations	Neurological diagnosis
Avula et al. 2020 [49] ^d	81	4	1/3	Pos (4)	1. AMS 2. Dysarthria, left facial droop, left hemiparesis and hemineglect 3. AMS, left hemiparesis 4. Fifteen minutes of right arm weakness, numbness, aphasia	CT head and CTA CT head and CTA CT head, CTA, CTP CRP 162.4 mg/L, D-dimer 13,966 ng/mL MRI (positive for stroke) and MRA.	Left MCA stroke Right MCA stroke Right ICA stroke TIA/Left MCA stroke

Table 3 (continued)

Author, year	Mean age (year)	Patients, Number	Male/female, Number	SARS-CoV-2		Neurological presentation	Neurological investigations	Neurological diagnosis
				Nasal swab	CSF			
Al Saiegh et al. 2020 [50] ^e	46.5	2	1/1	Pos (2)	Neg (2)	1. Sudden headache, loss of consciousness 2. Right hemiparesis, aphasia	CT head, conventional angiography and CSF testing CT head, CTA and CSF testing	Posterior fossa aneurysmal SAH and ICH Left MCA stroke
Beyrouiti et al. 2020 [51] ^f	69.33	6	5/1	Pos (6)	NA	1. Left arm incoordination, 7 days later, bilateral incoordination and right homonymous hemianopia 2. Confusion, incoordination 3. Dysarthria, right hemiparesis 4. Dysarthria, left hemiparesis 5. Dysarthria, left hemiparesis 6. Dysphasia, right hemiparesis	MRI brain. Pos lupus anticoagulant, D-dimer > 80,000 ng/mL. CRP 305.4 mg/L. Fibrinogen 950 mg/dL CT head, Pos lupus anticoagulant. D-dimer 7,750 ng/mL. CRP 150.1 mg/L. Fibrinogen 703 mg/dL CT head, Neg lupus anticoagulant, D-dimer 16,100 ng/mL. CRP 161.2 mg/L. Fibrinogen 530 mg/dL MRI brain. Pos lupus anticoagulant, D-dimer 27,190 ng/mL. CRP 12.8 mg/L. Fibrinogen 463 mg/dL CT head and CTA. Pos lupus anticoagulant, D-dimer 19,450 ng/mL. CRP 27.7 mg/L. Fibrinogen 496 mg/dL MRI. Pos lupus anticoagulant, D-dimer 1,080 ng/mL. CRP 179.9 mg/L	Left vertebral artery occlusion-> left PICA stroke-> 7 days later left PCA stroke Left cerebellar and right parietooccipital infarcts Left PCA stroke Right MCA stroke Right MCA stroke Basilar artery thrombus and bilateral P2 stenosis Right ICA stroke
Oxley et al. 2020 [52] ^g	40.4	5	4/1	Pos (5)	NA	1. Left hemiplegia, homonymous hemianopia, right gaze preference 2. AMS, dysphasia, right hemiplegia 3. AMS, left hemiplegia, homonymous hemianopia, right gaze preference, ataxia 4. AMS, global aphasia, right hemiplegia, left gaze 5. AMS, left hemiplegia, dysarthria, left facial droop	CT, CTA, MRI. D-dimer 52 ng/mL, Fibrinogen 370 mg/dL CT, CTA, CTP, MRI. D-dimer 2230 ng/mL, Fibrinogen 739 mg/dL CT, CTA, MRI. D-dimer 1388 ng/mL, Fibrinogen 443 mg/dL CT, CTA, CTP. D-dimer 1750 ng/mL, Fibrinogen 531 mg/dL	Left MCA stroke Right PCA stroke Left MCA stroke Right MCA stroke

Table 3 (continued)

Author, year	Mean age (year)	Patients, Number	Male/female, Number	SARS-CoV-2		Neurological presentation	Neurological investigations	Neurological diagnosis
				Nasal swab	CSF			
Tunç et al. 2020 [53]	65.25	4	2/2	Pos (4)	NA	1. Left hemiparesis, dysarthria, left facial droop 2. Right hemiparesis, dysarthria 3. Right hemiparesis, loss of consciousness 4. Left hemi-hyposesthesia, mild ataxia	MRI brain. D-dimer 803 ng/mL. CRP 142 mg/L MRI brain. D-dimer 1040 ng/mL. CRP 4 mg/L MRI brain. D-dimer 644 ng/mL. CRP 33 mg/L MRI brain. D-dimer 378 ng/mL. CRP 366 mg/L	Right MCA stroke Left lenticulostriate artery infarction Left MCA stroke Right pontine infarction
Li et al. 2020 [54] ^b	71.61	13	7/6	Pos (13)	NA	No neurological presentations were reported	CTV (1), CT head (1 R MCA and 1 L BG hg). CRP (median) 51.1 mg/L (13). D-dimer (median) 6900 ng/mL (13)	ICH (1). CVT (1). LVO (5). SVD stroke (3). CE stroke (3)

AMS altered mental status, ACA anterior cerebral artery, CCA common carotid artery, COVID-19 Coronavirus disease 2019, CT computed tomography, CTA CT angiography, CTP CT perfusion, CTV CT venogram, DVT deep vein thrombosis, DWI diffusion weighted images, ICA Internal carotid artery, ICU intensive care unit, INR international normalized ratio, LDH Lactate dehydrogenase, MCA middle cerebral artery, MRI magnetic resonance imaging, NA not applicable, Neg negative, Pos positive, RT-PCR real-time polymerase chain reaction, SARS-CoV-2 severe acute respiratory syndrome coronavirus 2, T2WI/FLAIR T2-weighted images/fluid attenuation inversion recovery, CRP C-reactive protein, PTT partial thromboplastin time, WBCs white blood cells, CSF cerebral spinal fluid, ICH intracerebral hemorrhage, CVT cerebral vein thrombosis, L left, R right, PICA posterior inferior cerebellar artery, PEs pulmonary embolisms, LVO large vessel occlusion, SVD small vessel disease, CE cardioembolic, CVT cerebral vein thrombosis, WM white matter, AIDP acute inflammatory demyelinating polyradiculoneuropathy

^aThe patient had free medical history but smoker. CTA revealed free-floating thrombus in the ascending aorta with no signs of aortic atheromatosis

^bAntiphospholipid antibodies were negative

^cThe patient did not have history of hypertension or anticoagulation therapy. Platelets of $210 \times 10^9/L$

^dCase # 4: MRI/MRA revealed left medial temporal lobe small infarct and left M1 stenosis

^eAfter 10 days, patient#2 presented with hemorrhagic conversion and hydrocephalus

^fPatient 1 and 4 had PEs. Patient 2 INR was 3.6 (patient was already on warfarin). Patient 6 had right thalamus, left pons, right occipital lobe and right cerebellar infarcts. One patient had non-treated atrial fibrillation, 1 had treated atrial fibrillation, and 1 had previous stroke;

^g2 patients had diabetes, and 1 patient had hyperlipidemia and hypertension

^h9 out of 13 patients had hypertension, 6 out of 13 had diabetes mellitus, 3 out of 13 had cardiovascular disease, 1 out of 13 had malignancy, and 11 out of 13 had severe COVID-19 with multiorgan failure

Table 4 Summary of the neuromuscular complications of COVID-19

Author, year	Age (year), sex	SARS-CoV-2		Neurological presentation	Neurological investigations	Neurological diagnosis	CSF and others
		Nasal swab	CSF				
Zhao et al. 2020 [20]	61, F	Pos	NA	Legs and arms weakness Areflexia	Day 5 EMG/NCS revealed demyelinating pattern	GBS	CSF: protein 124 mg/dL. Cell counts 5 cells/ μ L
Sedaghat et al. 2020 [21]	65, M	Pos	NA	Ascending quadriparesis. Bifacial nerve palsy. Areflexia	Day 9 EMG/NCS revealed axonal pattern	GBS variant—AMSAN	CSF was not performed
Virani et al. 2020 [22]	54, M	Pos	NA	Ascending weakness and Paresthesia. Areflexia	T & L spine MRI was normal. EMG/NCS were not performed	GBS	CSF was not performed
El-Otmani et al. 2020 [23]	70, F	Pos	Neg	Quadriplegia. Hypotonia. Areflexia	Day 10 EMG/NCS revealed axonal pattern	GBS variant—ASAN	CSF: protein 100 mg/dL. Normal WBC
Alberti et al. 2020 [24]	71, M	Pos	Neg	Ascending weakness and paresthesia. Areflexia	EMG/NCS revealed mixed axonal and demyelinating patterns	GBS—mixed damage	CSF: protein 54 mg/dL. WBCs 9 cells/ μ L
Camdessanche et al. 2020 [25] ^a	64, M	Pos	NA	Flaccid tetraparesia and paresthesia. Areflexia	Day 5 EMG/NCS revealed demyelinating pattern	GBS	CSF: protein 166 mg/dL. Normal WBCs
Padroni et al. 2020 [26]	70, F	Pos	NA	Gait difficulty and paresthesia. Areflexia	EMG/NCS revealed demyelinating pattern	GBS	CSF: protein 48 mg/dL. WBCs 1 cells/ μ L
Scheidt et al. 2020 [27]	54, F	Pos	NA	Paraparesis. Areflexia	Admission EMG/NCS revealed demyelinating pattern	GBS	CSF: protein 140 mg/dL. Normal WBCs
Ottaviani et al. 2020 [28]	66, F	Pos	Neg	Difficulty walking, paraparesis. Areflexia then quadriparesis and facial weakness	Day 10 EMG/NCS revealed mixed axonal and demyelinating patterns	GBS—mixed damage	CSF: protein 108 mg/dL. Normal WBCs. Serum anti-glycolipid antibodies were absent
Abdelhour et al. 2020 [29]	69, M	Pos	NA	Bilateral lower limb weakness. Areflexia	Brain and spine MRIs were normal. EMG/NCS were not performed	GBS	CSF was not performed
Caamaño DS et al. 2020 [30]	61, M	Pos	Neg	Bilateral facial weakness. Unresponsive blink reflex on both eyes	Brain MRI and CT were normal. EMG/NCS were not performed	Atypical GBS variant—Facial diplegia	CSF: protein 44 mg/dL. WBCs 0 cells
Wei et al. 2020 [31]	62, M	Pos	NA	Binocular diplopia and left ptosis. Left eye was down and out at rest. No anisocoria. No areflexia	Brain MRI and MRA were negative	Left oculomotor nerve palsy	CSF was not performed. CRP 142.21 mg/L
Jin et al. 2020 [32]	61, F	Pos	NA	Muscle tenderness and weakness of lower extremities	EMG/NCS were not performed	Rhabdomyolysis	Myoglobin > 12,000.0 μ g/L. CK 11,842 U/L. LDH 2,347 U/L. CRP 111 mg/L
Suwanwongse et al. 2020 [33]	88, M	Pos	NA	Bilateral thighs weakness and pain	EMG/NCS were not performed	Rhabdomyolysis	CK 13,581 U/L. LDH 364 U/L

Table 4 (continued)

Author, Year	Mean age (years)	Patients, Number	Male/female, Number	SARS-CoV-2		Neurological presentation	Neurological investigations	Neurological diagnosis
				Nasal swab	CSF			
Toscano et al. 2020 [44] ^b	58.4	5	4/1	Pos (4) Neg (1)	Neg (5)	Tetraparesis (2), paraplegia (1), paresthesia (2), facial weakness (4), ataxia (2). Areflexia (5)	Days 3–12 EMG/NCS: axonal (3), demyelination (2). MRI: caudal nerves enhancement (2), facial nerves enhancement (1), normal (2)	GBS: AMSAN variant (3), AIDP variant (2)
Gutiérrez-Ortiz et al. 2020 [45] ^c	44.5	2	2/0	Pos (2)	Neg (2)	1. Vertical diplopia, perioral paresthesia, gait instability. Areflexia 2. Diplopia. Areflexia	Pos GD1b-IgG antibody CSF: protein 80 mg/dL, WBCs 0 cells. No EMG was performed	Miller Fisher syndrome (right INO and right fascicular oculo-motor palsy)
Chan et al. 2020 [46]	73	2	1/1	Pos (2)	NA	Generalized weakness (2), leg twitching (1)	CSF: protein 62 mg/dL, WBCs 2 cells / μ L Serum (ave): CK 2313 U/L; LDH 517.5 U/L. CRP: 11.25 mg/dL	Polyneuropitis cranialis (bilateral abducent nerve palsy) Rhabdomyolysis

GBS Guillain-Barré syndrome, AMSAN acute motor-sensory axonal neuropathy, CK creatine kinase, CMAP compound muscle action potential, COVID-19 Coronavirus disease 2019, EMG electromyography, ICU intensive care unit, LDH lactate dehydrogenase, MRI magnetic resonance imaging, NA not applicable, NCS nerve conduction studies, Neg negative, Pos positive, OCBs oligoclonal bands, PMN polymorphonuclear cells, RT-PCR real-time polymerase chain reaction, SARS-CoV-2 severe acute respiratory syndrome coronavirus 2, SNAP sensory nerve action potential, T2WI/FLAIR T2-weighted images/fluid attenuation inversion recovery, CRP C-reactive protein, PTT partial thromboplastin time, WBCs white blood cells, Ave average, CSF cerebral spinal fluid

^aNegative serum anti-gangliosides

^bCSF: protein (mg/dL): 101, 123, 193, normal protein, 40. WBCs (cells per mm³): 4,0,0,0,3. Antiganglioside antibodies: negative (3), not tested (2)

^cCase#1: Exam revealed limited adduction and downgaze movements of his right eye, and left eye nystagmus on left gaze. Case#2: Exam revealed limited abduction in both eyes, and fixation nystagmus, with the upper gaze more impaired

Table 5 Summary of the CNS infectious or inflammatory-related complications of COVID-19

Author, Year	Age(years), Sex	SARS-CoV-2		Neurological presentation	Neurological investigations	Neurological diagnosis	CSF and others
		Nasal swab	CSF				
Poyiadji et al. 2020 [12] ^a	58, F	Pos	NA	Altered mental status (AMS)	MRI: Hemorrhagic rim enhancing lesions within the bilateral thalami, medial temporal lobes, and subinsular regions	Acute hemorrhagic necrotizing encephalopathy	CSF was negative for HSV-1 and 2, VZV and West Nile PCRs
Moriguchi et al. 2020 [13] ^b	24, M	Neg	Pos	Headache then unconsciousness, generalized convulsions and neck rigidity	T2WI/FLAIR: hyperintensity in the right mesial temporal lobe and hippocampus	Meningitis/encephalitis ventriculitis	CSF: OP > 32 cmH ₂ O, 12 mononuclear cells, 2 PMNs, CSF HSV-1 PCR was not tested
Duong et al., Haung et al. 2020 [14, 15] ^c	41, F	Pos	Pos	Headache, new onset seizure, neck stiffness, fever and photophobia	CT head was normal EEG: Generalized slowing with no epileptic discharges	Meningoencephalitis	CSF: protein 100 mg/dL, WBCs 70 cells/ μ L, 100% lymphocyte. Glucose 120
Ye et al. 2020 [16] ^d	No age, M	Pos	Neg	Myalgia and confusion. Nuchal rigidity, positive Kernig sign and Brudzinski sign	CT head was normal	Encephalitis	CSF: OP 220 mmHg, Normal WBC, protein and glucose
Yin et al. 2020 [17]	64, M	Pos	Neg	AMS, neck stiffness. Positive clonus, Babinski, Chaddock and Brudzinski signs	CT head was normal	Encephalitis	CSF: OP 200 cmH ₂ O, protein, WBCs and glucose were normal
Filatov et al. 2020 [18] ^e	74, M	Pos	NA	Headache and AMS	EEG: bilateral slowing and focal slowing in the left temporal region with sharply contoured waves	Encephalopathy	CSF: protein 68 mg/dL, WBCs 4 cells/ μ L
Wong et al. 2020 [19] ^f	40, M	Pos	NA	Ataxia, diplopia, oscillopsia, hiccups, right arm paresthesia	MRI: T2 hyperintensity of the right inferior cerebellar peduncle and upper cord associated with micro-hemorrhages	Rhombencephalitis	CSF: normal WBC, protein and glucose
Vollono et al. 2020 [34] ^g	78, F	Pos	NA	Myoclonic jerks of the right face and right limbs. Fever	EEG: semi-rhythmic, irregular, high amplitude delta activity, predominantly over the left fronto-centro-temporal regions	Focal status epilepticus	CSF was not performed
Sohal et al. 2020 [35]	72, M	Pos	NA	AMS, episodes of tonic colonic movements	CT head: no acute findings EEG: Six left temporal seizures and left temporal sharp waves	Status epilepticus	CSF was not performed
Zanin et al. 2020 [36] ^h	54, F	Pos	Neg	AMS	MRI: Periventricular confluent white matter hyperintensity EEG: Two focal fronto-temporal seizures	Demyelinating lesions	CSF: normal WBC, protein and glucose. No OCBs were sent CRP 41.3 mg/L

Table 5 (continued)

Author, Year	Age(years), Sex	SARS-CoV-2		Neurological presentation	Neurological investigations	Neurological diagnosis	CSF and others
		Nasal swab	CSF				
Paniz-Mondolfi et al. 2020 [37]	74, M	Pos	NA	Confusion and falls	CT head: no acute findings Autopsy revealed 80 to 110 nm viral particles in frontal lobe brain (neurons and endothelial cells)	Postmortem presence of virus in neural and capillary endothelial cells in frontal lobe from a patient infected with COVID-19	CRP 183.5 mg/L, D-dimers 2925 ng/mL
Author, year	Mean age (years)	Patients, number	Male/female, number	SARS-CoV-2	Neurological presentation	Neurological investigations	Neurological diagnosis
Bernard-Valnet et al. 2020 [47] ⁱ	65.5	2	0/2	Pos (2) Neg (2)	1. tonic-clonic seizure. Verbal and motor perseverations 2. Intense headache and AMS. Left hemianopia and sensory hemineglect	EEG: status epilepticus MRI brain: normal CSF: protein 46.6 mg/dL, WBCs 17 cells/mm ³ (97% lymphs)	Meningoencephalitis
Dogan et al. 2020 [48] ^j	49.1	6	5/1	Pos (6) Neg (6)	Failure to recover consciousness or severe agitation during weaning from mechanical ventilation (6)	MRI brain: normal CSF: 46.1 mg/dL, WBCs 21 cells/mm ³ (89% lymphs) MRI: Cortical or WM hyperintensities, contrast enhancement, and sulcal hemorrhages (3)	Meningoencephalitis Autoimmune Meningoencephalitis

AMS altered mental status, OP opening pressure, CK Creatine Kinase, CMV Cytomegalovirus, COVID-19 Coronavirus disease 2019, CT Computed tomography, DWI Diffusion Weighted Images, EEG Electroencephalography, HSV Herpes Simplex Virus, ICU Intensive-care unit, LDH Lactate dehydrogenase, MRI Magnetic Resonance Imaging, NA not applicable, Neg negative, Pos positive, OCBs oligoclonal bands, PMN Polymorphonuclear cells, RT-PCR Real-Time Polymerase Chain Reaction, SARS-CoV-2 severe acute respiratory syndrome coronavirus 2, T2WI/FLAIR T2-weighted Images/Fluid Attenuation Inversion Recovery, VZV Varicella Zoster Virus, CRP C-reactive protein, WBCs white blood cells, CSF: cerebral spinal fluid, WM white matter

^aCSF analysis was limited due to traumatic LP

^bDWI: hyperintensity along the wall of the inferior horn of the right lateral ventricle

^cSARS-CoV-2 infection was entirely confined to the central nervous system

^dCSF anti-SARS-CoV-2 IgM and IgG were not detected

^eCT head revealed left PCA distribution encephalomalacia. CSF was negative for bacterial cultures, HSV PCR, RSV, and CMV PCR

^fMyelin oligodendrocyte glycoprotein antibody (MOG-IgG) and aquaporin 4 antibody results were requested, but no results reported

^gThe patient has history of well-controlled post-encephalitic epilepsy

^hMRI also reveals bulbo-medullary and C2-T6 focal intramedullary hyperintensities. No contrast enhancement

ⁱCase#1 Negative CSF anti-NMDA antibodies. Case #1&2: Negative HSV/VZV PCRs

^jSerum ferritin levels remarkably improved post-plasmapheresis in recovering patients. CSF (median): protein 69.4 mg/dL, WBCs 0 cells/μL, Glucose 116. OCBs neg (5)

Discussion

Our systematic review indicates that SARS-CoV-2 infection is not solely a respiratory illness, as neurological complications are not rare. Ischemic and hemorrhagic stroke, Guillain–Barre syndrome, and its variants, encephalitis, and seizure have all been observed, which emphasizes the importance of neurological surveillance. In an analysis of 214 cases of COVID-19 in Wuhan, China, 78 (36.4%) had neurological complications. Patients with severe infection were more likely to have neurological manifestations like alteration in sensorium and muscle weakness (45.5% Vs 30.2% in non-severe). The manifestations involved both the central and peripheral nervous system. The severity of these manifestations ranged from acute cerebrovascular disease and impaired consciousness to dizziness and headache [60].

Cerebrovascular complications

In our review, ischemic stroke was the most common neurological manifestation, occurring in 42.7% of the subjects, with LVO representing 77% of the ischemic stroke. According to a series of 388 COVID-19 patients from Italy, thromboembolic events occurred in 21% of the patients, including venous thromboembolism, ischemic stroke, and acute coronary syndrome [61]. The exact mechanism of the hypercoagulable state is not well understood. D-dimers might play a major prothrombotic role in COVID-19 patients. In this review, 80% of the ischemic stroke patients had elevated D-dimer levels, which are independently associated with poor outcome [62]. Severe COVID-19 respiratory infection often leads to sepsis induced hypercoagulability, evident by increased intravascular platelet activation, increased fibrinogen, and mild prolongation of PT and aPTT [63]. Indeed, a study in Wuhan, China, showed that 71.4% of patients who died of COVID-19 had disseminated intravascular coagulation (DIC) [62]. Moreover, SARS-CoV-2 virus is known to bind angiotensin-converting enzyme 2 (ACE2) on endothelial cells which promotes a proinflammatory and vasoconstrictive state of endothelial dysfunction leading to end organ damage, including stroke. ACE2 recombinant therapy, therefore, may be a promising targeted therapy for COVID-19-related stroke [64]. Transient production of antiphospholipid antibodies may also play a role. In a study by Harzallah et al., 25 out of 56 patients with confirmed or suspected SARS-CoV-2 infection were positive for lupus anticoagulants, and five patients had either anticardiolipin or anti- β 2-glycoprotein I antibodies [65]. Zhang et al. detected antiphospholipid antibodies in three COVID-19 patients; all of them had multiple cerebral infarcts [66]. In

this review, five of the LVO stroke tested positive for lupus anticoagulant.

When presenting in the appropriate time window, thrombolytic treatment of COVID-19 patients with ischemic stroke is reasonable. The role of anticoagulation, like LMWH, in this clinical context is still unclear [64]. Harzallah et al. recommended early anticoagulation therapy for individuals with SARS-CoV-2 infection and positive lupus anticoagulant [65]. Previous investigations suggested that COVID-19 is associated with both platelet and clotting cascade activation [67]. Further clinical trials are necessary to determine the role of antiplatelets and/or anticoagulation for the treatment and prevention of thrombotic events in COVID-19, including milder cases.

Neuromuscular complications

Previously identified coronaviruses, including SARS-CoV-1 and MERS, were associated with GBS [68]. In our review, neuromuscular disorders are the second most commonly encountered neurological complication of SARS-CoV-2 infection (28%), especially GBS. The mechanisms of GBS related to SARS-CoV-2 are still incompletely understood. Both para- and post-infectious mechanisms were proposed [20, 26]. Two patients, in our review, did not experience preceding fever, respiratory, or GI symptoms and GBS was the initial presentation. This suggests a para-infectious process, as has been reported recently with Zika virus [69]. One possible immunological explanation is the cytokine release syndrome (CRS), caused by an exacerbated recruitment and activation of macrophages, neutrophils, and natural killer cells (NK) in response to SARS-CoV-2 infection. Cytokines involved in CRS include IL-1 β , IL-1Ra, IL-6, IL-17, TNF- α , CCL2, and sIL2-R α ; a critical step in the process is binding of IL-6 to IL-6R (sIL-6R) causing JAK-STAT3 activation, and subsequent secretion of vascular endothelial growth factor (VEGF), monocyte chemoattractant protein-1 (MCP-1), IL-8, and more IL-6, as well as decreased E-cadherin expression [70, 71]. This cytokine storm can produce extensive tissue damage, including the peripheral nervous system [72], and appears to correlate with COVID-19 severity. Accordingly, several therapeutic options are under study, with the intent to stabilize the immune system in COVID-19 and either prevent or minimize the consequences of this storm, as reviewed by Diamanti et al. [73]

A second mechanism explaining GBS in COVID-19 may be production of antibodies against ganglioside components of the peripheral nerves, owing to molecular mimicry with surface antigens of the infectious pathogen. This mechanism explains GBS following *Campylobacter jejuni* infection [74], which is frequently associated with axonal findings on electrophysiology. Similar molecular

mimicry phenomena may occur in COVID-19 [75], and in fact, five cases in our review were electrophysiologically characterized as AMSAN, yet the exact frequency of ganglioside antibodies remains unknown, because those antibodies were not tested in most cases that we reviewed. Furthermore, sporadic reports of other autoimmune complications in the context of SARS-CoV-2 infection, such as steroid responsive encephalitis [76], immune thrombocytopenic purpura [77], and autoimmune hemolytic anemia [78], suggest that SARS-CoV-2 infection may serve as a trigger for autoimmune disorders.

With the emergence of more cases of acute neuropathies temporally linked to SARS-CoV-2 infection, we should gain a better understanding of the underlying pathophysiology and potential therapeutic options of GBS related to COVID-19. Since these neuropathies are treatable and they pose increased morbidity and mortality, neurologists, intensivists, and internists working with COVID-19 patients must be vigilant of this association.

CNS infection by COVID-19

Coronavirus can be neuroinvasive and cause direct CNS infection; this was convincingly demonstrated by the detection of particles and/or RNA of SARS-CoV-1, a virus with 79% genetic homology to SARS-CoV-2 [79], in human autopsies [80, 81]. Likewise, two of the cases that we reviewed showed positive CSF SARS-CoV-2 PCR [13, 15], and one [37] documented the evidence of viral particles in the neurons and capillary endothelial cells of the frontal lobe in a postmortem examination. The authors concluded that there was an active viral entry across the brain microvasculature into the neurons, as there was blebbing of viral particles coming in and out of the endothelial membrane [37]. Mechanistically, SARS-CoV-2 virus may enter the CNS through hematogenous route or retrograde synaptic transmission. The ACE 2 protein, which functions as a receptor for SARS-CoV-2, is abundantly expressed in the endothelial cells, supporting glia and neurons, and might be the binding site facilitating hematogenous entry. The systemic hyperinflammation increases the permeability of the blood–brain and blood–CSF barriers, which might facilitate CNS entry, as well [82, 83]. Retrograde synaptic transmission may occur via the olfactory nerve [84]. This possibility is supported by the fact that anosmia is a frequent early sign of COVID-19 [85]. It has been proposed that SARS-CoV-2 neurotropism may explain not only the common symptoms of encephalitis, but also the respiratory failure, by involvement of the medullary respiratory centers. This mechanism has been demonstrated in animal models, but not yet in humans [86].

It should be noted, however, that in most cases of suspected “meningoencephalitis”, the virus could not be detected in the CSF. There are several potential explanations

for this negative result. One is that the encephalitis in COVID-19 is more often immune-mediated, resulting from post-infectious or para-infectious mechanisms, and cytokine dysregulation, as previously discussed in GBS, rather than a result of direct viral invasion [83]. The response of the encephalitic syndrome to plasmapheresis in five cases [48] supports this notion, as does the occurrence of acute necrotizing encephalopathy in one case [12]. Acute necrotizing encephalopathy was previously described following influenza and other viral infections and attributed to cytokine storm [87]. A second explanation is that the virus may cause endothelial injury and induce a thrombotic microangiopathy (TMA)-like state, which can lead to severe encephalopathy with no evidence of inflammation based on CSF studies. A third theory is that PCR testing in the CSF has suboptimal sensitivity for the detection of SARS-CoV-2. This limitation of PCR is well known to neurologists, as it occurs with several other neuroinvasive viruses, including West Nile Virus [88], and enterovirus-D68 causing acute flaccid myelitis [89]. Detection of intrathecal virus-specific antibodies and their ratio to serum antibodies, and the recently developed metagenomic sequencing technology [90, 91], may increase the sensitivity of viral detection in the CSF in those cases, and it would be interesting to explore the utility of those techniques in COVID-19 in the near future. Detailed investigations, including CSF studies, imaging, and, when possible, autopsy, are required to better elucidate those mechanisms.

Epileptic complications

Although two COVID-19 patients in our review presented with status epilepticus, one of them had an established history of epilepsy from another cause. Lu et al. studied 304 COVID-19 patients and concluded that none of these patients had acute symptomatic seizures or status epilepticus [92]. The available data are too limited to make conclusions about the association of COVID-19 with development of seizures. Nevertheless, patients with severe SARS-CoV-2 infection, especially those hospitalized in intensive care units, are at risk for subclinical seizures or nonconvulsive status epilepticus (NCSE), owing to polypharmacy, metabolic derangements, toxemia, hypoxic-anoxic brain injury, or less commonly stroke or encephalitis related to SARS-CoV-2 infection. Therefore, continuous video EEG monitoring may be warranted in selected cases, as delayed diagnosis and treatment of NCSE will increase morbidity and mortality [93].

Finally, Lovati et al. reported a case of HSV-1 encephalitis, where the diagnosis and treatment were delayed because of anchoring on COVID-19 and its neurological complications [94]. Despite all the reports of COVID-19 neurological complications, other pathologies are still more common.

Table 6 Summary of previous systematic reviews of the neurological manifestations of SARS-CoV-2

Author, year	Goals	Search date	Reviewed studies	Reviewed pathologies	Conclusions	Comments/limitations
Whittaker et al., 2020 [95]	To provide a comprehensive review of the neurological manifestations of SARS-CoV-2 and its effect on mortality	Not reported. Submitted on April 30, 2020	Thirty-one studies: 13 case reports, 2 observational studies, 13 retrospective, 2 prospective and 1 cross-sectional study	Olfactory and gustatory dysfunction, Headache, encephalopathy, seizure, GBS, CVA	More data is required to correlate the neurological manifestations to SARS-CoV-2 infection	Very well-written paper Limited number of studies on cerebrovascular disease
Montalvan et al., 2020 [96]	To review the neurological aspects of SARS-CoV-2 and other coronaviruses	April 2020	Sixty-seven studies; 12 systematic reviews, 15 experimental model studies, 21 series, 3 cases and controls and 16 case reports Only 11 of the reviewed studies were related to the novel SARS-CoV-2. The rest were related to other coronaviruses	Encephalitis, demyelination, polyneuropathy, CVA	SARS-CoV-2 might be neuropathogenic, but underdiagnosed	Not limited to SARS-CoV-2. Limited description of the clinical manifestations which limits its use as a reference for clinicians
Leonardi et al., 2020 [97]	To prove the presence of central and peripheral nervous system manifestations in Coronavirus	April 5, 2020	29 studies were examined	CVA, GBS, hypoguesia, hyposmia, encephalopathy, encephalitis, rhabdomyolysis, seizure	Prospective cohorts are needed to identify any long-term neurological complications of SARS-CoV-2. Recommended open data sharing between centers	Limited description of the clinical manifestations which limits its use as a reference for clinicians
Asadi-Pooya et al., 2020 [98]	To discuss the evidence of CNS involvement in SARS-CoV-2	March 26, 2020	Two main studies identified (a narrative review and a viewpoint). Six other reports were extracted from their reference lists	CVA, headache, confusion, dizziness, ataxia, seizures	It is very likely that patients with severe infection would have neurological manifestations of SARS-CoV-2	Limited number of studies Did not describe the clinical manifestations which limits its use as a reference for clinicians
Munhoz et al., 2020 [99]	To point out the main neurological manifestations of SARS-CoV-2 with their epidemiology, pathophysiology, and clinical findings	May 10, 2020	Thirty-seven studies. Including case reports and series, retrospective studies, and a prospective study	CVA, encephalopathy, GBS, anosmia, ageusia, myalgias, headache	Neurological manifestations occur in > 1/3 of the hospitalized patients with variable severity. SARS-CoV-2 may be neuroinvasive and/or indirectly affects the CNS and PNS	A well-written review with useful information for clinicians
Romoli et al., 2020 [100]	To identify cases of confirmed nervous system invasion or post-infectious manifestation	April 24, 2020	Twenty-seven studies: 14 case reports, 5 series, 2 case-control, 2 cross-sectional, 2 prospective, and 2 retrospective studies	CVA, GBS, encephalopathy meningitis, encephalitis, smell and taste changes	More precise and larger clinical studies are required with follow up. Suggested a reporting system for future research in the topic	Provides useful guidance for future research and reporting

GBS Guillain-Barré syndrome, *CNS* central nervous system, *CVA* cerebrovascular disease, *PNS* peripheral nervous system, *SARS-CoV-2* severe acute respiratory syndrome coronavirus 2

Ignoring this would result in significant delays in diagnosing and treating neurological patients.

A number of recently published systematic reviews on COVID-19 have addressed the same topic (Table 6). The novelty of our review lies in the breadth of coverage, allowing it to serve as a primer for neurologists by summarizing the most recent evidence and the most important and relevant practical points. However, our study has some limitations. First, most of the used evidence is based on single case reports or small series, which limits its generalizability. Second, some case reports did not complete or report the full work-up required to exclude alternative causes of the neurological syndrome presented. Third, many cases are reported from specific ethnic populations, and hence, several demographics, genetic, or microbiologic variables might preclude the applicability of the conclusions in different populations. Fourth, several stroke patients had multiple comorbidities and potentially causative vascular risk factors that we did not include in our analysis. Fifth, due to incomplete work-up of several of the ischemic stroke studies included in the review, we did not have enough data for accurate stroke mechanism classification per TOAST in several cases. Last but not least, because of the small number of subjects studied and the suboptimal quality of study design, it is not possible to reach firm conclusions about the causal effect of COVID-19 for some neurological disorders.

Conclusions

Neurological manifestations of COVID-19 are not rare, especially large vessel stroke, Guillain–Barre syndrome, and meningoencephalitis. They could be related to the direct cytopathic effect of the virus, the inflammatory response, hypercoagulable state, or complications of treatment and ICU stay. Moving forward, further studies are needed to clarify the prevalence of the neurological complications of COVID-19, investigate their biological background, and test treatment options. Physicians should be cautious not to overlook other neurological diagnoses that can mimic COVID-19 during the pandemic.

Author contributions Dr. Ghannam planned the search strategy, made the inclusion and exclusion criteria, and built the key words for the systematic review. Dr. Ghannam, Dr. Alshaer and Dr. Manousakis participated in articles screening and assessing their eligibility to the study. Both Dr. Ghannam and Dr. Manousakis completed the final form of PRISMA flowchart of the selection of the studies for this review. Dr. Ghannam, Dr. Alshaer, Dr. Al-Chalabi, Dr. Zakarna and Dr. Robertson were responsible for drafting and editing the manuscript. Dr. Ghannam was responsible for making the tables and the figures. Dr. Manousakis participated in critical revision of the manuscript for intellectual content. All authors read and approved the final manuscript.

Funding No funding was obtained for this study.

Data availability All the data supporting our findings are contained within manuscript.

Compliance with ethical standards

Conflicts of interest The authors declare that they have no competing interests.

Ethical approval There was no ethics committee approval as the data have been analyzed in a retrospective manner and have no effect on treatment of the patient.

References

1. Paules CI, Marston HD, Fauci AS (2020) Coronavirus infections—more than just the common cold. *JAMA* 323(8):707–708
2. Perlman S (2020) Another decade, another coronavirus. *N Engl J Med* 382(8):760–762
3. Niu J et al (2020) Non-invasive bioluminescence imaging of HCoV-OC43 infection and therapy in the central nervous system of live mice. *Antiviral Res* 173:104646
4. Tsai LK, Hsieh ST, Chang YC (2005) Neurological manifestations in severe acute respiratory syndrome. *Acta Neurol Taiwan* 14(3):113–119
5. Lau KK et al (2004) Possible central nervous system infection by SARS coronavirus. *Emerg Infect Dis* 10(2):342–344
6. Netland J et al (2008) Severe acute respiratory syndrome coronavirus infection causes neuronal death in the absence of encephalitis in mice transgenic for human ACE2. *J Virol* 82(15):7264–7275
7. Guan WJ, Ni ZY, Hu Y et al (2020) Clinical characteristics of coronavirus disease 2019 in China. *N Engl J Med* 382(18):1708–1720
8. Pérez CA (2020) Looking ahead: the risk of neurologic complications due to COVID-19. *Neurol Clin Pract*. <https://doi.org/10.1212/CJP.0000000000000836>
9. Guan WJ, Liang WH, Zhao Y et al (2020) Comorbidity and its impact on 1590 patients With COVID-19 in China: a nationwide analysis. *Eur Respir J* 55(5):2000547
10. Moher D, Shamseer L, Clarke M et al (2015) Preferred reporting items for systematic review and meta-analysis protocols (PRISMA-P) 2015 statement. *Syst Rev* 4(1):1
11. Moola S, Munn Z, Sears K et al (2015) Conducting systematic reviews of association (etiology): The Joanna Briggs Institute’s Approach. *Int J Evid Based Healthc*. 13(3):163–169 (**12–54 Tables 1**)
12. Poyiadji N, Shahin G, Noujaim D et al (2020) COVID-19-associated acute hemorrhagic necrotizing encephalopathy: CT and MRI features. *Radiology* 201187
13. Moriguchi T, Harii N, Goto J et al (2020) A first case of Meningitis/Encephalitis associated with SARS-Coronavirus-2. *Int J Infect Dis*. 94:55–58
14. Duong L, Xu P, Liu A (2020) Meningoencephalitis without respiratory failure in a young female patient with COVID-19 infection in Downtown Los Angeles, early April 2020. *Brain Behav Immun*. <https://doi.org/10.1016/j.bbi.2020.04.024>
15. Huang Y, Jiang D, Huang J (2020) SARS-CoV-2 detected in cerebrospinal fluid by PCR in a case of COVID-19 encephalitis. *Brain Behav Immun*. <https://doi.org/10.1016/j.bbi.2020.05.012>

16. Ye M, Ren Y, Lv T (2020) Encephalitis as a clinical manifestation of COVID-19. *Brain Behav Immun*. <https://doi.org/10.1016/j.bbi.2020.04.017>
17. Yin R, Feng W, Wang T et al (2020) Concomitant neurological symptoms observed in a patient diagnosed with coronavirus disease 2019. *J Med Virol*. <https://doi.org/10.1002/jmv.25888>
18. Filatov A et al (2020) Neurological complications of coronavirus disease (covid-19): encephalopathy. *Cureus* 12(3):e7352
19. Wong PF, Craik S, Newman P et al (2020) Lessons of the month 1: a case of rhombencephalitis as a rare complication of acute COVID-19 infection. *Clin Med (Lond)* clinmed.2020-0182
20. Zhao H, Shen D, Zhou H et al (2020) Guillain-Barré syndrome associated with SARS-CoV-2 infection: causality or coincidence? *Lancet Neurol* 19(5):383–384
21. Sedaghat Z, Karimi N (2020) Guillain Barre syndrome associated with COVID-19 infection: a case report. *J Clin Neurosci* 76:233–235
22. Virani A, Rabold E, Hanson T et al (2020) Guillain-Barré Syndrome associated with SARS-CoV-2 infection. *IDCases* 20:e00771
23. El Otmami H, El Moutawakil B, Rafai MA et al (2020) Covid-19 and Guillain-Barré syndrome: more than a coincidence! *Rev Neurol (Paris)* 176(6):518–519
24. Alberti P, Beretta S, Piatti M et al (2020) Guillain-Barré syndrome related to COVID-19 infection. *Neurol Neuroimmunol Neuroinflamm* 7(4):e741
25. Camdessanche JP, Morel J, Pozzetto B et al (2020) COVID-19 may induce Guillain-Barré syndrome. *Rev Neurol (Paris)* 176(6):516–518
26. Padroni M, Mastrangelo V, Asioli GM et al (2020) Guillain-Barré syndrome following COVID-19: new infection, old complication? *J Neurol* 24:1–3
27. Scheidl E, Canseco DD, Hadji-Naumov A et al (2020) Guillain-Barre syndrome during SARS-CoV-2 pandemic: a case report and review of recent literature. *J Peripher Nerv Syst*. <https://doi.org/10.1111/jns.12382>
28. Ottaviani D, Boso F, Tranquillini E et al (2020) Early Guillain-Barré syndrome in coronavirus disease 2019 (COVID-19): a case report from an Italian COVID-hospital. *Neurol Sci* 41(6):1351–1354
29. Abdelnour L, Abdalla ME, Babiker S (2020) COVID 19 infection presenting as motor peripheral neuropathy. *J Formos Med Assoc* 119(6):1119–1120
30. Juliao Caamaño DS, Beato RA (2020) Facial diplegia, a possible atypical variant of Guillain-Barré Syndrome as a rare neurological complication of SARS-CoV-2. *J Clin Neurosci*
31. Wei H, Yin H, Huang M et al (2020) The 2019 novel coronavirus pneumonia with onset of oculomotor nerve palsy: a case study. *J Neurol* 25:1–4
32. Jin M, Tong Q (2020) Rhabdomyolysis as potential late complication associated with COVID-19. *Emerg Infect Dis* 26(7)
33. Suwanwongse K, Shabarek N (2020) Rhabdomyolysis as a presentation of 2019 novel coronavirus disease. *Cureus* 12(4):e7561
34. Vollono C, Rollo E, Romozzi M et al (2020) Focal status epilepticus as unique clinical feature of COVID-19: a case report. *Seizure* 21(78):109–112
35. Sohal S, Mossamat M (2020) COVID-19 presenting with seizures. *IDCases* 1:e00782
36. Zanin L, Saraceno G, Panciani PP et al (2020) SARS-CoV-2 can induce brain and spine demyelinating lesions. *Acta Neurochir (Wien)* 4:1–4
37. Paniz-Mondolfi A, Bryce C, Grimes Z et al (2020) Central nervous system involvement by severe acute respiratory syndrome Coronavirus -2 (SARS-CoV-2). *J Med Virol* 92(7):699–702
38. González-Pinto T, Luna-Rodríguez A, Moreno-Estébanez A et al (2020) Emergency room neurology in times of COVID-19: malignant ischemic stroke and SARS-COV2 infection. *Eur J Neurol*. <https://doi.org/10.1111/ene.14286>
39. Zhou B, She J, Wang Y et al (2020) A case of coronavirus disease 2019 with concomitant acute cerebral infarction and deep vein thrombosis. *Front Neurol* 22(11):296
40. Valderrama EV, Humbert K, Lord A et al (2020) Severe acute respiratory syndrome Coronavirus 2 infection and ischemic stroke. *Stroke STROKEAHA* 120030153
41. Viguier A, Delamarre L, Duplantier J et al (2020) Acute ischemic stroke complicating common carotid artery thrombosis during a severe COVID-19 infection. *J Neuroradiol*. <https://doi.org/10.1016/j.neurad.2020.04.003>
42. Hughes C, Nichols T, Pike M et al (2020) Cerebral venous sinus thrombosis as a presentation of COVID-19. *Eur J Case Rep Intern Med* 7(5):001691
43. Sharifi-Razavi A, Karimi N, Rouhani N (2020) COVID-19 and intracerebral haemorrhage: causative or coincidental? *New Microbes New Infect* 27(35):100669
44. Toscano G, Palmerini F, Ravaglia S et al (2020) Guillain-Barré Syndrome associated with SARS-CoV-2. *N Engl J Med NEJMc2009191*
45. Gutiérrez-Ortiz C, Méndez A, Rodrigo-Rey S et al (2020) Miller Fisher Syndrome and polyneuritis cranialis in COVID-19. *Neurology*. <https://doi.org/10.1212/WNL.00000000000009619>
46. Chan KH, Farouji I, Abu Hanoud A et al (2020) Weakness and elevated creatinine kinase as the initial presentation of coronavirus disease 2019 (COVID-19). *Am J Emerg Med*. <https://doi.org/10.1016/j.ajem.2020.05.015>
47. Bernard-Valnet R, Pizzarotti B, Anichini A et al (2020) Two patients with acute meningo-encephalitis concomitant to SARS-CoV-2 infection. *Eur J Neurol*. <https://doi.org/10.1111/ene.14298>
48. Dogan L, Kaya D, Sarikaya T et al (2020) Plasmapheresis treatment in COVID-19-related autoimmune meningoencephalitis: case series. *Brain Behav Immun*. <https://doi.org/10.1016/j.bbi.2020.05.022>
49. Avula A, Nalleballe K, Narula N et al (2020) COVID-19 presenting as stroke. *Brain Behav Immun*. <https://doi.org/10.1016/j.bbi.2020.04.077>
50. Al Saiegh F, Ghosh R, Leibold A et al (2020) Status of SARS-CoV-2 in cerebrospinal fluid of patients with COVID-19 and stroke. *J Neurol Neurosurg Psychiatry*. <https://doi.org/10.1136/jnnp-2020-323522>
51. Beyrouti R, Adams ME, Benjamin L et al (2020) Characteristics of ischaemic stroke associated with COVID-19. *J Neurol Neurosurg Psychiatry*. <https://doi.org/10.1136/jnnp-2020-323586>
52. Oxley TJ, Mocco J, Majidi S et al (2020) Large-vessel stroke as a presenting feature of Covid-19 in the young. *N Engl J Med*. 382(20):e60
53. Tunç A, Ünlübaşı Y, Alemdar M et al (2020) Coexistence of COVID-19 and acute ischemic stroke report of four cases. *J Clin Neurosci*. <https://doi.org/10.1016/j.jocn.2020.05.018>
54. Li Y, Wang M, Zhou Y, Chang J (2020) Acute cerebrovascular disease following COVID-19: a single center, retrospective, observational study. Available at SSRN: <https://ssrn.com/abstract=3550025>
55. Weitz JI, Fredenburgh JC, Eikelboom JW (2017) A test in context: D-Dimer. *J Am Coll Cardiol*. 70(19):2411–2420
56. Ranucci M, Ballotta A, Di Dedda U et al (2020) The procoagulant pattern of patients with COVID-19 acute respiratory distress syndrome. *J Thromb Haemost*
57. Clyne B, Olshaker JS (1999) The C-reactive protein. *J Emerg Med Nov-Dec* 17(6):1019–1025
58. Liu F, Li L, Xu M et al (2020) Prognostic value of interleukin-6, C-reactive protein, and procalcitonin in patients with COVID-19. *J Clin Virol* 127:104370

59. Levy JH, Goodnough LT (2015) How I use fibrinogen replacement therapy in acquired bleeding. *Blood* 125:1387
60. Mao L, Jin H, Wang M et al (2020) Neurologic manifestations of hospitalized patients with coronavirus disease 2019 in Wuhan, China. *JAMA Neurol* e201127
61. Lodigiani C, Iapichino G, Carenzo L et al (2020) Venous and arterial thromboembolic complications in COVID-19 patients admitted to an academic hospital in Milan, Italy. *Thromb Res* 23(191):9–14
62. Tang N, Li D, Wang X (2020) Abnormal coagulation parameters are associated with poor prognosis in patients with novel coronavirus pneumonia. *J Thromb Haemost* 18(4):844–847
63. Violi F, Pastori D, Cangemi R et al (2020) Hypercoagulation and antithrombotic treatment in Coronavirus 2019: a new challenge. *Thromb Haemost* 120(6):949–956
64. Hess DC, Eldahshan W, Rutkowski E (2020) COVID-19-related stroke. *Transl Stroke Res* 7:1–4
65. Harzallah I, Debliquis A, Drénou B (2020) Lupus anticoagulant is frequent in patients with Covid-19. *J Thromb Haemost*. <https://doi.org/10.1111/jth.14867>
66. Zhang Y, Xiao M, Zhang S et al (2020) Coagulopathy and antiphospholipid antibodies in patients with Covid-19. *N Engl J Med* 382(17):e38
67. Connell NT, Battinelli EM, Connors JM (2020) Coagulopathy of COVID-19 and antiphospholipid antibodies. *J Thromb Haemost*. <https://doi.org/10.1111/jth.14893>
68. Chao CC et al (2003) Peripheral nerve disease in SARS: report of a case. *Neurology* 61(12):1820–1821
69. da Silva IRF, Frontera JA, Bispo de Filippis AM et al (2017) Neurologic complications associated with the zika virus in Brazilian adults. *JAMA Neurol* 74(10):1190–1198
70. Moore JB, June CH (2020) Cytokine release syndrome in severe COVID-19. *Science* 368(6490):473–474
71. Jamilloux Y, Henry T, Belot A et al (2020) Should we stimulate or suppress immune responses in COVID-19? Cytokine and anti-cytokine interventions. *Autoimmun Rev* 19(7):102567
72. Lyons-Weiler J (2020) Pathogenic priming likely contributes to serious and critical illness and mortality in COVID-19 via autoimmunity. *J Transl Autoimmun* 9(3):100051
73. Diamanti AP, Rosado MM, Pioli C et al (2020) Cytokine release syndrome in COVID-19 patients, a new scenario for an old concern: the fragile balance between infections and autoimmunity. *Int J Mol Sci* 21(9):E3330
74. Willison HJ, Jacobs BC, van Doorn PA (2016) Guillain-Barré Syndrome. *Lancet* 388(10045):717–727
75. Cappello F (2020) Is COVID-19 a proteiform disease inducing also molecular mimicry phenomena? *Cell Stress Chaperones* 25(3):381–382
76. Pilotto A, Odolini S, Masciocchi SS et al (2020) Steroid-responsive encephalitis in Covid-19 disease. *Ann Neurol*. <https://doi.org/10.1002/ana.25783>
77. Zulfiqar AA, Lorenzo-Villalba N, Hassler P et al (2020) Immune thrombocytopenic purpura in a patient with Covid-19. *N Engl J Med* 382(18):e43
78. Lazarian G, Quinquenel A, Bellal M et al (2020) Autoimmune haemolytic anaemia associated with COVID-19 infection. *Br J Haematol*. <https://doi.org/10.1111/bjh.16794>
79. Wang H, Li X, Li T et al (2020) The genetic sequence, origin, and diagnosis of SARS-CoV-2. *Eur J Clin Microbiol Infect Dis* 24:1–7
80. Gu J, Gong E, Zhang B et al (2005) Multiple organ infection and the pathogenesis of SARS. *J Exp Med* 202(3):415–424
81. Xu J, Zhong S, Liu J et al (2005) Detection of severe acute respiratory syndrome coronavirus in the brain: potential role of the chemokine mig in pathogenesis. *Clin Infect Dis* 41(8):1089–1096
82. McGonagle D, Sharif K, O'Regan A et al (2020) The role of cytokines including interleukin-6 in COVID-19 induced pneumonia and macrophage activation syndrome-like disease. *Autoimmun Rev* 3:102537
83. Qin C, Zhou L, Hu Z et al (2020) Dysregulation of immune response in patients with COVID-19 in Wuhan, China. *Clin Infect Dis*. <https://doi.org/10.1093/cid/ciaa248>
84. Mao XY, Jin WL (2020) The COVID-19 pandemic: consideration for brain infection. *Neuroscience* 437:130–131
85. Gane SB, Kelly C, Hopkins C (2020) Isolated sudden onset anosmia in COVID-19 infection. A novel syndrome? *Rhinology* 58(3):299–301
86. Li YC, Bai WZ, Hashikawa T (2020) The neuroinvasive potential of SARS-CoV2 may play a role in the respiratory failure of COVID-19 patients. *J Med Virol*
87. Wu X, Wu W, Pan W et al (2015) Acute necrotizing encephalopathy: an underrecognized clinicoradiologic disorder. *Mediators Inflamm* 2015:792578
88. Briese T, Glass WG, Lipkin WI (2000) Detection of West Nile Virus sequences in cerebrospinal fluid. *Lancet* 355(9215):1614–1615
89. Chong PF, Kira R, Mori H et al (2018) Clinical features of acute Flaccid Myelitis temporally associated with an Enterovirus D68 outbreak: results of a nationwide survey of acute flaccid paralysis in Japan, August–December 2015. *Clin Infect Dis* 66(5):653–664
90. Schubert RD, Hawes IA, Ramachandran PS et al (2019) Pan-viral serology implicates enteroviruses in acute flaccid myelitis. *Nat Med* 25(11):1748–1752
91. Wilson MR, Sample HA, Zorn KC et al (2019) Clinical metagenomic sequencing for diagnosis of meningitis and encephalitis. *N Engl J Med* 380(24):2327–2340
92. Lu L, Xiong W, Liu D et al (2020) New onset acute symptomatic seizure and risk factors in coronavirus disease 2019: a retrospective multicenter study. *Epilepsia*. <https://doi.org/10.1111/epi.16524>
93. Gelisse P, Rossetti AO, Genton P et al (2020) How to carry out and interpret EEG recordings in COVID-19 patients in ICU? *Clin Neurophysiol*. <https://doi.org/10.1016/j.clinph.2020.05.006>
94. Lovati C, Osio M, Pantoni L (2020) Diagnosing herpes simplex-1 encephalitis at the time of COVID-19 pandemic. *Neurol Sci*
95. Whittaker A, Anson M, Harky A (2020) Neurological manifestations of COVID-19: a systematic review and current update. *Acta Neurol Scand* 142(1):14–22
96. Montalvan V, Lee J, Bueso T et al (2020) Neurological manifestations of COVID-19 and other coronavirus infections: a systematic review. *Clin Neurol Neurosurg* 194:105921
97. Leonardi M, Padovani A, McArthur JC (2020) Neurological manifestations associated with COVID-19: a review and a call for action. *J Neurol* 1–4
98. Asadi-Pooya A, Simani L (2020) Central nervous system manifestations of COVID-19: a systematic review. *J Neurol Sci* 413:116832
99. Munhoz R, Pedrosa J, Nascimento F et al (2020) Neurological complications in patients with SARS-CoV-2 infection: a systematic review. *Arq Neuropsiquiatr* 78(5):290–300
100. Romoli M, Jelcic I, Bernard-Valnet R et al (2020) A systematic review of neurological manifestations of SARS-CoV-2 infection: the devil is hidden in the details. *Eur J Neurol*