



ELSEVIER

Contents lists available at [ScienceDirect](https://www.sciencedirect.com)

Trauma Case Reports

journal homepage: www.elsevier.com/locate/tcr

Case Report

Partial triceps tendon avulsion delayed reconstruction using Achilles tendon allograft, a case report

Klemen Aleš Pilih^{a,*}, Mitja Kozic^b

^a Department of Traumatology and Orthopedics, General Hospital Slovenj Gradec, Gosposvetska cesta 1, 2380 Slovenj Gradec, Slovenia

^b Department of Traumatology, University Medical Centre Maribor, Ljubljanska ulica 5, 2000 Maribor, Slovenia

ARTICLE INFO

Keywords:

Triceps tendon avulsion
Surgical treatment
Delayed reconstruction
Achilles tendon allograft
Isokinetic strength measurement

ABSTRACT

A case report of a 32-year-old bodybuilder with an incomplete triceps tendon avulsion on his right dominant upper extremity is presented. At initial presentation, an avulsion injury was suspected. Ultrasound diagnostics pointed toward partial distal triceps tendon rupture, and since the patient had retained active elbow extension, a trial of conservative treatment was initiated. The patient failed to regain forceful elbow extension. MRI revealed an avulsion fracture of the olecranon with large partial triceps tendon rupture with muscle retraction. A triceps tendon tenolysis and fixation with transosseous olecranon sutures was conducted in a secondary trauma center. However, we failed to recognize the true tendon in the extensive scar tissue formation, and the patient did not regain appropriate elbow extension strength. He was administered to a university medical center. An extensive triceps tenolysis was performed along with clear identification of retracted bony avulsion fragment and re-fixation of true triceps tendon on the olecranon using Achilles tendon allograft. During the postoperative period and physical rehabilitation therapy, the patient gradually developed normal elbow extension strength and was able to return to bodybuilding without limitations. Goniometric measurements and isokinetic testing were performed one year after the second surgery, showing only a minor reduction of right elbow extension strength compared to the uninjured elbow. Elbow function measured by the functional score questionnaire was comparable to the uninjured upper extremity.

Introduction

Triceps tendon injuries are uncommon, representing less than 1 % of tendon injuries in human [1]. Injury is more common in men, with a mean age between 30 and 50 years [2]. A primary mechanism of injury is a force-full elbow extension against resistance or a fall on an outstretched arm [2,3]. Anabolic steroid use is a significant risk factor, making young male weightlifters a clear risk group for the injury [4]. Other risk factors reported include chronic olecranon bursitis [5], local corticosteroid injections [6], or systemic diseases [7]. Interestingly, about one-third of patients report a history of chronic elbow pain with activity before injury [7], and about two-thirds of patients have radiological signs of chronic triceps tendinitis at the time of the injury [7].

When injury occurs, a clear “pop” is often felt at the tendon's anatomical detachment site of the tendon [3]. The injury typically represents itself with pain and swelling at the extensor side of the elbow [2,3]. With complete or larger partial tears, a gap in the tendon may be palpable. Often clinical observation of an extension deficit is compromised acutely since pain may inhibit any movement.

* Corresponding author at: General Hospital Slovenj Gradec, Gosposvetska cesta 1, 2380 Slovenj Gradec, Slovenia.
E-mail address: klemen.pilih@sb-sg.si (K.A. Pilih).

However, the elbow extension against gravity can be preserved despite complete central tendon rupture due to the preservation of both the medial and lateral tendinous insertion [2,8] and anconeus muscle. Since the injury is most common at the tendon-osseous junction, it often presents with a bony avulsion fragment visible on an X-ray (tear sign). Although X-ray may be informative, ultrasound (US) or magnetic resonance imaging (MRI) are often needed to confirm the diagnosis and to assess the injury severity and possible muscle retraction. It is not uncommon that the correct diagnosis is missed or injury severity underestimated predominantly due to the infrequency of the injury and low clinical suspicion [2]. Consequentially, the patients are unsuccessfully treated for months until the correct diagnosis is reached and proper treatment is initiated.

There is a lack of data published on distal triceps injuries and reconstruction procedures in particular. The largest study on surgical treatment of distal triceps tendon ruptures has been conducted on American military personnel [7]. However, it has been based on the treatment of acute ruptures, with the majority of procedures being repairs and not reconstructions. They concluded that surgical repair reliably restores triceps function even in high-demand patients. The largest report on reconstructive procedures we encountered is based on Mayo Clinic experience [8], where they report on 16 procedures: eight primary repairs and eight reconstructions. In the repairs the strength of the injured extremity returned within an average of 90 % of the uninjured extremity, while with reconstructions the mean strength of recovery was 85 %. As a special notion, the author suggests that especially with reconstructions the time to recovery may be somewhat prolonged, with some patients still demonstrating improvement even one year after surgery.

Even though the surgery has an established role as a successful treatment of substantial distal triceps tendon injury, a successful conservative treatment trial has been reported with a near-to-total distal triceps rupture [9]. This puts even more pressure on the scientific community to develop evidence-based treatment guidelines for distal triceps ruptures.

Treatment course

The patient presented himself to the ER 5 days after an injury to his dominant right elbow. He has fallen from a standing height and has hit a solid object with the extensor side of his elbow. As an amateur bodybuilder, he had been experiencing pain at physical exercise in the injured elbow for some time before the injury. He later admitted to occasionally using human growth hormone. Clinical findings at presentation showed a swollen and painful right elbow with hematoma formation in the proximal forearm. Active motion in the injured elbow was preserved, however, extension against resistance was painful. X-ray showed an osseous loose body approx. 4 cm proximal to the tip of the olecranon and was interpreted as a possible bony avulsion fracture or the olecranon (Fig. 1). A senior trauma surgeon was consulted. RICE therapy and diagnostic US were recommended. US was performed the following day, showing partial medial triceps head retraction but overall preserved triceps tendon continuity. Conservative treatment was initiated based on the US exam. The patient was instructed to restrain himself from heavy exercise for 1 month and to perform range-of-motion exercises. He was instructed to return to outpatient control should deficient muscle strength persist.

The patient underwent early rehabilitation without success. Deficient elbow extensor strength was observed, and MRI was recommended. The MRI performed approx. 3 months after the injury showed avulsion injury of the triceps tendon with blurred architecture of the medial and long triceps head. The patient was again referred to our department, where operative treatment was recommended. Due to personal reasons, the patient postponed the procedure until approx. 5 months after the injury.

During an initial operative procedure, a vast scar tissue formation was observed just under the skin incision. We believed we were able to recognize the true triceps tendon with a bony chip correctly. Tenolysis and re-fixation of the tendon to the olecranon with

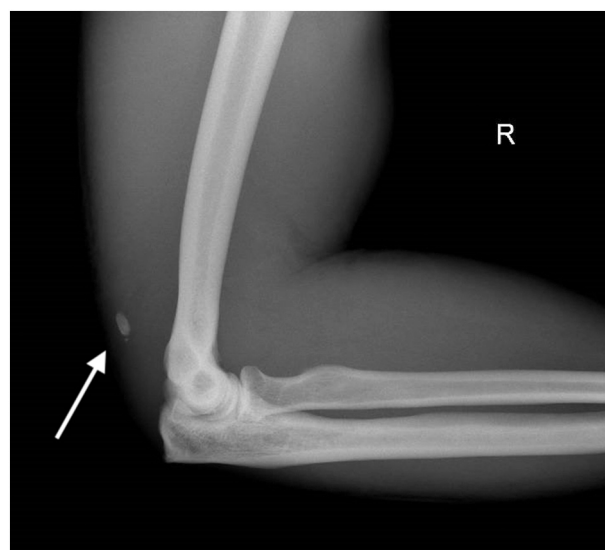


Fig. 1. Lateral X-ray of the injured elbow at the presentation. A bony avulsion fragment can be seen (arrow).

transosseous sutures was performed based on the modified Paci technique [10]. A strong construct was created, tested for strength intraoperatively, and the operation completed. The postoperative X-ray revealed, however, an unchanged location of the avulsion fragment, meaning we had failed in intraoperative recognition of the true triceps tendon and had only fixed scar tissue to the olecranon. A senior trauma-orthopedic surgeon in a university medical center was consulted, and the patient was openly discussed. A joint decision was reached to complete the postoperative rehabilitation protocol and reassess muscle strength upon completion of training. Rehabilitation failed to restore appropriate elbow extension strength, and a second procedure was planned. Additionally, the patient developed sharp pain at forced elbow extension, located at the ulnar transosseous suture exit point from the olecranon. MRI was performed preoperatively, showing an increased triceps tendon retraction with the defect measured at nearly 6 cm (Fig. 2).

The second procedure was performed in August 2020. The operative technique was based on an operative technique described by Morrey [8]. An extensive dorsal midline approach was performed by expanding the old postoperative scar on the upper arm proximally. Triceps aponeurosis was visualized. Previously, we had measured the exact distance of the bony avulsion fragment from the tip of the olecranon on the MRI, and we located it intraoperatively in the scar tissue with a needle after measuring the distance from the olecranon. After clearly visualizing and releasing the bony chip, an extensive triceps tendon tenolysis above the middle of the upper arm was performed, and old suture material was removed. Also, we released the ulnar nerve and transposed it in front of the medial epicondyle for the time of operation, only to lay it back in its anatomical position after the triceps tendon reconstruction has been completed. While releasing the ulnar nerve, it has become clear that the ulnar-most transosseous suture exit point on the olecranon from the first operation was laid in great proximity to the nerve, and we recommend cautiousness and identification of the nerve with extensive procedures in the future. Other anatomical structures were not visualized as we felt they were not particularly at risk. After mobilization of the triceps tendon, a 2 cm gap remained. An Achilles tendon allograft without a calcaneal bone fragment was used to bridge the gap to the olecranon. An osseous groove was performed on the dorsal aspect of the olecranon to accommodate 3 cm of the tubular portion of the allograft. Three transverse transosseous canals were drilled bilaterally in the sidewalls of the groove, and the allograft was fixed through them. In full extension, the proximal portion of the allograft was laid over the distal triceps and securely sutured to the aponeurosis (Fig. 3). The arm was laid into a splint with 30° flexion.

Three weeks post-op, passive movement until 90° of elbow flexion was initiated. Eight weeks post-op, active exercises using elastic bands were allowed. The patient was highly motivated and has self-reportedly gained full range of motion 3 months post-op, while at the same time beginning strength training. At first with moderate weight and then gradually increasing the load. Since he did not report any pain, he was allowed to fully engage in bodybuilding 6 months post-op and has progressively regained strength since.

Goniometric measurements (Table 1) and isokinetic testing (Table 2) were performed 1 year after the second surgery. Goniometric measurements showed a comparable range of motion of both (injured and uninjured) elbows. Isokinetic analysis showed that the torque of the extensors of the injured elbow was only slightly decreased compared to the uninjured side.

One year after the second surgery, a control MRI was performed, showing reconstructed triceps tendon continuity (Fig. 2). Oxford elbow score (OES) and Disabilities of the Arm, Shoulder and Hand (DASH) were performed. OES has dropped from 44/60 preoperatively to 12/60 postoperatively, and DASH score has fallen from 44.2 preoperatively to 0 postoperatively, reflecting a great improvement. Furthermore, one-year post-surgery the patient feels he can live his life unaffected by the injury.

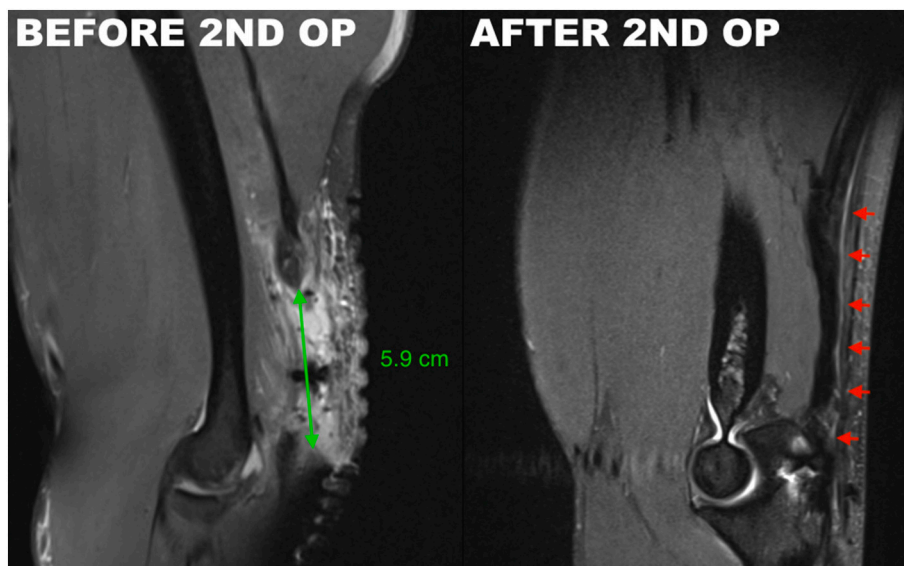


Fig. 2. MRI comparison before and after the 2nd operation.

Left image (before 2nd op.) shows a significant defect (green arrow) between the bony avulsion fragment and the olecranon tip. Right image (after 2nd op.) shows a continuity of the reconstructed triceps tendon (red arrows).

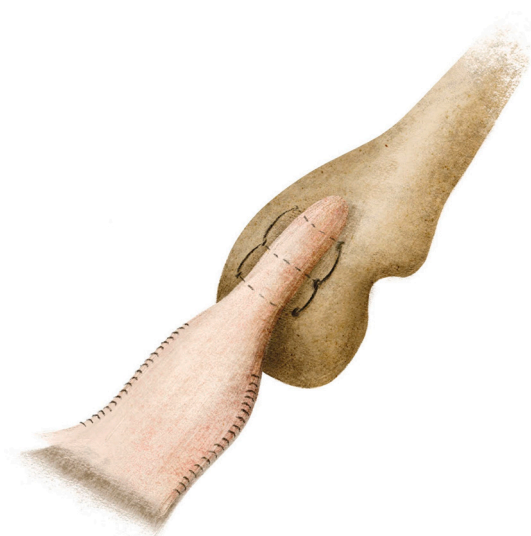


Fig. 3. Demonstration of triceps tendon reconstruction – fixation of the Achilles tendon allograft.

A tubular portion of the Achilles tendon is laid into a created osseous groove on the dorsal aspect of the olecranon and fixed with transosseous sutures. Proximally, the aponeurotic part of the Achilles tendon allograft is laid over the distally mobilized triceps tendon aponeurosis and fixed with running sutures.

Table 1

Goniometric testing.

	Uninvolved left		Involved right	
	Passive	Active	Passive	Active
Flexion	130°	125°	130°	125°
Extension	0°	0°	0°	0°
Supination	90°	85°	85°	80°
Pronation	90°	85°	90°	85°
Valgus	10°		15°	

The range of motion was measured with a universal goniometer. Active and passive range of motion for the flexion/extension movement of both elbows (injured and uninjured) were the same, ranging from full extension (0°) until 130° flexion passively and only 5° less (125°) actively. There was a minor difference between supination of the injured and uninjured elbow, with the uninjured besting the injured by 5° in active and passive motion. Both the active and the passive range of motion of pronation, 85° and 90°, respectively, were the same for both extremities. We interpret the minor differences as unlikely to produce substantial functional impairment.

Conclusion

A presented case of a 32-year-old bodybuilder, who was able to return to preinjury level of activities following a prolonged period of triceps muscle retraction due to a miss-interpreted injury severity at presentation and failed initial surgical treatment, we believe, shows us that it is important to aim for anatomical reconstruction and restoration of function in a motivated individual, even after a prolonged muscle retraction and after first undergone treatment has not yielded desired results.

Funding

No funding has been received for any part of the patient treatment, follow-up, diagnostics (MRI studies, Goniometric and Isokinetic testing) and writing of the article. Funding for the Article Processing Charge is provided by the General Hospital Slovenj Gradec Research Fund.

CRedit authorship contribution statement

Klemen Aleš Pilih: Conceptualization, Methodology, 1st operation, Writing – Original draft, Visualisation.

Mitja Kozic: Conceptualization, Methodology, 2nd operation, Writing – Review & Editing.

Table 2
Isokinetic testing.

	EXTENSION 60 °/s			FLEXION 60 °/s			EXTENSION 120 °/s			FLEXION 120 °/s		
	UNINVOL LEFT	INVOLVED RIGHT	DEFICIT	UNINVOL LEFT	INVOLVED RIGHT	DEFICIT	UNINVOL LEFT	INVOLVED RIGHT	DEFICIT	UNINVOL LEFT	INVOLVED RIGHT	DEFICIT
# OF REPS (60 °/s): 5												
# OF REPS (120 °/s): 10												
PEAK TORQUE (Nm)	77.3	70.3	9.0	83.2	95.6	-14.8	74.9	72.0	3.9	75.9	74.7	1.5
PEAK TQ/BW (%)	73.7	67.1		79.4	91.1		71.5	68.6		72.3	71.3	
MAX REP TOT WORK (J)	47.5	42.9	9.7	51.3	56.6	-10.3	43.4	39.0	10.1	44.7	41.9	6.3
COEFF. OF VAR. (%)	6.2	15.5		1.5	3.3		6.9	9.9		3.0	6.0	
AVG. POWER (W)	54.8	42.3	22.8	59.1	63.4	-7.2	80.4	73.9	8.1	79.8	84.4	-5.9
TOTAL WORK (J)	227.2	180.6	20.5	250.1	271.3	-8.5	400.3	345.0	13.8	428.3	405.3	5.4
ACCELERATION TIME (ms)	20.0	40.0		50.0	50.0		50.0	70.0		70.0	70.0	
DECELERATION TIME (ms)	190.0	220.0		220.0	180.0		180.0	180.0		210.0	170.0	
ROM (°)	40.2	39.7		40.2	39.7		40.2	39.6		40.2	39.6	
AVG PEAK TQ (Nm)	73.4	60.4		81.6	91.3		69.7	61.3		72.7	68.2	
AGONIANTAG RATIO (%)	107.7	135.9	G: 97.0				101.3	103.8	G: 93.0			

Muscle strength was assessed with isokinetic testing (System 4 Pro™, Biodex Medical Systems, Shirley, NY, USA). At 60°/s and five repetitions (reps), the maximal torque of the elbow extension was 77.3 Nm for the uninjured side and 70.3 Nm for the injured side, representing a 9 % deficit. The “real” deficit is probably a little bigger since the patient is right-hand dominant, and his right upper extremity was self-reportedly stronger before the injury. The difference between extremities is even more significant when total work or average power of the whole movement are measured. The deficit reaches the range of 20 % (22.8 % deficit with the average power generation and 20.5 % deficit with the total work generation). At 120°/s and ten reps, the trend was similar, with uninjured extremity besting the injured one in all categories. The differences were, however, less profound, indicating the explosive strength (low amplitude, low reps) was more affected than the endurance strength (high amplitude, high reps). Interestingly, the flexors of the injured elbow remained stronger even after two operative procedures and a long period of immobilization, indicating the patient must have been truly distinctly right-hand dominant. The difference was profound with explosive movement (60°/s), however, it disappeared with the endurance testing (120°/s).

The red color represents the “true” deficit of the involved extremity compared to the uninvolved extremity. The green color represents a negative deficit (superiority) of the involved extremity compared to the uninvolved extremity.

Acknowledgments

Firstly, we would like to thank a radiologist, Mitja Friedrich, MD, who has helped arrange MRI schedules, made image interpretations on short notice, was readily available for consultation, and helped arrange MR images presented in this article.

Secondly, physiotherapists Renata Vauhnik, PhD, PT, and Katarina Skaza, PT, must be acknowledged for their performance and help in the interpretation of the goniometric and isokinetic measurements.

Thirdly, great regard for Jernej Myint, an illustrator, for a swift and generous contribution of his artwork to improve the clarity of this article (Fig. 3).

Fourthly, a special thanks to the first author's mentor, Matej Jezernik, MD, is deserved. He offered consulting and support during treatment planning and even after the first treatment had failed.

Finally, the first author of this article would like to thank the patient, David Mesner, who has shown incredible motivation and understanding through the ups and downs of the treatment course. It is rare to see a patient preserving trust in his chosen physician even after initial treatment failure.

References

- [1] S. Anzel, K. Covey, A. Weiner, et al., Disruption of muscles and tendons; an analysis of 1,014 cases, *Surgery* 45 (1959) 406–414.
- [2] J. Tom, N. Kumar, D. Cerynik, R. Mashru, M. Parrella, Diagnosis and treatment of triceps tendon injuries, *Clin. J. Sport Med.* 24 (3) (2014) 197–204, <https://doi.org/10.1097/jsm.0000000000000010>.
- [3] M. Demirhan, A. Ersen, Distal triceps ruptures, *EFORT Open Rev.* 1 (6) (2016) 255–259, <https://doi.org/10.1302/2058-5241.1.000038>.
- [4] J. Dunn, N. Kusnezov, A. Fares, et al., Triceps tendon ruptures: a systematic review, *Hand* 12 (5) (2016) 431–438, <https://doi.org/10.1177/1558944716677338>.
- [5] R. Heikenfeld, R. Listringhaus, G. Godolias, Endoscopic repair of tears of the superficial layer of the distal triceps tendon, *Arthroscopy* 30 (7) (2014) 785–789, <https://doi.org/10.1016/j.arthro.2014.03.005>.
- [6] S. Mair, W. Isbell, T. Gill, T. Schlegel, R. Hawkins, Triceps tendon ruptures in professional football players, *Am. J. Sports Med.* 32 (2) (2004) 431–434, <https://doi.org/10.1177/0095399703258707>.
- [7] G. Balazs, A. Brelin, T. Dworak, D. Brooks, T. Mauntel, S. Tintle, J. Dickens, Outcomes and complications of triceps tendon repair following acute rupture in American military personnel, *Injury* 47 (10) (2016) 2247–2251, <https://doi.org/10.1016/j.injury.2016.07.061>.
- [8] B. Morrey, in: *Master Techniques in Orthopaedic Surgery: The Elbow*, 3rd ed., Wolters Kluwer, Philadelphia, 2015, pp. 301–314. Ch. 23.
- [9] W. Martins, J. Blasczyk, S. Soares, W. de Paula, M. Bottaro, P. Gentil, A novel approach for rehabilitation of a triceps tendon rupture: a case report, *Phys. Ther. Sport* 32 (2018) 194–199, <https://doi.org/10.1016/j.ptsp.2018.05.016>.
- [10] J. Paci, J. Clark, A. Rizzi, Distal triceps knotless anatomic footprint repair: a new technique, *Arthrosc. Tech.* 3 (5) (2014) e621–e626, <https://doi.org/10.1016/j.eats.2014.06.019>.