



ELSEVIER

Contents lists available at ScienceDirect

# Medical Mycology Case Reports

journal homepage: [www.elsevier.com/locate/mmcr](http://www.elsevier.com/locate/mmcr)

## First imported coccidioidomycosis in Turkey: A potential health risk for laboratory workers outside endemic areas <sup>☆</sup>



A. Serda Kantarcioglu <sup>a,\*</sup>, M. Sandoval-Denis <sup>b</sup>, Gokhan Aygun <sup>a</sup>, Nuri Kiraz <sup>a</sup>, Canan Akman <sup>c</sup>, Hulya Apaydin <sup>d</sup>, Emin Karaman <sup>e</sup>, Josep Guarro <sup>b</sup>, G. Sybren de Hoog <sup>f</sup>, M.S. Gurel <sup>g</sup>

<sup>a</sup> Cerrahpasa Medical Faculty, Department of Medical Microbiology, Deep Mycosis Laboratory, Istanbul University, Istanbul 34098, Turkey

<sup>b</sup> Unitat de Microbiologia, Facultat de Medicina i Ciències de la Salut, IISPV, Universitat Rovira i Virgili, 43201 Reus, Spain

<sup>c</sup> Cerrahpasa Medical Faculty, Department of Radiology, Istanbul University, Istanbul 34098, Turkey

<sup>d</sup> Cerrahpasa Medical Faculty, Department of Neurology, Istanbul University, Istanbul 34098, Turkey

<sup>e</sup> Cerrahpasa Medical Faculty, Department of Otorhinolaryngology, Istanbul University, Istanbul 34098, Turkey

<sup>f</sup> CBS-KNAW Fungal Biodiversity Centre, Utrecht, The Netherlands

<sup>g</sup> Department of Dermatology, Samatya Training and Research Hospital, Istanbul 34098, Turkey

### ARTICLE INFO

#### Article history:

Received 3 November 2013

Received in revised form

19 December 2013

Accepted 10 January 2014

#### Keywords:

*Coccidioides*

Coccidioidomycosis

Non-endemic countries

Laboratory safety

### ABSTRACT

Coccidioidomycosis caused by *Coccidioides immitis* or *Coccidioides posadasii* is endemic in arid climate zones in America, travel-related cases have been reported. We report the first documented case of coccidioidomycosis in Turkey, overviewing reported cases in Europe and underlying difficulties of differential diagnosis outside endemic regions. The patient was an otherwise healthy 41-year-old man who travelled endemic areas. Laboratory diagnosis was based on direct microscopy of two subsequent subcutaneous biopsy specimens and culture and confirmed molecularly. Laboratory personnel should become aware that BioSafety Level-3 organisms may become more frequent and widespread.

© 2014 International Society for Human and Animal Mycology. International Society for Human and Animal Mycology. Published by Elsevier B.V. All rights reserved.

## 1. Introduction

Coccidioidomycosis is an endemic disease of arid and semi-arid regions of northern and southern America caused by *Coccidioides posadasii* and *Coccidioides immitis*, which can only be separated by DNA sequencing. Travellers to endemic areas are at risk of developing coccidioidomycoses through inhalation of airborne conidia. A history of travel to endemic areas as well as a high index of suspicion is imperative for timely and accurate diagnosis [1]. In order to differentiate this infection from other systemic mycoses, diagnostic spherules should be observed in clinical samples, and/or typical barrel shaped arthroconidia in culture. The present case is the first report of proven, imported coccidioidomycosis in Turkey. Unfamiliarity with the disease might present a severe biohazard to laboratory personnel.

## 2. Case

On June 2011, a 41-year-old, otherwise healthy, Turkish man travelled to Texas for 2 months where he spent his spare time in walking through the forests, and then took 1 month trip by car to Grand Canyon, Las Vegas and San Francisco during which he fasted in accordance with Ramadan, but felt unusually weak and lost weight. On his 80th day in the USA, he felt very ill near Niagara Falls and laid down on the grass, suffered from chest pain and severe sweating. Ten days later, he was admitted to an hospital in Texas with coughing, fever, vomiting and loss of appetite (day 0). He was diagnosed with pneumonia and given 400 mg/day moxifloxacin. The next day he returned to Batman, Turkey and attended University Hospital with nausea, vomiting, weakness, sweating, productive coughing and fever (day +1). Serologic assays for IgM levels of CMV, Herpes type II, Rubella, Parvovirus B19, and EBV EBNA were all negative. CRP was 30.7 mg/L and increased to 42.5 mg/L (day +4). Sputum, throat, urine cultures and haemoculture as well as stains for acid-fast bacteria and mycobacterial cultures were also negative while moxifloxacin was continued. Chest X-rays were normal but chest CT scan revealed a 18 mm nodule on the left upper lobe with suspected histoplasmosis. Bronchoscopy showed white mucosal nodularity and a biopsy was performed. Fungal cultures of the biopsy specimen were

<sup>☆</sup>This is an open-access article distributed under the terms of the Creative Commons Attribution-NonCommercial-No Derivative Works License, which permits non-commercial use, distribution, and reproduction in any medium, provided the original author and source are credited.

\* Corresponding author.

negative. A blood sample gave negative result for *Histoplasma* DNA identification by PCR. Abdominal ultrasound and a cranial CT scan were normal. Due to persistent fever up to 40 °C and night sweat, patient was switched to imipenem and clarithromycin. He refused pulmonary biopsy and left hospital (day +11). Following the development of a cutaneous lesion of about 1 cm diameter on his neck (day +38), he attended University Hospital in Ankara and was hospitalised. CRP level was 15.8 mg/L and increased to 22.5 mg/L (day +42). Routine clinical laboratory data were unremarkable. Cytology and stains for acid-fast bacteria, as well as fungal and mycobacterial microscopy and cultures of two subsequent bronchoalveolar lavage (BAL) samples and a lymph node biopsy specimen were all negative. For his neck lesion, amoxicillin-clavulanic acid, 1000 mg, t.i.d. and a topical fusidic acid cream were started and then he was discharged (day +46).

He attended Batman State hospital with severe chest pain, lack of appetite, the persistent lesion on the neck and an additional small papule in the left palm (day +47). An abdominal CT scan revealed ascites, and the cytology of aspirated peritoneal fluid showed numerous lymphocytes, neutrophils, eosinophils and histiocytes.

He was admitted to another hospital and a chest CT scan revealed a nodule of about 18 mm on the left upper lobe and oedema (day +54). Pathological examination of a punch biopsy of his neck lesion revealed pseudoepitheliomatous hyperplasia-like verrucose proliferation and neutrophils in the epidermis. A dense infiltrate of neutrophils, lymphocytes, plasma cells, histiocytes and eosinophils invading epithelia were present in the dermis. Langerhans-like multi-nuclear giant cells and granuloma formations were also observed. PAS-positive, round, thick-walled fungal elements were observed in the cytoplasm of the giant cells in neutrophilic abscesses. North American blastomycosis was suspected. Stains for acid-fast bacteria and mycobacterial cultures were negative. Histopathological preparations sent for consultation were reported as being fungal dermatitis. Itraconazole (ITZ) 100 mg b.i.d. was prescribed for 6 months.

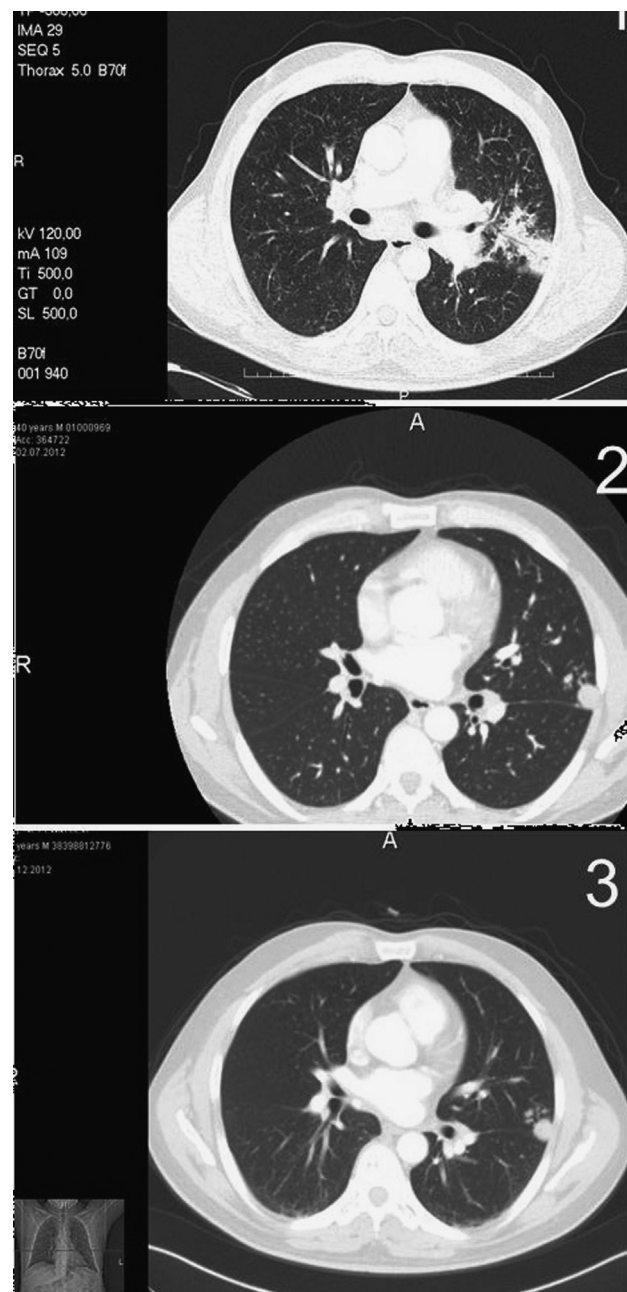
When he was admitted to a university hospital in Ankara (day +164), CRP level was 1.74 mg/L. A chest CT scan revealed additional lymph nodes with an infectious appearance in the left lung. Parenchymal lesions were smaller than they were on the day +4. No ascites was detected on abdominal CT scan. He was free of pain. ITZ treatment was continued. A chest CT scan made in Batman (day +308) showed micronodules in the left lung and left hilar lymphadenopathy of a “tree-in-bud” appearance with some regression when compared with the CT scans of day +2. His palm lesion was healed but lung lesions were sustained after having been treated with ITZ 200 mg/day for 6 months. On follow-up visit (day +363), because of his persisted neck lesion despite ITZ treatment, the patient was transferred to a Research Hospital in Istanbul for further evaluation for suspected blastomycosis and its treatment with amphotericin B (AMB).

When he admitted to the dermatology department (day +368), he was conscious, cooperative and oriented with normal physical examination. He had an erythematous, slightly elevated atrophic lesion on his neck of about 4.3 cm and brightly coloured peripheric minor papules. Serology for HBsAg, Anti HBs, Anti HCV and Anti-HIV were all negative. Neck ultrasonography revealed several lymph nodes having a reactive appearance, smaller than 12 mm in diameter. Abdominal magnetic resonance imaging (MRI), cranial CT scans and a whole body bone scintigram were normal (day +373). Pulmonary radiological scans were thought compatible with blastomycosis.

Two subsequent punch biopsies of 5 mm were carried out (days +368 and +379) and sent to Cerrahpasa Medical Faculty (CMF), Deep Mycoses Laboratory (DML), with clinical suspicion of North American blastomycosis and the patient was discharged at his own request. Previous histopathological sections were requested from the laboratory for mycological re-examination.

*Coccidioides* sp. was identified by microscopy and two subsequent biopsy samples were cultured. Treatment was continued with ITZ 200 mg/day for 3 months.

When the patient was seen on day+465, his neck lesion was healed and his physical examination and routine clinical laboratory data were unremarkable. On the chest CT scan parenchymal miliary lesions were resolved, lesions defined on the left lung and mediastinal windows showed no significant differences with those of the previous years, but there was a significant reduction of the diameter of the left axillary and mediastinal lymph nodes. Nodularity consolidation documented on the left lung altered to granuloma-like configuration (Fig. 1). A nasal endoscopy was carried out. A previous sinoorbital MRI was reviewed but revealed no abnormality except



**Fig. 1.** Chest images. (1) MRI on September 2011 showing pneumonic infiltration and nodular appearance also suggestive for fungal infection in the middle lobe. (2) MRI on July 2012 showing micronodules in the left lung and left hilar lymphadenopathy of “tree-in-bud” appearance. (3) CT image on December 2012, there was no significant differences with that of July 2012 and was interpreted as a sequela.



right concha hypertrophy and deviation of nasal septum. Neurological examination was normal. Previous MRIs of the brain were re-examined. A T2-weighted MRI of the brain showed a few small gliotic foci on the basal surface of the frontal lobe as well as tubinate hypertrophy of the nasal mucosa that blocked the nasal passage. A lumbar puncture revealed normal opening pressure with normal biochemistry. A cerebrospinal fluid (CSF) sample was sent to the Deep Mycoses Laboratory. CSF direct microscopy and cultures of the CSF samples were negative. Based on radioscopic data, antifungal treatment was continued and a 3-month follow-up appointment scheduled.

When seen on day +564, physical examination and routine laboratory data were normal. Antifungal therapy was stopped. He is now free of symptoms. Authors speculate that the presence of turbinate hypertrophy of the nasal mucosa facilitated the incubation of the pathogen.

### 2.1. Materials and methods

Two subsequent biopsy specimens from neck nodules were submitted to CMF, DML for mycological evaluation (days +368 and +379), with a clinical suspicion of North American blastomycosis. Direct microscopical examination was carried out using Gram, Ehrlich Ziehl Nielsen, Giemsa, and methylene blue stained slide preparations of the imprinted tissue samples. Specimens were inoculated by embedding onto Sabouraud dextrose agar (SDA), chocolate agar with sheep blood (5%) plates as primary culture media and incubated at 30° C and 37° C. Microscopic morphology of the isolate was examined by staining with lactophenol cotton blue. PAS stained histopathological preparations from day +54 were also requested and examined for microorganisms. Phenotypical identification was made using classical mycological techniques.

The isolate was identified by sequencing of the internal transcribed spacers (ITS) 1 and 2, and 5.8S domains of rDNA. They were compared with the sequences of type and reference strains deposited in GenBank.

*In vitro* susceptibility of the isolate against AMB, ITZ, fluconazole (FLZ), voriconazole (VRZ) and posaconazole (PSZ) was examined using MIC Test Strip (Liofilchem s.r.l., Italy). Tests were carried out according to the manufacturer's instructions.

### 2.2. Results

Direct microscopical examination of Giemsa stained imprinted tissue slides of biopsy materials revealed the presence of a few, thick-walled, round fungal cells, some with a granular protoplasm (Fig. 2), small chains of oval to round cells and a few sporangium-

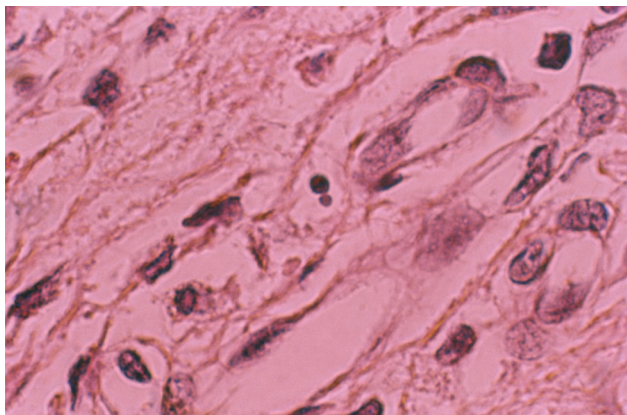


Fig. 2. Thick walled budding cells with a granular protoplasm and a thin long neck seen in Giemsa stained preparations (100 ×).

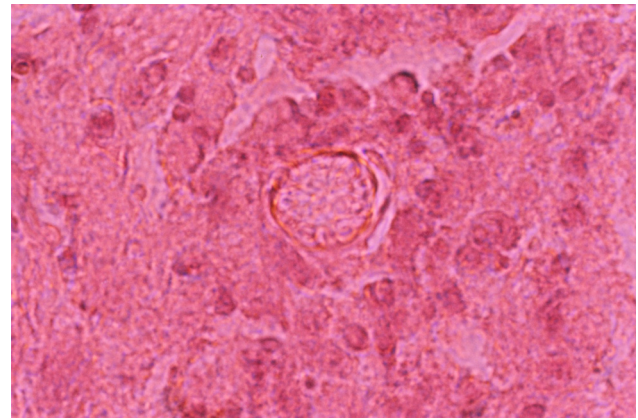


Fig. 3. Thick-walled, round morphology full of endospores seen in Giemsa stained preparations (100 ×).

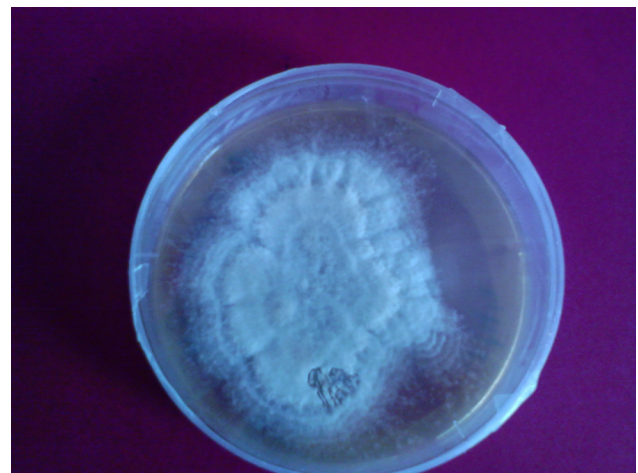

Fig. 4. Mature colony morphology on Sabouraud dextrose agar plate.

like, large, thick walled, round, dense or empty cells of between 20 and 40 μm in size (Fig. 3), with double-contoured wall. Histopathological sections of the tissue biopsy carried out on day +54 were sent for mycological re-examination and the organism appeared in tissue in double-encapsulated, empty spherical form.

After 4–5 days incubation, cultures on SDA at 30° C and 37° C initially grew glabrous colonies just around the tissue biopsy specimens. Fungal morphology seen directly in patient material and glabrous colonial characteristics of the early culture raised the possibility of the presence of a *Prototheca* sp, compatible with his rest near a waterfall. However, after 2–3 weeks of incubation the colonies were white, floccose, with a tan reverse. The same fungus was isolated as pure culture from all the tissue samples. Microscopic examination of lactophenol cotton blue stained slide preparations made at the early mould phase revealed smooth, hyaline, septate, sterile hyphal structures with some spirals similar to those of dermatophytes. When colonies had matured, for about 2–3 weeks (Fig. 4), barrel-shaped arthroconidia were observed. Fungal morphology allowed the tentative identification of the fungus as *Coccidioides* sp. Subcultures were submitted to JG at Reus for molecular confirmation and the strain was identified as *C. immitis* by sequencing the rDNA ITS region showing a 99% sequence similarity with the reference strains CBS 113852, CBS 113856 and CBS 113857 (accession numbers EF186788, EF186789 and EF186790, respectively). The sequence generated was deposited in GenBank under the accession number HG380500. The

isolate is stored in the collection of University of the Centraal bureau voor Schimmelcultures, Utrecht, The Netherlands, at CBS 136242 (FMR 12608).

MICs ( $\mu\text{g/ml}$ ) were 32 for AMB,  $> 256$  for FLZ,  $> 32$  for ITZ, 0.64 for VRZ, 0.047 for PSZ.

### 2.3. Exposure by laboratory staff and environmental controls

Regarding the results of direct microscopical examination of tissue preparations stained by PAS and Giemsa methods and early glabrous colony morphology, prothothecosis, chlorellosis, coccidioidomycosis or skin dermatophytosis were all initially suspected. Culture slides were prepared twice, once at the early mould growth phase and again at maturity. Early preparations revealed only thin, hyaline, septate hyphae without conidia, resembling dermatophyte hyphae but mature colonies revealed the presence of typical barrel-shaped arthroconidia. All patient's cultures were immediately destroyed by autoclaving them together with biological indicators, then placing them in boxes set aside for biohazardous waste. Environmental controls were carried out periodically in both the mycology laboratory and inside the incubators. Petri dishes containing SDA were opened for 3 h and then incubated at  $30^\circ\text{C}$  and  $37^\circ\text{C}$ . The same fungus grew in cultures, which were autoclaved immediately. All surfaces in the laboratory were disinfected using sodiohypochlorite (10%) and the cleaning staff wore N95 respirators, disposable protective laboratory coatings, gloves and hair covers. Air was decontaminated with pulverising hydrogen peroxide ( $15\text{ ml/m}^3$ ), allowing overnight contact. The DML was kept closed, signs were posted to alert personnel that this may be a contaminated area that should not be entered and work was transferred to another room. The Infectious Disease Committee of CMF was officially informed immediately. Environmental controls and decontamination using hydrogen peroxide were carried out four more times. Air sampling and cultures are still currently being continued as a precaution despite culture results having been negative on the third test. Serum samples of personnel were taken and stored. Nasopharyngeal and sputum samples of laboratory staff were cultured. Antifungal prophylaxis with ITZ was given at a therapeutic dose to laboratory workers for 3 months and sinonasal and chest MRIs were taken at the end of the prophylaxis, which showed no abnormalities.

### 3. Discussion

Although travel history is important in diagnosing endemic mycosis particularly in non endemic countries, it is not always easy. In the present case, the patient was first diagnosed as North American blastomycosis in several separate hospitals based on his travel story and clinical findings despite negative culture, during nearly 1 year course.

Diagnosis of coccidioidomycosis is usually determined based on the presence of endospores however microscopical findings are not always typical. Environmental algae *Prototheca* and *Chlorella* spp. can be isolated from grass, soil and water and malnutrition is listed among risk factors of algae infection as was in this patient. The two subsequent biopsy specimens revealed randomly distributed atypical thick-walled large yeast-like cells that were not indicative of either *Coccidioides* sp. or an algae infection. Multi-nucleated endosporulating sporangium-like, small, immature spherules seen in Giemsa and PAS stained tissue preparations, double-encapsulated, empty spherical form seen in histopathological sections and initially glabrous colony morphology on SDA lead us to suspect both algal infection and coccidioidomycosis. Misleading and unusual immature forms of *C. immitis* have previously been reported *in vivo* [2–5]. Undiagnostic, thin,

hyaline hyphae seen in preparations of this glabrous colony pointed to a possible dermatophyte isolation, albeit from two separate biopsy specimens. Although single-celled, barrel-shaped arthroconidia were expected to occur in 4–7 days on SDA at  $25^\circ\text{C}$ , the late maturation of the isolates might probably be due to the partial inhibition of the patient's long-term antifungal treatment before biopsy specimens were obtained and submitted to DML.

A positive serological test may have diagnostic value for acute coccidioidomycosis in patients from nonendemic countries, particularly in relation with a travel history, but negative tests should not be used to rule out the disease, and serological tests for *C. immitis* are uncommon in Europe and Turkey. Karasu and Sirman [6] carried out serological tests using coccidioidin antigen in 1953. They applied both histoplasmin and coccidioidin to 66 patients with pulmonary lesions and 11 of them were positive for both antigens and two of them positive for coccidioidin.

Today's changes in travelling behaviour may increasingly cause people to encounter infections with organisms that are uncommon in their own countries. Because of the low incidence of coccidioidomycosis on Europe, diagnosis of the disease is not well known in practice. We found 19 cases of coccidioidomycosis imported into Europe as outlined in Table 1 [7–25]. In the data given by the European Confederation of Medical Mycology (ECMM) Working Group of the Survey of Coccidioidomycosis in Europe, 36 cases were reported from nine countries but limited or no data were provided (<http://www.ecmm.eu/node/193>). The first report in Turkey [26] found spherule-like forms in skin biopsy specimens of facial erythematous papulo-pustular lesions presented by a 53-year-old woman gardener. Arthroconidia were seen in cultures of skin biopsy and blood. The strain was inoculated to mice and spherules were observed in visceral organs, although the isolate was not submitted to a reference centre for confirmation. Austen et al. [27] reported a patient from The Netherlands who travelled to California in 2008. Two weeks after her visit, she travelled to Turkey, where she was admitted to an intensive care unit with severe "community-acquired pneumonia", but no pathogen was identified. The authors presume that this was probably a primary infection by coccidioidomycosis. We report the first coccidioidomycosis case, proven by culturing, in Turkey.

Approximately 40% of infected people are asymptomatic or develop flu-like symptoms. In rare instances, individuals develop severe lung disease (e.g., cavitary pneumonia) and in  $< 1\%$  of infected people the fungus disseminates to the central nervous system, joints, bones and skin [1]. Although our patient was an otherwise healthy, relatively young, returned home soon with severe symptoms and developed disseminated infection with a skin lesion on his neck and one in palm.

The literature on antifungal susceptibility testing of *Coccidioides* spp. is rather limited. In review of previous susceptibility studies of *Coccidioides* spp. MIC ranges ( $\mu\text{g/ml}$ ) were reported as 0.06–2 for AMB, 0.03–1.0 for ITZ, 2.0–64.0 for FLZ,  $< 0.06$ –1 for VRZ and PSZ [28]. Although the fungus appeared *in vitro* to be highly susceptible to most antifungal agents, the treatments for chronic and disseminated coccidioidomycosis can be prolonged and often complicated and only 50–60% of patients are responsive to treatment with ITZ and FLZ [29]. In this case the fungus was isolated from biopsy samples obtained on day +310 of ITZ treatment and showed high MIC values both for FLZ ( $> 256$ ) and ITZ ( $> 32$ ). Since no defined susceptibility breakpoints exist for both FLZ and ITZ activity against *Coccidioides* spp., and comparable MIC values of the wild type isolate were not available, and the patient's response to ITZ gradually decreased, facing such a high MIC value may suggest possible acquired resistance to both azoles occurred during long term therapy. Voriconazole and PSZ which were apparently more

**Table 1**  
Imported European cases proven by direct microscopy and/or culture (n=20).

Reference	Patient characteristics						
	Age/sex/nationality	Underlying disease	Risk factor/travel to	Site of infection/other locations	Specimens/identification methods	Antifungal therapy	Outcome
Kantarcioglu	41/M/Turkish	Otherwise healthy	Texas	Pulmonary nodules/skin	Biopsy	ITZ (200 mg/day)	Asymptomatic
Austen et al. [27]	77/F/NL	Otherwise healthy	California (2008)	Total knee arthroplasty	Aspirate of the knee	FLZ (400 mg/day, life long)	The initial complaints of pain and swelling were completely resolved
Gobbi et al. [8]	28/M/Italian	Otherwise healthy	Arizona	Pulmonary nodules	BAL/Gram staining; serum/anti-coccidioidin antibodies	ITZ (200 mg b.i.d., 6 months)	Complete clinical recovery, negative radiological results
Lacassagne et al. [10]	57/F/French	Otherwise healthy	Arizona	A solitary pulmonary nodule	Surgical resection material	NM	Asymptomatic and well (1 year later)
Brugiere [11]	58/M/French	Lung transplant recipient		NM	NM	NM	NM
Indhirajhanti et al. [12]	35/M/NL	Otherwise healthy	California	NM	BAL/culture and serology	ITZ (Continued)	Gradually improved
Buijze et al. [13]	58/M/Asian	Otherwise healthy	California	Pulmonary abscess	Lymph node biopsy	FLZ (400 mg/day), lack of therapeutic response, changed into KTZ (400 mg once daily)	Stabilized
Goegebuer et al. [14]	34/M/Belgium	Otherwise healthy		Pulmonary nodule, lymph	Tissue from wedge resection	No specific therapy was initiated	Good general condition
Hombach et al. [15]	61/M/Swiss	Otherwise healthy	Arizona	Pulmonary nodule	Tissue/culture	NM	NM
Chandesris et al. [16]	63/F/Vietnamien living in France	Otherwise healthy	Los Angeles	Pulmonary abscess with a cavity	BAL/culture	NM	NM
Pistone et al. [17]	46/M/Colombian immigrant	HIV+, mucocutaneous Kaposi's sarkoma, candidiasis, histoplasmosis,	Archaeologist/Mexico and Caribbean	Pulmonary abscess	BAL/culture	ITZ (600 mg/day, 2 months)	Lost to follow up
Petrini et al. [18]	65/F/Swedish	Otherwise healthy	Arizona (8 months ago)	Pulmonary nodules	Tissue/Grocotte-Gomori silver stain	NM	NM
Holemans et al. [22]	47/F/Swiss	NM	Mexico	Probable lung localisation	Serology	NM	NM
Fohlman et al. [19]	68/M/Swedish citizen	Previously healthy	Arizona (3 years ago)	Pulmonary abscess	Culture, serology	No antifungal therapy was given	Returned to US?
Zalatnai et al. [20]	61/M/US citizen	Otherwise healthy	Arizona (2 years ago)	Multiple pulmonary abscesses	Biopsy culture, serology	KTZ (400 mg/day, 4 months)	symptomless
Hernandez et al. [21]	39/M/Spanish	HIV+, iv drug user	Arizona, Nevada, California (12 years ago)	Several enlarged lymph nodes in the left cervical and supraclavicular regions, radiographs of the chest were normal	Microscopy and culture of cervical lymph node biopsy	FLZ (400 mg, twice daily for 1 month, reduced to 400 mg/day for 4 months, 200 mg/day as secondary prophylaxis)	Felt well (9 months later)
Papadopoulos et al. [24]	43/M/Sweden	Immunocompetent	No travel history	Adrenal	NM	NM	NM
Libow et al. [23]	25/M/USA	Black, soldier	NM	Chest wall abscess	Microscopy of abscess drainage	NM	NM
Alanko et al. [25]	-/-/Finland	NM	NM	Pulmonary	Clinical, radiology and serology (positive coccidioidin test)	AMB	Recovered
	-/F/Finland	Pregnant	Arizona	Pulmonary cavitation	Culture of sputum and resected specimen	Cavity resection, abortion, pre- and post-operative AMB	Completely recovered

Abbreviations: AMB—amphotericin B; FLZ—fluconazole; ITZ—itraconazole; KTZ—ketoconazole; P—pulmonary involvement; NM—not mentioned.

active azoles *in vitro* were reported as options for salvage treatment of refractory coccidioidomycosis in patients who were unresponsive to the first line antifungal agents [30,31]. When

seen on day +564, the patient's physical examination and routine laboratory data were normal. Antifungal therapy was stopped. Actually, the patient is free of symptoms.



All laboratory staff had to have an antifungal prophylaxis for 3 months against the risk of presence of mature disarticulated conidia in the air, although the benefits of such a prophylactic approach have not been proven. Early treatment of experimental coccidioid infection in animal models clearly facilitates a favourable outcome [1,32].

Laboratory-associated coccidioidomycosis is a documented hazard of working with sporulating cultures of *Coccidioides* spp. [33–35]. Attack rates for laboratory exposure is higher than for ambient exposure when large numbers of conidia are inhaled [34]. Risk of respiratory infection from exposure to infected tissue or aerosols of infected secretions is low. Therefore, Biosafety Level 3 practices, containment equipment, and facilities were recommended for manipulating sporulating cultures of *Coccidioides* to avoid inhalation of infectious arthroconidia from cultures of the mould form [35].

In conclusion, with increase in international travels, coccidioidomycosis is now emerging as an important infection outside its previously known endemic areas. In non-endemic countries, in spite of the patient's prior travel history, coccidioidomycosis may not be easy to diagnose if there has been previous empirical antifungal treatment and/or atypical strain morphology. Laboratory personnel may be at risk of exposure to fungal cells while working with unexpected fungi during incubation and identification. Furthermore, the lack of appropriate Biosafety Level 3 conditions in laboratories in European countries is a significant risk factor for exposure to *Coccidioides*.

#### Conflict of interest

There are none.

#### References

- [1] Panackal AA, Hajjeh RA, Cetron MS, Warnock DW. Fungal infections among returning travellers. *Clin Infect Dis* 2002;35:1088–94.
- [2] Lee CH, Wilcox L, Chorneyko K, McIvor A. *Coccidioides immitis*: two cases of misidentified mycosis. *Can Respir J* 2008;15:377–9.
- [3] Ke Y, Smith CW, Salaru G, Joho KL, Deen MF. Unusual forms of immature sporulating *Coccidioides immitis* diagnosed by fine-needle aspiration biopsy. *Arch Pathol Lab Med* 2006;97–100:130 2006:97–100.
- [4] Munoz B, Castanon LR, Calderon I, Vazquez ME, Manjarrez ME. Parasitic mycelial forms of *Coccidioides* species in Mexican patients. *J Clin Microbiol* 2004;42:1247–9.
- [5] Kaufman L, Valero G, Padhye AA. Misleading manifestations of *Coccidioides immitis* in vivo. *J Clin Microbiol* 1998;36:3721–3.
- [6] Karasu N, Sirman AA. Ankara'da histoplasmin ve coccidioidin deri testleri ile yapılan arařtırmalar. *Tüberk Toraks* 1953;1:3–14.
- [7] Austen S, van der Weegen W, Verduin CM, van der Valk CM, Hoekstra HJ. Coccidioidomycosis infection of a total knee arthroplasty in a nonendemic region. *J Arthroplasty* 2013;28(375):375.e13–5.
- [8] Gobbi F, Angheben A, Farina C, et al. Coccidioidomycosis: first imported case in Italy. *J Travel Med* 2012;19:192–4.
- [9] Buitrago MJ, Cuenca-Estrella M. Current epidemiology and laboratory diagnosis of endemic mycoses in Spain. *Enferm Infecc Microbiol Clin* 2012;30:407–13.
- [10] Lacassagne L, Fajadet P, Carné JM, et al. Coccidioidomycosis presenting as a pulmonary nodule after pneumonia. *Rev Mal Respir* 2011;28:1162–6.
- [11] Brugiére O. Coccidioidomycosis in a lung transplant recipient acquired from the donor graft in France. *Transplant* 2009;88:1319–20.
- [12] Indhirajanti S, Maartens E, Posthuma EFM, Pannekoek BJM, Vreede RV. Pulmonary coccidioidomycosis: import illness and the importance of travel history. *J Med* 2009;67:353–5.
- [13] Buijze GA, Kok P, Botha-Scheepers SA, Smith SJ, Sleeboom H. Fungal disease of the Western hemisphere: a patient with coccidioidomycosis. *Eur J Int Med* 2009;20:319–22.
- [14] Goegebuier T, Nackaerts K, Himpe U, Verbeken E, Lagrou K. Coccidioidomycosis: an unexpected diagnosis in a patient with persistent cough. *Acta Clin Belg* 2009;64:235–8.
- [15] Hombach M, Stulz P, Arnold W, Pfyffer GE. Pulmonary *Coccidioides* nodule in a patient with chronic lymphoid leukemia. *J Med Microbiol* 2008;57:1427–30.
- [16] Chandresis MO, Hot A, Dannaoui E, et al. Une maladie d'importation. *Med Mal Infect* 2008;38:291–2.
- [17] Pistone T, Lacombe K, Poirot JL, Girard PM, Meynard JL. Imported concomitant coccidioidomycosis and histoplasmosis in an HIV-infected Colombian migrant in France. *Trans R Soc Trop Med Hyg* 2005;99:712–5.
- [18] Petrini B, Sköld CM, Bronner U, Elmberger G. Coccidioidomycosis mimicking lung cancer. *Respiration* 2003;70:651–4.
- [19] Fohlman J, Sjölin J, Bennich H, Chryssanthou E, von Rosen M, Petrini B. Coccidioidomycosis as imported atypical pneumonia in Sweden. *Scand J Infect* 2000;32:440–1.
- [20] Zalattnai A, Zala J, Sandor G. Coccidioidomycosis in Hungary. *Pathol Oncol Res* 1998;4:147–50.
- [21] Hernandez JL, Echevarria S, Garcia-Valtuille A, Mazorra F, Salesa R. Atypical coccidioidomycosis in an AIDS patient successfully treated with fluconazole. *Eur J Clin Microbiol Infect Dis* 1997;16:592–4.
- [22] Holemans X, Leveque P, Despontin K, Maton JP. First reported coccidioidomycosis associated with Sweet syndrome. *Presse Med* 2000;29:1282–4.
- [23] Libow LF, Lum GH, Jackson JL, Zaenglein J. Disseminated coccidioidomycosis in an American soldier in Europe. *J Eur Acad Dermatol* 1995;5:36–40.
- [24] Papadopoulos KI, Castor B, Klingspor L, Dejmek A, Loren I, Brannert M. Bilateral isolated coccidioidomycosis. *J Intern Med* 1996;239:275–8.
- [25] Alanko K, Khanpaa A, Patiala J. The first two cases of coccidioidomycosis in Finland. *Acta Med Scand* 1975;198:235–40.
- [26] Aktan G, Çoğlu S, Baransu O, Büget E. *Coccidioides immitis* in Türkiye'de ilk izolasyonu. *KÜKEM Derg* 1985;1:61.
- [27] Austen S, van der Weegen W, Verduin CM, van der Valk CM, Hoekstra HJ. Coccidioidomycosis infection of a total knee arthroplasty in a nonendemic region. *J Arthroplasty* 2013;28:375.e13–5.
- [28] Ramani R, Chaturverdi V. Antifungal susceptibility profiles of *Coccidioides immitis* and *Coccidioides posadasii* from endemic and non-endemic areas. *Mycopathologia* 2007;163:315–9.
- [29] Galgiani JN, Ampel NM, Blair JL, et al. Coccidioidomycosis. *Clin Infect Dis* 2005;41:1217–23.
- [30] Stevens DA, Clemons KV, Levine HB, et al. Expert opinion: what to do when there is *Coccidioides* exposure in a laboratory. *Clin Infect Dis* 2009;49:919–23.
- [31] Kim MM, Vikram HR, Kusne S, Seville MT, Blair JE. Treatment of refractory coccidioidomycosis with voriconazole and posaconazole. *Clin Infect Dis* 2011;53:1060–6.
- [32] Pappagiannis D. Coccidioidomycosis (San Joaquin or Valley Fever). In: di Salvo A, editor. *Occupational mycoses*. Lea and Fabinger; Philadelphia; 1983. p. 13–28.
- [33] Nabarro JDN. Primary pulmonary coccidioidomycosis. Case of laboratory infection in England. *Lancet* 1948;1:982–4.
- [34] Smith CE. The hazard of acquiring mycotic infections in the laboratory. In: *Proceedings of the 78th annual meeting of American Public Health Association*. St. Luis, MO; 1950.
- [35] *Biosafety in Microbiological and Biomedical Laboratories*. 5th Ed. US Washington: Department of Health and Human Services Public Health Service Center for Disease Control and Prevention and National Institute of Health; 2009. p. 171–2.