

# Radical modular pancreatoduodenectomy for pancreatic head cancer using a combination of multiple artery-first approaches technique

Kai-Ming Leng, MD, PhD, Xiang-Yu Zhong, MD, PhD, Sheng Tai, MD, PhD, Peng-Cheng Kang, MD, PhD, Ming Wan, MD, PhD, Xing-Ming Jiang, MD, PhD, Hao Wang, MD, PhD, Yi Xu, MD, PhD, Zhi-Dong Wang, MD, PhD\*, Yun-Fu Cui, MD, PhD\*

## Abstract

The aim of this study was to describe and assess the efficacy of a combination of multiple artery-first approaches (CMAFA) in pancreatoduodenectomy (PD) depending on the tumor location from an embryonic point of view.

Between January 2011 and December 2016, seventy-nine consecutive patients with pancreatic head cancer (PHC) underwent PD with curative intent. Patients were classified into two groups according to the surgical procedure: CMAFA-PD group (n=38) and conventional PD (Co-PD) group (n=41). Clinicopathological variables and clinical outcomes were compared among the two groups.

The CMAFA technique demonstrated an improved rate of R0 resection (89.5% vs. 70.7%,  $P=.038$ ) and a higher median lymph node yield (24 vs. 20,  $P=.034$ ). The CMAFA-PD group was associated with reduced blood loss (450 vs. 600 ml,  $P=.049$ ), lower rate of blood transfusion (23.7% vs. 46.3%,  $P=.035$ ), and shorter length of hospital stay (19 vs. 26 days,  $P<.001$ ). The rates of 90-day mortality, major morbidity, and readmission were comparable among the two groups.

This study demonstrates that CMAFA is a feasible and efficient technique with acceptable perioperative and oncological outcomes in treating patients with PHC.

**Abbreviations:** AFA = artery-first approach, CA = celiac axis, CHA = common hepatic artery, CMAFA = combination of multiple artery-first approaches, CoPD = conventional PD, CT = computed tomography, GDA = gastroduodenal artery, IPDA = inferior pancreaticoduodenal arteries, LRV = left renal vein, PD = pancreatoduodenectomy, PHC = pancreatic head cancer, PV = portal vein, SMA = superior mesenteric artery, SMV = superior mesenteric vein, TPD = total pancreaticoduodenectomy, UICC = Internationale Contre le Cancer.

**Keywords:** Artery-first approach, embryology, pancreatic head cancer, pancreatoduodenectomy, superior mesenteric artery

## 1. Introduction

Pancreaticoduodenectomy (PD) is the standard surgical procedure for pancreatic head cancer (PHC). Since the initial report of the PD technique by Whipple and Kausch,<sup>[1,2]</sup> some modified PD procedures at the resection stage have been developed over the years, such as superior mesenteric artery (SMA) first approach,<sup>[3]</sup>

no-touch isolation technique,<sup>[4,5]</sup> uncinate process-first approach,<sup>[6]</sup> and the hanging maneuver.<sup>[5,7]</sup> Artery-first approach (AFA) is one of the important progresses in the evolution of PD, featuring early judgment of resectability,<sup>[3,8–10]</sup> optimal exposure of arterial abnormalities,<sup>[3,6,11,12]</sup> simplification of clearing the posteromedial resection margins,<sup>[3,10,13]</sup> and significant reduction of intraoperative blood loss.<sup>[6,9,11]</sup> Up to now, there are main six artery-first approaches reported in the published papers, all of which have its own applicable characteristics and provide pancreatic surgeons with some options in the treatment of PHC.<sup>[3,4,6,9–11,14–16]</sup> Most studies reported AFA mainly focused on the surgical exploration for the purposes of early determining resectability and usually used one of those six techniques as the initial approach for SMA dissection. But in most cases, it is not enough to use a single AFA to expose the whole length of the SMA and/or celiac axis (CA), particularly for locally advanced PHC. Therefore, a combination of different artery-first approaches based on the tumor location and extent of invasion may be pretty necessary.

Several Japanese studies demonstrated that lymphatic spread and perineural invasion of the PHC differ greatly between the dorsal and ventral primordium.<sup>[17–19]</sup> For tumors confined to the ventral pancreas domain, lymph node metastases and perineural invasion are prone to spread toward the SMA; on the other hand, tumors confined to the dorsal pancreas domain have a propensity to spread toward common hepatic artery (CHA) and the hepatoduodenal ligament. These results suggest that a safe and effective lymph nodes and nerve plexus dissection should be designed according to the primary tumor location.

Editor: Feng Yang.

*Funding/support:* This work was supported by the Postgraduate Innovative Research Project of Harbin Medical University (Grant Nos. YJSCX2017-41HYD, YJSCX2016-21HYD) and Chen Xiaoping Foundation for the Development of Science and Technology of Hubei Province (Grant Nos. CXPJJH11800004-001, CXPJJH11800004-003).

The authors of this work have nothing to disclose.

Department of Hepatopancreatobiliary Surgery, The Second Affiliated Hospital of Harbin Medical University, No.246 XueFu Avenue, Harbin, Heilongjiang Province, 150086, China.

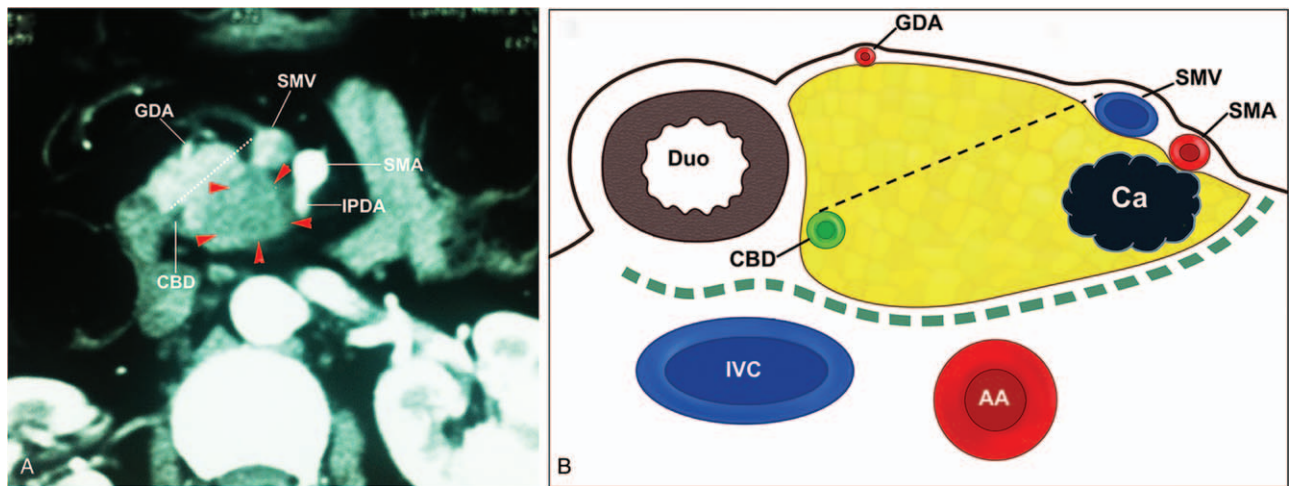
\* Correspondence: Yun-Fu Cui, and Zhi-Dong Wang, Permanent address: No. 246 XueFu Avenue, Harbin city, Heilongjiang Province, 150086, China (e-mails: yfcui777@hotmail.com, wzd98y2@163.com).

Copyright © 2019 the Author(s). Published by Wolters Kluwer Health, Inc. This is an open access article distributed under the terms of the Creative Commons Attribution-Non Commercial License 4.0 (CCBY-NC), where it is permissible to download, share, remix, transform, and build up the work provided it is properly cited. The work cannot be used commercially without permission from the journal.

Medicine (2019) 98:13(e14976)

Received: 27 June 2018 / Received in final form: 1 March 2019 / Accepted: 1 March 2019

<http://dx.doi.org/10.1097/MD.0000000000014976>



**Figure 1.** (A) CT scan image showing a tumor confined to the ventral pancreatic head. (B) Schematic diagram corresponding to (A). AA=abdominal aorta, Ca=cancer, CBD=common bile duct, Duo=duodenum, GDA=gastroduodenal artery, IPDA=inferior pancreaticoduodenal artery, IVC=inferior vena cava, SMA=superior mesenteric artery, SMV=superior mesenteric vein.

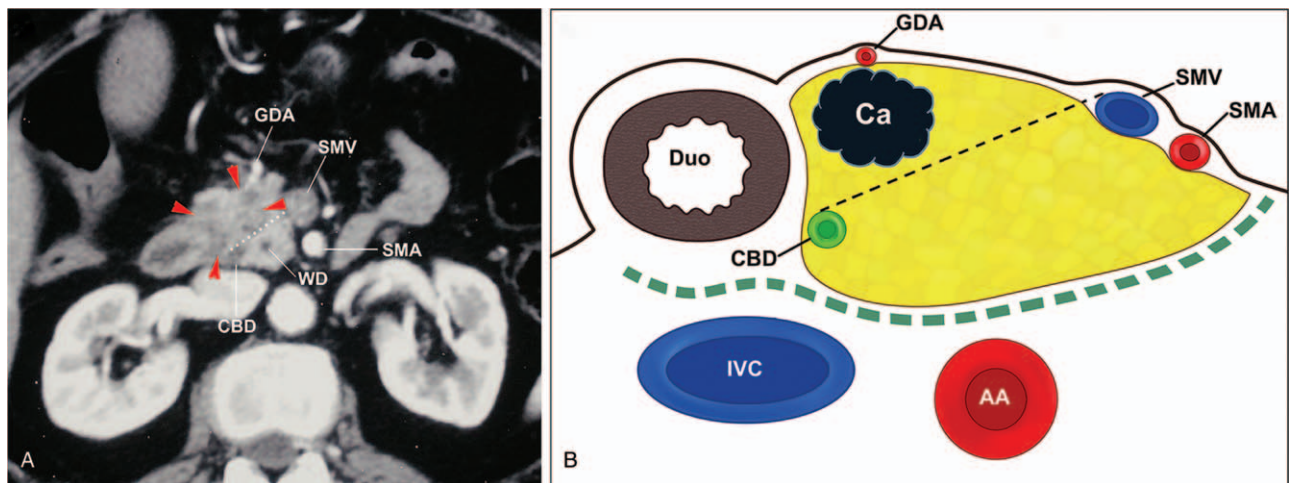
In the past several years, we have developed and implemented the radical modular PD technique with the combination of multiple artery-first approaches (CMAFA) depending on the aforementioned tumor classification. In the present study, we described the details of this technique and assess its feasibility and efficacy based on clinicopathological results.

## 2. Methods

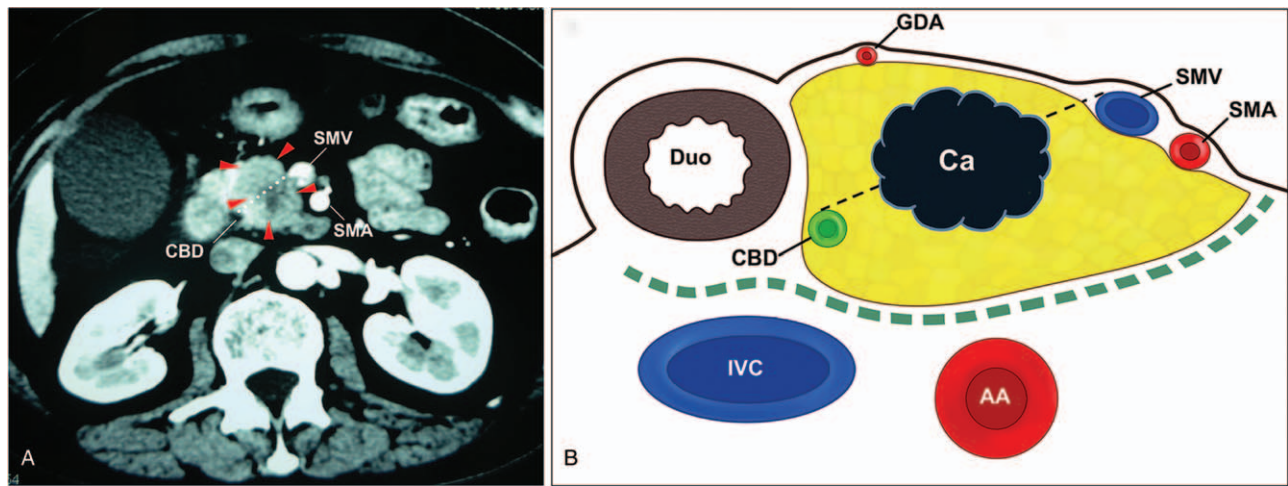
### 2.1. Concept and indications of the combination of multiple artery-first approaches

Based on the previous study,<sup>[19]</sup> it is relatively easy to recognize which domain the PHC is located by the line linking the portal vein/superior mesenteric vein (PV/SMV) and anterior edge of the intrapancreatic bile duct on the preoperative computed tomography (CT) images. Therefore, we classify the PHC into 3 types according to the preoperative imaging studies. Type I is greater than 90% of the tumor confined to ventral pancreatic head

(Fig. 1). Type II is greater than 90% of the tumor confined to dorsal pancreatic head (Fig. 2). Type III is the tumor extended to both areas of the pancreatic head (Fig. 3). Up to now, six AFAs were described in the published studies. In order to facilitate its application in this study, we divided the six AFAs into three types: superior approach,<sup>[20]</sup> posterior approach,<sup>[9,13]</sup> and inferior approach. CMAFA-PD is performed with different combinations of AFAs mainly based on four principles: the first is a priority to the targeting of the resection area guided by the tumor location; the second is the early judgment of resectability for borderline resectable PHC; the third is reducing the intraoperative blood loss so as to ensure the safety of the operation; and the fourth is the en bloc dissection of the posteromedial pancreatic margin. Accordingly, for Type I PHC, the area of resection should be focused along the whole length of SMA, thus both inferior and posterior approaches are considered; while in the case of Type II PHC, the area of resection should be concentrated along the CHA to the origin of the CA, thus superior and posterior approaches are considered. For Type III PHC, the root of SMA is usually



**Figure 2.** (A) CT scan image showing a tumor confined to the dorsal pancreatic head. (B) Schematic diagram corresponding to (A). AA=abdominal aorta, Ca=cancer, CBD=common bile duct, Duo=duodenum, GDA=gastroduodenal artery, IVC=inferior vena cava, SMA=superior mesenteric artery, SMV=superior mesenteric vein, WD=Wirsung duct.



**Figure 3.** (A) CT scan image showing a tumor extends to both ventral and dorsal pancreatic head. (B) Schematic diagram corresponding to (A). AA=abdominal aorta, Ca=cancer, CBD=common bile duct, Duo=duodenum, IVC=inferior vena cava, SMA=superior mesenteric artery, SMV=superior mesenteric vein.

**Table 1**  
Surgical approaches for different tumor types.

Combination of multiple AFAs	Tumor types		
	Type I (n=15)	Type II (n=10)	Type III (n=13)
I+P+S	15		
S+P		3	
S+P+I		7	
P+S+I			6
P+I+S			7

AFAs=artery-first approaches, I=inferior approach, P=posterior approach, S=superior approach. Type I, greater than 90% of the tumor limited to ventral pancreas; Type II, greater than 90% of the tumor limited to dorsal pancreas; Type III, tumor extended to both areas of the head of the pancreas.

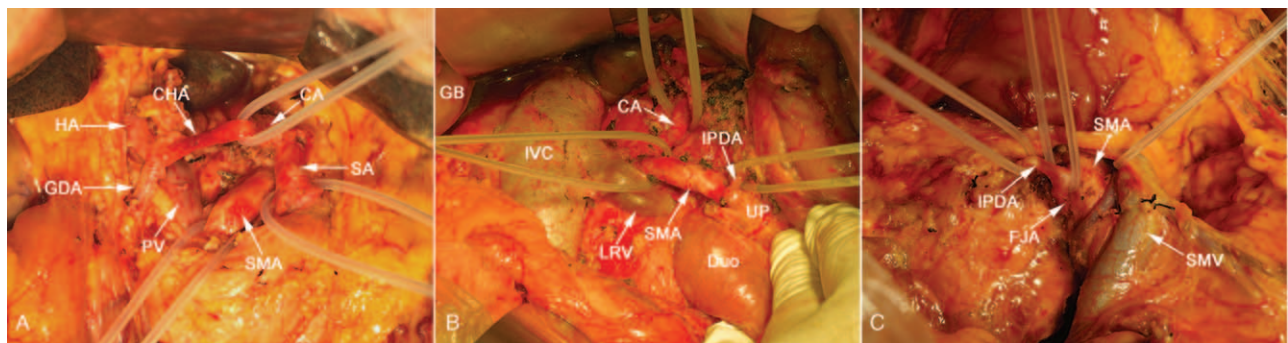
involved by the large tumor mass, thus posterior approach is performed first and dissection should be including along the SMA and the CHA. Therefore, superior and inferior approaches are also required. Additionally, superior and inferior approaches are performed in almost every CMAFA-PD for early ligation of the gastroduodenal artery (GDA) and inferior pancreaticoduodenal arteries (IPDA), except the circumstances that IPDA is easily dissected using posterior approach and thus the inferior approach

is not necessary in type II PHC. Details of surgical approaches for different tumor types in CMAFA-PD group are shown in Table 1.

**2.2. Surgical technique**

**2.2.1. Superior approach.** The superior approach used in this study was similar to that described by Sanjay et al.<sup>[20]</sup> In the present study, there are two levels in superior approach. Level 1 is the first dissection of the hepatoduodenal ligament to expose the whole length of CHA until its origin from the CA. At this stage, GDA is divided, and the PV is isolated at the upper border of the pancreatic neck. Level 2 is the dissection along the CA down to the aorta so as to expose the root of the SMA. For type II PHC that usually spreads to the CHA/CA and the root of the SMA, the superior approach is used to start the surgery and both levels are required to be performed; while for type I PHC, only level 1 is required. The crucial surgical steps in superior approach are depicted in Figure 4A.

**2.2.2. Posterior approach.** The posterior approach we used was similar to that described by Pessaux and Popescu et al.<sup>[10,15]</sup> Using an extended Kocher’s maneuver, the inferior vena cava and the distal portion of the left renal vein (LRV) can be exposed completely. The origin of the SMA is exposed where it passes in



**Figure 4.** Intraoperative images demonstrating the superior artery-first approach (A), posterior artery-first approach (B), and inferior artery-first approach (C). CA=celiac axis, CBD=common bile duct, CHA=common hepatic artery, Duo=duodenum, FJA=first jejuna artery, GDA=gastroduodenal artery, HA=hepatic artery, IVC=inferior vena cava, LRV=left renal vein, PV=portal vein, SA=splenic artery, SMA=superior mesenteric artery, SMV=superior mesenteric vein.

front of the distal portion of LRV. Using a vascular tape around the SMA, the right semicircle exfoliation of the nerve plexus together with the lymphatic connective tissue around the SMA is dissected cranio-caudally. Dissection along the right semicircle of the SMA is continued until the exposure of the lateral border of the SMV. At this stage, the IPDA and the replaced right hepatic artery can be identified. Then, the dissection is performed along the anterior surface of the aorta to expose the origin of the CA (Fig. 4B). The right semicircle connective tissue around the CA is then dissected, and the origin of the CHA can be exposed, if necessary. For type III PHC that occupied predominantly in the ventral pancreas, a combination of inferior approach is necessary. Similarly, for type III PHC that occupies predominantly in the dorsal pancreas, superior approach is usually required.

**2.2.3. Inferior approach.** The inferior approach to the SMA used in our institution included right/medial uncinate approach,<sup>[6]</sup> inferior supracolic approach,<sup>[4]</sup> and mesenteric approach.<sup>[3,21]</sup> Medial uncinate approach as one of the inferior approaches is used most frequently in this study, which is similar to that described by Hackert et al and Shukla et al.<sup>[6,22]</sup> The SMA is dissected in a supracolic, anterior, and retrograde fashion initiated from the caudal end of the uncinate process. In this process, IPDA and the first jejunal artery are divided and controlled (Fig. 4C). In most cases, a combination of inferior and posterior approaches could be conducive to access the full length of the SMA.

**2.2.4. Conventional PD.** In this study, Co-PD is defined that the dissection of the SMA is performed at the final stage of resection. In Co-PD, the dissection usually begins with the Kocher's maneuver so that a hand can be passed behind the pancreatic head to palpate the tumor mass. Thus, this step can roughly determine the tumor infiltration of the SMA or PV/SMV. After the irreversible divisions of pancreas, the pancreas head is pulled rightward, and the posterior surface of PV/SMV is carefully dissected from the uncinate process. Then, taping the SMV, the SMA can be divided from cranial to caudal and the right semicircle dissection of soft connective tissue around the SMA is dissected completely.

**2.2.5. Patients.** From January 2011 to December 2016, 101 consecutive patients with PHC underwent surgery with curative intent at the Department of Hepatopancreatobiliary Surgery, Second Affiliated Hospital of Harbin Medical University. Of these, a total of 79 patients who received PD, performed by a senior surgeon (Y.F. Cui), were enrolled in this study, excluding 22 patients underwent palliative surgery. In the present study, Co-PD was mainly performed in the early period (2011–2013), and our routine procedure was converted to CMAFA-PD afterward. This study only included patients with resectable or borderline resectable PHC according to the National Comprehensive Cancer Network (NCCN) guidelines and expert consensus statement in 2009.<sup>[23,24]</sup> Excluding criteria were as follows: (1) patients with severe medical complication; (2) with evidence of distant metastasis; and (3) patients were older than 75 years. All patients in this study were discussed and treated by a multidisciplinary team. The included patients were divided into 2 groups according to the surgical procedure. The first group of 41 patients underwent conventional PD (Co-PD group), and the second group of 38 patients received PD using the CMAFA technique (CMAFA-PD group).

Preoperative assessment of the resectability of the PHC was based on the enhanced CT with thin-slice scans and magnetic

resonance cholangiopancreatography. All clinical, surgical, and pathological data were recorded prospectively. A R1 resection margin was defined as the tumor cells were  $\leq 1$  mm from the margins. The postoperative pancreatic fistula was classified into 2 groups (grades B and C), according to the latest version of the International Study Group of Pancreatic Fistula definition.<sup>[25]</sup> Delayed gastric emptying, postpancreatectomy hemorrhage, and biliary fistula were defined according to the International Study Group on Pancreatic Surgery definitions.<sup>[26,27]</sup> This study was approved by the Institutional Ethics Committee of Harbin Medical University. All study participants provided written informed consent prior to study enrollment.

### 2.3. Statistical analysis

For continuous variables, descriptive statistics were expressed as median values with range. Continuous variables were compared by Wilcoxon rank-sum test. Categorized variables were performed using Pearson Chi-square test or Fisher's exact test. *P* values of less than .05 were considered as statistically significant. Data were analyzed using IBM SPSS 22.0 software (version 22.0; SPSS, Chicago, IL).

## 3. Results

### 3.1. Patient characteristics

A total of 79 consecutive patients with PHC underwent radical PD during the 6-year study period (CMAFA-PD=38, Co-PD=41). No significant differences were found between the 2 groups with respect to age, gender, BMI, and the rates of diabetes. The distribution of tumor location was similar in 2 groups. The rates of borderline tumors in 2 groups were also similar. In addition, the rates of patients who received neoadjuvant chemotherapy (gemcitabine 1000 mg/m<sup>2</sup> on days 1 and 8 plus S-1 65 mg/m<sup>2</sup> on days 1 through 14 of a 21-day cycle, 3 cycles of GS chemotherapy before surgery) in 2 groups were well balanced. Baseline patient demographics are presented in Table 2.

### 3.2. Pathologic analysis

There were no significant differences between the two groups in terms of tumor size, TNM stage, histologic type, perineural invasion, vessel invasion, and lymphatic permeation. Total number of dissected lymph node in CMAFA-PD group, however, was significantly higher than that of the Co-PD group. Curability was significantly higher in CMAFA-PD group. R0 resection rate was 70.7% in the Co-PD group and 89.5% in the CMAFA-PD group. Three patients with microscopically positive posterior resection margin were found in the CMAFA-PD group, 1 patient with microscopically positive margins on pancreatic stump. However, there were 5 patients with microscopically positive posterior margins, 3 patients with microscopically positive margins on pancreatic stump, and 4 patients with macroscopically positive margins on SMA in the Co-PD group. Pathologic details were shown in Table 2.

### 3.3. Perioperative outcomes

The perioperative outcomes are presented in Table 3. CMAFA-PD was associated with less blood loss (450 vs. 600 ml; *P* = .049) and lower rates of blood transfusion (23.7% vs. 46.3%; *P* = .035). Operative time and the number of patients with organ

**Table 2**  
**Patient and tumor characteristics.**

Variables	CMAFA-PD (n = 38)	CoPD (n = 41)	P
Age (year), median (range)	57 (36–76)	60 (42–77)	.423
Gender (male/female)	18/20	25/16	.225
BMI, median (range)	22.95 (15.2–29.8)	24.5 (15.4–32.5)	.307
Diabetes, n (%)	2 (5.3)	8 (19.5)	.089 <sup>‡</sup>
Preoperative biliary drainage, n (%)	6 (15.8)	10 (24.4)	.342
Tumor types, n (%)			.092
Type I	15 (39.5)	15 (36.6)	
Type II	10 (26.3)	4 (9.8)	
Type III	13 (34.2)	22 (53.7)	
Borderline tumors, n (%)	16 (42.1)	12 (29.3)	.233
Neoadjuvant chemotherapy, n (%)	4 (10.5)	3 (7.3)	.705 <sup>‡</sup>
Pathological data			
Tumor size (mm), median (range)	30 (15–60)	25 (10–80)	.829
TNM stage, n (%)			.210 <sup>‡</sup>
IA	4 (10.5)	9 (22.0)	
IB	12 (31.6)	15 (36.6)	
IIA	4 (10.5)	1 (2.4)	
IIB	16 (42.1)	11 (26.8)	
III	2 (5.3)	5 (12.2)	
IV	0 (0)	0 (0)	
Histologic differentiation, n (%)			.082
Well	5 (13.2)	12 (29.3)	
Poor/moderate	33 (86.8)	29 (70.7)	
Perineural invasion, n (%)	13 (34.2)	15 (36.6)	.825
Vessel invasion, n (%)	11 (28.7)	11 (26.8)	.834
Total number of LN dissected, median (range)	24 (7–38)	20 (5–35)	.024
Total number of metastatic LNs, median (range)	1.5 (0–14)	1 (0–8)	.984
Resection margin, n (%)			.038
R0	34 (89.5)	29 (70.7)	
R1/2	4 (10.5)	12 (29.3)	

<sup>‡</sup> Fisher's exact test.

BMI = body mass index, calculated as weight in kilograms divided by height in meters squared, LNs = lymph nodes. Type I, greater than 90% of the tumor limited to ventral pancreas; Type II, greater than 90% of the tumor limited to dorsal pancreas; Type III, tumor extended to both areas of the head of the pancreas. R0, microscopically curative resection; R1, microscopically positive resection margin; R2, macroscopically positive resection margin.

coresection and reoperation were comparable among groups. The rate of postoperative pancreatic fistula (POPF) was similar between the CMAFA-PD group and Co-PD group. The length of hospital stay was significantly shorter in the CMAFA-PD group, whereas the rates of the overall complication and 90-day readmission were similar between groups. One patient (2.4%) died in Co-PD group because of portal vein thrombosis after PV reconstruction, leading to liver failure.

### 3.4. Feasibility and validity of CMAFA-PD

There was no CMAFA-PD conversion to Co-PD. Twenty two patients were excluded from this study. Of these patients, 13 patients were found to show peritoneal dissemination and/or liver metastasis. We used the CMAFA technique to detect SMA involvement before reaching the “point of no return” in 6 patients who underwent palliative surgery afterward. Three patients with conventional approaches also underwent bypass surgery for major vessel invasion. Moreover, 4 patients experienced the “point of no return” in Co-PD group and ended up with macroscopically positive margins on SMA, whereas no patients experienced that point in CMAFA-PD group.

**Table 3**  
**Perisurgical outcomes.**

Variables	CMAFA-PD (n = 38)	CoPD (n = 41)	P
Operative time (min), median (range)	337 (170–645)	360 (195–625)	.558
Blood loss (ml), median (range)	450 (200–2400)	600 (150–1800)	.049
Blood transfusion, n (%)	9 (23.7)	19 (46.3)	.035
Coresection, n (%)			.679 <sup>‡</sup>
SMV- PV	9 (23.7)	7 (17.1)	
SV-PV	2 (5.3)	0 (0)	
Colon	1 (2.6)	1 (2.4)	
TP	4 (10.5)	1 (2.4)	
Point of no return, n (%)	0 (0)	4 (9.8)	.117 <sup>‡</sup>
Reoperation, n (%)	0 (0)	1 (2.4)	1.000 <sup>‡</sup>
90-day mortality, n (%)	0 (0)	1 (2.4)	1.000 <sup>‡</sup>
Overall complications, n (%)	16 (42.1)	22 (53.7)	.304
POPF, n (%)	3 (7.9)	7 (17.1)	.314 <sup>‡</sup>
Grade B/C	3/0	7/0	
DGE, n (%)	3 (7.9)	4 (9.8)	1.000 <sup>‡</sup>
Grade A/B/C	2/1/0	3/1/0	
PPH, n (%)	2 (5.3)	1 (2.4)	.606 <sup>‡</sup>
Grade A/B/C	1/1/0	0/0/1	
Biliary fistula, n (%)	0 (0)	3 (7.3)	.241
Chyle leak, n (%)	3 (7.9)	3 (7.3)	1.000 <sup>‡</sup>
Pulmonary infection, n (%)	0 (0)	1 (2.4)	1.000 <sup>‡</sup>
Abdominal abscess, n (%)	0 (0)	1 (2.4)	1.000 <sup>‡</sup>
Diarrhea, n (%)	6 (15.6)	4 (9.8)	.509
Wound infection, n (%)	1 (2.6)	2 (4.9)	1.000 <sup>‡</sup>
Portal vein thrombosis, n (%)	0 (0)	1 (2.4)	1.000 <sup>‡</sup>
Hospital stay (days), median (range)	19 (14–28)	26 (15–52)	<.001
90-day readmission, n (%)	1 (2.6)	2 (4.9)	1.000 <sup>‡</sup>

<sup>‡</sup> Fisher's exact test.

DGE = delayed gastric emptying, LN = lymph node, POPF = postoperative pancreatic fistula, PPH = postpancreatectomy hemorrhage, PV = portal vein, SMA = superior mesenteric artery, SMV = superior mesenteric vein, SV = splenic vein, TP = total pancreatectomy.

## 4. Discussion

Although the PD procedures are highly standardized in most high-volume pancreatic centers, consensus does not appear to have been reached regarding the optimal operative decision making according to the tumor location and extent of invasion. This is the first report that described a combination of multiple artery-first approaches for patients with PHC depending on the tumor location from an embryological point of view. The current study showed that CMAFA technique was associated with decreased intraoperative blood loss, blood transfusion, and length of hospital stay. Moreover, CMAFA technique was also associated with improved lymph nodal harvest and margin status.

It is necessary to establish a classification of PHC that contributes to optimize the operative decision making. Several classification systems have been published, such as the Japan Pancreas Society and the Union Internationale Contre le Cancer (UICC) classifications.<sup>[28]</sup> However, both of the two classification systems mainly focused on the reliability of predicting outcome rather than guidance of operative decision making. Recently, Wang et al proposed a classification system of PHC by the relationship of the tumor to key vascular around the pancreatic head.<sup>[29]</sup> However, the details of their technique for each type were vague. Although the AFA technique has been increasingly performed, there remains no consensus as to which AFA is indicated in which situation.<sup>[30]</sup> At our center, we used the duct of Santorini/Wirsung, the PV/SMV, and the bile duct as landmarks

in the enhanced CT with thin-slice scans to access the tumor location and extension preoperatively, which was described by Okamura et al.<sup>[17–19]</sup> According to the finding in the imaging studies, we categorize the PHC into three types based on an embryological division of the pancreatic head. Therefore, we have the opportunity to tailor different approaches to fit the different types of the PHC during PD.

Four major advantages seem to contribute to develop the CMAFA technique to PD. The first was a priority to dissect the vessel, nerve plexus, and lymph nodes that tumors were prone to spread and extend, following oncologic principles.<sup>[31]</sup> Especially for borderline resectable PHC, the presence of key vasculature involvement could be identified early enough to avoid the “point of no return”. The second was establishing a logical strategy to dissect the SMA margin first and to guarantee the maximum cancer margin. The third was the facilitation of the “no touch” resection of PV/SMV infiltrated by the PHC. In this case, the dissection of the SMA to PV/SMV was the critical part of the PD procedure. The CMAFA technique enabled the surgeon to perform an en bloc tumor resection without interfering with tumor integrity.<sup>[9,31,32]</sup> The fourth was the en bloc resection of tumors located on the pancreatic body and required PD. Using the CMAFA technique, the final transection of pancreas can be performed at any desired level without unnecessary incision of the tumor. Additionally, if total pancreaticoduodenectomy (TPD) was needed to perform, our CMAFA technique facilitated the dissection along the splenic artery and splenic vein to the splenic hilum, and thus contributed to preserve spleen. Using CMAFA technique, we successfully performed 4 TPD in CMAFA-PD group with no mortality in 90 days of resection.

At present, evidence that an AFA can increase the rate of R0 resection is sparse, and evidence that an AFA improves the lymph node yield is even more so. Five studies compared Co-PD with an AFA technique,<sup>[9,11,12,33,34]</sup> and only one study demonstrated significantly improved R0 rate and a higher lymph node yield.<sup>[34]</sup> Similarly, results from our study showed improved margin status and lymph node yield with CMAFA-PD. Three potential factors contribute to interpret the results. First, the CMAFA technique guarantees a complete resection of “the mesopancreas triangle,” which allows an en bloc resection of the pancreatic head with retroperitoneal tissue.<sup>[35]</sup> Second, the CMAFA technique facilitates the en bloc resection of the tumor-bearing region with high ligation of supplying arteries, such as GDA and IPDA. Third, we detected key vascular involvement in 6 cases by using CMAFA technique, and thus avoided unnecessary resection. On the contrary, 4 cases experienced the “point of no return” in Co-PD group, and thus received R2 resection.

A previous study compared Co-PD with a posterior AFA and showed that the AFA technique was associated with a significant reduction in estimated blood loss and duration of surgery time.<sup>[9]</sup> Although the operating time in our study was comparable among the two groups, both intraoperative blood loss and length of hospital stay in CMAFA-PD group were significantly lower than in the Co-PD group. The CMAFA technique in this study was used not only to explore the SMA but also focused on the early ligation of IPDA and GDA, thus reducing the congestion into the pancreatic head. We believe that it is an important advantage of CMAFA technique, which is feasible in every type of patients with PHC. Horiguchi et al used another modified procedure of PD to first ligation of IPDA and GDA before dissecting the corresponding afferent veins.<sup>[8]</sup> By doing this, bleeding from the resected surface was significantly reduced. It is reported that estimated blood loss was an important risk factor for

postoperative overall complications. In this study, there was no significant difference in the rates of the overall complication between groups, although operative blood loss was significantly higher in Co-PD group.

There are several inherent limitations in this study. First, because the sample size of this study was small, and the follow-up time of the CMAFA group was short, analysis of the long-term survival was not performed. Second, the study periods of the two groups did not overlap, thus our results cannot rule out the impact of the learning curve of the surgeon over time. Third, due to the surgical records regarding the abnormal vascular were incomplete, our study did not specifically document the early recognition of arterial abnormalities during PD.

## 5. Conclusions

In conclusion, this study demonstrates that CMAFA is a feasible and efficient technique with acceptable perioperative and oncological outcomes in treating patients with PHC. Based on our current experience, we believe that CMAFA would be applicable for radical modular PD depending on the tumor location and extent of invasion to choose an optimal combination of AFAs. This novel concept needs further randomized controlled trials to confirm.

## Author contributions

**Conceptualization:** Kai-Ming Leng, Zhi-Dong Wang, Yun-Fu Cui.

**Data curation:** Yun-Fu Cui.

**Formal analysis:** Xing-Ming Jiang, Zhi-Dong Wang.

**Funding acquisition:** Xing-Ming Jiang, Yun-Fu Cui.

**Investigation:** Hao Wang.

**Methodology:** Sheng Tai, Peng-Cheng Kang, Ming Wan.

**Project administration:** Yi Xu, Yun-Fu Cui.

**Resources:** Yi Xu.

**Software:** Peng-Cheng Kang, Hao Wang.

**Supervision:** Sheng Tai, Yun-Fu Cui.

**Validation:** Xiang-Yu Zhong, Sheng Tai, Zhi-Dong Wang, Yun-Fu Cui.

**Writing – original draft:** Kai-Ming Leng.

**Writing – review & editing:** Kai-Ming Leng, Xiang-Yu Zhong.

## References

- [1] Whipple AO, Parsons WB, Mullins CR. Treatment of carcinoma of the ampulla of Vater. *Ann Surg* 1935;102:763–79.
- [2] Das WK. Carcinom der papilla duodeni und seine radikale Entfernung: beitrage klinischen. *Chirurgie* 1912;78:47.
- [3] Weitz J, Rahbari N, Koch M, et al. The “artery first” approach for resection of pancreatic head cancer. *J Am Coll Surg* 2010; 210:e1–4.
- [4] Hirota M, Kanemitsu K, Takamori H, et al. Pancreatoduodenectomy using a no-touch isolation technique. *Am J Surg* 2010;199:e65–8.
- [5] Addeo P, Marzano E, Rosso E, et al. Hanging maneuver during pancreaticoduodenectomy: a technique to improve R0 resection. *Surg Endosc* 2011;25:1697–8.
- [6] Hackert T, Werner J, Weitz J, et al. Uncinate process first – a novel approach for pancreatic head resection. *Langenbecks Arch Surg* 2010;395:1161–4.
- [7] Marzano E, Piardi T, Pessaux P. The “hanging maneuver” technique during pancreaticoduodenectomy: the result of a technical evolution to approach the superior mesenteric artery. *JOP* 2011;12: 429–30.
- [8] Horiguchi A, Ishihara S, Ito M, et al. Pancreatoduodenectomy in which dissection of the efferent arteries of the head of the pancreas is performed first. *J Hepatobiliary Pancreat Surg* 2007;14:575–8.

- [9] Dumitrascu T, David L, Popescu I. Posterior versus standard approach in pancreaticoduodenectomy: a case-match study. *Langenbecks Arch Surg* 2010;395:677–84.
- [10] Pessaux P, Varma D, Arnaud JP. Pancreaticoduodenectomy: superior mesenteric artery first approach. *J Gastrointest Surg* 2006;10:607–11.
- [11] Kurosaki I, Minagawa M, Takano K, et al. Left posterior approach to the superior mesenteric vascular pedicle in pancreaticoduodenectomy for cancer of the pancreatic head. *JOP* 2011;12:220–9.
- [12] Shrikhande SV, Barreto SG, Bodhankar YD, et al. Superior mesenteric artery first combined with uncinate process approach versus uncinate process first approach in pancreaticoduodenectomy: a comparative study evaluating perioperative outcomes. *Langenbecks Arch Surg* 2011;396:1205–12.
- [13] Lupascu C, Moldovanu R, Andronic D, et al. Posterior approach pancreaticoduodenectomy: best option for hepatic artery anatomical variants. *Hepatogastroenterology* 2011;58:2112–4.
- [14] Partensky C. Pancreaticoduodenectomy by a superior mesenteric artery first approach. *J Chir (Paris)* 2008;145:598–600.
- [15] Popescu I, David L, Dumitra AM, et al. The posterior approach in pancreaticoduodenectomy: preliminary results. *Hepatogastroenterology* 2007;54:921–6.
- [16] Xu YF, Liu ZJ, Gong JP. Pancreaticoduodenectomy with early superior mesenteric artery dissection. *Hepatobiliary Pancreat Dis Int* 2010;9:579–83.
- [17] Okamura Y, Fujii T, Kanzaki A, et al. Clinicopathologic assessment of pancreatic ductal carcinoma located at the head of the pancreas, in relation to embryonic development. *Pancreas* 2012;41:582–8.
- [18] Kitagawa H, Ohta T, Makino I, et al. Carcinomas of the ventral and dorsal pancreas exhibit different patterns of lymphatic spread. *Front Biosci* 2008;13:2728–35.
- [19] Makino I, Kitagawa H, Ohta T, et al. Nerve plexus invasion in pancreatic cancer: spread patterns on histopathologic and embryological analyses. *Pancreas* 2008;37:358–65.
- [20] Sanjay P, Takaori K, Govil S, et al. ‘Artery-first’ approaches to pancreaticoduodenectomy. *Br J Surg* 2012;99:1027–35.
- [21] Nakao A, Takagi H. Isolated pancreatectomy for pancreatic head carcinoma using catheter bypass of the portal vein. *Hepatogastroenterology* 1993;40:426–9.
- [22] Shukla PJ, Barreto G, Pandey D, et al. Modification in the technique of pancreaticoduodenectomy: supracolic division of jejunum to facilitate uncinate process dissection. *Hepatogastroenterology* 2007;54:1728–30.
- [23] National Comprehensive Cancer Network (NCCN) clinical practice guidelines in oncology. Pancreatic adenocarcinoma. Available at: [http://www.nccn.org/professionals/physician\\_gls/default.asp](http://www.nccn.org/professionals/physician_gls/default.asp).
- [24] Callery MP, Chang KJ, Fishman EK, et al. Pretreatment assessment of resectable and borderline resectable pancreatic cancer: expert consensus statement. *Ann Surg Oncol* 2009;16:1727–33.
- [25] Bassi C, Marchegiani G, Dervenis C, et al. The 2016 update of the International Study Group (ISGPS) definition and grading of postoperative pancreatic fistula: 11 years after. *Surgery* 2017;161:584–91.
- [26] Wente MN, Bassi C, Dervenis C, et al. Delayed gastric emptying (DGE) after pancreatic surgery: a suggested definition by the International Study Group of Pancreatic Surgery (ISGPS). *Surgery* 2007;142:761–8.
- [27] Wente MN, Veit JA, Bassi C, et al. Postpancreatectomy hemorrhage (PPH): an International Study Group of Pancreatic Surgery (ISGPS) definition. *Surgery* 2007;142:20–5.
- [28] Isaji S, Kawarada Y, Uemoto S. Classification of pancreatic cancer: comparison of Japanese and UICC classifications. *Pancreas* 2004;28:231–4.
- [29] Wang M, Zhang H, Zhu F, et al. Pancreaticoduodenectomy for borderline resectable pancreatic head cancer with a modified artery-first approach technique. *Hepatobiliary Pancreat Dis Int* 2017;16:215–21.
- [30] Pandanaboyana S, Bell R, Windsor J. Artery first approach to pancreaticoduodenectomy: current status. *ANZ J Surg* 2016;86:127–32.
- [31] Cole WH, Packard D, Southwick HW. Carcinoma of the colon with special reference to prevention of recurrence. *J Am Med Assoc* 1954;155:1549–53.
- [32] Del Chiaro M, Segersvard R, Rangelova E, et al. Cattell-Braasch maneuver combined with artery-first approach for superior mesenteric-portal vein resection during pancreatectomy. *J Gastrointest Surg* 2015;19:2264–8.
- [33] Figueras J, Codina-Barreras A, Lopez-Ben S, et al. Cephalic duodeno-pancreatectomy in periampullary tumours. Dissection of the superior mesenteric artery as an initial approach. Description of the technique and an assessment of our initial experience. *Cir Esp* 2008;83:186–93.
- [34] Vallance AE, Young AL, Pandanaboyana S, et al. Posterior superior mesenteric artery first dissection versus classical approach in pancreaticoduodenectomy: outcomes of a case-matched study. *Pancreas* 2017;46:276–81.
- [35] Adham M, Singhirunnusorn J. Surgical technique and results of total mesopancreas excision (TMpE) in pancreatic tumors. *Eur J Surg Oncol* 2012;38:340–5.