

# Recent developments in MOG-IgG associated neurological disorders

Harald Hegen and Markus Reindl 

*Ther Adv Neurol Disord*

2020, Vol. 13: 1–20

DOI: 10.1177/  
1756286420945135

© The Author(s), 2020.  
Article reuse guidelines:  
sagepub.com/journals-  
permissions

**Abstract:** In the past few years, acquired demyelinating syndromes of the central nervous system associated with antibodies against myelin oligodendrocyte glycoprotein (MOG) have evolved into a new inflammatory disease entity distinct from neuromyelitis optica spectrum disorders or multiple sclerosis. The meticulous clinical description of patients with MOG IgG antibodies (MOG-IgG) has been achieved by development and use of highly specific cell-based assays. MOG-IgG associated disorders comprise a wide spectrum of syndromes ranging from acute disseminated encephalomyelitis predominantly in children to optic neuritis or myelitis mostly in adults. In recent studies, phenotype of MOG-IgG associated disorders has further broadened with the description of cases of brainstem encephalitis, encephalitis with seizures and overlap syndromes with other types of autoimmune encephalitis. In this review, we provide an overview of current knowledge of MOG-IgG associated disorders, describe the clinical presentations identified, highlight differences from neuromyelitis optica spectrum disorders and multiple sclerosis, summarize clinical outcome and concepts of immune treatment, depict the underlying mechanisms of antibody pathogenicity and provide the methodological essentials of MOG-IgG assays.

**Keywords:** acute disseminated encephalomyelitis, antibody, encephalitis, myelin oligodendrocyte glycoprotein, optic neuritis, seizure, transverse myelitis

Received: 20 April 2020; revised manuscript accepted: 2 July 2020.

## Introduction

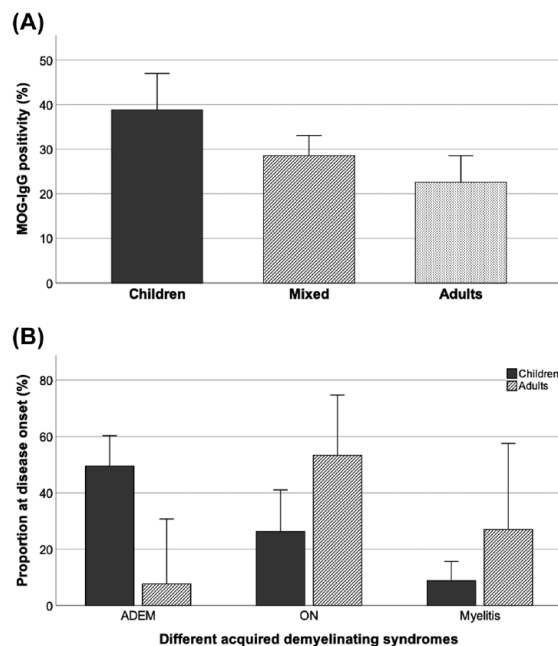
Myelin oligodendrocyte glycoprotein (MOG) is a highly conserved protein that is exclusively expressed in oligodendrocytes in the central nervous system (CNS).<sup>1,2</sup> Multiple isoforms of MOG exist that have identical extracellular immunoglobulin (Ig) domains, but differentially spliced intracellular C-termini. The differences in the C-terminal amino acids are the basis to distinguish  $\alpha$  or  $\beta$  isoforms of MOG.<sup>3,4</sup> Knowledge about the biological role of MOG and its isoforms is limited; however, the encephalitogenic potential of MOG that is eliciting demyelinating immune responses has been demonstrated in numerous experimental models.<sup>5–7</sup> For this reason, MOG-IgG antibodies (MOG-IgG) were extensively studied in the last two decades in different acquired demyelinating syndromes (ADSs). The development and use of highly specific cell-based assays (CBAs) enabled

the description of a variety of clinical disease manifestations ranging from certain ADS, for example, acute disseminated encephalomyelitis (ADEM) predominantly in children or optic neuritis mostly in adults, to cases of encephalitis with seizures.<sup>8–11</sup> This broad spectrum of clinical phenotypes associated with MOG-IgG has evolved into a new inflammatory CNS disease entity that is distinct from both multiple sclerosis (MS) and neuromyelitis optica spectrum disorders (NMOSDs).

In this review, we provide an overview of current knowledge of MOG-IgG associated disorders, describe the clinical presentations identified, highlight differences from NMOSD and MS, summarize clinical outcome and concepts of immune treatment, depict the underlying mechanisms of antibody pathogenicity and provide the methodological essentials in MOG-IgG assays.

Correspondence to:  
**Markus Reindl**  
Clinical Department  
of Neurology, Medical  
University of Innsbruck,  
Anichstrasse 35,  
Innsbruck, A-6020, Austria  
[markus.reindl@i-med.  
ac.at](mailto:markus.reindl@i-med.ac.at)

**Harald Hegen**  
Clinical Department  
of Neurology, Medical  
University of Innsbruck,  
Innsbruck, Austria



**Figure 1.** Frequency and clinical presentation of MOG-IgG associated disorders are age-dependent. (A) Frequency of MOG-IgG in AQP4-IgG negative non-MS demyelinating diseases out of studies including children,<sup>13–15,17,20–35</sup> mixed cohorts of children and adults<sup>36–51</sup> and adults<sup>8,12,52–75</sup> is shown. (B) Frequency of the main clinical phenotypes (ADEM, optic neuritis, myelitis) out of studies including children<sup>13–15,17</sup> and adults<sup>10,18,78</sup> is shown. The mean percentages (bars) with 95% confidence intervals (error bars) are shown. ADEM, acute disseminated encephalomyelitis; AQP4, aquaporin-4; IgG, immunoglobulin G; MOG, myelin oligodendrocyte glycoprotein; MS, multiple sclerosis; ON, optic neuritis.

## Clinical aspects

### Frequency of MOG-IgG in ADSs

The majority of studies of MOG-IgG in ADS have been retrospective and included selected patient populations. Only a few of the latest studies were designed prospectively or used a population-based approach. MOG-IgG were detected in 65 (31%) of 210 children with ADS in a large study conducted in Austria and Germany,<sup>12</sup> in 76 (32%) of 237 children in a UK study,<sup>13</sup> in 31 (22%) of 151 children in a study from The Netherlands,<sup>14</sup> in 94 (39%) of 239 children in a study from Spain,<sup>15</sup> in 17 (18%) of 92 children in a study from Denmark<sup>16</sup> and in 84 (31%) of 274 children in a study from Canada.<sup>17</sup> Reported incidence rates ranged from 0.16 to 1.4 per 100,000 that is – among the group of ADS – in the range

of NMOSD, but clearly below the incidence of MS (see the following).<sup>12,18,19</sup>

Summarizing the data from all available studies that used CBAs [combined with fluorescence activated cell sorting (FACS) or immunofluorescence (IF)] in aquaporin-4 (AQP4)-IgG negative non-MS ADS to analyse MOG-IgG revealed a clear association of their prevalence with age. The proportion of patients with MOG-IgG positive ADS was higher among children (39%)<sup>13–15,17,20–35</sup> than among mixed cohorts of children and adults (29%)<sup>36–51</sup> or adults (23%)<sup>8,12,52–75</sup> [Figure 1(A)]. This higher seroprevalence of MOG-IgG in children might be a consequence of the age-dependent manifestation of different demyelinating CNS diseases, as MS and AQP4-IgG positive NMOSDs are more common in adults.<sup>76,77</sup>

### Spectrum of MOG-IgG associated demyelinating syndromes

Clinical and magnetic resonance imaging (MRI) characteristics of patients with positive MOG-IgG were reported by a multitude of studies in the past few years including different cohorts of patients, that is, children, adults or both, patients with monophasic and recurrent or with relapsing disease course only.<sup>9,10,13,14,17,23,25,35,48,49,51,56,57,68,78–86</sup> Overall, the clinical phenotype of MOG-IgG associated demyelinating syndromes changes with age from ADEM-like (ADEM, ADEM–optic neuritis, multiphasic disseminated encephalomyelitis) in children to opticospinal (optic neuritis, myelitis) in adults. A detailed overview on six recent representative large observational studies showing the frequency of different disease manifestations in adults and children is given in Table 1. Accordingly, MOG-IgG positive children presented as ADEM in approximately 50% of cases, whereas adults in less than 10%. Vice versa, onset with optic neuritis or myelitis was observed in up to 50% and 30% of adults, whereas in approximately 25% and 10% of children (Figure 1(B)). Manifestations with brainstem, cerebral or multifocal symptoms were – in most studies – quite infrequent (<10%) at any age.<sup>10,13,15,17,18,78,87</sup> Symptoms associated with involvement of the area postrema, for example, nausea, vomiting and hiccups, were reported in a small subset of patients (at or before presentation). The majority of these patients did not show discrete area postrema lesions, but patchy, poorly demarcated lower brainstem lesions (most commonly in the context of ADEM; the isolated presentation was rare).<sup>87–89</sup>

**Table 1.** Demographic, clinical, MRI and CSF features of MOG-IgG positive cohorts of six large studies.

	Study					
	Hennes <i>et al.</i> <sup>13,a</sup>	Armangue <i>et al.</i> <sup>15,b</sup>	Waters <i>et al.</i> <sup>17,c</sup>	De Mol <i>et al.</i> <sup>18,d</sup>	Jury <i>czyk et al.</i> <sup>10,e</sup>	Cobo-Calvo <i>et al.</i> <sup>78,f</sup>
<b>Demographics</b>						
Patient cohort	ADS	ADS and encephalitis	ADS	ADS	ADS	ADS
No. of patients	65	116	84	34	27	197
% female	54	49	55	47	44	49
% children	100	100	100	100	0	29 <sup>g</sup>
Age at onset	Median 6 yr (range 0–17)	Median 6 yr (IQR 4–10)	Median 7 yr (IQR 5–11)	Median 9 yr (IQR 6–12)	Median 33 yr (IQR 25–49)	Median 36 yr (range 19–77)
<b>Clinical manifestation at disease onset</b>						
% with ADEM	52	40	50	56	0	18
% with ON	29	17	38	21	44	55
% with bilateral ON	ND	5	ND	6	26	25
% with myelitis	13	11	8	3	41	18
% with LETM	ND	10	ND	3	19	14
% with ON and myelitis	5	ND	4	ND	ND	9
% with brainstem, cerebral or multifocal symptoms	1	ND	4 <sup>h</sup>	6	4	0
<b>Follow-up</b>						
Median months of follow-up	24 (range 24–86)	42 (range 8–197)	81 (IQR 57–105)	31 (IQR 10–71)	20 (IQR 11–43)	26 (range 0–492)
% with relapsing disease	34	28	20	27	41	44
Annualized relapse rate	0.40	0.61 <sup>i</sup>	0.50 <sup>j</sup>	ND	ND	0.20 <sup>g</sup>
% that met 2015 criteria for NMOSD <sup>k</sup>	5	5	0	15	11	40 <sup>g</sup>
% with disability of follow-up	21% <sup>l</sup>	28% <sup>m</sup>	ND	ND	ND	59%
% with EDSS score of $\geq 3$ at follow-up	5	ND	ND	ND	ND	ND
% with EDSS score $\geq 4$ at follow-up	3	ND	ND	ND	ND	7 <sup>o</sup>

(Continued)

Table 1. (Continued)

Study						
	Hennes <i>et al.</i> <sup>13,a</sup>	Armangue <i>et al.</i> <sup>15,b</sup>	Waters <i>et al.</i> <sup>17,c</sup>	De Mol <i>et al.</i> <sup>18,d</sup>	Jury <i>czyk et al.</i> <sup>10,e</sup>	Cobo-Calvo <i>et al.</i> <sup>7,8,f</sup>
<b>Magnetic resonance imaging</b>						
% with brain abnormalities	ND	80	67	ND	ND	45
<b>Cerebrospinal fluid and serum findings</b>						
% with CSF OCBs	11 <sup>p</sup>	19 <sup>q</sup>	16	11	28	12 <sup>r</sup>
% with CSF pleocytosis (>5 cells/ $\mu$ l)	49 <sup>t</sup>	ND <sup>u</sup>	ND	ND	ND	38 <sup>v</sup>
% with persistent MOG-IgG	71 <sup>o</sup>	48	36	64 <sup>x</sup>	72 <sup>y</sup>	92 <sup>z</sup>

<sup>a</sup>MOG-IgG were detected in a cell-based assay with an anti-human IgG (total molecule) specific secondary antibody and visualized by immunofluorescence (CBA-IF). A titre  $\geq 1/160$  was considered seropositive. Borderline seropositive samples (titres of 1/160–1/1,280) were confirmed with an anti-human IgG heavy chain specific secondary antibody.

<sup>b</sup>MOG-IgG were detected in a cell-based assay with an anti-human IgG secondary antibody and visualized by immunofluorescence (CBA-IF). A titre  $\geq 1/160$  was considered seropositive.

<sup>c</sup>MOG-IgG were detected in a cell-based assay with an anti-human IgG1 specific secondary antibody and visualized by immunofluorescence (CBA-IF). A titre  $\geq 1/20$  was considered seropositive.

<sup>d</sup>MOG-IgG were detected in a cell-based assay with an anti-human IgG secondary antibody and visualized by flow cytometry (CBA-FACS). A titre  $\geq 1/200$  was considered seropositive.

<sup>e</sup>MOG-IgG were detected in a cell-based assay with an anti-human IgG1 specific secondary antibody and visualized by immunofluorescence (CBA-IF). A titre  $\geq 1/20$  was considered seropositive.

<sup>f</sup>MOG-IgG were detected in a cell-based assay with an anti-human IgG heavy chain specific secondary antibody and visualized by flow cytometry (CBA-FACS). A titre  $\geq 1/640$  was considered seropositive.

<sup>g</sup>Only data from a subset of patients ( $n = 75$ ) are included.

<sup>h</sup>Three out of 84 patients had disease manifestation other than ON, myelitis or ADEM.

<sup>i</sup>Annualized relapse rate was not reported; instead it was calculated as the total number of relapses divided by the number of patients experiencing any relapse and normalized for 1 year follow-up.

<sup>j</sup>Annualized relapse rate of the first 48 months.

<sup>k</sup>See Wingerchuk *et al.*<sup>20</sup>

<sup>l</sup>Disability was defined as an EDSS score  $> 1$ .

<sup>m</sup>Disability was defined as a modified Rankin Scale score of  $\geq 1$ .

<sup>n</sup>Data from only a subset of patients ( $n = 77$ ) are included.

<sup>o</sup>Data from only a subset of patients ( $n = 51$ ) are included.

<sup>p</sup>Data from only a subset of patients ( $n = 63$ ) are included.

<sup>q</sup>Data from only a subset of patients ( $n = 47$ ) are included.

<sup>r</sup>Data from only a subset of patients ( $n = 24$ ) are included.

<sup>s</sup>Data from only a subset of patients ( $n = 175$ ) are included.

<sup>t</sup>Data from only a subset of patients ( $n = 61$ ) are included.

<sup>u</sup>Percentage of patients with CSF pleocytosis ( $>5$  cells/ $\mu$ l) was not reported, but instead the median white blood cell count of 26 (IQR 9–58) cells/ $\mu$ l.

<sup>v</sup>Data from only a subset of patients ( $n = 47$ ) are included.

<sup>w</sup>Data from only a subset of patients ( $n = 138$ ) are included.

<sup>x</sup>Frequency of persisting MOG-IgG was provided for adults and children as one group.

<sup>y</sup>Data from only a subset of patients ( $n = 57$ ) are included.

ADDEM, acute disseminated encephalomyelitis; ADS, acquired demyelinating syndrome; CBA, cell-based assay; CSF, cerebrospinal fluid; EDSS, Expanded Disability Status Scale; FACS, fluorescence-activated cell sorting; IF, immunofluorescence; IgG, immunoglobulin G; IQR, interquartile range; No., number; LETM, longitudinal extensive transverse myelitis; MOG, myelin oligodendrocyte glycoprotein; MRI, magnetic resonance imaging; ND, not determined; NMO/SD, neuromyelitis optica spectrum disorder; OCB, oligoclonal IgG bands; ON, optic neuritis; SD, standard deviation; yr, years.

**Table 2.** Demographic, clinical, MRI and CSF features of MS, AQP4-IgG positive NMOSD and MOG-IgG associated disease.

Disease		MS
MOG-IgG associated disease		AQP4-IgG positive NMOSD
<b>Epidemiology</b>		
Prevalence (per 100,000)	1–4	1–4
Incidence (per 100,000 and year) <sup>12,18</sup>	0.2–1.4	~0.5
<b>Demographics</b>		
Female:male ratio	1–2:1	8–9:1
Age at onset	More often in childhood than adulthood	>40 years
<b>Clinical presentation</b>		
Clinical presentation	ADEM-like (ADEM, MDEM, ADEM–optic neuritis, encephalitis) or opticospinal (optic neuritis, myelitis) or brainstem encephalitis	Optic neuritis, myelitis, area postrema syndrome, brainstem syndrome, narcolepsy or acute diencephalic syndrome, cerebral syndrome with NMOSD-typical brain lesions
Disease course	Monophasic and recurrent (recurrence often presents as optic neuritis)	More often recurrent than monophasic
<b>Magnetic resonance imaging</b>		
Brain MRI <sup>80,91</sup>	ADEM-like, atypical for MS (fluffy lesions or three lesions or fewer) or no brain lesions	Atypical for MS and/or lesions in the brainstem; or no brain lesions
Frequency of normal brain MRI at disease onset <sup>78,85,92</sup>	Up to 50% (depending on type of manifestation; normal brain MRI often seen in optic neuritis)	Up 50%
Spinal MRI <sup>140,93,94</sup>	Long-segment lesions (>3 vertebral segments); typically involving thoracolumbar segment and conus; confined to grey matter (H sign); contrast-enhancement infrequent	Long-segment lesions (>3 vertebral segments); typically involving cervicothoracic segment; central cord predominance; contrast-enhancement frequent
		Short-segment lesions (<3 vertebral segments); axial peripheral (dorsal/lateral column); contrast-enhancement frequent

*(Continued)*

Table 2. (Continued)

Disease		MS
	MOG-IgG associated disease	AQP4-IgG positive NMOSD
Optic neuritis <sup>95</sup>	Bilateral more often than unilateral, often anterior optic pathway, long lesion, often recurrent, severe, good recovery	Bilateral more often than unilateral, often posterior optic pathway, involvement of optic chiasma, long lesion, often recurrent, severe, often residual deficits
<b>Cerebrospinal fluid</b>		
Pleocytosis	Common (>70% of patients)	Common (>70% of patients)
Cytology <sup>97,98</sup>	Mononuclear, but neutrophils can occur (in up to ~50% of samples)	Mononuclear, but neutrophils can occur (in up to ~50% of samples)
OCBs	Rare (<10–20% of patients)	Rare (<10% of patients)
<b>Optical coherence tomography</b>		
Axonal damage (assessed, e.g., by pRNFL decrease) <sup>70,97–99</sup>	Moderate (per optic neuritis attack)	Severe (per optic neuritis attack)
<b>Neuropathology</b>		
Pathological hallmark	Oligodendro-cytopathy	Astrocytopathy
<b>Treatment and outcome</b>		
Treatment	Immunosuppressive	Immunosuppressive
Risk of future disability <sup>100</sup>	Low, owing to good recovery from attacks; in a subset of patients recovery from the initial attack is poor	High, owing to poor recovery from attacks and a high relapse rate

Apart from the references provided in the table, the data summarize several studies of MS,<sup>76, 101–103</sup> AQP4-IgG positive NMOSD<sup>80,90, 104–106</sup> and MOG-IgG associated disorders.<sup>9, 10, 13, 14, 23, 25, 35, 48, 49, 51, 56, 57, 68, 78, 79, 81–86, 107</sup> ADEM, acute disseminated encephalomyelitis; AQP4, aquaporin-4; CSF, cerebrospinal fluid; IgG, immunoglobulin G; MDEM, multiphasic disseminated encephalomyelitis; MOG, myelin oligodendrocyte glycoprotein; MS, multiple sclerosis; MRI, magnetic resonance imaging; NA, not available; NMOSD, neuromyelitis optica spectrum disorder (according to the 2015 diagnostic criteria); OCB, oligoclonal IgG band; pRNFL, peripapillary retinal nerve fibre layer.

### *Delineating MOG-IgG associated disorders from other demyelinating CNS diseases*

Patients with MOG-IgG associated demyelinating syndromes show certain demographic and clinical characteristics, cerebrospinal fluid (CSF) and MRI findings that allow the differentiation from patients with MS or AQP4-IgG positive NMOSD to a certain extent and can be the basis for reasonable antibody testing. A comprehensive comparison between MOG-IgG associated disorders, AQP4-IgG positive NMOSD and MS is shown in Table 2; MRI findings are further detailed in the following.

**MRI.** Brain MRI in patients with MOG-IgG associated disorders typically shows few, poorly demarcated, 'fluffy', sometimes large lesions that affect both the white matter and the grey matter, the latter including cortex and deep grey nuclei.<sup>9,91</sup> However, a reliable discrimination of MOG-IgG associated disorders from AQP4-IgG positive NMOSD and MS based on brain MRI findings is not possible.<sup>9,10,13,15,17,18,78,91,95,108</sup> Characteristic MRI features have been reported for optic pathway and spinal cord. Patients with MOG-IgG associated disorders and optic neuritis typically had bilateral involvement of the anterior optic pathways with long lesions and optic nerve head swelling.<sup>95,109</sup> Bilateral involvement was of similar frequency in MOG-IgG associated disorders and AQP4-IgG positive NMOSD, but significantly more frequent than in MS. Affection of the chiasma was reported in some patients with MOG-IgG associated disorders; whether the frequency differs from AQP4-IgG positive NMOSD is still contradictory. The involvement of the optic tract was uncommon in MOG-IgG associated disorders.<sup>95,109</sup> MRI of the spinal cord typically showed longitudinally extensive T2-signal abnormalities (>3 vertebral segments) predominantly of the thoracolumbar region<sup>40</sup> involving the ventral spinal cord parenchyma confined to the grey matter (sagittal line and axial H sign) without contrast-enhancement,<sup>93</sup> allowing distinction of myelitis from AQP4 positive NMOSD and MS. Longitudinally extensive T2 lesions were of similar frequency in MOG-IgG associated disorders and AQP4-IgG positive NMOSD but not found in MS.<sup>93,94</sup> Multiple spinal cord lesions and conus involvement were more frequent with MOG-IgG than AQP4-IgG but not different from MS.<sup>93</sup> Besides these reported MRI features, the initial scan of the brain<sup>15,17,78,85</sup> as well as of the spinal cord<sup>110</sup> can be normal in patients with MOG-IgG

associated disorders, also despite severe clinical manifestation, which can lead to diagnostic uncertainty.

### *Expanding the MOG-IgG disease spectrum*

**Encephalitis.** The association of MOG-IgG with an encephalitic presentation has been known since the first report in 2017. An adult was described with steroid-responsive encephalitis involving the cortical areas who experienced focal seizures that subsequently generalized and who was eventually shown to be positive for MOG-IgG. When the patient's treatment of prednisolone was tapered, a relapse occurred with optic neuritis.<sup>111</sup> Later case series confirmed the association between MOG-IgG, cortical brain lesions on MRI (typically with contrast enhancement) and seizures. The vast majority of patients had a relapsing disease course and had experienced demyelinating events such as optic neuritis or myelitis before, with or after encephalitis onset; and some patients had additional deep white matter or brainstem lesions on MRI.<sup>78,112–115</sup>

To further explore the significance of encephalitis associated with MOG-IgG, a large, prospective, multicentre, observational study was performed that included children with the whole spectrum of encephalitis (i.e. of infectious, autoimmune and unknown origin). The authors reported that among patients with autoimmune encephalitis (other than ADEM) MOG-IgG were more common (34%) than all neuronal antibodies combined (with N-methyl-D-aspartate-receptor [NMDAR] antibodies in 22% as the second most frequent).<sup>15</sup> These MOG-IgG positive encephalitis patients developed clinical syndromes including decreased level of consciousness (100%), seizures [64% (45% with status epilepticus)], fever (59%), and abnormal behaviour (50%) and movements (36%). Brain MRI showed extensive cortical involvement, basal ganglia or thalamic involvement, in some cases also only minimal changes (those associated with refractory status epilepticus), or revealed normal scans. Within a median follow-up of 45 months, 23% of patients had at least one relapse; almost all of them showed a demyelinating syndrome (optic neuritis or myelitis).<sup>15</sup>

Altogether, MOG-IgG were found to be associated with the clinical presentation of encephalitis (other than ADEM). The majority of patients

showed also features of demyelination either clinically before, concomitantly or after encephalitis onset, or by means of MRI.

*Overlap syndromes.* Overlap syndromes with MOG-IgG and NMDAR antibodies are known. A recent study reported that in patients with NMDAR encephalitis concurrent glial antibodies were present in approximately 4% of cases; half of them were MOG-IgG.<sup>116</sup> NMDAR encephalitis patients with additional MOG-IgG showed more frequently atypical disease manifestation including brainstem or cerebellar symptoms or presented distinct demyelinating features such as optic neuritis or myelitis; MRI revealed lesions typically in subcortical white matter, infratentorial region or the spinal cord with facultative contrast-enhancement. In some cases involvement of the basal ganglia and cortical regions as well as meningeal enhancement have been reported.<sup>47,116</sup> From a pathophysiological point of view, the shared contribution of NMDAR antibodies and immune responses to myelin dysfunction is unknown, but it should be noted that oligodendrocytes contain NMDAR.<sup>117</sup> It has been suggested that MOG-IgG could reflect, for example, a secondary immune reaction.<sup>118</sup> However, patients with overlapping antibodies also often had a history of episodes of encephalitis or demyelinating syndromes.<sup>47,116</sup> Of note, the distribution of the concurrent antibodies was different in serum and CSF in some patients, suggesting different compartmentalization of the immune responses.<sup>116</sup> Evolution and sequence of concurrent antibodies as well as the underlying immune mechanisms have to be explored by further studies. Nevertheless, these findings emphasize the importance of examining MOG-IgG in patients with NMDAR encephalitis and atypical clinical or imaging features, especially because double-positive patients might have worse prognosis and possibly need more aggressive immune treatment.<sup>47</sup>

*Seizures.* Seizures as an isolated phenomenon have been reported to be associated with MOG-IgG, that is, seizures were not accompanied by clinical manifestation of encephalitis or ADS, and brain MRI was unremarkable at onset. Seizures occurred solitarily or as cluster over a short interval of days. As a direct contribution of MOG-IgG to epileptogenesis is very unlikely, based on pathophysiological considerations and by findings that seizure occurrence did not differ between MOG-IgG positive (11%) and negative (14%) patients

with ADEM,<sup>34</sup> one might hypothesize that subtle inflammation of brain cortex was already present at onset of seizures but not detectable on regular brain MRI. Indeed, all of these patients developed ADS or encephalitis symptoms and eventually MRI abnormalities during follow-up.<sup>119</sup>

*Other possible disease presentations.* Several cases of cranial neuritis with concurrent CNS involvement and MOG-IgG positivity have been described.<sup>120,121</sup> The cranial nerve involvement was determined by contrast-enhancement on MRI at the nerve root entry zone. Possible explanations for MOG-IgG reactivity might include that at this anatomical region of the cranial nerve, the so called transitional zone, an overlap of central and peripheral myelin features exist, or that an inflammatory process from CNS lesions might progress downstream.<sup>120</sup> Cases with isolated or a clear additional affection of the peripheral nervous system, such as cranial neuritis or inflammatory demyelinating polyneuropathy, remain elusive.<sup>122,123</sup>

#### *MOG-IgG in daily clinical routine*

Recently, a diagnostic algorithm for the inclusion of MOG-IgG in daily clinical practice in patients with ADS has been proposed, leading to four main phenotypes: MS, AQP4-positive NMOSD, MOG-IgG associated disorders and antibody-negative ADS (Figure 2).<sup>25,50,101,108</sup> As MS is the most common ADS and frequently shows a characteristic MRI pattern as well as CSF-restricted oligoclonal bands,<sup>101</sup> it seems reasonable first to perform these two examinations. In the case of MS-atypical findings and negative AQP4-IgG, MOG-IgG should be determined. As the clinical phenotype associated with MOG-IgG expands to patients with autoimmune encephalitis, as shown by recent studies, MOG-IgG testing should also be considered in these cases especially after other differential diagnoses have been ruled out (Figure 2). It is crucial to limit MOG-IgG testing to these atypical cases, as screening of unselected, large populations for a rare biomarker generally decreases its positive predictive value by increasing the rate of false-positive results. Even if an assay shows a high specificity (e.g.  $\geq 99\%$ ), the true-positive results can easily be outnumbered by false-positive results if the prevalence of a biomarker is low and the number of samples tested is high. This fundamental statistical fact also applies to MOG-IgG testing. In order to avoid overdiagnosing MOG-IgG associated disorders, a list of



<p style="text-align: center;"><b>MOG-IgG associated disorder</b></p> <p style="text-align: center;"><b>Clinical syndrome</b> ADEM, ON, TM, autoimmune encephalitis</p> <p style="text-align: center;"><b>MRI</b> Atypical</p> <p style="text-align: center;"><b>CSF</b> OCB 10%</p> <p style="text-align: center;"><b>Antibodies</b> MOG-IgG positive</p>	<p style="text-align: center;"><b>Neuromyelitis optica spectrum disorder</b></p> <p style="text-align: center;"><b>Clinical syndrome</b> ON, TM, BS</p> <p style="text-align: center;"><b>MRI</b> Atypical</p> <p style="text-align: center;"><b>CSF</b> OCB 10%</p> <p style="text-align: center;"><b>Antibodies</b> AQP4-IgG positive</p>
<p style="text-align: center;"><b>Other acquired demyelinating syndrome</b></p> <p style="text-align: center;"><b>Clinical syndrome</b> ON, TM, (multi)focal demyelinating</p> <p style="text-align: center;"><b>MRI</b> Atypical</p> <p style="text-align: center;"><b>CSF</b> OCB mostly negative</p> <p style="text-align: center;"><b>Antibodies</b> MOG-IgG and AQP4-IgG negative</p>	<p style="text-align: center;"><b>Multiple Sclerosis</b></p> <p style="text-align: center;"><b>Clinical syndrome</b> ON, TM, BS</p> <p style="text-align: center;"><b>MRI</b> Typical</p> <p style="text-align: center;"><b>CSF</b> OCB 90%</p> <p style="text-align: center;"><b>Antibodies</b> MOG-IgG and AQP4-IgG negative</p>

**Figure 2.** Spectrum of demyelinating diseases of the central nervous system.

ADEM, acute disseminated encephalomyelitis; AQP4, aquaporin-4; BS, brainstem syndrome; CSF, cerebrospinal fluid; IgG, immunoglobulin G; MOG, myelin oligodendrocyte glycoprotein; MRI, magnetic resonance imaging; OCB, oligoclonal bands; ON, optic neuritis; TM, transverse myelitis.

indications as well as ‘red flags’ for MOG-IgG testing based on expert consensus have been recently proposed.<sup>108</sup>

*Disappearance of MOG-IgG is associated with a monophasic disease course*

Approximately 35% of patients with MOG-IgG associated demyelinating disorders were reported to have a relapsing disease course, and relapses often manifest as optic neuritis irrespective of the initial type of disease manifestation.<sup>10,13,15–17,78</sup> Most of the studies reported that a relapsing disease course was more likely in patients with higher MOG-IgG titres at onset<sup>13,78</sup> and persisting MOG-IgG over time, whereas transient low titre MOG-IgG were typically associated with a monophasic disease course.<sup>10,13,15,17,30,37,46,50,78,124</sup> Two recent studies each including more than 60 MOG-IgG positive patients with serial testing

revealed that the median time to become seronegative was about 12 months.<sup>15,17</sup> Overall, the predictive value of persisting MOG-IgG for the occurrence of relapses was only moderate (positive predictive value of approximately 60%); however, seroreversion to MOG-IgG negativity during early disease course reliably predicted monophasic disease (negative predictive value of approximately 90%). A summary of studies investigating the predictive value of MOG-IgG persistency is given in Table 3. Even though the predictive capability of MOG-IgG seems to be clear in general, there are still some limitations that do not allow their uncritical use in clinical routine and that have to be overcome first; for example, the usage of different cut-offs for defining antibody positivity due to various MOG-IgG assays, or the univariate statistical analyses that did not correct for the impact of other covariates, for example, immune treatment, on relapse risk

**Table 3.** Association of persistent MOG-IgG with a relapsing disease course.

Reference	Assay	Cut-off <sup>a</sup>	Follow-up	No. of patients	Transient/persistent MOG-IgG	NPV, PPV
Jury czyk <i>et al.</i> <sup>10</sup>	CBA-IF	≥1:20	29/28 mo <sup>b</sup>	57	14/43 <sup>h</sup>	14/14 (100%), 24/43 (56%)
Hennes <i>et al.</i> <sup>13</sup>	CBA-IF	≥1:1280	22/30 mo <sup>c</sup>	34	27/7	18/27 (67%), 6/7 (85%)
Cobo-Calvo <i>et al.</i> <sup>78</sup>	CBA-IF	≥1:160	6 mo <sup>d</sup>	24	2/22	2/2 (100%), 13/22 (59%)
Armangue <i>et al.</i> <sup>15</sup>	CBA-IF	≥1:160	At 24 mo	62	32/30	31/32 (97%), 20/30 (67%)
Waters <i>et al.</i> <sup>17</sup>	CBA-IF	≥1:20	~48 mo <sup>e</sup>	67	38/29 <sup>i</sup>	32/38 (84%), 11/29 (38%)
Pröbstel <i>et al.</i> <sup>30</sup>	CBA-FACS	≥1:50	Up to 14 mo <sup>f</sup>	16	10/6	10/10 (100%), NA <sup>j</sup>
López-Chiriboga <i>et al.</i> <sup>50</sup>	CBA-FACS	≥1:20	16–32/39–75 mo <sup>g</sup>	25	8/17	15/17 (88%), 7/8 (88%)

<sup>a</sup>Dilution defining MOG-IgG positivity.

<sup>b</sup>Median FU time is shown for patients with persistent and transient MOG-IgG.

<sup>c</sup>Median FU time is shown for patients with monophasic and recurrent disease course.

<sup>d</sup>Median FU time for the whole cohort.

<sup>e</sup>Median FU time was 4.29 years for patients with persistent MOG-IgG, 4.04 years for patients with transient MOG-IgG and 5.20 years for patients with fluctuating MOG-IgG serostatus.

<sup>f</sup>Ten of these 16 patients converted to MOG negativity within 14 months.

<sup>g</sup>In the persistent MOG-IgG group, median FU time ranged from 39 months (adults) to 75 months (children); in the transient MOG-IgG group, FU time ranged from 16 months (adults) to 32 months (children).

<sup>h</sup>Two patients turned negative and then positive again; none of them relapsed.

<sup>i</sup>Five patients fluctuated between positive and negative MOG-IgG status.

<sup>j</sup>None of these six patients had relapsing disease course.

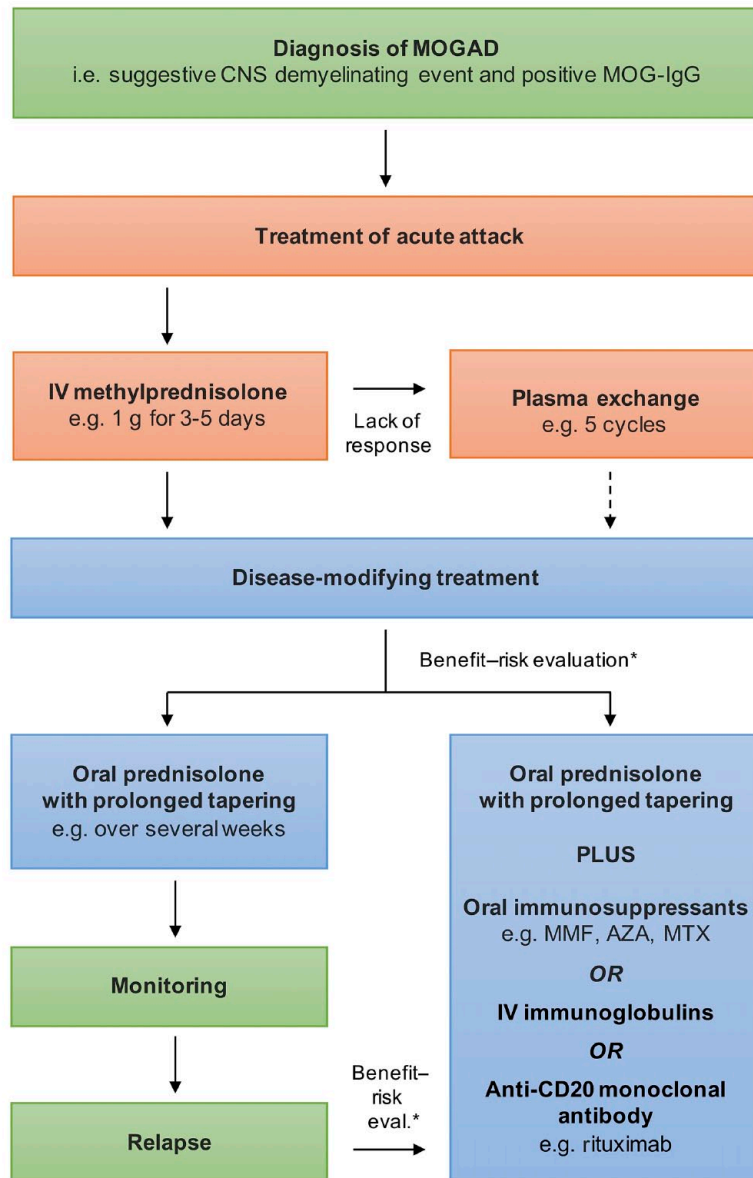
CBA, cell based assay; FACS, fluorescence-activated cell sorting; FU, follow-up; IF, immunofluorescence; mo, months; IgG, immunoglobulin G; MOG, myelin oligodendrocyte glycoprotein; NA, not available; No., number; NPV, negative predictive value; PPV, positive predictive value.

and did not show the independent predictive value of MOG-IgG persistency. Furthermore, as the association of MOG-IgG with disease course and the calculation of its predictive value were determined by retrospective analyses only, studies that *a priori* apply, for example, a definition for MOG-IgG persistency and follow patients for a second attack are needed to clearly capture a clinically relevant predictive value of MOG-IgG.

#### Treatment and outcome

**Treatment of acute attacks.** A significant proportion of patients with MOG-IgG associated disorders shows permanent disability depending on the age of manifestation, with higher risk of disability in adults.<sup>10,13,15,78</sup> In up to 60% of those patients, disability results from the onset attack, while in the remaining patients disability accumulation is due to the occurrence of further relapses.<sup>9,10,46,78</sup> These findings imply that attention should be paid to acute management, because the time to treatment might be important for the

prevention of permanent disability, as this is the case in NMO<sup>125</sup> and other types of autoimmune encephalitis.<sup>126</sup> Currently, there are no evidence-based guidelines for the acute treatment of patients with MOG-IgG associated disorders. Mostly, intravenous methylprednisolone and plasma exchange were used to treat acute attacks (Figure 3); however, intravenous immunoglobulins were also applied by some studies.<sup>78</sup> According to a seminal multicentre study that systematically investigated clinical and paraclinical features of patients with MOG-IgG associated disorders, intravenous methylprednisolone was applied at doses ranging from 1 to 2 g once a day for 3–5 days with good or complete recovery in approximately 50%.<sup>9</sup> If steroids did not result in recovery of symptoms, plasma exchange (usually with five cycles) was used as a second-line treatment, which further achieved substantial improvement in 40% of this steroid-non-responder.<sup>9</sup> Other studies reported even higher recovery rates from attacks of up to almost 90%; however, acute management was a mix of several consecutive



**Figure 3.** Therapeutic management of MOG-IgG associated disorders.

\*Benefit-risk evaluation based on prognostic factors for relapse and/or disability, for example, patient's age, previous disease course, present clinical syndrome or MOG-IgG persistency.

AZA, azathioprine; CNS, central nervous system; eval., evaluation; IgG, immunoglobulin G; IV, intravenous; MMF, mycophenolate mofetil; MOG, myelin oligodendrocyte glycoprotein; MOGAD, MOG-IgG associated disorder; MTX, methotrexate.

treatments in a certain proportion of patients, that is, the effect with a single treatment was not assessed.<sup>15</sup>

*Disease-modifying treatment.* Following treatment of the acute attack, a decision regarding the need for further disease-modifying treatment has to be made. Currently, there are no established

parameters that allow a reliable risk evaluation for the occurrence of further relapses or disability. On these grounds, decision to start a preventive longer-lasting immune treatment remains to be made by an individual benefit-risk evaluation typically influenced, for example, by the severity of and the recovery from the acute attack, if more than one attack has occurred from the time to

relapse and, if appropriate, from other factors that might be associated with the likelihood of relapse, for example, MOG-IgG persistency.<sup>127</sup> A treatment concept for patients with MOG-associated disorders is given in Figure 3.

Most immune treatments that are used in MOG-IgG associated disorders – which include corticosteroids, intravenous immunoglobulin, immunosuppressive drugs (such as mycophenolate mofetil, azathioprine and methotrexate) and rituximab – are associated with a reduction in time to relapse and annual relapse rate, respectively.<sup>9,10,78,84,85,128</sup> Of note, immunomodulatory treatments for MS, such as interferon- $\beta$  and glatiramer acetate, are ineffective.<sup>9,84</sup> Most of the studies were retrospective, including various treatments, each with a small number of patients and, therefore, addressed only whether any treatment was superior to no treatment.

The main concrete conclusions drawn from these studies are described in the following. Relapses frequently occurred either during steroid weaning or shortly after its cessation.<sup>9,10,78,84,85</sup> A recent study reported that relapses were mostly observed at doses <20 mg prednisone per day in adults or at doses <0.5 mg/kg per day in children.<sup>85</sup> The duration of treatment seems to impact relapse risk as well. The risk of relapse was higher in patients with only short-term immunosuppressive therapy (less than 3 months) as compared with those treated for a longer time.<sup>10</sup> Also of interest, one study showed that MOG-IgG positive patients treated with rituximab had some reduction of relapses, but relapse prevention was not associated with an effective depletion of memory B cells – in contrast to AQP4-positive NMOSD patients, in whom most relapses occurred after reemergence of memory B cells<sup>129</sup> and in whom B cell depleting therapies perform exceptionally well.<sup>130–132</sup>

However, a serious comparison of different therapies in terms of efficacy or even the estimation of the size of treatment effects is not feasible yet due to insufficient evidence (Class IV) and largely missing head to head analyses. Randomized controlled trials – as recently published for AQP4-positive NMOSD<sup>130–132</sup> – are urgently needed also for MOG-IgG associated disorders. As such trials are difficult to perform due to the rarity of the disorder, profound statistical analyses adjusting for known covariates of real-world-data, for example, from national registries, are definitely an alternative. A recent prospective observational study showed an

impressive risk reduction of relapse due to treatment with mycophenolate mofetil (MMF).<sup>133</sup> This study included 79 MOG-IgG positive patients presenting with ADEM, optic neuritis, transverse myelitis and/or brainstem syndrome compatible with demyelination who received either MMF or no immune treatment based on consensual decision with the treating physician and were followed for a median of 400 days; additional treatment for the acute phase with steroid tapering was allowed. Multivariate analyses adjusting for potential confounders such as age, sex, previous disease course and initial level of MOG-IgG titre revealed that MMF treatment resulted in a reduced risk of relapse by 86%.<sup>133</sup>

## Laboratory aspects

### *Validation of MOG-IgG assays*

Only when measured using CBAs has an association between MOG-IgG and a non-MS demyelinating phenotype been established (reviewed by Reindl and Waters 2019<sup>134</sup>). Recently, first blinded multicentre validation studies have addressed assay reproducibility between centres. The first study compared 394 samples using three different MOG-IgG CBAs from three international centres in a blinded validation experiment.<sup>135</sup> Overall, the concordance for all three CBAs was 98%, for the two live CBAs 99%. Clinical specificity ranged from 98.1% to 100%. Positive predictive values were higher for live CBAs (95.5% and 100%) than for fixed CBA (82.1%), whereas negative predictive values were comparable (78.8–79.8%). The second study compared three blinded samples in 13 centres using 13 different MOG-IgG CBAs.<sup>136</sup> Overall, the agreement of assays was 85%. Finally, the third study compared the reproducibility of 11 antibody assays for MOG-IgG [four live CBA-IF, three live CBA-FACS, one fixed CBA-IF and two enzyme-linked immunosorbent assay (ELISA)] and MOG-IgM (one live CBA-IF) from five international centres on 189 blinded samples.<sup>137</sup> Live MOG-IgG CBAs for samples previously identified as clearly positive or negative from four different national testing centres showed excellent agreement (96%) between the seven live CBAs for MOG-IgG. Agreement was lower with fixed CBA-IF (90%) and the ELISA showed no concordance with CBAs for detection of human MOG-IgG. All CBAs showed excellent inter-assay reproducibility. However, the agreement of

MOG-IgG CBAs for borderline negative (77%) and particularly low positive (33%) samples was less good. Finally, most samples from healthy blood donors (97%) were negative for MOG-IgG in all CBAs.

In conclusion these three studies indicate that there is a good agreement of currently used live CBAs for high-titre, but not for low-titre, positive samples. We therefore recommend that results on the MOG-IgG status should include not only the qualitative results (i.e. positive or negative), but also a quantitative estimate (e.g. titre or FACS binding ratio with reference range) and the type of assay used. This would also help to clarify the presence of MOG-IgG in MS, which was re-assessed by two large studies. The first study analysed serum samples of 200 patients with chronic progressive MS and found that none of the patients was positive for MOG-IgG.<sup>138</sup> The second study analysed serum samples from 685 consecutive patients with MS, and found only two of them (0.3%) were MOG-IgG positive.<sup>139</sup> Both studies clearly indicate that MOG-IgG is rare in MS and if present indicate either insufficient assay specificity or an inappropriate clinical diagnosis.

#### *The clinical relevance of CSF MOG-IgG*

The clinical relevance of CSF MOG-IgG was recently re-analysed in 80 seronegative patients with demyelinating diseases (NMOSD and related diseases, MS).<sup>140</sup> Three seronegative cases (two NMOSD and one ADEM) had CSF MOG-IgG (4% of the whole cohort or 7% of cases excluding patients with MS). MOG-IgG were also detectable in the CSF of eight of 13 MOG-IgG seropositive cases, but in none of 36 patients with neurodegenerative disorders. This study and other previously published case reports reviewed by the authors indicate that analyzing CSF could improve diagnostic sensitivity in seronegative patients.

#### *Pathology and pathophysiology of MOG-IgG associated diseases*

The pathophysiology and neuropathology of autoimmune responses to MOG has been well established in animal models and has been reviewed in detail elsewhere.<sup>6</sup>

So far, only case reports were available on the neuropathology associated with MOG-IgG in patients with inflammatory demyelinating diseases (reviewed

by Reindl and Waters<sup>134</sup>). The pathological features of MOG-IgG associated disorders were recently analysed in a larger series of two autopsies and 22 brain biopsies from patients with CNS inflammatory demyelinating diseases.<sup>141</sup> Both autopsies and the 22 brain biopsies had similar clinical, radiologic, laboratory and histopathological features. Pathology was dominated by the coexistence of both perivascular and confluent white matter demyelination, with an over-representation of intracortical demyelinated lesions compared with typical MS. Inflammatory cellular infiltrates were dominated by CD4+ T-cells and granulocytes. Complement deposition was present in all active white matter lesions, but a preferential loss of MOG was not observed. In contrast to the AQP4-IgG associated NMOSD pathology, AQP4 and astrocytes were preserved, whereas variable oligodendrocyte and axonal destruction was present. These results have most recently been confirmed by a second large case series from Japan.<sup>142</sup> Parallels with MOG-induced experimental autoimmune encephalomyelitis (EAE) suggest that MOG-IgG may be an amplification factor that augments CNS demyelination. Studies using the transfer of human MOG-IgG to experimental animal models indicated that human MOG-IgG can be pathogenic in rodents if they cross-react with rodent MOG and the titres and affinities of these antibodies are sufficiently high (reviewed by Reindl and Waters<sup>134</sup>). Tissue injury is triggered by antibody-mediated injury or augmentation of inflammation caused by MOG-reactive T cells. When compared with AQP4-IgG the pathogenic role of human MOG-IgG is less evident. However, since the vast majority of MOG-IgG in patients are reactive only to human epitopes an appropriate test system available to determine their *in vivo* pathogenicity is still missing.

The importance of T-cell mediated inflammation was recently confirmed in two studies analysing serum and CSF cytokine and chemokine profiles in MOG-IgG positive patients.<sup>143,144</sup> Both studies demonstrated that the CSF cytokine and chemokine profile associated with MOG-IgG is similar to AQP4-IgG positive NMOSD and distinct from MS. The inflammatory profile is characterized by coordinated upregulation of T helper 17 and other cytokines, particularly of interleukin-6.

#### **Conclusion**

In the last years, a multitude of studies using highly specific CBA have consolidated

the clinical spectrum of ADS associated with MOG-IgG. Young children most often manifest with ADEM, whereas the typical clinical presentation of adults includes optic neuritis or myelitis [Figure 1(B)] with certain paraclinical features distinct from those observed in MS or AQP4-positive NMOSD (Table 2). Additional clinical phenotypes have also been described in MOG-IgG positive patients, for example, encephalitis other than ADEM<sup>15</sup> – frequently showing seizures and demyelinating events within intervals of months or years – as well as overlap syndromes with NMDAR encephalitis.

Apart from the important diagnostic value (Figure 2), MOG-IgG also imply some predictive capability. Early reversion of MOG-IgG to seronegativity shows a fair predictive value for a monophasic disease (Table 3), even though the predictive value of persisting MOG-IgG for a relapsing course is of minor importance. In clinical practice, one might conclude that MOG-IgG seroreversion encourages a ‘wait and see’ strategy, whereas the sole persistence of MOG-IgG does not justify uncritical initiation of long-term immune therapy.

Treatment of patients with MOG-IgG associated neurological disorders is still based on Class IV evidence (Figure 3); however, studies are now coming up that show at least controlled designs (with treatment and control arms) and, thus, will provide the urgently needed evidence of treatment efficacy. In the light of all this amazing clinical progress, high-quality and specific MOG-IgG assays are – more than ever – of utmost importance.

#### Conflict of interest statement

The University Hospital and Medical University of Innsbruck (Austria; employer of HH and MR) receives payments for antibody assays (MOG, AQP4 and other autoantibodies) and for MOG and AQP4 antibody validation experiments organized by Euroimmun (Lübeck, Germany).

#### Funding

The authors disclosed receipt of the following financial support for the research, authorship, and/or publication of this article: Markus Reindl is supported by a research grant from the Austrian Science Fund (FWF, project P32699).

#### ORCID iD

Markus Reindl  <https://orcid.org/0000-0003-2817-1402>

#### References

1. Brunner C, Lassmann H, Waehnel TV, *et al.* Differential ultrastructural localization of myelin basic protein, myelin/oligodendroglial glycoprotein, and 2',3'-cyclic nucleotide 3'-phosphodiesterase in the CNS of adult rats. *J Neurochem* 1989; 52: 296–304.
2. Pham-Dinh D, Mattei MG, Nussbaum JL, *et al.* Myelin/oligodendrocyte glycoprotein is a member of a subset of the immunoglobulin superfamily encoded within the major histocompatibility complex. *Proc Natl Acad Sci USA* 1993; 90: 7990–7994.
3. Delarasse C, Gaspera Della B, Lu CW, *et al.* Complex alternative splicing of the myelin oligodendrocyte glycoprotein gene is unique to human and non-human primates. *J Neurochem* 2006; 98: 1707–1717.
4. Boyle LH, Traherne JA, Plotnek G, *et al.* Splice variation in the cytoplasmic domains of myelin oligodendrocyte glycoprotein affects its cellular localisation and transport. *J Neurochem* 2007; 102: 1853–1862.
5. Linington C, Bradl M, Lassmann H, *et al.* Augmentation of demyelination in rat acute allergic encephalomyelitis by circulating mouse monoclonal antibodies directed against a myelin/oligodendrocyte glycoprotein. *Am J Pathol* 1988; 130: 443–454.
6. Peschl P, Bradl M, Höftberger R, *et al.* Myelin oligodendrocyte glycoprotein: deciphering a target in inflammatory demyelinating diseases. *Front Immunol* 2017; 8: 529.
7. Iglesias A, Bauer J, Litzenburger T, *et al.* T- and B-cell responses to myelin oligodendrocyte glycoprotein in experimental autoimmune encephalomyelitis and multiple sclerosis. *Glia* 2001; 36: 220–234.
8. Waters P, Woodhall M, O'Connor KC, *et al.* MOG cell-based assay detects non-MS patients with inflammatory neurologic disease. *Neurol Neuroimmunol Neuroinflamm* 2015; 2: e89.
9. Jarius S, Ruprecht K, Kleiter I, *et al.* MOG-IgG in NMO and related disorders: a multicenter study of 50 patients. Part 2: epidemiology, clinical presentation, radiological and laboratory features, treatment responses, and long-term outcome. *J Neuroinflammation* 2016; 13: 280.
10. Juryńczyk M, Messina S, Woodhall MR, *et al.* Clinical presentation and prognosis in MOG-antibody disease: a UK study. *Brain* 2017; 140: 3128–3138.
11. Foadelli T, Matteo G, Silvia S, *et al.* Seizures and myelin oligodendrocyte glycoprotein

- (MOG) antibodies: two paradigmatic cases and a review of the literature. *Mult Scler Relat Disord* 2020; 41: 102011.
12. Sepúlveda M, Aldea M, Escudero D, *et al.* Epidemiology of NMOSD in Catalonia: influence of the new 2015 criteria in incidence and prevalence estimates. *Mult Scler* 2017; 24: 1843–1851.
  13. Hennes EM, Baumann M, Schanda K, *et al.* Prognostic relevance of MOG antibodies in children with an acquired demyelinating syndrome. *Neurology* 2017; 89: 900–908.
  14. De Mol CL, Wong YYM, van Pelt ED, *et al.* Incidence and outcome of acquired demyelinating syndromes in Dutch children: update of a nationwide and prospective study. *J Neurol* 2018; 265: 1310–1319.
  15. Armangue T, Olivé-Cirera G, Martínez-Hernández E, *et al.* Associations of paediatric demyelinating and encephalitic syndromes with myelin oligodendrocyte glycoprotein antibodies: a multicentre observational study. *Lancet Neurol* 2020; 19: 234–246.
  16. Boesen MS, Jensen PEH, Born AP, *et al.* Incidence of pediatric neuromyelitis optica spectrum disorder and myelin oligodendrocyte glycoprotein antibody-associated disease in Denmark 2008–2018: a nationwide, population-based cohort study. *Mult Scler Relat Disord* 2019; 33: 162–167.
  17. Waters P, Fadda G, Woodhall M, *et al.* Serial anti-myelin oligodendrocyte glycoprotein antibody analyses and outcomes in children with demyelinating syndromes. *JAMA Neurol.* Epub ahead of print 23 September 2019. DOI:10.1001/jamaneurol.2019.2940.
  18. De Mol CL, Wong Y, van Pelt ED, *et al.* The clinical spectrum and incidence of anti-MOG-associated acquired demyelinating syndromes in children and adults. *Mult Scler* 2019; 26: 806–814.
  19. Senanayake B, Jitrapaikulsan J, Aravinthan M, *et al.* Seroprevalence and clinical phenotype of MOG-IgG-associated disorders in Sri Lanka. *J Neurol Neurosurg Psychiatry* 2019; 90: 1381–1383.
  20. Lalive PH, Häusler MG, Maurey H, *et al.* Highly reactive anti-myelin oligodendrocyte glycoprotein antibodies differentiate demyelinating diseases from viral encephalitis in children. *Mult Scler* 2011; 17: 297–302.
  21. Brilot F, Dale RC, Selter RC, *et al.* Antibodies to native myelin oligodendrocyte glycoprotein in children with inflammatory demyelinating central nervous system disease. *Ann Neurol* 2009; 66: 833–842.
  22. Hacoheh Y, Absoud M, Deiva K, *et al.* Myelin oligodendrocyte glycoprotein antibodies are associated with a non-MS course in children. *Neurol Neuroimmunol Neuroinflamm* 2015; 2: e81.
  23. Duignan S, Wright S, Rossor T, *et al.* Myelin oligodendrocyte glycoprotein and aquaporin-4 antibodies are highly specific in children with acquired demyelinating syndromes. *Dev Med Child Neurol* 2018; 60: 958–962.
  24. Rostásy K, Mader S, Hennes EM, *et al.* Persisting myelin oligodendrocyte glycoprotein antibodies in aquaporin-4 antibody negative pediatric neuromyelitis optica. *Mult Scler* 2013; 19: 1052–1059.
  25. Hacoheh Y, Mankad K, Chong WK, *et al.* Diagnostic algorithm for relapsing acquired demyelinating syndromes in children. *Neurology* 2017; 89: 269–278.
  26. Rostásy K, Mader S, Schanda K, *et al.* Anti-myelin oligodendrocyte glycoprotein antibodies in pediatric patients with optic neuritis. *Arch Neurol* 2012; 69: 752–756.
  27. Dale RC, Tantsis EM, Merheb V, *et al.* Antibodies to MOG have a demyelination phenotype and affect oligodendrocyte cytoskeleton. *Neurol Neuroimmunol Neuroinflamm* 2014; 1: e12.
  28. Fernandez-Carbonell C, Vargas-Lowy D, Musallam A, *et al.* Clinical and MRI phenotype of children with MOG antibodies. *Mult Scler* 2016; 22: 174–184.
  29. Ketelslegers IA, Van Pelt DE, Bryde S, *et al.* Anti-MOG antibodies plead against MS diagnosis in an acquired demyelinating syndromes cohort. *Mult Scler* 2015; 21: 1513–1520.
  30. Pröbstel AK, Dornmair K, Bittner R, *et al.* Antibodies to MOG are transient in childhood acute disseminated encephalomyelitis. *Neurology* 2011; 77: 580–588.
  31. Selter RC, Brilot F, Grummel V, *et al.* Antibody responses to EBV and native MOG in pediatric inflammatory demyelinating CNS diseases. *Neurology* 2010; 74: 1711–1715.
  32. Hacoheh Y, Absoud M, Woodhall M, *et al.* Autoantibody biomarkers in childhood-acquired demyelinating syndromes: results from a national surveillance cohort. *J Neurol Neurosurg Psychiatry* 2014; 85: 456–461.
  33. Hacoheh Y, Nishimoto Y, Fukami Y, *et al.* Paediatric brainstem encephalitis associated with glial and neuronal autoantibodies. *Dev Med Child Neurol* 2016; 58: 836–841.

34. Baumann M, Sahin K, Lechner C, *et al.* Clinical and neuroradiological differences of paediatric acute disseminating encephalomyelitis with and without antibodies to the myelin oligodendrocyte glycoprotein. *J Neurol Neurosurg Psychiatry* 2015; 86: 265–272.
35. Lechner C, Baumann M, Hennes E-M, *et al.* Antibodies to MOG and AQP4 in children with neuromyelitis optica and limited forms of the disease. *J Neurol Neurosurg Psychiatry* 2016; 87: 897–905.
36. O'Connor KC, McLaughlin KA, De Jager PL, *et al.* Self-antigen tetramers discriminate between myelin autoantibodies to native or denatured protein. *Nat Med* 2007; 13: 211–217.
37. Di Pauli F, Mader S, Rostásy K, *et al.* Temporal dynamics of anti-MOG antibodies in CNS demyelinating diseases. *Clin Immunol* 2011; 138: 247–254.
38. Mader S, Gredler V, Schanda K, *et al.* Complement activating antibodies to myelin oligodendrocyte glycoprotein in neuromyelitis optica and related disorders. *J Neuroinflammation* 2011; 8: 184–214.
39. Kitley J, Waters P, Woodhall M, *et al.* Neuromyelitis optica spectrum disorders with aquaporin-4 and myelin-oligodendrocyte glycoprotein antibodies: a comparative study. *JAMA Neurol* 2014; 71: 276–283.
40. Sato DK, Callegaro D, Lana-Peixoto MA, *et al.* Distinction between MOG antibody-positive and AQP4 antibody-positive NMO spectrum disorders. *Neurology* 2014; 82: 474–481.
41. Martinez-Hernandez E, Sepúlveda M, Rostásy K, *et al.* Antibodies to aquaporin 4, myelin-oligodendrocyte glycoprotein, and the glycine receptor  $\alpha 1$  subunit in patients with isolated optic neuritis. *JAMA Neurol* 2015; 72: 187–193.
42. Ramberger M, Bsteh G, Schanda K, *et al.* NMDA receptor antibodies. *Neurol Neuroimmunol Neuroinflamm* 2015; 2: e141–e145.
43. Jarius S, Ruprecht K, Kleiter I, *et al.* MOG-IgG in NMO and related disorders: a multicenter study of 50 patients. Part 1: frequency, syndrome specificity, influence of disease activity, long-term course, association with AQP4-IgG, and origin. *J Neuroinflammation* 2016; 13: 279.
44. Piccolo L, Woodhall M, Tackley G, *et al.* Isolated new onset “atypical” optic neuritis in the NMO clinic: serum antibodies, prognoses and diagnoses at follow-up. *J Neurol* 2016; 263: 370–379.
45. Sepúlveda M, Armangue T, Sola-Valls N, *et al.* Neuromyelitis optica spectrum disorders: Comparison according to the phenotype and serostatus. *Neurol Neuroimmunol Neuroinflamm* 2016; 3: e225.
46. Hyun JW, Woodhall MR, Kim SH, *et al.* Longitudinal analysis of myelin oligodendrocyte glycoprotein antibodies in CNS inflammatory diseases. *J Neurol Neurosurg Psychiatry* 2017; 88: 811–817.
47. Titulaer MJ, Höftberger R, Iizuka T, *et al.* Overlapping demyelinating syndromes and anti-N-methyl-D-aspartate receptor encephalitis. *Ann Neurol* 2014; 75: 411–428.
48. Mariotto S, Ferrari S, Monaco S, *et al.* Clinical spectrum and IgG subclass analysis of anti-myelin oligodendrocyte glycoprotein antibody-associated syndromes: a multicenter study. *J Neurol* 2017; 264: 2420–2430.
49. Cobo-Calvo Á, Ruiz A, D'Indy H, *et al.* MOG antibody-related disorders: common features and uncommon presentations. *J Neurol* 2017; 264: 1945–1955.
50. López-Chiriboga AS, Majed M, Fryer J, *et al.* Association of MOG-IgG serostatus with relapse after acute disseminated encephalomyelitis and proposed diagnostic criteria for MOG-IgG-associated disorders. *JAMA Neurol* 2018; 75: 1355–1363.
51. Pandit L, Sato DK, Mustafa S, *et al.* Relapsing optic neuritis and isolated transverse myelitis are the predominant clinical phenotypes for patients with antibodies to myelin oligodendrocyte glycoprotein in India. *Mult Scler J Exp Transl Clin* 2016; 2: 2055217316675634.
52. Lalive PH, Menge T, Delarasse C, *et al.* Antibodies to native myelin oligodendrocyte glycoprotein are serologic markers of early inflammation in multiple sclerosis. *Proc Natl Acad Sci U S A* 2006; 103: 2280–2285.
53. McLaughlin KA, Chitnis T, Newcombe J, *et al.* Age-dependent B cell autoimmunity to a myelin surface antigen in pediatric multiple sclerosis. *J Immunol* 2009; 183: 4067–4076.
54. Pröbstel A-K, Rudolf G, Dornmair K, *et al.* Anti-MOG antibodies are present in a subgroup of patients with a neuromyelitis optica phenotype. *J Neuroinflammation* 2015; 12: 46–47.
55. Yan Y, Li Y, Fu Y, *et al.* Autoantibody to MOG suggests two distinct clinical subtypes of NMOSD. *Sci China Life Sci* 2016; 59: 1270–1281.
56. van Pelt ED, Wong YYM, Ketelslegers IA, *et al.* Neuromyelitis optica spectrum



- disorders: comparison of clinical and magnetic resonance imaging characteristics of AQP4-IgG versus MOG-IgG seropositive cases in the Netherlands. *European J Neurol* 2016; 23: 580–587.
57. Jitprapaikulsan J, Chen JJ, Flanagan EP, *et al.* Aquaporin-4 and myelin oligodendrocyte glycoprotein autoantibody status predict outcome of recurrent optic neuritis. *Ophthalmology* 2018; 125: 1628–1637.
  58. Jitprapaikulsan J, López-Chiriboga AS, Flanagan EP, *et al.* Novel glial targets and recurrent longitudinally extensive transverse myelitis. *JAMA Neurol* 2018; 75: 892–895.
  59. Kitley J, Woodhall M, Waters P, *et al.* Myelin oligodendrocyte glycoprotein antibodies in adults with a neuromyelitis optica phenotype. *Neurology* 2012; 79: 1273–1277.
  60. Woodhall M, Çoban A, Waters P, *et al.* Glycine receptor and myelin oligodendrocyte glycoprotein antibodies in Turkish patients with neuromyelitis optica. *J Neurol Sci* 2013; 335: 221–223.
  61. Tanaka M and Tanaka K. Anti-MOG antibodies in adult patients with demyelinating disorders of the central nervous system. *J Neuroimmunol* 2014; 270: 98–99.
  62. Höftberger R, Sepúlveda M, Armangue T, *et al.* Antibodies to MOG and AQP4 in adults with neuromyelitis optica and suspected limited forms of the disease. *Mult Scler* 2015; 21: 866–874.
  63. Kim SM, Woodhall MR, Kim JS, *et al.* Antibodies to MOG in adults with inflammatory demyelinating disease of the CNS. *Neurol Neuroimmunol Neuroinflamm* 2015; 2: e163.
  64. Siritho S, Sato DK, Kaneko K, *et al.* The clinical spectrum associated with myelin oligodendrocyte glycoprotein antibodies (anti-MOG-Ab) in Thai patients. *Mult Scler* 2016; 22: 964–968.
  65. Hamid SHM, Whittam D, Mutch K, *et al.* What proportion of AQP4-IgG-negative NMO spectrum disorder patients are MOG-IgG positive? A cross sectional study of 132 patients. *J Neurol* 2017; 264: 2088–2094.
  66. Mader S, Jeganathan V, Arinuma Y, *et al.* Understanding the antibody repertoire in neuropsychiatric systemic lupus erythematosus and neuromyelitis optica spectrum disorder: do they share common targets? *Arthritis Rheumatol* 2018; 70: 277–286.
  67. Zhou L, Huang Y, Li H, *et al.* MOG-antibody associated demyelinating disease of the CNS: a clinical and pathological study in Chinese Han patients. *J Neuroimmunol* 2017; 305: 19–28.
  68. Zhao G, Chen Q, Huang Y, *et al.* Clinical characteristics of myelin oligodendrocyte glycoprotein seropositive optic neuritis: a cohort study in Shanghai, China. *J Neurol* 2018; 265: 33–40.
  69. Chalmoukou K, Alexopoulos H, Akrivou S, *et al.* Anti-MOG antibodies are frequently associated with steroid-sensitive recurrent optic neuritis. *Neurol Neuroimmunol Neuroinflamm* 2015; 2: e131.
  70. Soelberg K, Jarius S, Skejoe H, *et al.* A population-based prospective study of optic neuritis. *Mult Scler* 2017; 23: 1893–1901.
  71. Chen JJ, Tobin WO, Majed M, *et al.* Prevalence of myelin oligodendrocyte glycoprotein and aquaporin-4-IgG in patients in the optic neuritis treatment trial. *JAMA Ophthalmol* 2018; 136: 419–422.
  72. Ramanathan S, Reddel SW, Henderson A, *et al.* Antibodies to myelin oligodendrocyte glycoprotein in bilateral and recurrent optic neuritis. *Neurol Neuroimmunol Neuroinflamm* 2014; 1: e40.
  73. Cobo-Calvo Á, Sepúlveda M, Bernard-Valnet R, *et al.* Antibodies to myelin oligodendrocyte glycoprotein in aquaporin 4 antibody seronegative longitudinally extensive transverse myelitis: clinical and prognostic implications. *Mult Scler* 2016; 22: 312–319.
  74. Bouzar M, Daoudi S, Hattab S, *et al.* Neuromyelitis optica spectrum disorders with antibodies to myelin oligodendrocyte glycoprotein or aquaporin-4: clinical and paraclinical characteristics in Algerian patients. *J Neurol Sci* 2017; 381: 240–244.
  75. Costa BKD, Passos GRD, Becker J, *et al.* MOG-IgG associated optic neuritis is not multiple sclerosis. *Arq Neuropsiquiatr* 2017; 75: 687–691.
  76. Thompson AJ, Baranzini SE, Geurts J, *et al.* Multiple sclerosis. *Lancet* 2018; 391: 1622–1636.
  77. Wingerchuk DM, Lennon VA, Lucchinetti CF, *et al.* The spectrum of neuromyelitis optica. *Lancet Neurol* 2007; 6: 805–815.
  78. Cobo-Calvo Á, Ruiz A, Maillart E, *et al.* Clinical spectrum and prognostic value of CNS MOG autoimmunity in adults: the MOGADOR study. *Neurology* 2018; 90: e1858–e1869.
  79. Akaishi T, Nakashima I, Takeshita T, *et al.* Different etiologies and prognoses of optic

- neuritis in demyelinating diseases. *J Neuroimmunol* 2016; 299: 152–157.
80. Juryńczyk M, Geraldes R, Probert F, *et al.* Distinct brain imaging characteristics of autoantibody-mediated CNS conditions and multiple sclerosis. *Brain* 2017; 140: 617–627.
  81. Sepúlveda M, Armangue T, Martinez-Hernandez E, *et al.* Clinical spectrum associated with MOG autoimmunity in adults: significance of sharing rodent MOG epitopes. *J Neurol* 2016; 263: 1349–1360.
  82. Baumann M, Grams A, Djurdjevic T, *et al.* MRI of the first event in pediatric acquired demyelinating syndromes with antibodies to myelin oligodendrocyte glycoprotein. *J Neurol* 2018; 265: 845–855.
  83. Hacohen Y, Rossor T, Mankad K, *et al.* “Leukodystrophy-like” phenotype in children with myelin oligodendrocyte glycoprotein antibody-associated disease. *Dev Med Child Neurol* 2018; 60: 417–423.
  84. Hacohen Y, Wong YY, Lechner C, *et al.* Disease course and treatment responses in children with relapsing myelin oligodendrocyte glycoprotein antibody-associated disease. *JAMA Neurol* 2018; 75: 478–487.
  85. Ramanathan S, Mohammad S, Tantsis E, *et al.* Clinical course, therapeutic responses and outcomes in relapsing MOG antibody-associated demyelination. *J Neurol Neurosurg Psychiatry* 2018; 89: 127–137.
  86. Biotti D, Bonneville F, Tournaire E, *et al.* Optic neuritis in patients with anti-MOG antibodies spectrum disorder: MRI and clinical features from a large multicentric cohort in France. *J Neurol* 2017; 264: 2173–2175.
  87. Jarius S, Kleiter I, Ruprecht K, *et al.* MOG-IgG in NMO and related disorders: a multicenter study of 50 patients. Part 3: brainstem involvement - frequency, presentation and outcome. *J Neuroinflammation* 2016; 13: 281.
  88. Akaishi T, Konno M, Nakashima I, *et al.* Intractable hiccup in demyelinating disease with anti-myelin oligodendrocyte glycoprotein (MOG) antibody. *Intern Med* 2016; 55: 2905–2906.
  89. Kunchok A, Krecke KN, Flanagan EP, *et al.* Does area postrema syndrome occur in myelin oligodendrocyte glycoprotein-IgG-associated disorders (MOGAD)? *Neurology* 2020; 94: 85–88.
  90. Wingerchuk DM, Banwell B, Bennett JL, *et al.* International consensus diagnostic criteria for neuromyelitis optica spectrum disorders. *Neurology* 2015; 85: 177–189.
  91. Juryńczyk M, Tackley G, Kong Y, *et al.* Brain lesion distribution criteria distinguish MS from AQP4-antibody NMOSD and MOG-antibody disease. *J Neurol Neurosurg Psychiatry* 2017; 88: 132–136.
  92. Kim W, Park MS, Lee SH, *et al.* Characteristic brain magnetic resonance imaging abnormalities in central nervous system aquaporin-4 autoimmunity. *Mult Scler* 2010; 16: 1229–1236.
  93. Dubey D, Pittock SJ, Krecke KN, *et al.* Clinical, radiologic, and prognostic features of myelitis associated with myelin oligodendrocyte glycoprotein autoantibody. *JAMA Neurol* 2019; 76: 301–309.
  94. Asnafi S, Morris PP, Sechi E, *et al.* The frequency of longitudinally extensive transverse myelitis in MS: a population-based study. *Mult Scler Relat Disord* 2020; 37: 101487.
  95. Ramanathan S, Prelog K, Barnes EH, *et al.* Radiological differentiation of optic neuritis with myelin oligodendrocyte glycoprotein antibodies, aquaporin-4 antibodies, and multiple sclerosis. *Mult Scler* 2016; 22: 470–482.
  96. Jarius S, Paul F, Franciotta D, *et al.* Cerebrospinal fluid findings in aquaporin-4 antibody positive neuromyelitis optica: results from 211 lumbar punctures. *J Neurol Sci* 2011; 306: 82–90.
  97. Peng C, Wang W, Xu Q, *et al.* Thickness of macular inner retinal layers and peripapillary retinal nerve fibre layer in neuromyelitis optica spectrum optic neuritis and isolated optic neuritis with one episode. *Acta Ophthalmol* 2017; 95: 583–590.
  98. Pache F, Zimmermann H, Mikolajczak J, *et al.* MOG-IgG in NMO and related disorders: a multicenter study of 50 patients. Part 4: afferent visual system damage after optic neuritis in MOG-IgG-seropositive versus AQP4-IgG-seropositive patients. *J Neuroinflammation* 2016; 13: 282.
  99. Oertel FC, Outteryck O, Knier B, *et al.* Optical coherence tomography in myelin-oligodendrocyte-glycoprotein antibody-seropositive patients: a longitudinal study. *J Neuroinflammation* 2019; 16: 154–159.
  100. Mariano R, Messina S, Kumar K, *et al.* Comparison of clinical outcomes of transverse myelitis among adults with myelin oligodendrocyte glycoprotein antibody vs

- aquaporin-4 antibody disease. *JAMA Netw Open* 2019; 2: e1912732.
101. Thompson AJ, Banwell BL, Barkhof F, *et al.* Diagnosis of multiple sclerosis: 2017 revisions of the McDonald criteria. *Lancet Neurol*. Epub ahead of print 21 December 2017. DOI: 10.1016/S1474-4422(17)30470-2.
  102. Goodin DS. The epidemiology of multiple sclerosis: insights to a causal cascade. *Handb Clin Neurol* 2016; 138: 173–206.
  103. Filippi M, Bar-Or A, Piehl F, *et al.* Multiple sclerosis. *Nat Rev Dis Primers* 2018; 4: 43.
  104. Bennett JL, Lam C, Kalluri SR, *et al.* Intrathecal pathogenic anti-aquaporin-4 antibodies in early neuromyelitis optica. *Ann Neurol* 2009; 66: 617–629.
  105. Papadopoulos MC, Bennett JL and Verkman AS. Treatment of neuromyelitis optica: state-of-the-art and emerging therapies. *Nat Rev Neurol* 2014; 10: 493–506.
  106. Wingerchuk DM and Weinshenker BG. Neuromyelitis optica (Devic's syndrome). *Handb Clin Neurol* 2014; 122: 581–599.
  107. Shor N, Aboab J, Maillart E, *et al.* Clinical, imaging and follow-up study of optic neuritis associated with myelin oligodendrocyte glycoprotein antibody: a multicentre study of 62 adult patients. *Eur J Neurol* 2020; 27: 384–391.
  108. Jarius S, Paul F, Aktas O, *et al.* MOG encephalomyelitis: international recommendations on diagnosis and antibody testing. *J Neuroinflammation* 2018; 15: 134.
  109. Zhao Y, Tan S, Chan TCY, *et al.* Clinical features of demyelinating optic neuritis with seropositive myelin oligodendrocyte glycoprotein antibody in Chinese patients. *Br J Ophthalmol* 2018; 102: 1372–1377.
  110. Sechi E, Krecke KN, Pittock SJ, *et al.* Frequency and characteristics of MRI-negative myelitis associated with MOG autoantibodies. *Mult Scler*. Epub ahead of print 27 February 2020. DOI:10.1177/1352458520907900.
  111. Fujimori J, Takai Y, Nakashima I, *et al.* Bilateral frontal cortex encephalitis and paraparesis in a patient with anti-MOG antibodies. *J Neurol Neurosurg Psychiatry* 2017; 88: 534–536.
  112. Ikeda T, Yamada K, Ogawa R, *et al.* The pathological features of MOG antibody-positive cerebral cortical encephalitis as a new spectrum associated with MOG antibodies: a case report. *J Neurol Sci* 2018; 392: 113–115.
  113. Hamid SHM, Whittam D, Saviour M, *et al.* Seizures and encephalitis in myelin oligodendrocyte glycoprotein IgG disease vs aquaporin 4 IgG disease. *JAMA Neurol* 2018; 75: 65–71.
  114. Ogawa R, Nakashima I, Takahashi T, *et al.* MOG antibody-positive, benign, unilateral, cerebral cortical encephalitis with epilepsy. *Neurol Neuroimmunol Neuroinflamm* 2017; 4: e322.
  115. Tao R, Qin C, Chen M, *et al.* Unilateral cerebral cortical encephalitis with epilepsy: a possible special phenotype of MOG antibody-associated disorders. *Int J Neurosci* 2020; 26: 1–5.
  116. Martinez-Hernandez E, Guasp M, García-Serra A, *et al.* Clinical significance of anti-NMDAR concurrent with glial or neuronal surface antibodies. *Neurology* 2020; 94: e2302–e2310.
  117. Lipton SA. NMDA receptors, glial cells, and clinical medicine. *Neuron* 2006; 50: 9–11.
  118. Reindl M, Di Pauli F, Rostásy K, *et al.* The spectrum of MOG autoantibody-associated demyelinating diseases. *Nat Rev Neurol* 2013; 9: 455–461.
  119. Ramanathan S, O'grady GL, Malone S, *et al.* Isolated seizures during the first episode of relapsing myelin oligodendrocyte glycoprotein antibody-associated demyelination in children. *Dev Med Child Neurol* 2019; 61: 610–614.
  120. Cobo-Calvo Á, Aygnac X, Kerschen P, *et al.* Cranial nerve involvement in patients with MOG antibody-associated disease. *Neurol Neuroimmunol Neuroinflamm* 2019; 6: e543.
  121. Shen Y, Cheng Z and Zhou C. Bilateral trigeminal root entry zone enhancement in MOG-IgG-associated brainstem encephalitis. *Neurol Sci* 2019; 40: 1083–1085.
  122. Kawakami S, Akamine S, Chong PF, *et al.* Isolated cranial neuritis of the oculomotor nerve: expanding the MOG phenotype? *Mult Scler Relat Disord* 2020; 41: 102040.
  123. Vazquez Do Campo R, Stephens A, Marin Collazo IV, *et al.* MOG antibodies in combined central and peripheral demyelination syndromes. *Neurol Neuroimmunol Neuroinflamm* 2018; 5: e503.
  124. Cobo-Calvo Á, Sepúlveda M, D'Indy H, *et al.* Usefulness of MOG-antibody titres at first episode to predict the future clinical course in adults. *J Neurol* 2019; 266: 806–815.
  125. Bonnan M, Valentino R, Debeugny S, *et al.* Short delay to initiate plasma exchange is the

- strongest predictor of outcome in severe attacks of NMO spectrum disorders. *J Neurol Neurosurg Psychiatry* 2018; 89: 346–351.
126. Thompson J, Bi M, Murchison AG, *et al.* The importance of early immunotherapy in patients with faciobrachial dystonic seizures. *Brain* 2018; 141: 348–356.
  127. Hacoen Y and Banwell B. Treatment approaches for MOG-Ab-associated demyelination in children. *Curr Treat Options Neurol* 2019; 21: 2–14.
  128. Cobo-Calvo Á, Sepúlveda M, Rollot F, *et al.* Evaluation of treatment response in adults with relapsing MOG-Ab-associated disease. *J Neuroinflammation* 2019; 16: 134.
  129. Durozard P, Rico A, Boutiere C, *et al.* Comparison of the response to rituximab between myelin oligodendrocyte glycoprotein and aquaporin-4 antibody diseases. *Ann Neurol* 2020; 87: 256–266.
  130. Pittock SJ, Berthele A, Fujihara K, *et al.* Eculizumab in aquaporin-4-positive neuromyelitis optica spectrum disorder. *N Engl J Med* 2019; 381: 614–625.
  131. Cree BAC, Bennett JL, Kim HJ, *et al.* Inebilizumab for the treatment of neuromyelitis optica spectrum disorder (N-MOMentum): a double-blind, randomised placebo-controlled phase 2/3 trial. *Lancet* 2019; 394: 1352–1363.
  132. Yamamura T, Kleiter I, Fujihara K, *et al.* Trial of satralizumab in neuromyelitis optica spectrum disorder. *N Engl J Med* 2019; 381: 2114–2124.
  133. Li S, Ren H, Xu Y, *et al.* Long-term efficacy of mycophenolate mofetil in myelin oligodendrocyte glycoprotein antibody-associated disorders: a prospective study. *Neurol Neuroimmunol Neuroinflamm* 2020; 7: e705.
  134. Reindl M and Waters P. Myelin oligodendrocyte glycoprotein antibodies in neurological disease. *Nat Rev Neurol* 2019; 15: 89–102.
  135. Waters PJ, Komorowski L, Woodhall M, *et al.* A multicenter comparison of MOG-IgG cell-based assays. *Neurology* 2019; 92: e1250–e1255.
  136. Gastaldi M, Zardini E, Scaranzin S, *et al.* Autoantibody diagnostics in neuroimmunology: experience from the 2018 Italian neuroimmunology association external quality assessment program. *Front Neurol* 2019; 10: 1385.
  137. Reindl M, Schanda K, Woodhall M, *et al.* International multicenter examination of MOG antibody assays. *Neurol Neuroimmunol Neuroinflamm* 2020; 7: e674.
  138. Jarius S, Ruprecht K, Stellmann JP, *et al.* MOG-IgG in primary and secondary chronic progressive multiple sclerosis: a multicenter study of 200 patients and review of the literature. *J Neuroinflammation* 2018; 15: 88–95.
  139. Cobo-Calvo Á, D’Indy H, Ruiz A, *et al.* Frequency of myelin oligodendrocyte glycoprotein antibody in multiple sclerosis: a multicenter cross-sectional study. *Neurol Neuroimmunol Neuroinflamm* 2020; 7: e649.
  140. Mariotto S, Gajofatto A, Batzu L, *et al.* Relevance of antibodies to myelin oligodendrocyte glycoprotein in CSF of seronegative cases. *Neurology* 2019; 93: e1867–e1872.
  141. Höftberger R, Guo Y, Flanagan EP, *et al.* The pathology of central nervous system inflammatory demyelinating disease accompanying myelin oligodendrocyte glycoprotein autoantibody. *Acta Neuropathol* 2020; 139: 875–892.
  142. Takai Y, Misu T, Kaneko K, *et al.* Myelin oligodendrocyte glycoprotein antibody-associated disease: an immunopathological study. *Brain* 2020; 143: 1431–1446.
  143. Kaneko K, Sato DK, Nakashima I, *et al.* CSF cytokine profile in MOG-IgG+ neurological disease is similar to AQP4-IgG+ NMOSD but distinct from MS: a cross-sectional study and potential therapeutic implications. *J Neurol Neurosurg Psychiatry* 2018; 89: 927–936.
  144. Hofer LS, Mariotto S, Wurth S, *et al.* Distinct serum and cerebrospinal fluid cytokine and chemokine profiles in autoantibody-associated demyelinating diseases. *Mult Scler J Exp Transl Clin* 2019; 5: 2055217319848463.