

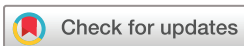Novel drug-repository contact lens for prolonging the antimicrobial-cornea interaction for bacterial keratitis treatment: randomised controlled trial results

Lional Raj Daniel Raj Ponniah , Velupillai Ranilakshmi, Heber Anandan, Jeyakumar Caroline, Antonysamy Arulanandham

To cite: Daniel Raj Ponniah LR, Ranilakshmi V, Anandan H, *et al*. Novel drug-repository contact lens for prolonging the antimicrobial-cornea interaction for bacterial keratitis treatment: randomised controlled trial results. *BMJ Open Ophthalmology* 2022;**7**:e001093. doi:10.1136/bmjophth-2022-001093

► Additional supplemental material is published online only. To view, please visit the journal online (<http://dx.doi.org/10.1136/bmjophth-2022-001093>).

Received 16 June 2022
Accepted 13 October 2022



© Author(s) (or their employer(s)) 2022. Re-use permitted under CC BY-NC. No commercial re-use. See rights and permissions. Published by BMJ.

Ophthalmology, Dr Agarwal's Eye Hospital, Tirunelveli, Tamil Nadu, India

Correspondence to

Dr Lional Raj Daniel Raj Ponniah; drionalraj@gmail.com

ABSTRACT

Background/Aims Microbial keratitis can cause unilateral blindness, but the drug delivery treatment options are poor. Therefore, this study evaluated the efficacy of a novel therapeutic drug-depository contact lens (DDCL) for bacterial keratitis (BK) treatment. The lens was designed to increase the corneal lesion-antimicrobial drug interaction time.

Methods Patients with BK were randomised (1:1) into two groups: topical antimicrobial treatment only (group 1) and DDCL plus antimicrobial treatment (group 2). Both groups received 0.5% moxifloxacin. We evaluated BK recovery, anterior chamber (AC) reactions, corneal haze and pain (on a 10-point scale) 12 hours and 1, 3, 5 and 14 days after treatment.

Results The baseline corneal-infiltration (ie, BK severity) values were comparable for groups 1 (18 cases) and 2 (17 cases) ($p=0.92$). After 12 hours, the scores improved in both groups and continued to improve throughout the follow-up period; the improvements were more pronounced in group 2 than in group 1 (all $p<0.05$). Complete recovery occurred on days 14 and 5 in groups 1 and 2, respectively. Furthermore, the AC reaction resolved by day 3 in group 2. The baseline pain scores were also comparable between groups 1 and 2 ($p=0.52$) and decreased throughout the follow-up period (all $p<0.05$); the decrease was more pronounced in group 2.

Conclusions Novel DDCLs augment the drug-lesion interaction time by prolonging corneal antimicrobial availability, which hastens corneal healing in BK. Thus, a DDCL may decrease the antibiotic regimen and improve patient tolerance, eliminating the necessity for a loading dose.

Trial registration number CTRI/2020/08/027088.

INTRODUCTION

Microbial keratitis (MK) can occur after ocular trauma and subsequent infection, causing unilateral blindness in 1.5 to 2 million corneal ulceration cases globally per year.¹ Annually in the USA, general practices treat 1 million cases of infectious keratitis, and emergency room physicians treat 58 000 cases.²

The human cornea naturally resists infection; thus, bacterial keratitis (BK) is rare

WHAT IS ALREADY KNOWN ON THIS TOPIC

- ⇒ Microbial keratitis is prevalent and causes unilateral blindness in low-income and middle-income countries owing to poor drug delivery options and precorneal factors that negatively affect the drug-cornea interaction time.
- ⇒ Currently, an intensive loading dose with topical agents is the primary treatment option.

WHAT THIS STUDY ADDS

- ⇒ Drug-depository contact lenses extend the drug-lesion contact time, improving the bacterial keratitis recovery time and early pain relief.

HOW THIS STUDY MIGHT AFFECT RESEARCH, PRACTICE OR POLICY

- ⇒ Drug-depository contact lenses reduce the loading-dose burden and improve treatment tolerance; consequently, treatment patterns may change.

without ocular trauma or foreign body entry. However, other factors, such as poor access to healthcare and occupational hazards associated with farming and agriculture, increase the BK incidence rate in lower-income countries. For example, reports indicate that 113 cases per 100 000 individuals (113/100 000) occur in Madurai, Tamil Nadu, India, 339/100 000 occur in Bhutan, 710/100 000 occur in Burma and 799/100 000 occur in Nepal.³ Furthermore, predisposing factors may alter the ocular surface's defence mechanisms, permitting bacteria to invade the cornea, including contact lens wear, trauma, corneal surgery, ocular surface disease, systemic diseases and immunosuppression, increasing the BK incidence rate,⁴ especially in low-income and middle-income and tropical countries.

Topical antibiotic eye drops treat BK by inundating the tissue with a high concentration of medication, called a loading dose. Furthermore, antimicrobial ointments used

before sleep are options for less severe cases or adjunctive therapy. However, ointments have poor solubility and corneal penetration, lessening the therapeutic effect.⁵ Nonetheless, antibiotic therapy reduces pain and the discharge amount, decreases eyelid oedema and conjunctival injection, consolidates and sharpens the perimeter boundary of the stromal infiltrate, reduces stromal oedema and infiltration, decreases the number of anterior chamber (AC) cells, improves the initial re-epithelialisation and ceases progressive corneal thinning.⁶

As mentioned, topical corneal ophthalmic drugs provide suboptimal treatment due to anatomical barriers. The cul-de-sac transiently retains only 30 µL of the administered eye drop. Tear film restoration occurs quite rapidly, within 2–3 min. However, most topically administered solutions are entirely washed away within 15–30 s. Thus, the amount of time the drug interacts with the absorptive membranes is extremely low, and the eye only receives approximately 5% of the administered dose. Therefore, reaching the deep corneal and intraocular tissues is the primary rate-limiting step for healing.⁷ However, Callegan *et al*⁸ reported two novel drug delivery systems for BK in an animal model; both were well tolerated and non-toxic. First was a collagen shield, designed initially as a bandage lens to prolong drug contact with the cornea. The second was transcorneal iontophoresis, which induced drug migration in the form of ions to the cornea.

Moreover, a new drug-delivery mechanism, called the drug-depository contact lens (DDCL; Hyper-CL (Acofilcon A)), has emerged. These therapeutic, soft contact lenses are used only briefly to protect the cornea by promoting corneal healing and alleviating corneal pain. For example, DDCLs have been used for acute or chronic corneal injuries and after cataract extraction. Furthermore, chronic corneal oedema from endothelial dysfunction has been improved by using the Hyper-CL lenses with an ophthalmic solution.

The efficacy of these new lenses for BK treatment remains unclear. Therefore, this study evaluated the effectiveness of DDCLs for BK treatment. We hypothesised that these lenses might improve the drug-cornea interaction time, facilitating BK recovery.

MATERIALS AND METHODS

Patient selection

We designed an open-labelled randomised controlled study to compare topical antimicrobial administration and antimicrobial administration with DDCLs for treating BK. The study was conducted at the Cornea and Ocular Surface Diseases Clinic at Dr Agarwal's Eye Hospital and Research Institute in Tirunelveli, South India. This study was registered in the Clinical Trials Registry-India (CTRI/2020/08/027088).

Patients with BK were enrolled based on the inclusion and exclusion criteria, then a computer-generated random table for treatment grouped the participants in a

1:1 ratio. We enrolled 40 participants since the study was an interventional exploratory medical device trial.

Men and women between 18 and 86 years old with BK in one eye and no prior antibiotic treatment were included. Furthermore, all enrolled patients had a BK and average infiltration length of at least grade 2 (online supplemental table 1), an average epithelial defect length of ≥ 1 mm, and best-corrected visual acuity of 6/60 or better in the uninvolved eye.

Patients with perforation or impending perforation of the cornea, signs of inflammation in both eyes, severe itching suggesting an allergic reaction, subepithelial infiltrate suggesting viral infection, a dendrite-like ulcer or suspected herpetic keratitis, previous penetrating keratoplasty, no light perception in the affected eye, active intraocular infection, infiltration suggesting anything other than bacterial infection (eg, fungal or parasitic aetiologies), a history of corneal transplant, inlays or refractive surgeries, glaucoma shunts or filters and lid deformities were excluded.

Interventional medical device

The DDCL (Hyper-CL) consists of 41% Acofilcon A and 59% water by weight when immersed in buffered saline solution. The Hyper-CL lens creates a thin tear film reservoir of drug between the back surface of the contact lens and the anterior corneal surface. The fenestrations increase tear film exchange, potentially increasing the accessibility and overall interaction time between ophthalmic solutions (ie, antimicrobial drops) and the cornea's centre. Therefore, the administered antibiotic drop migrates through the fenestration into the space between the lens and the cornea, extending the medication's interaction time.

Study intervention

The participants were split into two treatment groups. Group 1 was administered conventional treatment with topical antibiotics in the infected eye by the investigator until the lesion resolved. Group 2 was also administered conventional treatment with topical antibiotics but with the Hyper-CL lens. The investigator inserted the DDCL and administered the antibiotics. The participant used the DDCL until clinical signs of healing appeared. The patient did not remove the lens from the eye at night, and if the lens was lost from the eye by accident during the treatment period, a new lens was inserted. The lens remained in the participant's eye for at least 72 hours, and then the subject continued with the standard antibiotic treatment regimen; the investigator removed the lens.

Antibiotics regimen

Both treatment groups received a monotherapy of fourth-generation fluoroquinolones (0.5% moxifloxacin (ie, vigamox)) administered every 2 hours during waking hours for the first 2 days (ie, ten times per day), followed

by every 4 hours during waking hours for the next 12 days (ie, five times per day).

Study procedures

Each participant was involved with the study for approximately 14 days, starting from the time of enrolment and informed consent document signing. Each participant was hospitalised for a minimum of 72 (± 12) hours post-treatment initiation and presented to the hospital for post-treatment follow-up on days 5 and 14.

Study outcomes

The primary end point was the BK severity score change from baseline to day 14. The secondary end points were the BK severity score improvement (defined as a decrease of at least 2 points) duration and changes to the BK severity, pain and visual acuity scores compared with the baseline visit.

Statistical methods

BK severity score changes were evaluated by independent sample t-tests. Differences between the treatments were assessed by log-rank tests. Changes from baseline regarding the BK severity, pain and visual acuity scores were evaluated by independent sample t-tests for each follow-up day. All statistical tests were two-sided with nominal p values and a two-sided 95% CI. The data were analysed using the IBM SPSS statistics V.21.

RESULTS

Patients

We randomised 40 cases (1:1) into two groups, but 2 cases in group 1 and 3 cases in group 2 were excluded as they did not complete follow-up on specified time periods.

Therefore, we included 18 cases in group 1 and 17 cases in group 2 between August 2020 and June 2021.

In group 1 (antibiotics only), 13 cases (72 %) were Gram-positive infections (8 *Staphylococcus* cases (44%), 3 *Pneumococcus* (16.6%) and 2 *Streptococcus* (11%)) and 5 cases (28%) were Gram-negative. In group 2 (with DDCL), 12 cases (70.6%) were Gram-positive infections (6 cases *Staphylococcus* cases (35.4%) and 3 cases each (17.6%) of *Streptococcus* and *Pneumococcus*) and 5 cases (29.4%) were Gram-negative. All cases were identified and diagnosed by microbiological studies (eg, Gram staining) and other bacterial culture and antibiogram studies, as necessary.

BK severity and visual acuity

Table 1 presents the BK infiltration and improvement scores. The mean corneal infiltration scores (ie, BK severity score) at presentation were 2.63 (± 1.06) mm and 2.66 (± 0.75) in groups 1 and 2, respectively ($p=0.92$). After 12 hours, the mean improvement scores significantly differed between group 1 (0.04 mm) and group 2 (0.27 mm; $p=0.02$). This trend continued until day 14 when the lesions in both groups were completely healed ($p=0.62$) (figure 1 and online supplemental figures 1 and 2).

Online supplemental table 2 presents the visual acuity scores. On day 1, a mean one-line improvement was observed in both groups. Visual acuity improved by another line on day 3 in group 2 but not in group 1.

AC reaction and corneal haze

Table 2 presents the AC reaction and corneal haze changes. The mean baseline AC reaction scores were 1.94 (± 1.06) and 1.88 (± 0.33) in groups 1 and 2 ($p=0.818$).

Table 1 Bacterial keratitis infiltration and improvement scores over time

Group	Visit	Infiltration score		Improvement score		P value
		Mean	SD	Mean	SD	
1	Baseline	2.63	1.06	–		0.92
2		2.66	0.75			
1	12 hours	2.58	1.06	0.04	0.13	0.02
2		2.38	0.84	0.27	0.38	
1	D1	2.44	1.15	0.18	0.27	<0.0001
2		1.72	0.72	0.93	0.50	
1	D3	1.69	0.88	0.93	0.39	<0.0001
2		0.75	0.59	1.90	0.54	
1	D5	1.13	0.99	1.50	0.56	<0.0001
2		0.20	0.39	2.45	0.57	
1	D14	0.11	0.32	2.51	0.95	0.62
2		0.00	0.00	2.66	0.75	

Group 1 (antibiotic only, n=18) and group 2 (antibiotic+drug-depository contact lens, n=17).
D, day.;

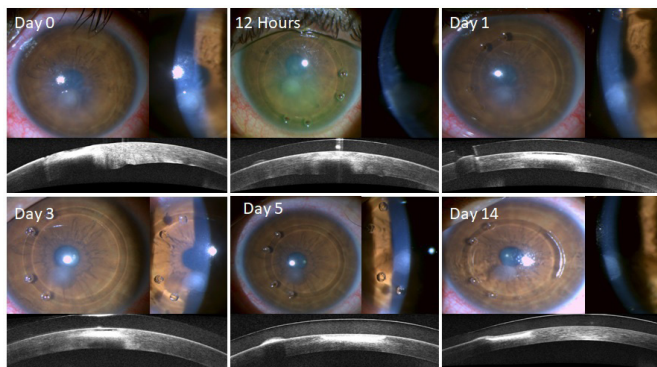


Figure 1 Representative images of corneal healing over time after bacterial keratitis infection. The treatment included a drug-depository contact lens and antibiotics along with respective corneal optical coherence tomography images.

On day 3, the AC reaction score significantly decreased in both groups. However, the difference was more pronounced in group 2 than in group 1. Corneal haze significantly improved in both groups throughout the follow-up period.

Pain

At baseline, the mean pain scores were 7.89 (± 1.08) and 7.65 (± 1.11) in groups 1 and 2, respectively ($p=0.52$; online supplemental table 3). After 12 hours, the pain scores decreased in both groups, but the decrease was more pronounced in group 2 than in group 1 ($p=0.023$). This trend continued until both groups were pain-free on day 5 (figure 2).

We also investigated drug retention over time using triamcinolone acetonide as a separate entity. We found that the drug availability in the central reservoir peaked immediately after application but was detected in the

potential precorneal space for up to 4 hours, indicating an extended drug-corneal interaction time (figure 3).

Mucous strands

Occasionally, mucous occupied the precorneal space behind the lens or clogging fenestrations holes, which were cleared by washing with a sterile balanced salt solution. No surface toxicities were noted in the DDCL group due to the medication or the contact lenses.

DISCUSSION

Poor drug bioavailability is a major concern regarding the ocular dosage, primarily due to precorneal loss following topical administration. Several physiological and anatomical constraints cause only a small portion of the topically administered medication to be absorbed into the deeper structures. In addition, several other factors, such as solution drainage, lacrimation, tear turnover and dilution, conjunctival absorption and very low corneal epithelial membrane permeability, play critical roles in poor ocular bioavailability.⁹

The Steroids for Corneal Ulcers Trial is a large, multicentre, international prospective treatment study comprising patients predominantly from Southern India. This study reported *Streptococcus pneumoniae* in 51.5%, *Pseudomonas aeruginosa* in 22.7% and *Nocardia* species in 11.5% of cases.¹⁰ In our study, 12 cases (70.6%) in the DDCL group were caused by Gram-positive infections, with 6 *Staphylococcus* cases (35.4%) and 3 cases each (17.6%) of *Streptococcus* and *Pneumococcus*. The remaining cases (29.4%) were Gram-negative infections. In the antibiotic-only group, 13 cases (72%) were Gram-positive infections, with 8 *Staphylococcus* cases (44%), 3 *Pneumococcus* cases (16.6%) and 2 *Streptococcus* cases (11%); 5 cases (28%) were Gram-negative infections.

Table 2 Anterior chamber (AC) reaction and corneal haze over time

Pair		AC reaction						Corneal haze					
		Group 1			Group 2			Group 1			Group 2		
		M	SD	P value	M	SD	P value	M	SD	P value	M	SD	P value
1	B	1.94	1.06	n/a	1.88	0.33	0.172	1.83	0.79	n/a	1.71	0.59	0.33
	12 hours	1.94	1.06		1.41	0.51		1.83	0.79		1.65	0.60	
2	B	1.94	1.06	*	1.88	0.33	0.004	1.83	0.79	0.083	1.71	0.59	0.04
	D1	1.44	1.09		0.76	0.66		1.67	0.84		1.47	0.62	
3	B	1.94	1.06	**	1.88	0.33	**	1.83	0.79	0.002	1.71	0.59	**
	D3	1.11	0.90		0.18	0.39		1.39	0.78		1.00	0.87	
4	B	1.94	1.06	**	1.88	0.33	**	1.83	0.79	**	1.71	0.59	**
	D5	0.61	0.61		0.06	0.24		1.11	0.76		0.47	0.62	
5	B	1.94	1.06	**	1.88	0.33	**	1.83	0.79	**	1.71	0.59	**
	D14	0.06	0.24		0.00	0.00		0.33	0.49		0.29	0.47	

Group 1 (antibiotic only, n=18) and group 2 (antibiotic+drug-depository contact lens, n=17).

* $P<0.001$; ** $p<0.0001$.

.B, baseline; D, day; M, mean; n/a, not available.

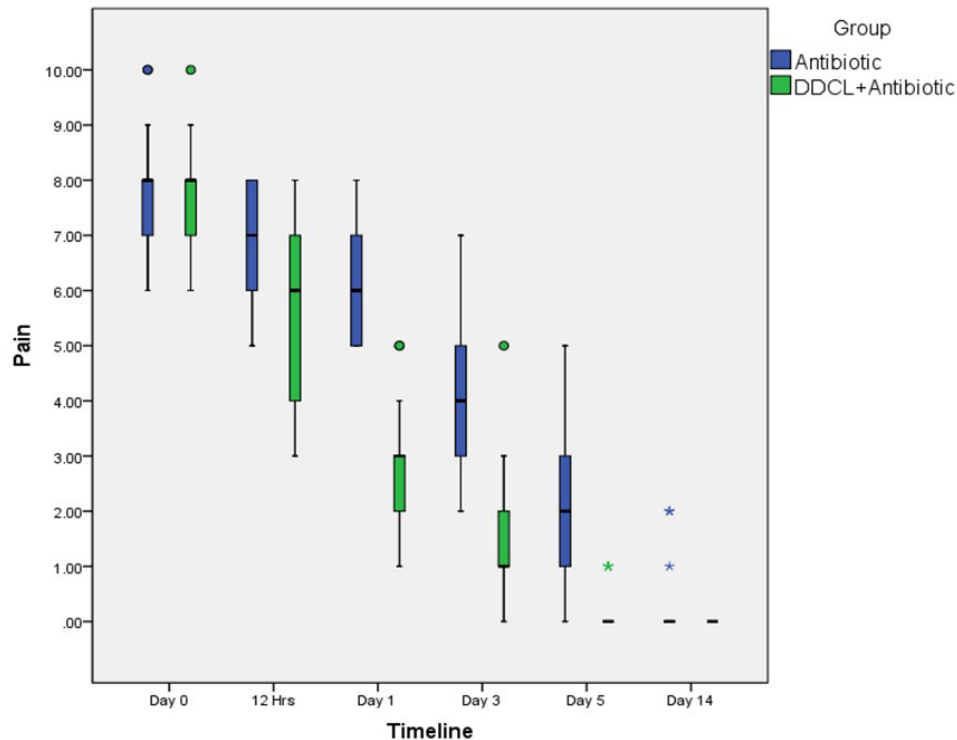


Figure 2 Pain scores during the healing process in the antibiotics only and drug-depository contact lens (DDCL) plus antibiotics groups.

A retrospective study of cases at the Hospital das Clínicas, Federal University of Espírito Santo Júlia¹¹ identified 398 cases of corneal ulcers, of which 60% were positive and 40% were negative for microbiological cultures. Furthermore, 28% were Gram-positive infections, while 61% were Gram-negative (Gram-staining was not performed in 11% of cases). This study provides practical information, helping physicians make more informed presumptive diagnoses and administer more initial empirical treatment as necessary. Our study only enrolled patients with BK (identified as bacterial by Gram-staining) and without fungal infection (confirmed

by potassium hydroxide mount) at the baseline visit, and the culture positivity was near 70%.

Moreover, Chawla *et al.*¹² investigated the microbiological profiles of 292 patients; 255 (87.3%) and 37 (12.7%) were Gram-positive and Gram-negative, respectively, and *Staphylococcus epidermidis* (227; 77.7%) was the most common. Furthermore, they found that the overall susceptibility of isolates was high (95.52% to gatifloxacin, 92.83% to moxifloxacin, 90.07% to tobramycin and 83.56% to cefazolin). Therefore, monotherapy with moxifloxacin or gatifloxacin is an effective alternative to a cefazolin-tobramycin combination as first-line empirical

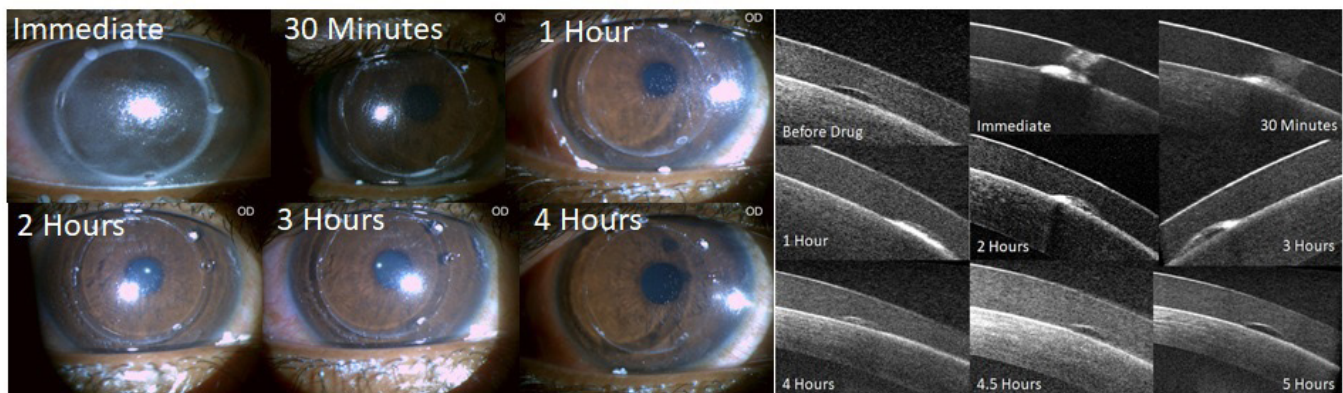


Figure 3 Representative images of drug retention over time. Triamcinolone acetonide reflected the drug availability in the central reservoir, which peaked immediately after administering the medication. However, it was detected in the potential precorneal space up for up to 4 hours. We chose triamcinolone because, in cataract surgeries, it stains the vitreous without staining the intraocular lens. (A) A magnified view of the eye. (B) Corneal optical coherence tomography images.



therapy for BK.^{13 14} Considering broad-spectrum activity, we decided to treat all BK cases with 0.5% moxifloxacin monotherapy regardless of the Gram-staining status.

Additionally, Gokhale⁶ evaluated antimicrobials for BK treatment, finding that the necessary administration frequency depends on the severity of the infection, but most patients should start with half-hourly drops for 24 hours. However, they advised a loading dose of one drop every 5 min for the first 30 min for severe ulcers. Then, they suggest reducing the frequency based on the clinical response. Our study used a 0.5% moxifloxacin (ie, vigamox) monotherapy with 2 hourly dosing during waking hours for the first 2 days followed by 4 hourly dosing during waking hours for the next 12 days to determine if the DDCL retains antimicrobials in the precorneal space for longer, facilitating a good healing response without requiring a loading dose.

In this study, we aimed to retain the medication in the precorneal space by using a highly specified DDCL with dual base curves, resulting in a central antimicrobial lake for drug retention rather than sustained release. In addition, the lens fenestrations captured the medication every time it was reapplied, refilling the central reservoir with the drug for a prolonged interaction with the cornea. We evaluated the effects of this using clinical parameter guidelines recommended by the American Academy of Ophthalmology. The treatment response was measured based on improvements to the corneal infiltration size (including the BK severity scores), the ulcer size, AC reactions, corneal haze, visual acuity and pain, allowing us to comprehensively assess positive responses to antibiotic therapy.

We observed corneal infiltration resolution on day 5 in the antibiotic only group and day 3 in the DDCL group. However, in both groups, the lesions completely healed after 2 weeks. Furthermore, the AC reaction significantly decreased in both groups, but the improvement was more pronounced in the DDCL group after 3 days; corneal haze also improved in both groups during the healing period. Notably, significant vision improvements were noticed after only 1 day in the DDCL group, whereas vision improvement did not begin until day 3 for the antibiotic only group. Hence, we recommend the DDCL for the first 3 days of treatment, then reassessing its necessity based on the healing progress for the remainder of the treatment regime. Finally, the pain was also significantly less in the DDCL group than in the antibiotics only group until day 5. However, both groups reported less pain after 12 hours. Therefore, another benefit of in situ contact lenses includes epithelialisation promotion, as the lens acts as a therapeutic bandage.

Despite prolonged exposure to the topical pharmacological agent, the DDCL group did not experience ocular surface toxicity, and neither group experienced adverse events. Occasionally, mucous occupied the precorneal space behind the lens. However, it was cleared by flushing the eye with a sterile balanced salt solution or removing, washing, and replacing the lens.

To build on our positive results, future DDCLs studies for keratitis should be performed in a larger cohort of patients with ulcers. Moreover, future studies should investigate reducing the topical application frequency and the applicability of this management strategy for protozoal and mycotic keratitis, which requires more extended drug-lesion contact periods than BK.

CONCLUSIONS

The DDCL is a therapeutic soft contact lens indicated for therapeutic use to promote healing and relieve pain by protecting the cornea during BK treatment. This new drug repository contact lens prolongs corneal antimicrobial availability and the cornea-lesion interaction time, resulting in faster corneal healing. Therefore, using a DDCL may reduce the antibiotic regimen, decrease the treatment burden on the medical staff, improve patient tolerance and reduce toxicities.

Acknowledgements We thank Dhanisha JL, Muthumari and Tamilselvi for their valuable contribution in this study.

Contributors LRDRP: planning, conduct, reporting, conception and design and interpretation of data. VR: planning, conduct, reporting and interpretation of data. HA: planning, conception and design, interpretation of data. JC: conduct, reporting and acquisition of data. AA: acquisition of data and interpretation of data. LRDRP is the principal investigator & guarantor.

Funding EyeYon Medical Ltd., Israel, sponsored this study.

Competing interests None declared.

Patient and public involvement Patients and/or the public were not involved in the design, or conduct, or reporting, or dissemination plans of this research.

Patient consent for publication Consent obtained directly from patient(s).

Ethics approval This study was approved by Dr Agarwal's Eye Hospital Institutional Review Board with approval number DAEH/TVL/EC-2001 and the study was conducted following the Declaration of Helsinki principles. Informed consent was obtained from all participants.

Provenance and peer review Not commissioned; externally peer reviewed.

Data availability statement All data relevant to the study are included in the article or uploaded as supplementary information.

Supplemental material This content has been supplied by the author(s). It has not been vetted by BMJ Publishing Group Limited (BMJ) and may not have been peer-reviewed. Any opinions or recommendations discussed are solely those of the author(s) and are not endorsed by BMJ. BMJ disclaims all liability and responsibility arising from any reliance placed on the content. Where the content includes any translated material, BMJ does not warrant the accuracy and reliability of the translations (including but not limited to local regulations, clinical guidelines, terminology, drug names and drug dosages), and is not responsible for any error and/or omissions arising from translation and adaptation or otherwise.

Open access This is an open access article distributed in accordance with the Creative Commons Attribution Non Commercial (CC BY-NC 4.0) license, which permits others to distribute, remix, adapt, build upon this work non-commercially, and license their derivative works on different terms, provided the original work is properly cited, appropriate credit is given, any changes made indicated, and the use is non-commercial. See: <http://creativecommons.org/licenses/by-nc/4.0/>.

ORCID iD

Lional Raj Daniel Raj Ponniah <http://orcid.org/0000-0002-4209-6069>

REFERENCES

- 1 Ung L, Bispo PJM, Shanbhag SS, *et al*. The persistent dilemma of microbial keratitis: global burden, diagnosis, and antimicrobial resistance. *Surv Ophthalmol* 2019;64:255–71.

- 2 Collier SA, Gronostaj MP, MacGurn AK, *et al.* Estimated burden of keratitis--United States, 2010. *MMWR Morb Mortal Wkly Rep* 2014;63:1027.
- 3 World Health Organization. Guidelines for the management of corneal ulcer at primary, secondary and tertiary care health facilities in the south-east Asia region. who regional office for south-east Asia, 2004. Available: <https://apps.who.int/iris/handle/10665/205174>
- 4 Henry CR, Flynn HW, Miller D, *et al.* Infectious keratitis progressing to endophthalmitis: a 15-year study of microbiology, associated factors, and clinical outcomes. *Ophthalmology* 2012;119:2443–9.
- 5 Hanet M-S, Jamart J, Chaves AP, Pinheiro Chaves A. Fluoroquinolones or fortified antibiotics for treating bacterial keratitis: systematic review and meta-analysis of comparative studies. *Can J Ophthalmol* 2012;47:493–9.
- 6 Gokhale N. Medical management approach to infectious keratitis. *Indian J Ophthalmol* 2008;56:215.
- 7 Gaudana R, Ananthula HK, Parenky A, *et al.* Ocular drug delivery. *Aaps J* 2010;12:348–60.
- 8 Callegan MC, O'Callaghan RJ, Hill JM. Pharmacokinetic considerations in the treatment of bacterial keratitis. *Clin Pharmacokinet* 1994;27:129–49.
- 9 Kaur IP, Garg A, Singla AK, *et al.* Vesicular systems in ocular drug delivery: an overview. *Int J Pharm* 2004;269:1–14.
- 10 Ray KJ, Prajna L, Srinivasan M, *et al.* Fluoroquinolone treatment and susceptibility of isolates from bacterial keratitis. *JAMA Ophthalmol* 2013;131:310–3.
- 11 Comarella JD, Saraiva PG, Saraiva FP. Úlcera de córnea: estudo retrospectivo de casos atendidos no Hospital das Clínicas da Universidade federal do Espírito Santo. *Rev Bras Oftalmol* 2015;74:76–80.
- 12 Chawla B, Agarwal P, Tandon R, *et al.* In vitro susceptibility of bacterial keratitis isolates to fourth-generation fluoroquinolones. *Eur J Ophthalmol* 2010;20:300–5.
- 13 Marangon FB, Miller D, Alfonso EC. Impact of prior therapy on the recovery and frequency of corneal pathogens. *Cornea* 2004;23:158–64.
- 14 Levey SB, Katz HR, Abrams DA, *et al.* The role of cultures in the management of ulcerative keratitis. *Cornea* 1997;16:383–6.