

One-Step Transpapillary Balloon Dilation under Cap-Fitted Endoscopy without a Preceding Sphincterotomy for the Removal of Bile Duct Stones in Billroth II Gastrectomy

Tae Hoon Lee*, Jae Chul Hwang[†], Hyun Jong Choi*, Jong Ho Moon*, Young Deok Cho*, Byung Moo Yoo[†], Sang-Heum Park*, Jin Hong Kim[†], and Sun-Joo Kim*

*Division of Gastroenterology, Department of Internal Medicine, Digestive Disease Center, Soonchunhyang University College of Medicine, Cheonan, [†]Division of Gastroenterology, Department of Internal Medicine, Ajou University School of Medicine, Suwon, Korea

Background/Aims: Endoscopic sphincterotomy may be limited in Billroth II gastrectomy because of difficulty in orientating the duodenoscope and sphincterotome as a result of altered anatomy. This study was planned to investigate the efficacy and safety of endoscopic transpapillary large balloon dilation (EPBD) without preceding sphincterotomy for removal of large CBD stones in Billroth II gastrectomy. **Methods:** Between March 2010 and February 2011, one-step EPBD under cap-fitted forward-viewing endoscopy was performed in patients who had undergone Billroth II gastrectomy at two tertiary referral centers. Main outcome measurements were successful duct clearance and EPBD-related complications. **Results:** Successful access to major duodenal papilla was performed in 13 patients, but successful selective CBD cannulation was achieved in 12 patients (92.3%). Median maximum transverse stone size was 11.5 mm (10 to 14 mm). The mean number of stones was 2 (1-5). The median CBD diameter was 15 mm (12 to 19 mm). Mean procedure time from successful biliary access to complete stone removal was 17.8 min. Complete duct clearance was achieved in all patients. Four patients (33.3%) needed one more session of ERCP for removal of remnant stones. Asymptomatic hyperamylasemia in two patients and minor bleeding in another occurred. **Conclusions:** Without preceding sphincterotomy, one-step EPBD (≥ 10 mm) under cap-fitted forward-viewing endoscopy may be safe and effective for the removal of large stones (≥ 10 mm) with CBD dilatation in Billroth II gastrectomy. (*Gut Liver* 2012;6:113-117)

Key Words: Endoscopic balloon dilation; Common bile duct;

Stone; Billroth II gastrectomy; Cap-fitted endoscopy

INTRODUCTION

Therapeutic endoscopic retrograde cholangiopancreatography (ERCP) is a difficult procedure to perform in patients who have undergone Billroth II gastrectomy, due to anatomical changes, long afferent loop, and sharp angulation. Moreover, endoscopic sphincterotomy (ES), the most frequently used endoscopic technique for removal of common bile duct (CBD) stones, may be limited in Billroth II gastrectomy because of difficulty in orientating the duodenoscope and sphincterotome as a result of altered anatomy.¹⁻⁴

In recent studies, most endoscopists have suggested that ES should be performed before endoscopic transpapillary balloon dilation (EPBD) for the extraction of CBD stones, because of the high risk of EPBD-related pancreatitis and the advantages of ES, including its ability to guide the ballooning direction, as well as its effectiveness in removing stones.⁵⁻¹⁰ However, in Billroth II gastrectomy, adequate full sphincterotomy and orientation of the CBD in the right direction can be difficult due to an altered anatomy. Also, in a recent preliminary study, it was reported that endoscopic transpapillary large balloon dilation (EPLBD) without preceding ES may be safe and effective for the retrieval of large CBD stones in normal anatomy.¹¹

We evaluated the usefulness and safety of one-step transpapillary large balloon dilatation (≥ 10 mm) without preceding sphincterotomy under cap-fitted forward-viewing endoscopy, for removal of bile duct stones (≥ 10 mm) in patients who underwent Billroth II gastrectomy.

Correspondence to: Tae Hoon Lee

Division of Gastroenterology, Department of Internal Medicine, Soonchunhyang University Cheonan Hospital, 23-20 Bongmyung-dong, Cheonan 330-721, Korea

Tel: +82-41-570-3662, Fax: +82-41-574-5762, E-mail: thlee9@lycos.co.kr

Received on June 9, 2011. Revised on August 8, 2011. Accepted on August 26, 2011.

pISSN 1976-2283 eISSN 2005-1212 <http://dx.doi.org/10.5009/gnl.2012.6.1.113>

© This is an Open Access article distributed under the terms of the Creative Commons Attribution Non-Commercial License (<http://creativecommons.org/licenses/by-nc/3.0>) which permits unrestricted non-commercial use, distribution, and reproduction in any medium, provided the original work is properly cited.

MATERIALS AND METHODS

1. Patients and definition

Patients who had previously undergone Billroth II gastrectomy with CBD stones; the maximum transverse diameter of the largest stone was ≥ 10 mm, were invited to participate in this study. Patients with non-naïve papilla, uncontrolled coagulopathy, concurrent malignant bile duct obstruction, failure of selective bile duct cannulation, and refusal to participate in this study were excluded. Twelve patients were enrolled and therapeutic outcomes were analyzed between March 2010 and February 2011. All participants gave informed consent for the endoscopic procedure. This clinical study was approved by the Institutional Review Board at each participating hospital.

Technical success and procedure-related complications were evaluated. Primary technical success was defined as complete duct clearance following one session of EPBD. ERCP-related complications were defined and graded in severity according to the consensus criteria.¹²

2. Endoscopic technique

All patients underwent ERCP with a forward-viewing endoscopy (GIF 260 or GIF-2TQ 260M; Olympus Optical Co., Ltd., Tokyo, Japan) in the prone or lateral decubitus position after sedation with intravenous midazolam (0.05 mg/kg) and/or propofol (0.5 mg/kg). A transparent cap (Distal attachment D-201-11802;

Olympus Optical Co., Ltd.) was attached to the tip of the endoscope. Prophylactic antibiotics and analgesics were permitted. All procedures were performed by two experienced endoscopists at each tertiary referral center. Selective cannulation of the CBD was achieved by wire-guided cannulation: a hydrophilic tipped guidewire (Jagwire; Boston Scientific, Natick, MA, USA), 0.035 inches in diameter, was preloaded into a pull-type papillotome

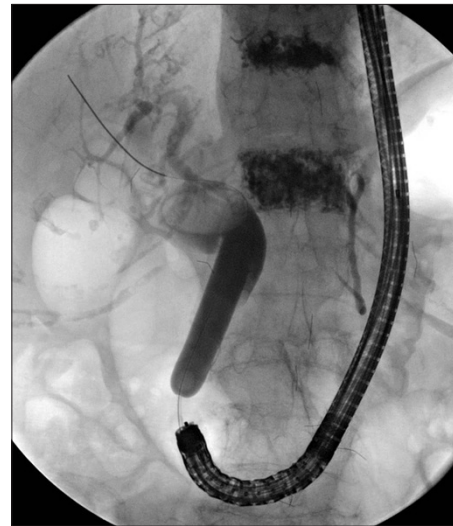

Fig. 1. Endoscopic retrograde cholangiopancreatography showing the CRE wire-guided dilation, 12 mm in diameter.

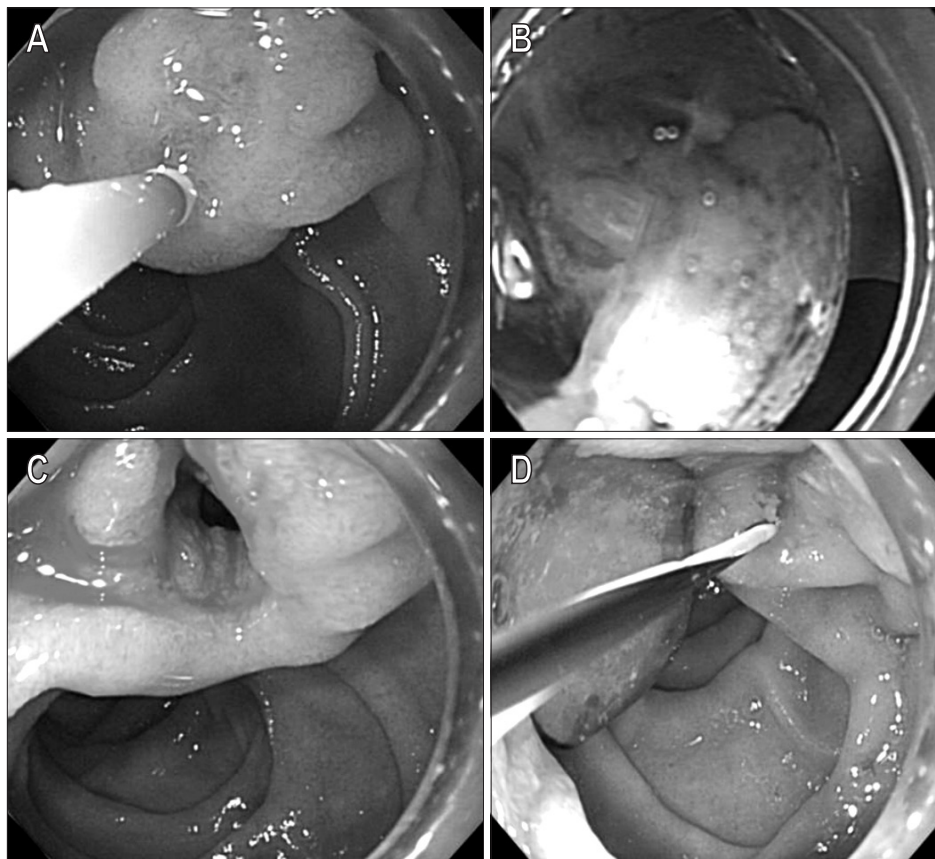


Fig. 2. The consecutive steps for the removal of common bile duct (CBD) stones under cap-fitted, forward-viewing endoscopy. Following the selective cannulation of the CBD using a guidewire-preloaded papillotome (A), CRE balloon dilation (12 mm in diameter) was maintained for 60 seconds (B). After dilating the major duodenal papilla, a large opening was noted (C), and the stones were removed by a retrieval balloon and mechanical lithotripter (D).

(Flow Cut; Olympus Optical Co., Ltd.) or Autotome RX cannulating sphincterotome (Boston Scientific, Natick, MA, USA). Following a minimal insertion (2 to 3 mm) of the pull-type papillotome into the ampulla, the guidewire was carefully advanced through the CBD under fluoroscopy until it was seen to enter the bile duct. The balloon catheter (CRE wire-guided dilator; Boston Scientific, Marlboro, MA, USA) was passed over the guidewire. If the maximum transverse diameter of the largest stone was ≥ 10 mm and/or there was ≥ 12 mm of CBD dilatation, we used a CRE balloon catheter with a diameter ≥ 10 mm (Fig. 1). However, we did not use a balloon with a larger diameter than the dilated extrahepatic bile duct. Preceding ES was not performed in all patients. The sphincter was considered to be adequately dilated if the waist of the balloon had disappeared completely on fluoroscopic examination. The fully expanded balloon was maintained in position for 60 seconds (ballooning time), and then deflated slowly and removed. EPBD was performed for just one session. The stones were removed with a conventional balloon or basket extraction technique (Fig. 2). A mechanical lithotripter (Lithotriptoren; MTW Endoskopie, Wesel, Germany) was used to crush the stones when stone extraction could not be achieved by using a basket or retrieval balloon, even after EPBD.

RESULTS

Cap-fitted endoscopy was attempted in 13 patients who underwent Billroth II gastrectomy. Successful access to major duodenal papilla was performed in all patients, but successful selective CBD cannulation was achieved in 12 patients (92.3%). The GIF 260 and GIF-2TQ 260M transparent cap-fitted endoscope was used in nine and three patients, respectively. The

results of the EPBD procedure are summarized in Table 1. Maximum stone size (transverse diameter) ranged from 10 to 14 mm (median, 11.5). The number of stones was 1 to 5 (median, 1.5). The CBD diameter was 12 to 19 mm (median, 15 mm). Papillary balloon dilatation using variously sized balloons, from 10 to 15 mm, was performed without preceding sphincterotomy. Mean procedure time (mean \pm SD) from successful biliary access to complete stone removal was 17.8 \pm 5.6 minutes (range, 9 to 28 minutes). Primary technical success rate following just one-step EPBD was 66.6% (8/12). The other four patients needed another session of ERCP for removal of remnant fragments or sludge because of a higher number of stones or fragments (Table 1). A mechanical lithotripter was used to crush the stones in two patients (16.7%). Totally, complete duct clearance was achieved in all patients (100%). Asymptomatic hyperamylasemia occurred in two patients and minor bleeding in one patient. There was no serious procedure-related adverse event, such as acute pancreatitis or perforation.

DISCUSSION

In Billroth II gastrectomy, even though the endoscope is successfully advanced to the major papilla by using cap-fitted forward-viewing endoscopy to overcome sharp angulation and a long afferent loop, adequate ES may be more difficult because the course that allows access to the CBD is located at the 5 to 6 o'clock position.^{13,14} Prediction of the traveling direction of the biliary tract is difficult, and the range of visual security may also be difficult, so that ES might fail or not remove a sufficient number of stones.

Several methods, such as needle knife sphincterotomy over a previously inserted endoprosthesis, or new instruments, such as

Table 1. Baseline Characteristics and Therapeutic Outcomes

Patient No.	Sex/ Age	Stone size, mm	Stone No.	CBD diameter	Balloon size	ERCP session	Mechanical lithotripsy	Procedure time*, min	Complication	Duct clearance
1	M/74	13	3	17	15	1	+	19	-	Yes
2	F/81	10	5	14	12	2	-	24	Bleeding [†]	Yes
3	F/65	10	1	13	12	1	-	14	Hyperamylasemia	Yes
4	M/73	12	1	15	12	1	-	14	-	Yes
5	M/68	11	1	16	13.5	1	-	8	Hyperamylasemia	Yes
6	M/76	10	2	15	12	1	-	7	-	Yes
7	M/67	12	1	16	12	1	-	19	-	Yes
8	F/72	10	1	12	10	1	-	16	-	Yes
9	F/90	12	3	19	13.5	2	+	11	-	Yes
10	M/69	14	3	15	12	2	-	28	-	Yes
11	M/65	10	2	19	10	2	-	15	-	Yes
12	M/64	12	1	15	12	1	-	18	-	Yes

CBD, common bile duct; ERCP, endoscopic retrograde cholangiopancreatography.

*From successful biliary access to complete stone removal; [†]Minor bleeding.

S-shaped sphincterotome and rotatable papillotome, have been developed to enable ES in Billroth II gastrectomy.¹⁵⁻¹⁸ However, it is generally accepted that ES in patients who have undergone Billroth II gastrectomy may often be difficult to perform easily and safely. In Billroth II gastrectomy, needle-knife sphincterotomy results in a reduced size of sphincterotomy opening compared with standard ES in patients with normal anatomy.¹³ With ES-related complications, generally perforation is rare below 1%; however, in patients who have undergone Billroth II gastrectomy, rates as high as 6% have been reported.¹⁹⁻²¹ Bergman *et al.*¹³ have shown that, compared with ES in patients with normal anatomy, ES in Billroth II gastrectomy has a lower rate of complete stone removal and a higher number of complications. In some centers, following insertion of biliary stents, stepwise sphincterotomy using needle-knife sphincterotomy is used. However, this is time-consuming and control of the direction of the cutting is also difficult, and the risk of perforation is increased; thus, an adequate sphincterotomy may be limited.¹⁵

Although ES is technically more demanding in Billroth II gastrectomy, EPBD is relatively easy to perform with no other prior procedure. Several studies of EPLBD have been reported for large bile duct stones since the initial study of Ersoz *et al.*⁵ in 2003. The use of large balloon dilation after ES has been shown to be effective for the removal of large bile duct stones in patients with normal anatomy. Once the papilla is reached and deep cannulation of the bile duct has been achieved, EPBD is a relatively maneuverable procedure that does not require special endoscopic skills.^{11,13,22} Balloon dilation using a standard size balloon (<10 mm) or large balloon (>10 mm) is a useful therapeutic tool for removal of bile duct stones in patients who have undergone Billroth II gastrectomy.^{13,18,22,23} However, in most studies, it has been suggested that ES should be performed before EPBD for the extraction of CBD stones because of the high risk of EPBD-related pancreatitis and the advantages of ES, including its ability to guide the ballooning direction, as well as its effectiveness for stone removal.^{5-10,22} Otherwise, in a recent preliminary study, EPLBD without preceding ES has been shown to be safe and effective for the retrieval of large CBD stones.¹¹

Based on these results, we considered that EPBD without ES may overcome the limitations and risks of sphincterotomy in Billroth II gastrectomy. We clarified the safety and efficacy of EPBD without a preceding sphincterotomy for removal of large bile duct stones in patients with a dilated CBD, who had undergone Billroth II gastrectomy. All of the procedures were performed by experienced endoscopists and their assistants in each center. When we dilate or deflate the balloon, it is performed very slowly while checking the diameter of the balloon under fluoroscopy. There was no significant complication, such as pancreatitis, perforation, or major bleeding, following EPBD (≥ 10 mm) without sphincterotomy. However, our study was performed over a short period, although it was in two tertiary referral centers. Also, we enrolled a small number of cases, and

we had no comparative results due to the limited inclusion criteria. Technically, balloon size was also relatively small, ranging from 10 to 15 mm, because more large stones are uncommon in enrolled patients.

In conclusion, EPBD without preceding ES appears to be a feasible and safe procedure for removal of large bile duct stones in patients who have undergone Billroth II gastrectomy. However, a larger-scale prospective study should be carried to demonstrate the safety of EPBD in various situations.

CONFLICTS OF INTEREST

No potential conflict of interest relevant to this article was reported.

REFERENCES

1. Forbes A, Cotton PB. ERCP and sphincterotomy after Billroth II gastrectomy. *Gut* 1984;25:971-974.
2. Osnes M, Rosseland AR, Aabakken L. Endoscopic retrograde cholangiography and endoscopic papillotomy in patients with a previous Billroth-II resection. *Gut* 1986;27:1193-1198.
3. Hintze RE, Adler A, Veltzke W, Abou-Rebyeh H. Endoscopic access to the papilla of Vater for endoscopic retrograde cholangiopancreatography in patients with billroth II or Roux-en-Y gastrojejunostomy. *Endoscopy* 1997;29:69-73.
4. Nakahara K, Horaguchi J, Fujita N, et al. Therapeutic endoscopic retrograde cholangiopancreatography using an anterior oblique-viewing endoscope for bile duct stones in patients with prior Billroth II gastrectomy. *J Gastroenterol* 2009;44:212-217.
5. Ersoz G, Tekesin O, Ozutemiz AO, Gunsar F. Biliary sphincterotomy plus dilation with a large balloon for bile duct stones that are difficult to extract. *Gastrointest Endosc* 2003;57:156-159.
6. Bang S, Kim MH, Park JY, Park SW, Song SY, Chung JB. Endoscopic papillary balloon dilation with large balloon after limited sphincterotomy for retrieval of choledocholithiasis. *Yonsei Med J* 2006;47:805-810.
7. Heo JH, Kang DH, Jung HJ, et al. Endoscopic sphincterotomy plus large-balloon dilation versus endoscopic sphincterotomy for removal of bile-duct stones. *Gastrointest Endosc* 2007;66:720-726.
8. Maydeo A, Bhandari S. Balloon sphincteroplasty for removing difficult bile duct stones. *Endoscopy* 2007;39:958-961.
9. Minami A, Hirose S, Nomoto T, Hayakawa S. Small sphincterotomy combined with papillary dilation with large balloon permits retrieval of large stones without mechanical lithotripsy. *World J Gastroenterol* 2007;13:2179-2182.
10. Attasaranya S, Cheon YK, Vittal H, et al. Large-diameter biliary orifice balloon dilation to aid in endoscopic bile duct stone removal: a multicenter series. *Gastrointest Endosc* 2008;67:1046-1052.
11. Jeong S, Ki SH, Lee DH, et al. Endoscopic large-balloon sphincteroplasty without preceding sphincterotomy for the removal of

- large bile duct stones: a preliminary study. *Gastrointest Endosc* 2009;70:915-922.
12. Cotton PB, Lehman G, Vennes J, et al. Endoscopic sphincterotomy complications and their management: an attempt at consensus. *Gastrointest Endosc* 1991;37:383-393.
 13. Bergman JJ, van Berkel AM, Bruno MJ, et al. A randomized trial of endoscopic balloon dilation and endoscopic sphincterotomy for removal of bile duct stones in patients with a prior Billroth II gastrectomy. *Gastrointest Endosc* 2001;53:19-26.
 14. Park CH, Lee WS, Joo YE, Kim HS, Choi SK, Rew JS. Cap-assisted ERCP in patients with a Billroth II gastrectomy. *Gastrointest Endosc* 2007;66:612-615.
 15. van Buuren HR, Boender J, Nix GA, van Blankenstein M. Needle-knife sphincterotomy guided by a biliary endoprosthesis in Billroth II gastrectomy patients. *Endoscopy* 1995;27:229-232.
 16. Hintze RE, Veltzke W, Adler A, Abou-Rebyeh H. Endoscopic sphincterotomy using an S-shaped sphincterotome in patients with a Billroth II or Roux-en-Y gastrojejunostomy. *Endoscopy* 1997;29:74-78.
 17. Al-Kawas FH, Geller AJ. A new approach to sphincterotomy in patients with Billroth II gastrectomy. *Gastrointest Endosc* 1996;43:253-255.
 18. Kim GH, Kang DH, Song GA, et al. Endoscopic removal of bile-duct stones by using a rotatable papillotome and a large-balloon dilator in patients with a Billroth II gastrectomy (with video). *Gastrointest Endosc* 2008;67:1134-1138.
 19. Freeman ML, Nelson DB, Sherman S, et al. Complications of endoscopic biliary sphincterotomy. *N Engl J Med* 1996;335:909-918.
 20. Wilkinson ML, Engelman JL, Hanson PJ. Intestinal perforation after ERCP in Billroth II partial gastrectomy. *Gastrointest Endosc* 1994;40:389-390.
 21. Bagci S, Tuzun A, Ates Y, et al. Efficacy and safety of endoscopic retrograde cholangiopancreatography in patients with Billroth II anastomosis. *Hepatogastroenterology* 2005;52:356-359.
 22. Itoi T, Ishii K, Itokawa F, Kurihara T, Sofuni A. Large balloon papillary dilation for removal of bile duct stones in patients who have undergone a billroth ii gastrectomy. *Dig Endosc* 2010;22 Suppl 1:S98-S102.
 23. Prat F, Fritsch J, Choury AD, Meduri B, Pelletier G, Buffet C. Endoscopic sphincteroclasys: a useful therapeutic tool for biliary endoscopy in Billroth II gastrectomy patients. *Endoscopy* 1997;29:79-81.