

[CASE REPORT]

Pulmonary Embolism and Splenic Infarction after Minocycline Infusion in a Patient with Polycythemia Vera

Makoto Takeuchi¹, Takenori Okada¹, Kouji Iwato², Kazuma Kawamoto³, Yuki Ikegami¹, Yumiko Nakamoto¹, Naomi Idei¹ and Norihiko Ohashi¹

Abstract:

A 55-year-old man treated with polycythemia vera visited our hospital, complaining of left abdominal pain and dyspnea. He had received minocycline infusions three weeks earlier for mycoplasma pneumonia. Contrast-enhanced computed tomography revealed pulmonary embolism and splenic infarction. Ultrasonography of the vein in the forearm revealed a thrombus filling the distal brachial veins to the radial veins on both sides. His condition improved after anticoagulant therapy, and right and left shunts were detected on transesophageal echocardiography. This suggested that thrombus in the forearm may have been the source of the embolism.

Key words: polycythemia vera, minocycline, pulmonary embolism, paradoxical embolism, splenic infarction

(Intern Med 60: 275-279, 2021)

(DOI: 10.2169/internalmedicine.5635-20)

Introduction

In patients with polycythemia vera (PV), cardiovascular conditions and hematological changes account for 45% and 13% of all deaths, respectively (1). Although PV is known to cause thrombosis, the rapid and long-term intravenous administration of minocycline is also associated with an increased risk of thrombophlebitis (2). While several cases of pulmonary embolism (PE) following superficial vein thrombosis (SVT) in the lower extremities have been reported (3), relatively few cases of PE following SVT in the upper extremities have been described (4, 5).

We herein report a rare case of PV with PE and paradoxical embolism after infusion of minocycline.

Case Report

A 55-year-old man with PV (diagnosed with *JAK2*^{V617F} mutation-positive PV 8 years ago) was admitted to the De-

partment of Hematology. Despite receiving treatment with hydroxyurea and aspirin, his control of PV gradually became poor. Two years ago, the treatment was changed to oral ruxolitinib, following which control was regained, and his spleen started to shrink. Myelofibrosis developed for a year, and the hemoglobin level was subsequently maintained at around 10.0 g/dL.

However, on this occasion, he complained of a seven-day history of dyspnea and dry cough, and the symptoms persisted even once he was hospitalized. Mycoplasma pneumonia was strongly suspected based on chest computed tomography (CT), various investigations, and his clinical symptoms. Minocycline was infused for five days to treat the mycoplasma pneumonia. However, each intravenous dose caused vascular pain and was discontinued immediately after initiation. At this time, no pigmentation or induration was observed in either forearm. After the infusion of minocycline for two days, an increase in D-dimer levels was observed, and an ultrasound examination of the leg veins was performed; however, no thrombus was detected. During hos-

¹Department of Cardiology, Hiroshima Red Cross Hospital and Atomic-bomb Survivors Hospital, Japan, ²Department of Hematology, Hiroshima Red Cross Hospital and Atomic-bomb Survivors Hospital, Japan and ³Department of Respiratory, Hiroshima Red Cross Hospital and Atomic-bomb Survivors Hospital, Japan

Received: June 17, 2020; Accepted: July 20, 2020; Advance Publication by J-STAGE: September 12, 2020

Correspondence to Dr. Makoto Takeuchi, mako0920take@outlook.jp

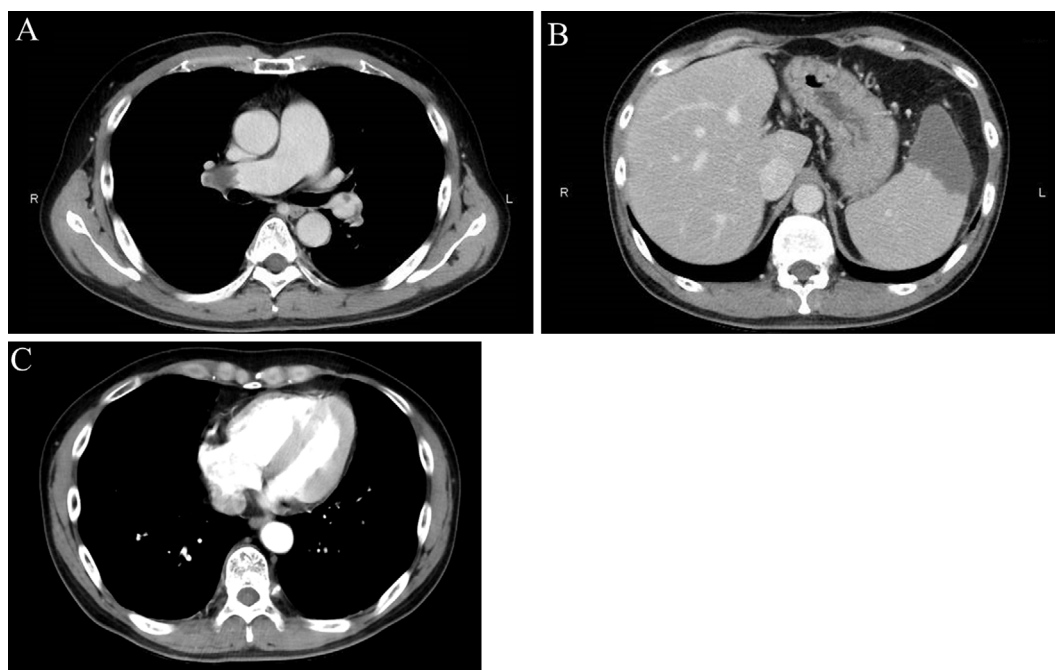


Figure 1. Contrast-enhanced CT for complaints of left abdominal pain and dyspnea. (A) We diagnosed submassive pulmonary embolism. (B) Large splenic infarctions were observed, measuring 7.1 cm×5.0 cm×5.5 cm and 9.0 cm×5.3 cm×8.0 cm at the upper and lower poles of the spleen, respectively. (C) The right ventricle is pushing into the left ventricle, suggesting expansion of the right ventricle.

Table. Laboratory Data.

Complete Blood Count		Coagulation	
WBC	7.0×10 ³ /μL	PT-INR	1.21
RBC	3.91×10 ⁶ /μL	APTT	34.8 sec
Hb	11.9 g/dL	Fibrinogen	522 mg/dL
PLT	209×10 ³ /μL	FDP	4.2 μg/mL
Biochemistry		D-dimer	4.2 μg/mL
AST	76 IU/L	LAC DRVVT	1.28
ALT	94 IU/L	Protein C activity	130
LDH	587 IU/L	Protein S antigen level	132
ALP	678 IU/L	Lipoprotein(a)	6.0
CRP	6.63 mg/dL	Cardiolipin antibody IgG	<8
		Homocysteine	20.8 nmol/mL

Blood tests performed when the patient complained of left abdominal pain and dyspnea. D-dimer elevation was observed, but the tests did not reveal any further congenital abnormalities of coagulation. The hemoglobin level was maintained at around 10.0 g/dL while on ruxolitinib. The increased inflammatory response was thought to be due to splenic infarction.

pitalization, he developed two episodes of paroxysmal hypoxia but was discharged six days after admission due to improvement in inflammatory reaction and dyspnea.

He subsequently developed sudden left abdominal pain and dyspnea and visited our hospital again three weeks later. Contrast-enhanced CT revealed submassive PE (Fig. 1A), requiring emergency hospitalization. Splenic infarctions measuring 7.1 cm ×5.0 cm ×5.5 cm and 9.0 cm ×5.3 cm ×8.0 cm were observed in the upper and lower poles of the spleen, respectively (Fig. 1B). However, CT revealed no venous thrombosis in the lower extremities, and the source of the

embolism could not be identified. After continuous intravenous administration of unfractionated heparin, we switched to edoxaban 60 mg that gradually improved the dyspnea and abdominal pain.

Along with the treatment, we looked for the source of the emboli. Although the presence of PV increases the risk of thrombus, blood tests obtained at the time of the visit did not reveal any congenital abnormalities of coagulation (Table).

On an examination, we found pigmentation along the blood vessels in the center of the left forearm (Fig. 2). The

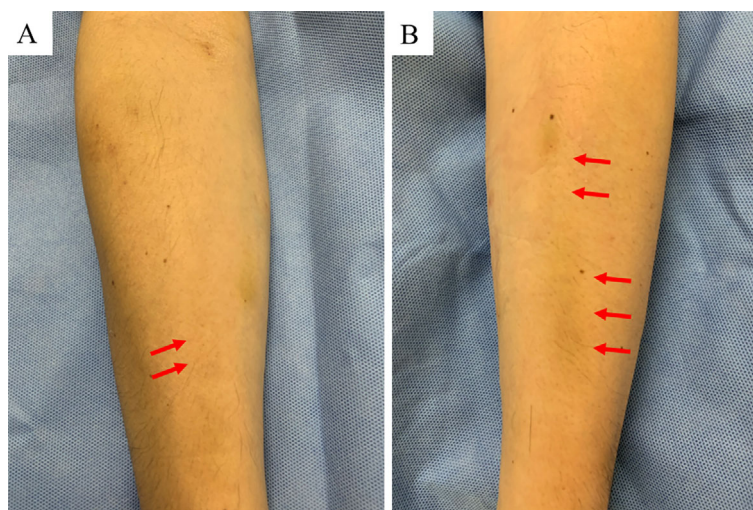


Figure 2. Pigmentation along the blood vessels. (A) Right forearm. (B) Left forearm. We found pigmentation in the center of the left forearm.

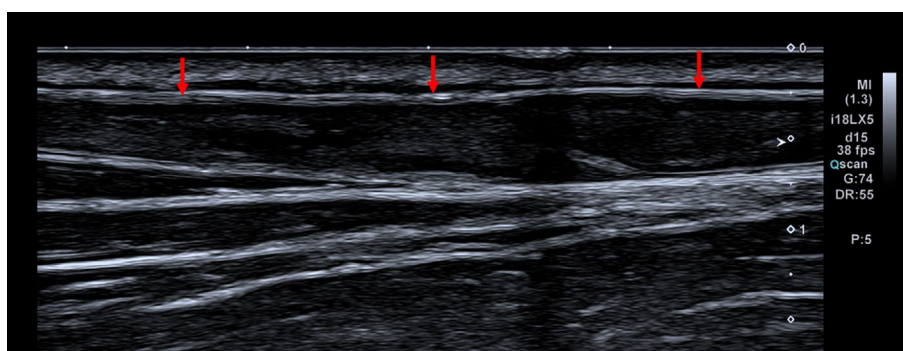


Figure 3. Ultrasonography of the vein in the left forearm. We found a thrombus extending from the radial vein up to the distal brachial vein. On pressing with an echo probe, the blood vessels did not collapse. Similar findings were also found on the right forearm.

vein showed no dilation or swelling, but painless induration was noted. Both upper limbs showed mild swelling, but the swelling was not enough to depict fullness.

Ultrasonography of the veins in the forearm revealed thrombi bilaterally, extending from the radial veins up to the distal brachial veins on both the sides (Fig. 3). The extent of the thrombi prior to the occurrence of the embolism is unknown, but at the time of the examination, no thrombus was found in the proximal portion of the brachial veins. Ultrasonography of the veins of the lower extremities and abdominal blood vessels also showed an absence of thrombi. He was never aware of any lower leg pain or any burning sensation during this period. After eight days of anticoagulant therapy, transesophageal echocardiography revealed right and left shunts in the patent foramen ovale (PFO). The bubble test was positive, showing moderate bubbles in the left heart system (Fig. 4). These results suggested that the intravenous administration of minocycline might have caused thrombosis in the upper extremities, which might have led to PE and splenic infarction through the PFO.

As a result of the anticoagulant therapy for PE, transthoracic echocardiography showed an improvement in the right

heart load findings and improved oxygenation. Lung perfusion scintigraphy taken after 15 days of anticoagulant therapy showed an improvement in the PE (Fig. 5). Pain and inflammation due to splenic infarction gradually improved with symptomatic treatment, and further definitive treatment, such as splenectomy, was not required. He was discharged home after 16 days of anticoagulant therapy.

Discussion

PV is a clonal disease of hematopoietic stem cells, and the $JAK2^{V617F}$ gene mutation has recently been found to be a major mutation of this disease (6). According to a large-scale cohort study (1) of PV patients, thrombosis in PV is more commonly in arteries than in veins. Indeed, arteries accounted for 28.7% of the thromboses, resulting in the incidence of cerebral ischemic attacks (10.3%), cerebral embolism (8.9%), acute myocardial infarction (8.9%), and peripheral vascular thrombosis (5.5%). In contrast, veins accounted for 13.7% of the thromboses, resulting in the incidence of deep vein thrombosis (8.2%), superficial vein thrombosis (6.1%), and pulmonary embolism (2.4%). In addition, cases

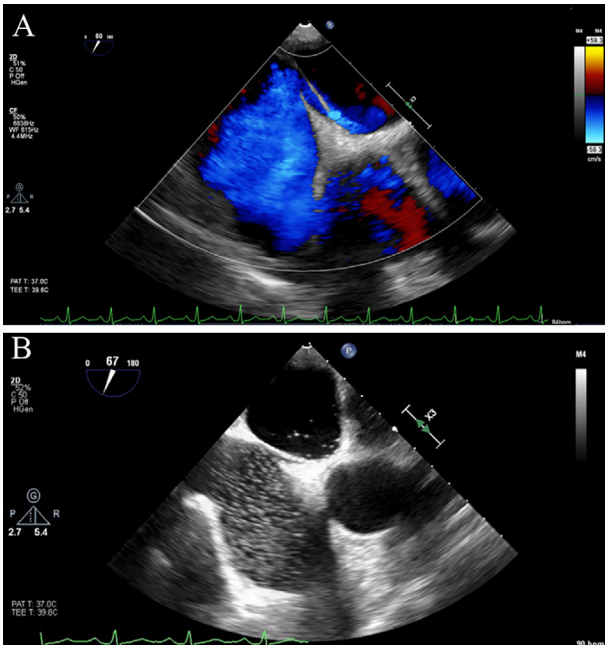


Figure 4. (A) After 8 days of anticoagulant therapy, transesophageal echocardiography revealed right and left shunts in the patent foramen ovale. (B) The bubble test was positive, showing moderate bubbles in the left heart system.

of thrombophlebitis caused by the injection of minocycline have also been reported (2). In the present case as well, 100 mg of minocycline was administered every 12 hours for ≥ 60 minutes, in keeping with the recommended dosage and rate of infusion. Although the standard minocycline administration technique was adhered to, PV itself may cause thrombosis, as described above, which may have caused this rare incident.

Regarding the relationship between SVT of the upper limbs and PE, although several cases of PE following SVT in the lower extremities have been reported (3), relatively few cases of PE following SVT in the upper extremities have been reported (4, 5). In 1990, Sassu et al. (4) reported a patient with recurrent superficial thrombophlebitis of the left arm who developed right-sided (but not massive) PE. Although Barros et al. (5) described a case of post-traumatic superficial thrombophlebitis of the basilic vein complicated with PE, in that case as well, the PE was not massive but was limited to the basal posterior and lateral segments of the right inferior lobe of the lung. These reports suggested that the intravenous administration of minocycline might have caused thrombosis in the upper extremities, which might have led to PE. In the case of thrombophlebitis due to minocycline, the onset of PE was considered to be around the third day after the onset of pneumonia, when symptoms first occurred, along with the appearance of right heart overload on the 12-lead electrocardiogram and elevated D-dimer levels. When the paradoxical embolism occurred, about 20 days had passed since the onset of PE. We consider that there was more right heart load when paradoxical embolism occurred than when we performed transesophageal echocar-

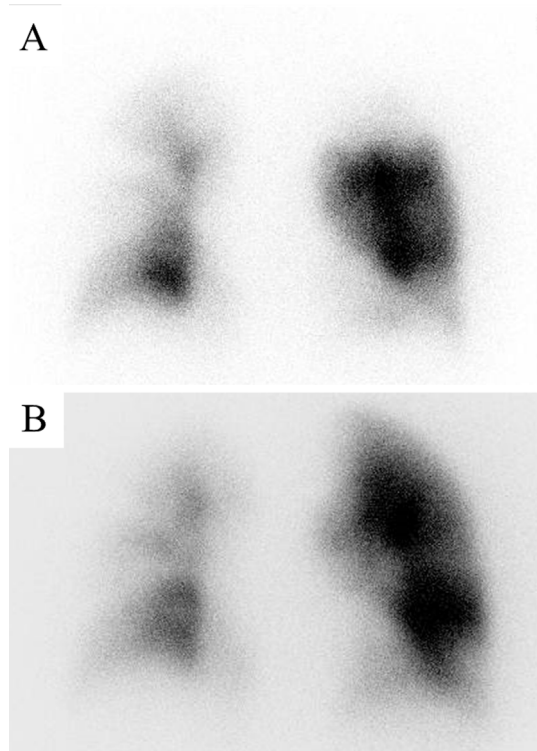


Figure 5. Lung perfusion scintigraphy conducted before anticoagulant therapy (A) and after 15 days of anticoagulant therapy (B). The left upper lung field improved, and the right lung tended to be slightly better overall.

diography (Fig. 1C). Right atrial pressure increased due to the right heart load, and there might have been more right and left shunts.

We also considered PFO catheter closure. Three meta-analyses investigated the efficacy of catheter-based closure for the treatment of a latent cerebral infarction with PFO (7-9). In addition, a study reported that 0.2% of patients who underwent closure of PFO developed device thrombosis (10). This patient was already at risk of device thrombosis because he had PV, which is characterized by spontaneous thrombosis. We suspected that treatment with edoxaban would be able to prevent the recurrence of venous thromboembolism. He was not treated with any intervention apart from edoxaban; however, he recovered without any deterioration.

Conclusion

We herein report a case in which the infusion of minocycline formed a thrombus in the forearm, which was thought to have resulted in embolism. We must bear in mind that drug-induced thrombophlebitis can lead to embolism. In addition, devising a better method of administering minocycline infusion may prevent thrombosis.

The authors state that they have no Conflict of Interest (COI).

References

1. Marchioli R, Finazzi G, Landolfi R, et al. Vascular and neoplastic risk in a large cohort of patients with polycythemia vera. *J Clin Oncol* **23**: 2224-2232, 2005.
2. Greig SL, Scott LJ. Intravenous minocycline: a review in acinetobacter infections. *Drugs* **76**: 1467-1476, 2016.
3. Kesteven P, Robinson B. Superficial thrombophlebitis followed by pulmonary embolism. *J R Soc Med* **94**: 186-187, 2001.
4. Sassu GP, Chisholm CD, Howell JM, Huang E. A rare etiology for pulmonary embolism: basilic vein thrombosis. *J Emerg Med* **8**: 45-49, 1990.
5. Barros FS, Sandri JL, Prezotti BB, et al. Pulmonary embolism in a rare association to a floating thrombus detected by ultrasound in the basilic vein at the distal arm. *Rev bras Ecocardiogr Imagem Cardiovasc* **24**: 89-92, 2011.
6. James C, Ugo V, Le Couédic JP, et al. A unique clonal JAK2 mutation leading to constitutive signalling causes polycythaemia vera. *Nature* **434**: 1144-1148, 2005.
7. Saver JL, Carroll JD, Thaler DE, et al. Long-term outcomes of patent foramen ovale closure or medical therapy after stroke. *N Engl J Med* **377**: 1022-1032, 2017.
8. Søndergaard L, Kasner SE, Rhodes JF, et al. Patent foramen ovale closure or antiplatelet therapy for cryptogenic stroke. *N Engl J Med* **377**: 1033-1042, 2017.
9. Mas JL, Derumeaux G, Guillon B, et al. Patent foramen ovale closure or anticoagulation vs. antiplatelets after stroke. *N Engl J Med* **377**: 1011-1021, 2017.
10. Rigatelli G, Zuin M, Dell'Avvocata F, Roncon L, Vassilev D, Nghia N. Light anti-thrombotic regimen for prevention of device thrombosis and/or thrombotic complications after interatrial shunts device-based closure. *Eur J Intern Med* **74**: 42-48, 2020.

The Internal Medicine is an Open Access journal distributed under the Creative Commons Attribution-NonCommercial-NoDerivatives 4.0 International License. To view the details of this license, please visit (<https://creativecommons.org/licenses/by-nc-nd/4.0/>).