



Treatment Dilemma of Latrogenic Pseudoaneurysm of the Intracavernous Internal Carotid Artery in Young Girl Following Transnasal Transsphenoidal Surgery: A Case Report

Amit K. Sharma¹ Anita Jagetia¹ Ghanshyam D. Singhal¹ Shaam Bodeliwala¹ Arvind K. Srivastava¹ Daljit Singh¹

¹Department of Neurosurgery, Govind Ballabh Pant Institute of Postgraduate Medical Education and Research, New Delhi, India

Address for correspondence Amit Kumar Sharma, MBBS, MS, MCh, Department of Neurosurgery, Govind Ballabh Pant Institute of Postgraduate Medical Education and Research, New Delhi 110002, India (e-mail: Dr.amitsharma982@gmail.com).

AJNS 2022;17:112–115.

Abstract

Epistaxis following transnasal transsphenoidal (TNTS) removal of pituitary adenoma can be massive and life-threatening. The intracranial source of bleeding is usually the intracavernous segment of the internal carotid artery (ICA) or adjacent branches. Injury to the cavernous ICA can lead to pseudoaneurysm (PA) or fistula formation. Management of PA is different from saccular aneurysms. A timely diagnosis and adequate management can restore vessel integrity and prevent associated morbidity. A young patient of growth hormone-secreting pituitary adenoma, who underwent microscopic TNTS excision of the tumour, presented with massive epistaxis. Pseudoaneurysm of the cavernous ICA was initially not seen on computed tomography angiography and was later diagnosed on digital subtraction angiography. The attempted management of PA with coils without stent could not stop aneurysm recurrence. The management of such complicated PAs is discussed, and a literature review is done regarding epistaxis in growth hormone secreting adenoma.

Introduction

Epistaxis following transnasal transsphenoidal (TNTS) removal of pituitary adenoma can be massive and life-threatening.¹ The intracranial source of bleeding is usually the intracavernous segment of the internal carotid artery (ICA) or adjacent branches. Injury to the cavernous ICA can lead to pseudoaneurysm (PA) or fistula formation.² Management of PA is different from saccular aneurysm. The timely diagnosis and adequate management can restore vessel integrity and prevent associated morbidity.³ We are reporting a case of growth hormone-secreting pituitary adenoma in a young girl who underwent microscopic TNTS excision of the tumor and

had presented with massive epistaxis. Pseudoaneurysm of the cavernous ICA was not seen on computed tomography (CT) angiography initially and later diagnosed on digital subtraction angiography (DSA). The attempted management of PA with coils without stent could not stop aneurysm growth. The management of such complicated PAs is discussed, and a literature review is done regarding epistaxis in growth hormone (GH) secreting adenoma.

Case Report

Twenty-six-year old young unmarried female was diagnosed with growth hormone-secreting pituitary macroadenoma

published online
June 1, 2022

DOI <https://doi.org/10.1055/s-0042-1749178>.
ISSN 2248-9614.

© 2022. Asian Congress of Neurological Surgeons. All rights reserved.

This is an open access article published by Thieme under the terms of the Creative Commons Attribution-NonDerivative-NonCommercial-License, permitting copying and reproduction so long as the original work is given appropriate credit. Contents may not be used for commercial purposes, or adapted, remixed, transformed or built upon. (<https://creativecommons.org/licenses/by-nc-nd/4.0/>)

Thieme Medical and Scientific Publishers Pvt. Ltd., A-12, 2nd Floor, Sector 2, Noida-201301 UP, India

for the last 3 years with features of acromegaly. Magnetic resonance imaging revealed a sellar mass of size $1.5 \times 1.6 \times 1.7$ cm. The GH level was 27.8 ng/mL. The near-total tumor excision was done using a microscopic TNS approach. Tumor was greyish pink and soft with rubbery inconsistency. Intraoperatively, there was moderate bleeding and could be controlled without much effort. Seller floor was reconstructed with fat, cartilage, and bone. The next 48 hours were uneventful until the removal of the nasal pack, which resulted in torrential hemorrhage. The nasal cavity was repacked. The patient was stabilized hemodynamically, and CT angiography brain was done, which did not reveal any vascular injury (\rightarrow Fig. 1B). The patient was reoperated to remove the nasal pack, and the tumor bed was inspected for any bleeding point. There was no active bleed. The patient was discharged after 2 days. After 2 weeks of surgery, she had repeated minor epistaxis at home, followed by one episode of massive epistaxis. The patient was readmitted, and nasal gauze packing was done. The GH level was 7.8 ng/mL. Digital subtraction cerebral angiography was performed, which revealed a PA arising from the cavernous segment of the right ICA measuring 0.75×0.45 cm with no cross flow between two ICAs (\rightarrow Fig. 2A). Two ev3 (Covidien) three-dimensional coils $6 \text{ mm} \times 10 \text{ cm}$ and $3 \text{ mm} \times 6 \text{ cm}$ coils were placed within the aneurysmal sac to occlude the neck. A postoperative angiogram showed complete obliteration of the aneurysmal sac (\rightarrow Fig. 2B). The patient was discharged with no neurological deficits. Her features of acromegaly were resolving. Examining angiogram 6 weeks thereafter showed refilling of aneurysm and coil mass compaction (\rightarrow Fig. 3A). The aneurysm was recoiled, and since there was no residual filling of the aneurysm (\rightarrow Fig. 3B), no stent across the aneurysm neck was placed. However, checking DSA 4 weeks thereafter again revealed coil mass compaction with recurrence of the aneurysm. Ultimately stent-assisted coiling of the aneurysm was performed (\rightarrow Fig. 4A). At one-year follow-up the patient was asymptomatic with stable obliteration on MRI and MRA (\rightarrow Fig. 4B).

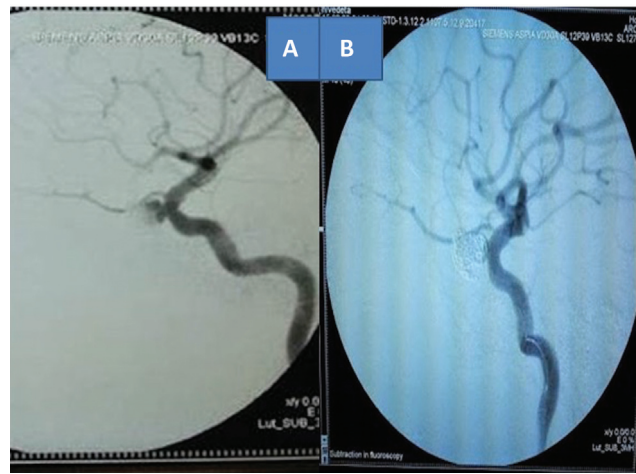


Fig. 2 (A) First digital subtraction angiography detected butterfly pseudoaneurysm of the cavernous segment of ICA (0.75×0.45 cm). (B) Post coiling DSA of aneurysm showed complete filling of sac.

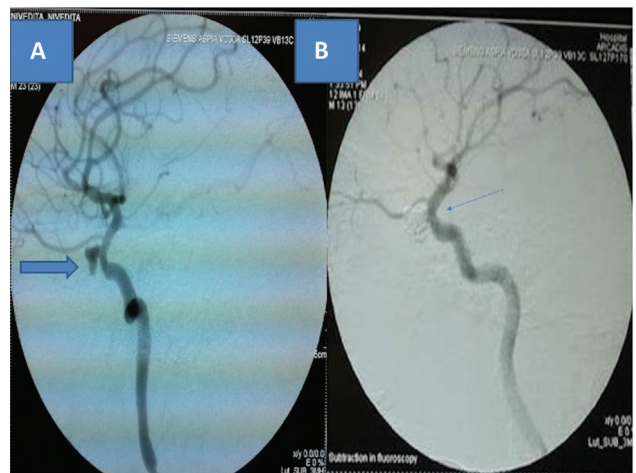


Fig. 3 (A) DSA after six weeks showed re-growth of pseudoaneurysm possible dissection of cavernous ICA. (B) Post-coiling DSA showing complete obliteration of aneurysm sac with reserved distal flow.

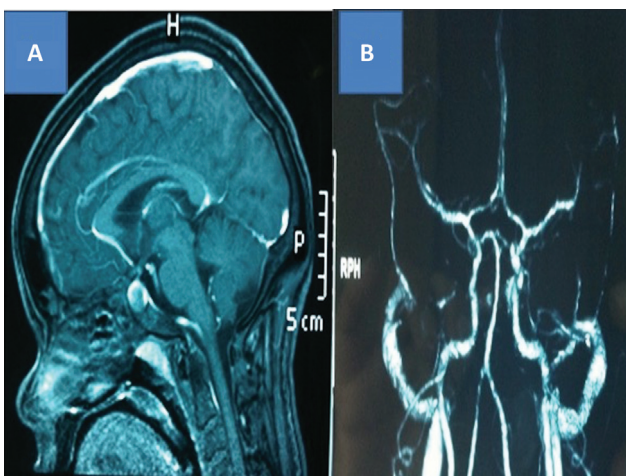


Fig. 1 (A) Sagittal view of Gadolinium-enhanced MRI showing contrast-enhanced pituitary macroadenoma. (B) Immediate Postoperative CT angiography of the brain after the first episode of epistaxis revealed no anatomic abnormality.

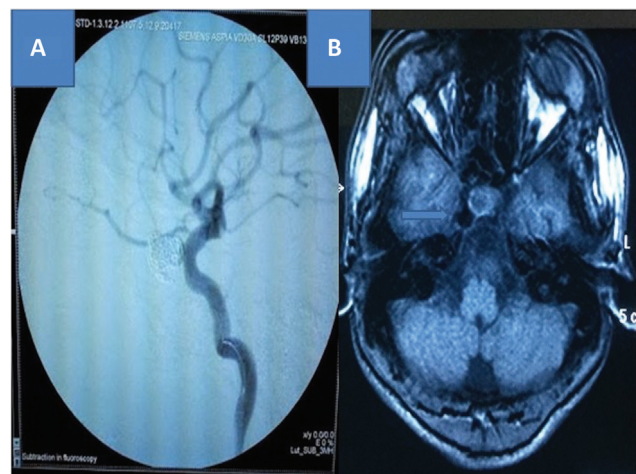


Fig. 4 (A) Digital subtraction angiogram showing stent-assisted coiling of ICA pseudoaneurysm with completely obliterated sac. (B) MRI (Axial T1 weighted) showing thrombosed stable aneurysm.

Studies	Age/Sex	Diagnosis	Time of diagnosis	Treatment	Outcome
Wilson et al ¹⁵	NR	Delayed epistaxis	NR	Carotid ligation	NR
Cabezudo et al ¹⁶	41/F	Delayed epistaxis	1 mo	Gradual closure of carotid with Selverstone clamp over 7 d	Good
Reddy et al ¹⁷	56/F	Angiogram	6 wk	The surgical clip of supraclinoid ICA and ligation of extracranial ICA	Good
Ahuja et al ¹⁸	52/F	Follow-up angiogram	9 d	Endovascular occlusion of ICA	Temporary hemiparesis
Raymond et al ¹⁹	28/F	Angiogram	10 d	Surgical packing	Good
Cappabianca et al ⁶	22/F	Angiogram	NR	Coil embolization of the aneurysm	NR
De Souza et al ⁵	38/F	Postoperative MRI	NR	Endovascular cover stent	Good
Cinar et al ⁹	69/M	Angiogram	9 d	Endovascular Parent artery occlusion	Expired on 12th day
Current case (2015)	26/F	Postoperative DSA	2 wk	Endovascular stent-assisted coiling	Good

Abbreviations: DSA, digital subtraction angiography; MRI, magnetic resonance imaging; NR, no response.

Discussion

The incidence of vascular injury following TNS is 0.2 to 1.2%.^{2,3} Massive epistaxis can be due to cavernous ICA injury, which may result in a carotid-cavernous fistula or PA.⁴⁻⁶ Injury to the ICA during transsphenoidal resection of pituitary tumors typically occurs during aggressive dissection of macroadenomas especially invading the cavernous sinus and encasing the ICA.^{6,7} Carotid injuries are more likely to occur in patients with previous transsphenoidal surgery or radiation therapy, invasive adenomas, endoscopic surgery, anatomical variations such as bulging of ICA into the sphenoid sinus or covered only by the dura mater of the cavernous sinus and the mucosa of the sphenoid sinus without bony covering.^{8,9} In the present case, the tumor was not very large, and the probable cause of injury would have been a deviation from midline reaching more toward the right side of the sella.

The diagnosis could not be made on a CT angiogram, the howsoever good quality it is as in the present case. Perhaps, the vessel at the focal site was in spasm or the CT angiogram was done with nasal pack in situ, which must have covered the injury site of ICA. However, the dissection kept growing, which led to aneurysm formation, and was diagnosed with DSA. Therefore, even if the CT angiogram is negative, DSA should be done, and if first DSA is negative, repeat DSA should be done after 2 to 4 weeks, and DSA/CTA should be repeated following nasal pack removal.^{1,3,10}

The size of iatrogenic intimal injury is most important to produce PA or dissecting aneurysm. If the injury is less than 2 mm, then most of the time, it heals without morphological changes. However, if the size of arterial injury is around 4 mm, then it has a high probability to produce an aneurysm, and if the size is more than 6 mm, then it would cause complete stenosis of the injured vessel.¹¹ In the present case as well the neck of the PA was approximately 4 mm, and the rent in the intima is approximate of the same size would have resulted in the formation of PA. There have been many reports of vascular injury in pituitary adenoma, but only eight cases of iatrogenic carotid PA in GH secreting

pituitary macroadenoma with acromegaly following transsphenoidal surgery were identified. Acromegalic patients are at a higher risk of sustaining this complication because of the distortion of the nasal-sinus anatomy and the tendency to have tortuous and ectatic carotid arteries, sometimes protruding into the sella.

Treatment options include carotid ligation to endovascular intervention. The endovascular procedure includes parent artery occlusion, coil embolization, stent-assisted coiling, covered stent placement, and onyx embolization.¹¹⁻¹⁴ Endovascular intervention is the most preferred approach. The management of PA differs from saccular nondissecting aneurysm. Since the repair of the intima is essential in dissecting aneurysms, only coiling may not work. The wall can heal by covering it with a stent. The risk of long-term anticoagulation to prevent stroke is a major concern. Our assumption of putting the coils and trying to achieve a good result was wrong as the treatment of dissecting aneurysm is the reconstruction of vessel. The treatment got stable only when a stent was placed across the neck of the aneurysm, which helped in healing the wall and prevented the subsequent flow of blood in the sac.

Conclusion

Delayed massive epistaxis is rare but is a serious complication of transsphenoidal surgery. Vessel wall healing is as important as occluding the pseudoaneurysm.

Funding

None

Conflict of Interest

None declared.

References

- Dusick JR, Esposito F, Malkasian D, Kelly DF. Avoidance of carotid artery injuries in transsphenoidal surgery with the Doppler probe and micro-hook blades. *Neurosurgery* 2007;60(04, Suppl 2):322-328, discussion 328-329

- 2 Crowley RW, Dumont AS, Jane JA Jr. Bilateral intracavernous carotid artery pseudoaneurysms as a result of sellar reconstruction during the transsphenoidal resection of a pituitary macroadenoma: case report. *Minim Invasive Neurosurg* 2009;52(01):44–48
- 3 Berker M, Aghayev K, Saatci I, Palaoglu S, Onerci M. Overview of vascular complications of pituitary surgery with special emphasis on unexpected abnormality. *Pituitary* 2010;13(02):160–167
- 4 Kachhara R, Menon G, Bhattacharya RN, et al. False aneurysm of cavernous carotid artery and carotid cavernous fistula: complications following transsphenoidal surgery. *Neurol India* 2003;51(01):81–83
- 5 de Souza JM, Domingues FS, Espinosa G, Gadelha M. Cavernous carotid artery pseudo-aneurysm treated by stenting in acromegalic patient. *Arq Neuropsiquiatr* 2003;61(2B):459–462
- 6 Cappabianca P, Briganti F, Cavallo LM, de Divitiis E. Pseudoaneurysm of the intracavernous carotid artery following endoscopic endonasal transsphenoidal surgery, treated by endovascular approach. *Acta Neurochir (Wien)* 2001;143(01):95–96
- 7 Tuchman A, Khalessi AA, Attenello FJ, Amar AP, Zada G. Delayed cavernous carotid artery pseudoaneurysm caused by absorbable plate following transsphenoidal surgery: case report and review of the literature. *J Neurol Surg Rep* 2013;74(01):10–16
- 8 Jagetia A, Rajan S, Sinha S, Singh D. Fatal epistaxis from the fetal posterior communicating artery—a delayed complication of trans-sphenoidal surgery. *J Clin Neurosci* 2010;17(05):656–658
- 9 Cinar C, Bozkaya H, Parildar M, Oran I. Endovascular management of vascular injury during transsphenoidal surgery. *Interv Neuro-radiol* 2013;19(01):102–109
- 10 Hattori I, Iwasaki K, Horikawa F, Tanji M, Gomi M. [Treatment of a ruptured giant internal carotid artery pseudoaneurysm following transsphenoidal surgery: case report and literature review]. *No Shinkei Geka* 2006;34(11):1141–1146
- 11 Okamoto T, Miyachi S, Negoro M, et al. Experimental model of dissecting aneurysms. *AJNR Am J Neuroradiol* 2002;23(04):577–584
- 12 Saatci I, Cekirge HS, Ozturk MH, et al. Treatment of internal carotid artery aneurysms with a covered stent: experience in 24 patients with mid-term follow-up results. *AJNR Am J Neuro-radiol* 2004;25(10):1742–1749
- 13 Ahuja V, Tefera G. Successful covered stent-graft exclusion of carotid artery pseudo-aneurysm: two case reports and review of literature. *Ann Vasc Surg* 2007;21(03):367–372
- 14 Kadyrov NA, Friedman JA, Nichols DA, Cohen-Gadol AA, Link MJ, Piegras DG. Endovascular treatment of an internal carotid artery pseudoaneurysm following transsphenoidal surgery. Case report. *J Neurosurg* 2002;96(03):624–627
- 15 Wilson CB, Dempsey LC. Transsphenoidal microsurgical removal of 250 pituitary adenomas. *Journal of neurosurgery* 1978;48(1):13–22.
- 16 Cabezudo JM, Carrillo R, Vaquero J, Areitio E, Martinez R. Intracavernous aneurysm of the carotid artery following transsphenoidal surgery: Case report. *Journal of Neurosurgery* 1981;54(1):118–121.
- 17 Reddy K, Lesiuk H, West M, Fewer D. False aneurysm of the cavernous carotid artery: a complication of transsphenoidal surgery. *Surgical neurology* 1990;33(2):142–145.
- 18 Ahuja A, Guterman LR, Hopkins LN. Carotid cavernous fistula and false aneurysm of the cavernous carotid artery: complications of transsphenoidal surgery. *Neurosurgery* 1992;31(4):774–779.
- 19 Raymond J, Hardy J, Czepko R, Roy D. Arterial injuries in transsphenoidal surgery for pituitary adenoma; the role of angiography and endovascular treatment. *American Journal of Neuroradiology* 1997;18(4):655–665.