

Available online at www.sciencedirect.com

ScienceDirect

journal homepage: www.elsevier.com/locate/radcr

Case Report

A rare case of synchronous mucosa-associated lymphoid tissue (MALT) lymphoma involving bilateral breasts and subcutaneous tissues [☆]

Cecile D Moliva Anendaga, MD, Madhavi Raghu, MD, Jaime L Szarmach, MD, Seema Bakhru, MD, Francis T Flaherty, MD, Gilda Boroumand, MD*

Department of Radiology, Norwalk Hospital, 34 Maple Street, Norwalk, CT 06850, USA

ARTICLE INFO

Article history:

Received 10 May 2022

Revised 27 July 2022

Accepted 31 July 2022

Keywords:

Secondary breast lymphoma

MALT lymphoma

B-cell lymphoma

Synchronous lymphoma

Subcutaneous lymphoma

ABSTRACT

Marginal zone lymphoma of mucosa-associated lymphoid tissue is a B-cell lymphoma which arises in extranodal sites, most commonly the stomach. Involvement of the breast is very rare. We present a case of an asymptomatic 63-year-old woman with synchronous mucosa-associated lymphoid tissue lymphoma involving both breasts and subcutaneous tissues. This represents a form of secondary breast lymphoma (given the concurrent involvement of the breast and non-mammary organ systems) and is an exceedingly rare diagnosis which, to our knowledge, has only been discussed in a few case series.

© 2022 The Authors. Published by Elsevier Inc. on behalf of University of Washington.

This is an open access article under the CC BY-NC-ND license

(<http://creativecommons.org/licenses/by-nc-nd/4.0/>)

Introduction

Secondary breast lymphoma, which may be diagnosed in the setting of concurrent involvement of non-mammary organ systems, is a rare entity with a prevalence of 0.07%. It accounts for 0.4%–0.9% of all breast malignancies and 17% of all metastatic breast malignancies [1]. B-cell subtypes of non-Hodgkin lymphomas account for the majority of breast lymphomas. Extranodal presentation of marginal zone mucosa-associated lymphoid tissue (MALT) lymphoma of the breast is a low-grade B-cell lymphoma that represents an exceptionally rare diagnosis, accounting for less than 10% of breast lymphomas [2,3]. Even rarer still is the diagnosis of

synchronous MALT lymphoma involving the breast and subcutaneous tissues. We report the case of a 63-year-old woman with bilateral breast and diffuse subcutaneous involvement by MALT lymphoma, highlighting the challenge in diagnosing such a rare entity in an asymptomatic patient.

Case presentation

A 63-year-old woman with a family history of breast cancer in her mother (diagnosed at age 52) presented to our institution for a screening mammogram. The study showed a 1.6 cm new asymmetry in the posterior superior region of the right breast

[☆] Competing Interests: None.

* Corresponding author.

E-mail address: gilda.boroumand@nuvancehealth.org (G. Boroumand).

<https://doi.org/10.1016/j.radcr.2022.07.105>

1930-0433/© 2022 The Authors. Published by Elsevier Inc. on behalf of University of Washington. This is an open access article under the CC BY-NC-ND license (<http://creativecommons.org/licenses/by-nc-nd/4.0/>)

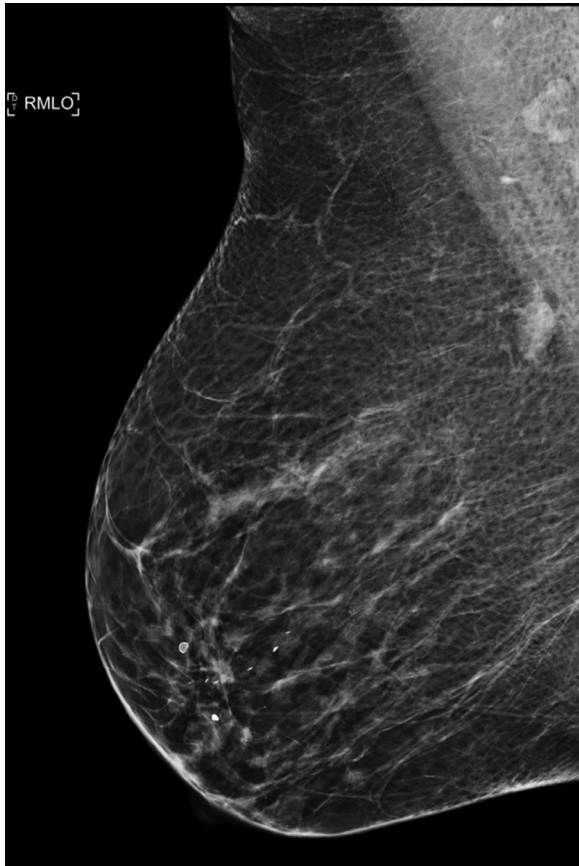


Fig. 1 – Screening mammogram. Medial lateral oblique (MLO) view of the right breast demonstrates an asymmetry in the superior breast at posterior depth.

present on the MLO view only (Fig. 1). Subsequent limited ultrasound demonstrated a 1.5 cm mass in the upper inner breast at the 1 o'clock position (Fig. 2), which was thought to possibly represent an intramammary lymph node with cortical thickening. The patient underwent ultrasound-guided biopsy which yielded reactive lymphoid tissue, without evidence of metastatic carcinoma or definitive evidence of lymphoma. This was thought to be concordant with imaging

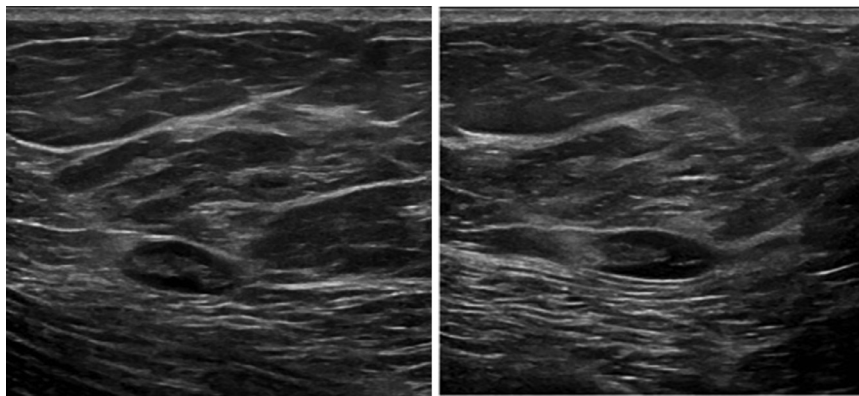


Fig. 2 – Radial (left) and anti-radial (right) gray scale ultrasound images of the right breast demonstrate a 1.5 cm mass in the upper inner breast which resembles an intramammary lymph node with mild cortical thickening. This correlates with the asymmetry on mammogram.

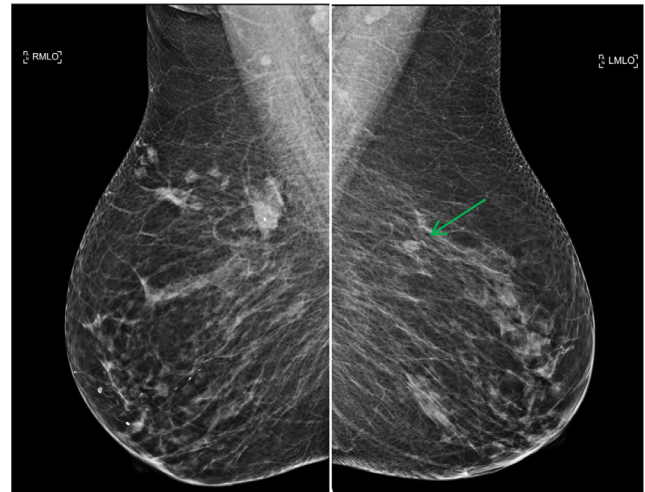


Fig. 3 – Diagnostic mammogram. MLO view of the right breast (left image) shows multiple new irregular masses in the superior breast and increased prominence of the previously biopsied mass which contains a biopsy clip. MLO view of the left breast (right image) shows a new mass in the superior breast (arrow).

findings, but surgical consultation was recommended given the unusual location and appearance of the lymph node. A follow-up ultrasound performed 3 months later demonstrated no significant change and the finding was given a BI-RADS 3 (probably benign) assessment. One year after her initial presentation, bilateral diagnostic mammogram (Fig. 3) and ultrasound (Fig. 4) demonstrated multiple new irregular masses in both breasts and increased prominence of the previously biopsied mass in the upper inner right breast. Bilateral ultrasound-guided biopsies of the 3 most dominant masses were performed. Histological examination of all 3 biopsy sites yielded lymphoid tissues with atypical lymphoid cell infiltrate, supporting a diagnosis of low-grade B-cell lymphoma with features consistent with extranodal marginal zone lymphoma of mucosa associated lymphoid tissue (MALT Lymphoma). IGH rearrangement studies confirmed B-cell clonality. FISH analysis was negative for MALT1 rearrangement.

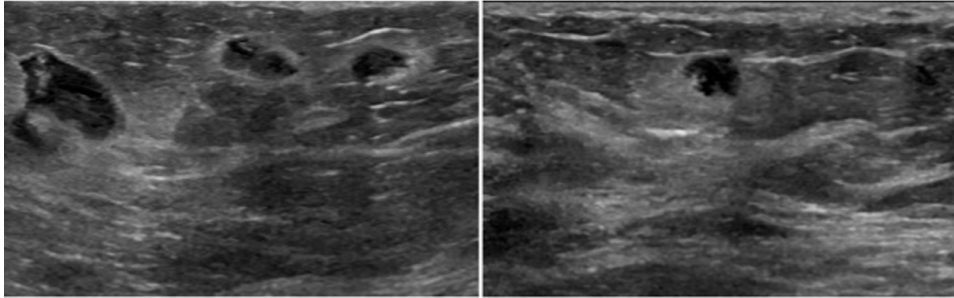


Fig. 4 – Gray scale ultrasound images demonstrate multiple irregular, hypoechoic masses with angular margins in the right breast (left image) and a similar-appearing mass in the left breast (right image). These correlate with the masses noted on mammogram.

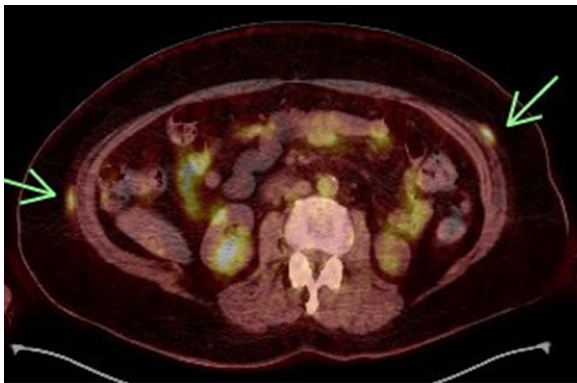

Fig. 5 – PET-CT shows increased metabolic activity in subcutaneous nodules in the abdominal wall (arrows). Multiple similar nodules were identified in the subcutaneous tissues of the chest, abdomen, and pelvis.

The patient reported no B symptoms, and 12-point review of systems was negative. Physical exam was normal. A staging PET-CT showed increased metabolic activity in right axillary lymph nodes, in the bilateral breast masses, as well as in innumerable subcutaneous nodules throughout the chest, abdomen, and pelvis (Fig. 5). A small focus of increased metabolic activity was also identified in the proximal stomach, but subsequent esophagogastroduodenoscopy (EGD) was negative for malignancy. Testing for *H. Pylori* infection, which has been associated with MALT lymphoma, was also negative. Bone marrow biopsy did not demonstrate any involvement by lymphoma. Based on the Ann Arbor classification, the patient was diagnosed with stage IV/advanced disease extranodal MALT lymphoma involving the breast, subcutaneous soft tissues, and lymph nodes.

Although the patient remained asymptomatic, systemic therapy was initiated due to her high disease burden. She received 4 weekly cycles of systemic chemotherapy with rituximab. A PET-CT performed one month after completion of therapy showed resolution of nearly all areas of prior increased metabolic activity, thus fulfilling the Lugano criteria for complete response to therapy. The patient will undergo active surveillance comprised of PET-CT every 6 months and bloodwork every 3 months for the first 2 years.

Discussion

Primary considerations for breast lymphomas include: diffuse large B-cell lymphoma (which is the most common subtype); follicular, marginal zone, and mantle cell lymphomas; and chronic lymphocytic leukemia/small lymphocytic lymphoma. A subtype of marginal zone lymphoma, mucosa associated lymphoid tissue (MALT) lymphoma is a low-grade B-cell lymphoma arising in extranodal sites. MALT lymphoma makes up less than 10% of breast lymphomas. Conversely, the breast is the site of disease in only 4% of cases of primary MALT lymphoma, with the stomach accounting for the site of origin in about 50% of patients [4].

Synchronous MALT lymphoma involving the breast and subcutaneous tissues is exceptionally rare and, to our knowledge, has only been discussed in a few case series. Jonak et al. have speculated that the breast, subcutaneous tissues, and ocular adnexa may be immunologically linked based on their observation that of their 216 patients with MALT lymphoma, all 12 who had subcutaneous disease had initially been diagnosed with MALT involvement of the breast or ocular adnexa [5]. In their case series, no patients with GI, salivary, or lung involvement were observed to have subcutaneous spread. Bailey et al. reported on 15 patients with MALT lymphoma involving the skin and subcutaneous tissues, and concluded that these lymphomas have a tendency to affect middle-aged to older women [6]. Of their 15 patients, 3 had concurrent MALT lymphoma involving both subcutaneous tissue and an extracutaneous site (one of which included the breast) at the time of primary diagnosis.

The majority of women with lymphoma of the breast are diagnosed by evaluation of a palpable breast mass [7]. Studies have shown only 3%-10% of breast lymphomas present as clinically occult findings identified by screening mammography, and the majority of these are secondary breast lymphomas, as in our case [1,8,9]. Both primary and secondary breast lymphomas most commonly manifest as a single breast mass, although secondary lymphomas are more likely to present with multiple and/or bilateral findings [1,9].

If there is a clinical suspicion for lymphoma, at least one core biopsy specimen should be placed in Roswell Park Memorial Institute (RPMI) medium. Unlike formalin, which is used for most other core biopsy specimens, RPMI medium is not a

fixative, but rather a culture medium that is used to support cell viability in biopsy samples. Therefore, it is used for flow cytometry, cytogenetics, and molecular studies, which require fresh, unfixed specimens. In breast imaging, RPMI medium is typically used when lymph node tissue is sampled to evaluate for lymphoma. Flow cytometry can be used to detect a monoclonal population of lymphocytes, and thereby lead to or support the findings of lymphoma by tissue diagnosis. Occasionally, flow cytometry findings alone lead to the diagnosis of lymphoma. This highlights the importance of using RPMI medium in the correct clinical setting. In our case, however, core biopsy samples from the breast masses were only placed in formalin as there was not sufficient clinical suspicion for breast lymphoma.

MALT lymphomas are low-grade, indolent lymphomas with overall good outcomes following various forms of treatment, regardless of stage [3,4]. Surgical excision may be performed in some cases for diagnostic purposes or as part of initial treatment, but surgical options do not seem to reduce local recurrence rates or improve survival for low-grade breast lymphomas [3,10–12]. Radiation therapy provides excellent local control in patients with early-stage disease, and is recommended for early-stage non-gastric MALT lymphomas [10]. Subsequent disease progression with relapses at distant sites is common, and non-gastric MALT lymphoma has been shown to be more likely to recur than gastric MALT lymphoma [4]. However, most relapses are responsive to systemic treatments. Asymptomatic cases of advanced stage disease may be managed with close observation or, alternatively, with chemotherapy, as in the case of our patient [3,13]. The rarity of MALT lymphoma precludes large-scale prospective studies evaluating treatment, clinical course, and long-term outcomes, and creates challenges in therapeutic decision-making.

Patient consent

Informed consent for publication of this case was obtained from the patient.

REFERENCES

- [1] Raj SD, Shurafa M, Shah Z, Raj KM, Fishman MDC, Dialani VM. Primary and secondary breast lymphoma: clinical, pathologic, and multimodality imaging review. *RadioGraphics* 2019;39(3):610–25. doi:10.1148/rg.2019180097.
- [2] Khalil MO, Morton LM, Devesa SS, Check DP, Curtis RE, Weisenburger DD, Dores GM. Incidence of marginal zone lymphoma in the United States, 2001–2009 with a focus on primary anatomic site. *Br J Haematol* 2014;165(1):67–77. doi:10.1111/bjh.12730.
- [3] Martinelli G, Ryan G, Seymour JF, Nassi L, Steffanoni S, Alietti A, et al. Primary follicular and marginal-zone lymphoma of the breast: clinical features, prognostic factors and outcome: a study by the International Extranodal Lymphoma Study Group. *Ann Oncol* 2009;20(12):1993–9. doi:10.1093/annonc/mdp238.
- [4] Thieblemont C, Basion Y, Berger F, Rieux C, Salles G, Dumontet C, et al. Mucosa-associated lymphoid tissue gastrointestinal and nongastrointestinal lymphoma behavior: analysis of 108 patients. *J Clin Oncol* 1997;15(4):1624–30. doi:10.1200/JCO.1997.15.4.1624.
- [5] Jonak C, Troch M, Kieseewetter B, Lukas J, Müllauer L, Jäger U, et al. Subcutaneous dissemination pattern in extranodal marginal zone B-cell lymphoma of mucosa-associated lymphoid tissue (MALT) lymphoma. *Haematologica* 2012;97(5):766–70. doi:10.3324/haematol.2011.057422.
- [6] Bailey EM, Ferry JA, Harris NL, Mihm MC Jr, Jacobson JO, Duncan LM. Marginal zone lymphoma (low-grade B-cell lymphoma of mucosa-associated lymphoid tissue type) of skin and subcutaneous tissue: a study of 15 patients. *Am J Surg Pathol* 1996;20(8):1011–23. doi:10.1097/00000478-199608000-00010.
- [7] Surov A, Holzhausen H-J, Wienke A, Schmidt J, Thomssen C, Arnold D, et al. Primary and secondary breast lymphoma: prevalence, clinical signs and radiological features. *Br J Radiol* 2012;85(1014):e195–205. doi:10.1259/bjr/78413721.
- [8] Domchek SM, Hecht JL, Fleming MD, Pinkus GS, Canellos GP. Lymphomas of the breast: primary and secondary involvement. *Cancer* 2002;94(1):6–13. doi:10.1002/cncr.10163.
- [9] Talwalkar SS, Miranda RN, Valbuena JR, Routbort MJ, Martin AW, Medeiros LJ. Lymphomas involving the breast: a study of 106 cases comparing localized and disseminated neoplasms. *Am J Surg Pathol* 2008;32(9):1299–309. doi:10.1097/PAS.0b013e318165eb50.
- [10] Ludmir EB, Milgrom SA, Pinnix CC, Gunther Jillian R, Westin J, Fayad LE, et al. Emerging treatment strategies for primary breast extranodal marginal zone lymphoma of mucosa-associated lymphoid tissue. *Clin Lymphoma Myeloma Leuk* 2019;19(4):244–50. doi:10.1016/j.clml.2018.12.016.
- [11] Koganti SB, Lozada A, Curras E, Shah A. Marginal zone lymphoma of the breast—a diminished role for surgery. *Int J Surg Case Rep* 2016;25:4–6. doi:10.1016/j.ijscr.2016.05.041.
- [12] Jennings WC, Baker RS, Murray SS, Howard CA, Parker DE, Peabody LF, et al. Primary breast lymphoma: the role of mastectomy and the importance of lymph node status. *Ann Surg* 2007;245(5):784–9. doi:10.1097/01.sla.0000254418.90192.59.
- [13] Talluri S, Subramanian CR, Werner E, Kasireddy V, Philip L. Bilateral primary marginal zone lymphoma of the breast—a rare breast malignancy. *In Vivo* 2020;34(6):3597–600. doi:10.21873/invivo.12204.