

EXPRESSION OF HLA-DR MOLECULES BY
KERATINOCYTES, AND PRESENCE OF LANGERHANS
CELLS IN THE DERMAL INFILTRATE OF ACTIVE
PSORIATIC PLAQUES

BY ALICE B. GOTTLIEB,* BEN LIFSHITZ,* SHU MAN FU,‡
LISA STAIANO-COICO,§ CHANG YI WANG,¶ AND D. MARTIN CARTER*

*From the *Laboratories of Immunology and Investigative Dermatology, The Rockefeller University, New York 10021; the ‡Immunology Program, Oklahoma Medical Research Foundation, Oklahoma City, Oklahoma 73104; the §Department of Surgery, New York Hospital-Cornell Medical Center, New York 10021; and the ¶Department of Research and Medicine, North Shore University Hospital-Cornell University Medical College, Manhasset, New York 11030*

Psoriasis is a common disease characterized by raised, scaly, erythematous lesions. The histologic changes include epidermal hyperplasia, inflammatory cell infiltrates, and increased cell turnover. Previous investigations (1-9) indicate that immunological injury may be an important mechanism in its pathogenesis. Immunohistochemical studies reveal that active psoriasis is associated with epidermal influx of activated T cells, and resolution is associated with suppressor T cells in the epidermis. In both cases, T lymphocytes are in close physical proximity to epidermal dendritic cells (10).

The importance of HLA-DR molecules in various immunological responses has been well documented (reviewed in 11). In normal skin, HLA-DR expression is confined to Langerhans cells with Birbeck granules (12, 13), indeterminate cells without Birbeck granules (13), and acrosyringeal epithelium (14, 15). HLA-DR expression by keratinocytes has been reported (16-19) in several human dermatoses characterized by mononuclear infiltrates. In the case of psoriasis, a recent study (20) reported the focal expression of HLA-DR antigens in epidermal cells. However, the nature of these cells was not well characterized. In view of the expression of HLA-DR antigens on activated T cells and Langerhans cells and the presence of those cells in the epidermis of active psoriatic lesions (10), and the failure of other investigators to identify HLA-DR⁺ keratinocytes (17, 21), we have undertaken a detailed analysis of a large series of patients with psoriasis. Qualitative studies of tissue sections and quantitative studies of epidermal suction blisters revealed HLA-DR expression by keratinocytes in a significant

This work was partially supported by grants AM35676, AM34485, AM34211, CM57720, and AI19080 from the U. S. Public Health Service, by The New York Chapter of the Arthritis Foundation, The Psoriasis Association of Florida, and the John A. and George L. Hartford Foundation. This research was also supported in part by a General Clinical Research Center Grant (RR00102) from the National Institutes of Health (Bethesda, MD) to The Rockefeller University Hospital, and with general support from the Pew Trusts.

proportion of the patients. In general, these patients had more severe disease, and the abnormality was reversible with successful therapy.

Materials and Methods

Skin Biopsies and Epidermal Suction Blisters. Biopsies of lesional and normal-appearing skin from 20 patients with psoriasis vulgaris and one patient with pustular psoriasis of the von Zumbusch type were taken after informed consent was obtained in compliance with a protocol approved by The Rockefeller University Hospital Institutional Review Board. As controls, skin biopsies were also obtained from individuals with other inflammatory dermatoses, including six cases of advanced scleroderma, three cases of lichen planus, and one case each of discoid lupus erythematosus, lupus profundus, cutaneous vasculitis, spongiotic dermatitis, nummular eczema, dermatomyositis, erythema multiforme, and subcorneal pustular dermatitis.

Epidermal suction blisters from psoriasis patients and normal individuals were generated with a temperature of 38°C and a negative pressure of 280 pounds per square inch using an apparatus designed by Dr. Alan Lipton (The Rockefeller University). Single-cell suspensions of keratinocytes were obtained by trypsinization of epidermal sheets (22).

Patients received 2–3 wk therapy with topical tar or anthralin and UV-B irradiation. Two of the patients received 6 mo of treatment with etretinate (11-*cis*-retinoic acid, Hoffman-La Roche, Nutley, NJ). One patient was treated for 2 mo with topical and systemic corticosteroids, and methotrexate. At the time posttreatment skin biopsies and suction blisters were obtained, all patients had at least 50% improvement in erythema, plaque elevation, and scaling.

Immunoreagents. mAb Josh 524.4.1 (IgG1) is directed against a nonpolymorphic determinant of the human HLA-DR molecule, and immunoprecipitates a 29/34 kD bimolecular complex (23). mAb CM 161.1 is specific for a determinant on the HLA-DQ molecule. Sequential immunoprecipitation studies (L. K. L. Jung, unpublished observation) show that it detects the same molecule as does mAb Leu-10 (Becton Dickinson Monoclonal Center, Mountain View, CA). Two mAbs directed against IFN- γ were used. One was purchased from Interferon Sciences, Inc. (New Brunswick, NJ). The other, A7, was prepared as previously reported (24). mAbs directed against the T3, T4, and T6 molecules and mAb 63D3 were obtained by culturing hybridoma cell lines obtained from the American Type Culture Collection (Rockville, MD). mAb B1 was purchased from Coulter Immunology (Hialeah, FL). mAbs OKT8 and FITC-labelled OKT6 were obtained from Ortho Diagnostic Systems (Raritan, NJ). mAb AT-1 is directed against the IL-2 receptor and is equivalent to anti-Tac (25). FITC and tetramethylrhodamine isothiocyanate-labelled Fab'₂ fragments of a goat anti-mouse IgG were purchased from Tago, Inc., (Burlingame, CA).

Immunoperoxidase Studies. Immunoperoxidase studies of formalin-fixed tissue sections were performed as previously described (26) using the Vectastain ABC immunoperoxidase staining system (Vector Laboratories, Burlingame, CA).

Immunofluorescence Studies. Immunofluorescence studies of tissue sections were performed as follows: 6- μ m-thick frozen tissue sections were fixed in either cold acetone or phosphate-buffered formalin, and washed in PBS. The sections were incubated with mouse mAbs for 30–60 min at room temperature, followed by further washes in PBS. Nonspecific staining was blocked by incubation with a 1:10 dilution of normal goat serum followed by washes in PBS. The sections were then incubated with FITC-labelled Fab'₂ fragments of a goat anti-mouse IgG antibody for 60 min at room temperature, followed by washes in PBS. Coverslips were mounted with polyvinyl alcohol and read with a Leitz Ortholux II fluorescence microscope (E. Leitz, Wetzlar, Federal Republic of Germany). Keratinocytes were tested with mouse mAbs by indirect immunofluorescence as previously described (27), using either a Leitz Ortholux 2 fluorescence microscope (E. Leitz) or an Ortho System 50H cell sorter (28) (Ortho Diagnostic Instruments, Westwood, MA).

For double-labelling immunofluorescence experiments, two different types of experiments were performed. In the first, formalin-fixed, washed skin sections were incubated

with mAb Josh 524.4.1 for 30 min at room temperature, washed in PBS, and then incubated with normal goat serum for 30 min at room temperature. Following washing and incubation for 60 min at room temperature with tetramethyl-rhodamine isothiocyanate-labelled Fab'₂ fragments of a goat anti-mouse IgG antibody, skin sections were washed and then incubated with a 1:8 dilution of FITC-labelled OKT6 for 30 min at room temperature. After washing for 90 min in PBS, coverslips were mounted, and slides were examined. It was possible that the rhodamine-labelled goat anti-mouse IgG antibody could have reacted with the fluorescein-labelled mAb OKT6. This was assessed by incubating normal or psoriatic skin sections with the basal layer-reactive mAb EL-2 (22), followed by incubation with the rhodamine-labelled goat anti-mouse IgG antibody and then fluorescein-conjugated mAb OKT6. Fluorescein fluorescence was observed on only epidermal dendritic cells, while rhodamine fluorescence was confined to the basal epidermal layer. These findings indicate that the rhodamine-conjugated goat anti-mouse IgG antibody did not bind significantly to the fluorescein-labelled mAb OKT6. In the second set of experiments, formalin-fixed, washed skin sections were incubated for 30 min at room temperature with a 1:10 dilution of normal goat serum. After washing, they were incubated with a 1:4 dilution of tetramethyl rhodamine isothiocyanate-conjugated Fab'₂ fragments of an anti-HLA-DR antiserum (29) for 30 min at room temperature. After washing, the sections were incubated with a 1:8 dilution of FITC-labelled OKT6 for 30 min at room temperature. After washing in PBS for 90 min, coverslips were mounted and slides were examined.

Results

Lesional Psoriatic Skin Contains HLA-DR⁺ Keratinocytes. Skin sections from 21 patients with active psoriasis were stained with mAb Josh 524.4.1, which is directed against a nonpolymorphic determinant of the HLA-DR molecule. Skin sections from 8 of 21 patients had HLA-DR-bearing keratinocytes, often in foci (Fig. 1a). The expression of HLA-DQ antigens was also examined using mAb 161.1, kindly provided by Dr. Laurence Jung. This mAb stained a subpopulation of presumptive Langerhans cells and cells in the dermal infiltrate, but failed to stain any HLA-DR⁺ keratinocytes.

To characterize these HLA-DR⁺ cells, double-labelling immunofluorescence was performed with Josh 524.4.1 and OKT6 on skin sections from eight patients. The vast majority of epidermal cells were reactive with Josh 524.4.1 (Fig. 1b), but not with OKT6 (Fig. 1c). The small proportion of cells that stained with both Josh 524.4.1 and OKT6 were presumably Langerhans cells (30). The results were confirmed with double-labelling immunofluorescence experiments using tetramethyl-rhodamine isothiocyanate-conjugated Fab'₂ fragments of an anti-HLA-DR antiserum and FITC-labelled OKT6. No HLA-DR⁺ keratinocytes were found in the normal appearing skin of six of six patients, although HLA-DR⁺, OKT6⁺ Langerhans cells were observed in the epidermis. Studies of lesional skin from the remaining 13 patients show that their keratinocytes were HLA-DR⁻. Epidermal HLA-DR staining was not due to lymphocytes or monocytes infiltrating the epidermis, because no epidermal reactivity was observed with mAb OKT3, B1, and 63D3, which stain peripheral T cells, B cells and monocytes, respectively. These mAbs stained appropriate regions of sectioned lymph nodes by the immunoperoxidase method we used.

Dermal Infiltrate of Lesional Psoriatic Skin Contains Activated T Cells, Macrophages, and Langerhans Cells. We also studied the dermal infiltrate of lesional psoriatic skin. In patients with (Fig. 2a) or without (Fig. 2g) HLA-DR⁺ kerati-

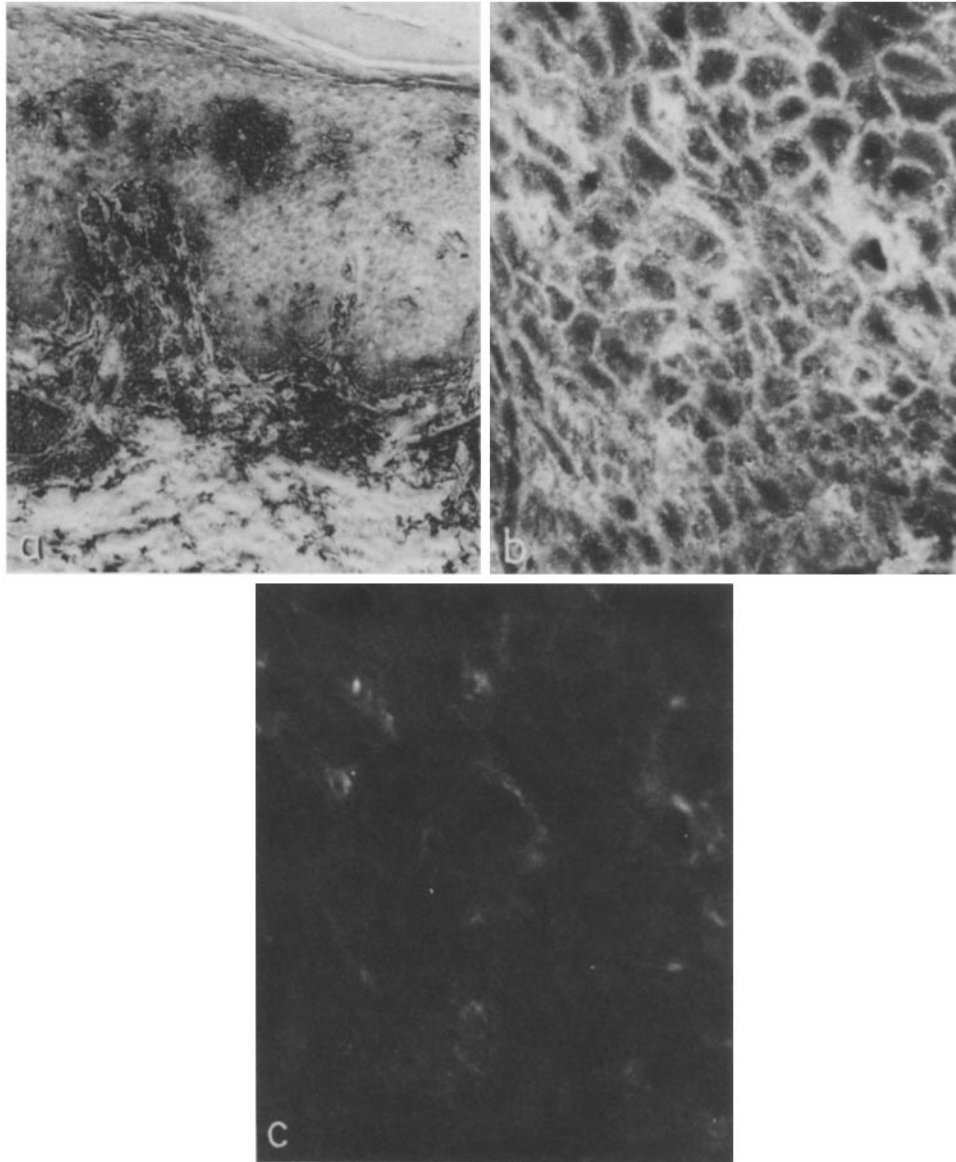


FIGURE 1. Reactivity of lesional psoriatic skin with mAbs Josh 524.4.1 and OKT6. (a) Immunoperoxidase staining of lesional skin (before treatment) from psoriasis patient MC with mAb Josh 524.4.1 reveals multiple foci of epidermal staining $\times 326$. (b and c) Double-labelling immunofluorescence staining of a psoriatic plaque from patient RN. $\times 1,300$. The same field is viewed after staining with mAb Josh 524.4.1 followed by tetramethyl rhodamine isothiocyanate-labelled Fab'2 fragments of a goat anti-mouse IgG antibody (b), and FITC-labelled OKT6 (c). The vast majority of epidermal cells were reactive with mAb Josh 524.4.1, but not mAb OKT6.

nocytes, many OKT3⁺ lymphocytes were observed in pretreatment psoriatic plaques (Fig. 2, b and h). Essentially all of the cells in the dermal infiltrates from both patients were stained by Josh 524.4.1, (Fig. 2, a and g). To further confirm

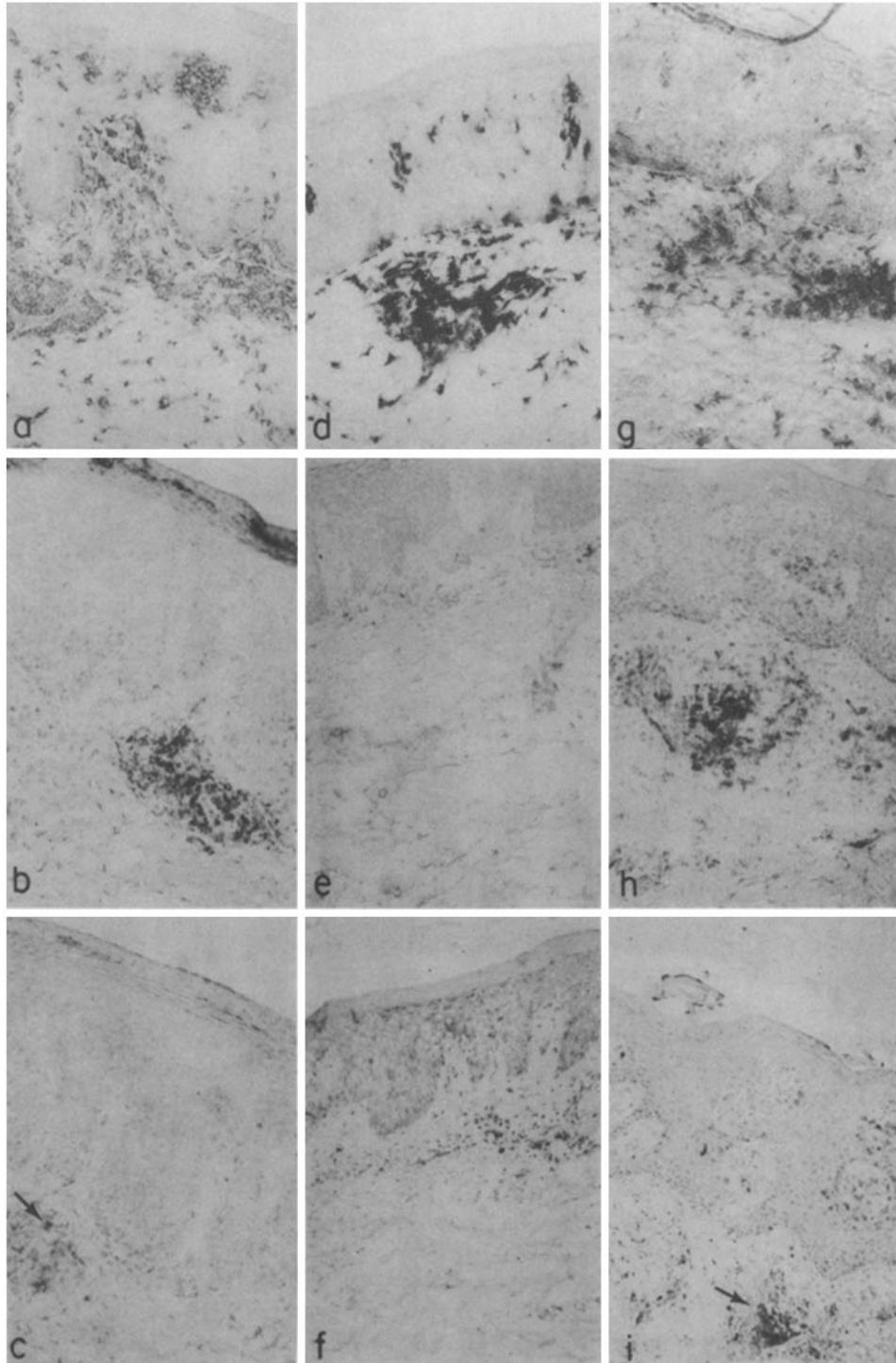


FIGURE 2. Characterization of the dermal infiltrate in psoriatic plaques by immunoperoxidase staining with mAbs. $\times 250$. Psoriatic plaque (before treatment) from patient MC stained with (a) mAb Josh 524.4.1; (b) mAb OKT3; (c) mAb AT-1. Psoriatic plaque from patient MC after 3 wk of therapy with topical tar and UV-B irradiation, and stained with (d) mAb Josh 524.4.1; (e) mAb OKT3; (f) mAb AT-1. Psoriatic plaque (before treatment) from patient JE stained with (g) mAb Josh 524.4.1; (h) mAb OKT3; (i) mAb AT-1. Black arrows in *c* and *i* point to positively-stained cells.

the presence of activated T cells, the sections were stained with mAb AT-1, which is specific for the IL-2 receptor (25). Seven of eight patients with HLA-DR⁺ keratinocytes showed significant AT-1 staining of the dermal infiltrate in pretreatment plaques (Fig. 2c). Only a minority of cells was stained with AT-1. In contrast, only three of nine plaques that lacked HLA-DR⁺ keratinocytes were associated with significant AT-1 staining of the dermal infiltrate (Fig. 2i). In these three patients, the pattern of AT-1 reactivity was indistinguishable from that seen in the dermis of patients with HLA-DR⁺ keratinocytes. In general, the number of AT-1-reactive cells was greatest in plaques with dense dermal infiltrates.

Further characterization of the dermal infiltrate from active psoriatic plaques suggested that Langerhans cells were present in addition to activated T lymphocytes. Psoriatic plaques from 16 of 18 patients had foci of OKT6⁺ cells within the dermal infiltrate. A cluster of OKT6⁺ cells is evident in Fig. 3a, and is surrounded by cells that stained with mAb OKT3 or 63D3 in serial sections (Fig. 2b). In contrast, OKT6⁺ cells were either absent, or present in only very low numbers in the dermal infiltrate of normal-appearing skin from psoriasis patients. Lesional skin from two patients with lichen planus, another condition characterized by the presence of HLA-DR⁺ keratinocytes and activated dermal T cells, had many OKT6⁺ cells in the dermal infiltrate (Fig. 3b). In addition, dermal infiltrates from patients with contact dermatitis, spongiotic dermatitis, and erythema multiforme contained foci of OKT6⁺ cells in a pattern indistinguishable from that seen in psoriatic plaques. Four patients with basal cell carcinoma and one patient with squamous cell carcinoma of the lip were studied, and all had significant numbers of OKT6⁺ cells scattered among the tumor islands (Fig. 3c).

Quantitation of HLA-DR Molecule Expression Using Epidermal Suction Blisters. Single-cell suspensions were prepared by trypsinization of epidermal suction blisters, and were used to further characterize HLA-DR⁺ keratinocytes. As published previously (22), these suspensions contained <1% nonkeratinocytes. No significant lymphocyte or monocyte contamination was present, since no reactivity was observed with mAbs OKT3, B1, and 63D3. Cells from six of eight active psoriasis patients with keratinocyte HLA-DR reactivity were studied (Table I). Keratinocytes isolated from active psoriatic plaques showed a range of 7–84% of cells reactive with mAb Josh 524.4.1. <5% of the same cell population reacted with mAb OKT6, a Langerhans cell-reactive mAb. In general, the proportion of HLA-DR⁺ epidermal cells in single-cell suspensions correlated with qualitative estimates obtained from studies of skin biopsies. Keratinocyte suspensions isolated from 6 of 13 psoriatic plaques lacking HLA-DR reactivity were studied. All contained <5% HLA-DR⁺ cells, as did epidermal populations isolated from normal-appearing skin from psoriasis patients and skin from three normal individuals.

Epidermal suction blisters, obtained from two separate lesional sites and one normal-appearing area from patient MSe during relapse were studied by flow cytometry, and the results agree with those obtained by immunofluorescence microscopy. 36.5% (Fig. 4c) and 21.9% (Fig. 4d) of cells from psoriatic plaques 1 and 2, respectively, reacted with mAb Josh 524.4.1. Only 6.3% of cells isolated from normal-appearing skin stained positively (Fig. 4b). The negative control

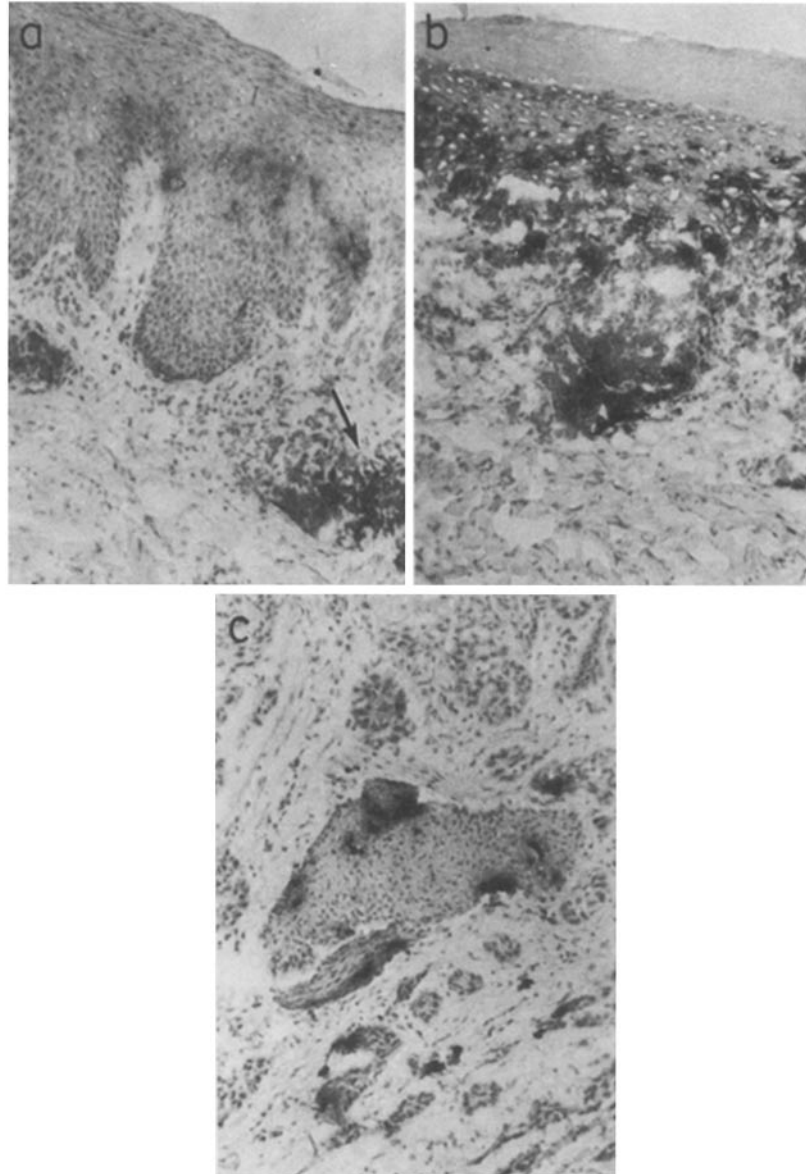


FIGURE 3. Presence of Langerhans cells in the dermal infiltrates of patients with psoriasis, lichen planus, and squamous cell carcinoma. $\times 270$. Immunoperoxidase staining with mAb OKT6 of lesional skin from a patient with (a) psoriasis; (b) lichen planus; (c) squamous cell carcinoma of the lip. Black arrow points to positively-stained cells.

(Fig. 4a) exhibited a background staining of 3%. Staining was not due to reactivity with contaminating activated T lymphocytes because no staining was seen with mAb OKT3. In all cases, there was a distinct population of cells that was reactive with Josh 524.4.1, and one that did not stain, so that the difference in reactivity seen between psoriatic and normal-appearing skin could not be

TABLE I
Quantitation of HLA-DR-bearing Keratinocytes in Single-cell Suspensions of Cells Obtained from Epidermal Suction Blisters

Skin source	Patient	Immunofluorescence reactivity with mAb Josh 524.4.1 (percent positive cells)*	
		Before treatment	After treatment
Psoriatic plaque	RB	84	0.5
	MSe	60	18
	JK	15	ND
	AF	9	1
	TD	8	0
Normal-appearing skin	SN	7	ND
	MSe	3	4
	JK	1	ND
	AF	1	2
	TD	3	2
	SN	0	ND

* By indirect immunofluorescence using tetramethyl rhodamine isothiocyanate-conjugated Fab'₂ fragments of a goat anti-mouse IgG antiserum.

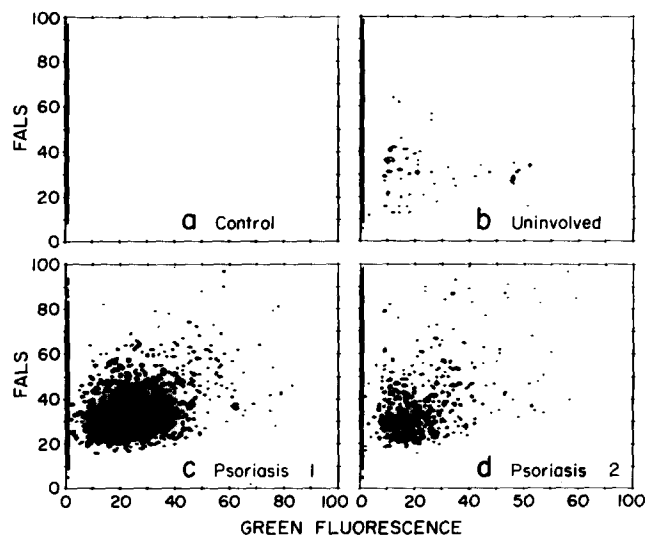


FIGURE 4. Reactivity of keratinocyte suspensions obtained from active psoriatic plaques and uninvolved skin from patient MSe with mAb Josh 524.4.1. Cells were stained using indirect immunofluorescence with mAb Josh 524.4.1 followed by a 1:20 dilution of FITC-conjugated Fab'₂ fragments of a goat anti-mouse IgG antibody, and then analyzed by flow cytometry. The ordinate depicts forward-angle light scatter (*FALS*) on a linear scale, and the abscissa shows log measurements of green fluorescence intensity displayed on a linear scale. (a) Control hybridoma medium reacted with cells from psoriasis plaque 2. (b) mAb Josh 524.4.1 reacted with uninvolved skin. (c) mAb Josh 524.4.1 reacted with cells from psoriasis plaque 1. (d) mAb Josh 524.4.1 reacted with cells from psoriasis plaque 2.

accounted for solely by a difference in intensity of staining. Frequency of HLA-DR positivity vs. cell size (analyzed by light scattering) revealed that keratinocytes of all sizes contained an HLA-DR⁺ subpopulation. However, HLA-DR molecule expression was most frequent in the small- to mid-sized cell population, which contains most of the epidermal stem cells (28).

HLA-DR Expression in Keratinocytes from Psoriatic Plaques Correlates with Disease Activity. To determine whether HLA-DR expression in keratinocytes from psoriatic plaques was correlated with disease activity, criteria for severe psoriasis were established. A patient was determined to have severe psoriasis if one or more of the following clinical signs was present: (a) coverage of >50% of the skin with psoriatic plaques, (b) erythroderma, (c) pustular lesions, (d) psoriatic arthritis, (e) signs of systemic illness such as fever, chills, and fluid and protein loss. In all cases, infectious etiologies that could have given rise to the same clinical signs were ruled out. Of the eight patients with HLA-DR⁺ keratinocytes in active plaques, six had severe disease. In particular, four of the eight patients had psoriatic arthritis. In contrast, of the 12 patients lacking HLA-DR⁺ keratinocytes, none had associated arthritis. Details of this aspect of the study will be reported elsewhere. Five of the HLA-DR⁻ patients had severe diseases, all of whom were characterized by >50% of skin coverage with psoriatic plaques. The other seven had nonsevere disease.

The reactivity of single-cell suspensions of epidermal cells obtained from psoriatic plaques after treatment was studied next (Table I). In all cases, the number of HLA-DR⁺ keratinocytes was dramatically decreased with ongoing successful medical therapy. The effect of drug treatment on HLA-DR molecule expression was further studied using immunoperoxidase experiments with mAb Josh 524.4.1, and double-labelling immunofluorescence studies with rhodamine-conjugated Fab'₂ fragments of an anti-HLA-DR antibody and fluorescein-labelled OKT6 on skin biopsies. Psoriatic skin (Fig. 5*b*) before treatment showed intense membrane reactivity of most keratinocytes with 524.4.1 (Fig. 5*a*). In contrast, psoriatic skin after the induction of remission (Fig. 5*d*) showed reactivity of only a very small proportion of epidermal cells (Fig. 5*c*). Skin biopsies obtained from the remaining seven patients with HLA-DR⁺ keratinocytes in plaques before treatment showed similar results, although the degree of HLA-DR-reactivity reduction varied.

Immunoperoxidase studies (Fig. 2, *d-f*) of the dermal infiltrate of psoriatic plaques during successful medical therapy revealed that the infiltrate was less dense than in active plaques before treatment. However, it was still composed of T cells, most of which were HLA-DR⁺, and Langerhans cells and macrophages. In six out of eight cases, AT-1 reactivity decreased with successful therapy. In the remaining two cases, no significant change was observed with ongoing medical treatment.

Presence of HLA-DR⁺ Keratinocytes in Other Inflammatory Cutaneous Disorders. Other inflammatory skin diseases were tested for keratinocyte HLA-DR expression. Skin sections from all three patients with lichen planus contained HLA-DR⁺ keratinocytes. HLA-DR⁺ keratinocytes were also observed in biopsies from spongiotic dermatitis, subcorneal pustular dermatitis, discoid lupus erythematosus and lupus profundus, but not in biopsies from patients with advanced

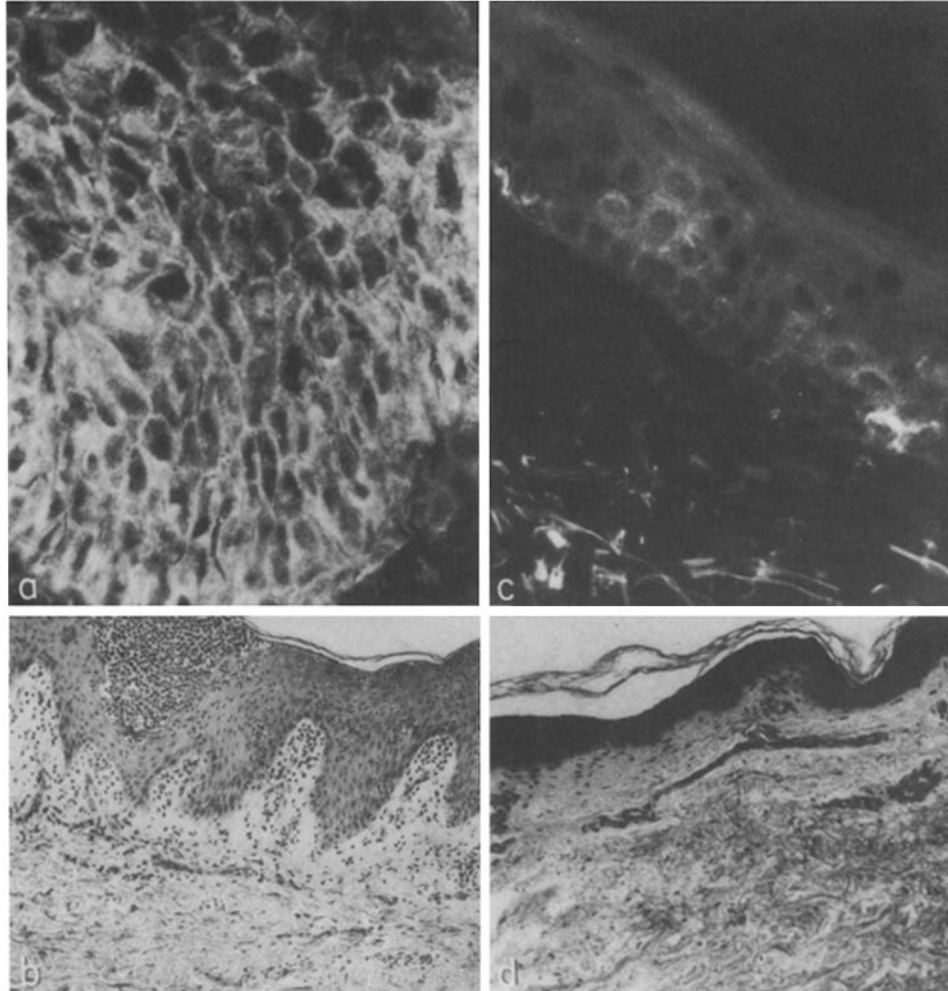


FIGURE 5. Immunofluorescence reactivity of lesional psoriatic skin from patient RB with mAb Josh 524.4.1 before and after successful medical therapy. (a) Skin before treatment shows intense membrane reactivity of most keratinocytes with mAb Josh 524.4.1. $\times 923$. (b) Routine formalin-fixed, paraffin-embedded, H and E-stained sections of the same skin as in a. $\times 231$. (c) Lesional skin from the same patient as in a after systemic and topical corticosteroids and methotrexate therapy shows reactivity of only a very small proportion of epidermal cells with mAb Josh 524.4.1. $\times 923$. (d) Routine formalin-fixed, paraffin-embedded, H and E-stained sections of same skin as in c shows remission after medical therapy. $\times 231$.

scleroderma (one linear, four CREST [calcinosis, Raynaud's phenomenon, esophageal hypomotility, sclerodactyly, and telangiectasia] variants, and one progressive systemic sclerosis), erythema multiforme, dermatomyositis, nummular eczema, and cutaneous vasculitis.

Discussion

HLA-DR-bearing keratinocytes were present in plaques from one-third of patients with active psoriasis. Immunofluorescence with two fluorochromes and

antibodies to HLA-DR and OKT6 antigens showed that HLA-DR molecules were present on keratinocytes in addition to Langerhans cells. This was also confirmed by staining keratinocytes obtained by suction blister induction. Thus, psoriasis should be added to an increasing list of dermatoses in which HLA-DR⁺ keratinocytes are present (16–19). In this context, the failure of other investigators to find HLA-DR⁺ keratinocytes in psoriatic plaques needs further explanation. In our patient population, a substantial number had psoriatic arthritis. These patients belong to the patient group with HLA-DR⁺ keratinocytes. None of the patients lacking HLA-DR⁺ keratinocytes had arthritis (31). In the general psoriatic population, psoriatic arthritis is quite rare (32). Our skewed population is due to an unusual referral pattern, in that patients with more severe skin lesions, which are resistant to conventional therapy, are likely to be referred to our clinic. Thus, patient selection and the limited number of patients studied are the likely explanations for the inability of other investigators to detect HLA-DR⁺ keratinocytes in psoriasis.

HLA-DR and HLA-DQ antigens are not detectable on keratinocytes in normal skin. Under various pathologic conditions, HLA-DR has been detected on keratinocytes in involved skin (16–19). Studies of human delayed-type hypersensitivity reactions *in vivo* have shown keratinocyte HLA-DR expression at only restricted times during the course of the response (33). In the case of HLA-DQ, its expression was not detected in this investigation on keratinocytes, despite its presence on a subset of Langerhans cells and cells in the dermal infiltrate of psoriatic plaques. However, in a recent publication (34), keratinocyte HLA-DQ expression has been reported to be a late manifestation of borrelia spirochete infection. Although the psoriasis patients in this series were studied at varying times from the onset of appearance of active plaques, the cited studies underscore the need for more detailed and serial studies.

Keratinocyte HLA-DR expression correlated somewhat with disease severity, and was reversible with successful medical therapy. Of interest is the observation that, during successful medical therapy, the dermal infiltrate showed disappearance of T cells with activated T cell markers. This correlation suggests that T cells are important in the generation of psoriatic plaques. IFN- γ has been shown to induce HLA-DR expression by normal keratinocytes (35), as well as by other epithelial cells (36–38). Recently (39), intradermal injection of recombinant IFN- γ into cutaneous lesions of patients with lepromatous leprosy has been shown to induce HLA-DR expression by keratinocytes. Attempts to identify IFN- γ -producing T cells and IFN- γ on HLA-DR⁺ keratinocytes in tissue sections by an immunohistochemical technique with an mAb against IFN- γ were unsuccessful. This might be due to technical problems, such as the destruction of relevant antigenic determinants by fixation, or inadequate section penetration. To circumvent these difficulties, in a limited number of patients, immunofluorescence staining of viable keratinocyte suspensions with the anti-IFN- γ was performed. The presence of IFN- γ on the surface membrane of keratinocyte populations containing HLA-DR⁺ cells but not those lacking HLA-DR⁺ keratinocytes was confirmed. Although these results are preliminary, they support the thesis that IFN- γ may be a key lymphokine in the generation of HLA-DR⁺ keratinocytes in psoriatic plaques. However, the possibility that other soluble mediators produced

by the infiltrating T cells and macrophages may also be responsible needs further consideration. Studies of blister fluid composition and its ability to induce keratinocyte HLA-DR expression, as well as those of the cellular components of the dermal infiltrate, using mAbs against newer markers and various lymphokines, would be informative.

Studies of single-cell suspensions of keratinocytes confirmed observations made using skin biopsies and quantitated the proportion of cells bearing HLA-DR molecules. Flow cytometry experiments suggested that keratinocytes from psoriatic plaques, at all stages of differentiation (as judged from their sizes) were HLA-DR⁺. However, the stem cell-enriched subpopulation contained the highest proportion of HLA-DR⁺ cells. Thus, psoriatic epidermis contained a subpopulation of HLA-DR⁺ keratinocytes that was absent from uninvolved skin. It was possible, however, that there was a small percentage of keratinocytes in normal-appearing skin that expressed HLA-DR molecules, and which was expanded in psoriatic plaques. Additional studies with basal cell layer-specific (22) and suprabasal cell-reactive (40) mAbs will be of use in further delineating the relationship between HLA-DR antigen expression and keratinocyte differentiation.

Our observations provide a new approach toward understanding the pathogenesis of psoriasis, and reemphasize the role that immunologic mechanisms play in this disease. HLA-DR⁺ keratinocytes and Langerhans cells in active psoriatic plaques could activate dermal T cells directly in an autologous mixed leukocyte/epithelial cell reaction, or present an as-yet-unknown antigen to T lymphocytes. It is well known that, in a subset of patients, psoriasis flares have been associated with antecedent streptococcal infection. T cell activation would then lead to the release of mediators of inflammation, and possibly of epidermal growth factors. This hypothesis would also provide an explanation for the chronicity of psoriasis. Independent of the inciting factors, HLA-DR⁺ keratinocytes could further activate dermal T cells in the absence of the etiologic agent. Similarly, HLA-DR⁺ adherent synovial cells can be found in the joints of patients with rheumatoid arthritis (41, 42), and are thought to be of importance in the development of synovial inflammation. It is likely that HLA-DR⁺ synovial cells will also be found in the arthritis associated with psoriasis, and that they may play a similar role in the pathogenesis of joint injury as do HLA-DR⁺ keratinocytes in psoriatic skin.

The role of Langerhans cells needs further consideration. Langerhans cells, as defined by reactivity with mAb OKT6, were seen in the dermal infiltrates of patients with psoriasis, lichen planus, contact dermatitis, spongiotic dermatitis, erythema multiforme, and basal and squamous cell carcinoma. The role of the Langerhans cells in epidermal antigen presentation has been clearly established (43). Ultraviolet light irradiation of the skin abrogates Langerhans cell function (44), and in experimental animals, leads to suppression of contact hypersensitivity and the dissemination of ultraviolet irradiation-induced basal cell carcinomas (45). In man, sun exposure increases the incidence of keratinocyte malignancies. Psoriasis and lichen planus are papulosquamous skin diseases of unknown etiology, which share certain immunopathologic features, in that many HLA-DR⁺ epidermal keratinocytes and activated dermal T cells are evident in lesional skin (16-18). Contact dermatitis and erythema multiforme are the result of cell-

mediated reactions in the skin (46, 47). It is possible that antigen, in association with Langerhans cells, migrates to the dermis from the epidermis. Langerhans cells can then enter the circulation and activate T cells at distal sites, e.g., draining lymph nodes. Once activated, T cells can migrate back to the dermis, by mechanisms that are still unknown. Activated T lymphocytes could then secrete IFN- γ and other lymphokines that would induce HLA-DR molecule expression by keratinocytes, in addition to promoting inflammation and epidermal growth. HLA-DR⁺ keratinocytes could activate additional T lymphocytes, accounting for the chronicity of some of these disorders. In support of this hypothesis is the observation (G. Kaplan, R. Steinman, and Z. Cohn, personal communication) that OKT6⁺ Langerhans cells are present in the dermis of cutaneous lesions of experimentally induced delayed-type hypersensitivity reactions in man. These observations may be relevant to a wide range of dermatologic diseases in which cell-mediated immunity plays a role.

Summary

Immunoperoxidase staining of skin sections and immunofluorescence analysis of keratinocyte suspensions obtained from suction blisters of psoriatic plaques were performed using an mAb, Josh 524.4.1, and Fab'₂ fragments of a rabbit antiserum, both of which are directed against nonpolymorphic determinants of HLA-DR molecules. HLA-DR⁺ keratinocytes were present in plaques, but not normal-appearing skin, from a significant portion of patients with active psoriasis. Double-labelling immunofluorescence experiments with either the monoclonal or polyclonal anti-HLA-DR antibody, in conjunction with the mAb OKT6, which identifies DR⁺ Langerhans cells, demonstrated that HLA-DR molecules were present on OKT6⁻ keratinocytes. The dermal infiltrate of psoriatic plaques contained T cells expressing the activation antigens, IL-2 receptor (Tac) and HLA-DR, as well as macrophages and OKT6⁺ cells. There was little difference in the characteristics of the dermal infiltrate between the lesions with or without HLA-DR⁺ keratinocytes. OKT6⁺ presumptive Langerhans cells were also found in the dermal infiltrates of patients with lichen planus, contact dermatitis, spongiotic dermatitis, erythema multiforme, basal and squamous cell carcinoma. Studies of keratinocyte suspensions showed that 7–84% of keratinocytes were HLA-DR⁺. Flow cytometry experiments showed that keratinocytes at all stages of differentiation were HLA-DR⁺. However, the stem cell-enriched population contained the highest proportion of HLA-DR⁺ cells. HLA-DR expression by keratinocytes correlated with disease activity. The expression was reversible with successful medical therapy.

HLA-DR⁺ keratinocytes may activate T cells directly or may present an as yet unknown antigen to T cells. These studies provide further support for the hypothesis that immunological mechanisms play an important role in the pathogenesis of psoriasis.

We thank the housestaff, nurse practitioners, and attending physicians of the Division of Dermatology, Department of Internal Medicine, at The New York Hospital, and of The Rockefeller University Hospital for their help in recruiting patients for these studies. We also thank Ms. Jeannine Acocella and Ms. Ann Hoy for their excellent technical assistance,

and Drs. Gilla Kaplan, Ralph Steinman, and Zanvil Cohn (The Rockefeller University, New York) for helpful discussion.

Received for publication 12 May 1986 and in revised form 19 June 1986.

References

1. Krogh, H. K., and O. Tonder. 1979. Stratum corneum antigens and antibodies. *In Immunopathology of the Skin*, Second edition. E. H. Beutner, T. P. Chorzelski, and B. F. Bean, editors. John Wiley and Sons, New York. 413.
2. Cormane, R. H. 1984. Immunopathology of psoriasis. *Arch. Dermatol. Res.* 270:201.
3. Kaneko, F., T. Muramatsu, Y. Takahashi, and Y. Miura. 1984. Extractable immune complex in soluble substances from psoriatic scales. *Arch. Dermatol. Res.* 276:45.
4. Krogh, H. K. 1973. Antibodies to stratum corneum in man. *In Immunopathology of the skin*. E. H. Beutner, T. P. Choreski, S. F. Bean, and R. E. Jordan, editors. Dowden, Hutchinson, and Ross, Inc., Stroudsburg, PA. 402-414.
5. Glinski, W., S. Obalek, A. Langner, S. Jablonska, and M. Haftek. 1978. Defective function of T lymphocytes in psoriasis. *J. Invest. Dermatol.* 70:105.
6. Krueger, G. G., H. R. Hill, and W. W. Jederberg. 1978. Inflammatory and immune cell function in psoriasis—a subtle disorder. I. In vivo and in vitro survey. *J. Invest. Dermatol.* 71:189.
7. Kaminshi, M., A. Szmurlo, and M. Pawinsha. 1984. Decreased natural killer cell activity in generalized pustular psoriasis (von Zumbusch type). *Br. J. Dermatol.* 110:565.
8. Lundin, A., L. Hakansson, R. Hallgren, G. Michaelsson, and P. Venge. 1983. Studies on the phagocytic activity of the granulocytes in psoriasis and palmoplantar pustulosis. *Br. J. Dermatol.* 109:539.
9. Krueger, G. G., W. W. Jederberg, B. E. Ogden, and D. L. Reese. 1978. Inflammatory and immune cell function in psoriasis. II. Monocyte function, lymphokine production. *J. Invest. Dermatol.* 71:195.
10. Baker, B. S., A. F. Swain, L. Fry, and H. Valdimarsson. 1984. Epidermal T lymphocytes and HLA-DR expression in psoriasis. *Br. J. Dermatol.* 110:555.
11. Giles, R. C., and J. D. Capra. 1985. Structure, function and genetics of human class II molecules. *Adv. Immunol.* 37:1.
12. Stingl, G., K. Tamaki, and S. I. Katz. 1980. Origin and function of epidermal Langerhans cells. *Immunol. Rev.* 53:149.
13. Dezutter-Dambuyant, C., G. Cordier, D. Schmitt, M. Favre, C. Laquoi, and J. Thivolet. 1984. Quantitative evaluation of two distinct cell populations expressing HLA-DR antigens in normal human epidermis. *Br. J. Dermatol.* 111:1.
14. Murphy, G. F., R. S. Shepard, T. J. Harrist, B. R. Bronstein, and A. K. Bhan. 1983. Ultrastructural documentation of HLA-DR antigen reactivity in normal human acrosyringial epithelium. *J. Invest. Dermatol.* 81:181.
15. Harrist, T. J., D. J. Ruiter, M. C. Mihm, and A. K. Bhan. 1983. Distribution of major histocompatibility antigens in normal skin. *Br. J. Dermatol.* 109:623.
16. Volc-Platzer, B., O. Majdic, W. Knapp, K. Wolff, W. Minterberger, K. Lechner, and G. Stingl. 1984. Evidence of HLA-DR antigen biosynthesis by human keratinocytes in disease. *J. Exp. Med.* 159:1784.
17. Aiba, S., and H. Tagami. 1984. HLA-DR antigen expression on the keratinocyte surface in dermatoses characterized by lymphocyte exocytosis (e.g., pityriasis rosea). *Br. J. Dermatol.* 111:285.
18. Lampert, I. A. 1984. Expression of HLA-DR (Ia-like) antigen on epidermal keratinocytes in human dermatoses. *Clin. Exp. Immunol.* 57:93.

19. Scheynius, A., and U. Tjernlund. 1984. Human keratinocytes express HLA-DR antigens in the tuberculin reaction. *Scand. J. Immunol.* 19:141.
20. Morhenn, V. B., E. A. Abel, and G. Mahrle. 1982. Expression of HLA-DR antigen in skin from patients with psoriasis. *J. Invest. Dermatol.* 78:165.
21. Haftek, M., M. Faure, D. Schmitt, and J. Thivolet. 1983. Langerhans cells in skin from patients with psoriasis: Quantitative and qualitative study of T6 and HLA-DR antigen-expressing cells and changes with aromatic retinoid administration. *J. Invest. Dermatol.* 81:10.
22. Gottlieb, A. B., D. N. Posnett, M. K. Crow, T. Horikoshi, L. Mayer, and D. M. Carter. 1985. Purification and vitro growth of human epidermal basal keratinocytes using a monoclonal antibody. *J. Invest. Dermatol.* 85:299.
23. Takaishi, M., and S. M. Fu. 1985. Monoclonal antibodies against human myelomonocytic cells. Detection of certain lineage-specific antigens on CFU-GM progenitors. *J. Immunol.* 135:1523.
24. Wang, C. Y., Y. Bushkin, P.-D. Chen, C. D. Platsoucas, and C. Long. 1984. Preparation and characterization of monoclonal antibodies directed at epitopes of human IFN- γ . *Hybridoma.* 3:321.
25. Jung, L. K. L., T. Hara, and S. M. Fu. 1984. Detection and functional studies of P60-65 (Tac antigen) on activated human B cells. *J. Exp. Med.* 160:1597.
26. Gottlieb, A. B., L. Mayer, F. Bonetti, D. M. Knowles II, J. Krueger, H. G. Kunkel, and D. M. Carter. 1985. A membrane protein preferentially expressed by a subpopulation of immature lymphoid cells, epidermal basal keratinocytes and other epithelial stem cells. *J. Am. Acad. Dermatol.* 13:54.
27. Gottlieb, A. B., S. M. Fu, D. T. Y. Yu, C. Y. Wang, J. P. Halper, and H. G. Kunkel. 1979. The nature of the stimulatory cell in human allogeneic and autologous MLC reactions: role of isolated IgM-bearing B cells. *J. Immunol.* 123:1497.
28. Staiano-Coico, L., P. J. Higgins, Z. Darzynkiewicz, M. Kimmel, A. B. Gottlieb, I. Pagan-Charry, M. R. Madden, J. L. Finkelstein, and J. M. Hefton. 1986. Human keratinocyte culture. Identification and staging of epidermal cell populations. *J. Clin. Invest.* 77:396.
29. Wang, C. Y. 1979. Structural and functional characterization of surface antigens on B lymphocytes. The Rockefeller University Press, New York. 154.
30. Fithian, E., P. Kung, G. Goldstein, M. Rubinfeld, C. Fenoglio, and R. Edelson. 1981. Reactivity of Langerhans cells with hybridoma antibody. *Proc. Natl. Acad. Sci. USA.* 78:2541.
31. Gottlieb, A. B., D. M. Carter, and S. M. Fu. 1986. HLA-DR molecule expression by keratinocytes in associated with psoriatic arthritis. *Arthritis Rheum.* 29:S55.
32. Espinoza, L. R. 1985. Psoriatic arthritis: Further epidemiologic and genetic considerations. In *Psoriatic Arthritis*. L. H. Gerber and L. R. Espinoza, editors. Grune and Stratton, Inc., Orlando, FL.
33. Kaplan, G., M. D. Witmer, I. Nath, R. M. Steinman, S. Laal, H. K. Prasad, E. N. Sarno, U. Elvers, and Z. A. Cohn. 1986. Influence of delayed immune reactions on human epidermal keratinocytes. *Proc. Natl. Acad. Sci. USA.* 83:3469.
34. Tjernlund, U., A. Scheynius, E. Asbrink, and A. Houmark. 1986. Expression of HLA-DQ antigens on keratinocytes in *Borrelia spirochete*-induced skin lesions. *Scand. J. Immunol.* 23:383.
35. Basham, T. Y., B. J. Nickoloff, T. C. Merigan, and V. B. Morhenn. 1984. Recombinant gamma interferon induces HLA-DR expression on cultured human keratinocytes. *J. Invest. Dermatol.* 83:88.
36. Bottazzo, G. F., B. M. Dean, J. M. McNally, E. H. MacKay, P. G. F. Swift, and D. R.

1028 HLA-DR⁺ KERATINOCYTES AND LANGERHANS CELLS IN PSORIASIS

- Gamble. 1985. In situ characterization of autoimmune phenomena and expression of HLA molecules in the pancreas in diabetic insulinitis. *N. Engl. J. Med.* 313:353.
37. Benson, E. M., R. B. Colvin, and P. S. Russell. 1985. Induction of IA antigens in murine renal transplants. *J. Immunol.* 134:7.
38. Berrih, S., F. Arenzana-Seisdedos, S. Cohen, R. Devos, D. Charron, and J.-L. Virelizier. 1985. Interferon- γ modulates HLA Class II antigen expression on cultured human thymic epithelial cells. *J. Immunol.* 135:1165.
39. Nathan, C., G. Kaplan, W. R. Levis, S. Nusrat, M. D. Witmer, S. A. Sherwin, C. K. Job, C. R. Horowitz, R. M. Steinman, and Z. A. Cohn. 1986. Local and systemic effects of low doses of recombinant γ -interferon after intradermal injection in patients with lepromatous leprosy. *N. Engl. J. Med.* 315:6.
40. Sun, T.-T., R. Eichner, W. C. Nelson, S. C. G. Tseng, R. A. Weiss, M. Jarvinen, and J. Woodcock-Mitchell. 1983. Keratin classes: Molecular markers for different types of epithelial differentiation. *J. Invest. Dermatol.* 81:109s.
41. Amento, E. P., A. K. Bahn, K. G. McCullagh, and S. M. Krane. 1985. Influences of gamma interferon on synovial fibroblast like cells. Ia induction and inhibition of collagen synthesis. *J. Clin. Invest.* 76:837.
42. Burmester, G. R., A. Dimitriu-Bona, S. J. Waters, and R. J. Winchester. 1983. Identification of three major synovial lining cell populations by monoclonal antibodies directed to Ia antigens and antigens associated with monocytes/macrophages and fibroblasts. *Scand. J. Immunol.* 17:69.
43. Katz, S. I., K. D. Cooper, M. Iijima, and T. Tsuchida. 1985. The role of the Langerhans cell in antigen presentation. *J. Invest. Dermatol.* 85:96s.
44. Stingl, G., L. A. Gazze-Stingl, W. Aberer, and K. Wolff. 1981. Antigen presentation by murine epidermal Langerhans cells and its alteration by UVB light. *J. Immunol.* 127:1707.
45. Kripke, M. L., and W. L. Morrison. 1985. Modulation of immune function by UV radiation. *J. Invest. Dermatol.* 85:62s.
46. Polak, L. 1980. Immunological aspects of contact sensitivity. *Monogr. Allergy.* 15:1.
47. Wuepper, K. D., P. A. Watson, and J. A. Kazmierowski. 1980. Immune complexes in erythema multiforme and the Stevens-Johnson syndrome. *J. Invest. Dermatol.* 74:368.