

Clinical Study to Assess the 1,060 nm Diode Laser for the Treatment of Post-Liposuction Deformities

Christine Petti, MD, FACS * and Jacqueline Stoneburner, BS
Palos Verdes Plastic Surgery Medical Center, Torrance, California

Background and Objectives: Liposuction has become increasingly popular in the past decade due to advances in technique and technology. Despite the demand, there exists a significant population of patients who have contour deformities post-liposuction. The 1,060 nm diode laser has been Food and Drug Administration cleared for the removal of unwanted fat, so it was theorized that this noninvasive laser system could be efficacious to smooth these areas of post-liposuction contour deformities. This study was designed to retrospectively study the clinical changes induced by a 1,060 nm diode laser system to treat contour deformities in tissue post-liposuction.

Study Design/Materials and Methods: Fifteen patients with contour deformities post-liposuction (minimally six months post-surgery) were treated in the area of the deformity with the noninvasive hyperthermic 1,060 nm diode laser system. Each patient received two treatments at a 6-week interval in the anatomical area of their contour deformity.

Results: Fifteen subjects had completed two treatments and the necessary follow-up needs to be included in these results. Two blinded evaluators could correctly identify the pre-treatment image compared to the post-treatment image in an average of 85% of subjects. So, 100% of the patients were graded to be at least “Improved” with an average of 40% of subjects being “Very Much Improved”. Patient satisfaction was “High” in all subjects who have completed the treatment protocol. The physician satisfaction was rated as “Much Improved” in 33% of the patient results and “Improved” in 66% of the patient results.

Conclusions: The noninvasive hyperthermic 1,060 nm diode system is highly effective and safe for the treatment of contour deformities post-liposuction. © 2019 The Authors. *Lasers in Surgery and Medicine* Published by Wiley Periodicals, Inc.

Key words: 1,060 nm diode laser; contour deformities; liposuction

BACKGROUND

The popularity of digital mobile photography, digital filters, and photoshop techniques has led to an explosion of instantaneous self-image critique with expectations of facial and body contour perfection. Individuals can have their self-images immediately attain global exposure through the

applications of social media, worldwide web online dating, viral videos, and memes. Vulnerability of an individual's appearance to these numerous and growing sites for viewing can be image building or image deflating. If an individual is not satisfied with his or her appearance, there are an infinite number of aesthetic surgical and nonsurgical procedures they can seek to achieve their desired contour.

Liposuction, fat grafting, and dermatolipectomy procedures alone or in combination have exploded in popularity over the past three decades. New technologies including laser, radiofrequency, ultrasound, and cryotherapy have kept pace with the ever-growing demand for the perfect aesthetic contour. In particular, there has been a growing demand for body contouring utilizing suction lipolysis, one of the most common aesthetic surgical procedures. Despite its universal popularity, liposuction has been associated with undesired contour deformities of the subcutaneous fat and skin as common post-procedure sequelae.

These post-liposuction contour deformities are present as soft tissue elevations, depressions, and waviness. The frequently-associated skin laxity is also a common source of post-liposuction persistent skin pannus, skin folds, and wrinkles [1]. All surgeons performing liposuction procedures, as well as all patients receiving liposuction procedures desire a smooth result without the need to consider undergoing another surgical procedure. There is an omnipresent demand for a reliable and reproducible technology that will have the ability to noninvasively, effectively, comfortably, and safely treat these common post-liposuction skin soft tissue and skin irregularities.

In 2017, a noninvasive 1,060 nm diode laser system (SculpSure®; Cynosure Lasers, Westford, MA) was introduced to the aesthetic market as an Food and Drug Administration (FDA) cleared device for noninvasive lipolysis of undesirable fatty contours of the abdomen and flanks. Since the FDA release of this 1,060 nm diode laser technology,

This is an open access article under the terms of the Creative Commons Attribution-NonCommercial-NoDerivs License, which permits use and distribution in any medium, provided the original work is properly cited, the use is non-commercial and no modifications or adaptations are made.

*Correspondence to: Christine Petti, MD, FACS, Palos Verdes Plastic Surgery Medical Center, 3400 West Lomita Boulevard, Suite 305, Torrance, CA 90505. E-mail: info@dr-petti.com

Accepted 13 May 2019

Published online 4 June 2019 in Wiley Online Library (wileyonlinelibrary.com).

DOI 10.1002/lsm.23109

our practice successfully used this technology not only to reduce bulky, targeted fat accumulations, but also to assist with the nonsurgical treatment of post-liposuction contour irregularities involving the subcutaneous tissue and skin. Physicians directly observed the mild skin erythema yet smooth appearance of the soft tissue after the 1,060 nm diode laser treatment. This inspired our theory that the 1,060 nm diode laser system could decrease the post-liposuction undesirable fat and skin contours, decreasing the degree of deformity and improving the overall aesthetic outcome, obviating a return to the operating room for a revision liposuction procedure.

There are multiple publications demonstrating collagen contraction at a given temperature [2,3] as well as adipocyte rupture, apoptosis, and subsequent fat reduction at a given temperature [4-6]. Despite the knowledge that during the 1,060 nm diode treatment, the precise target temperature for skin contraction was not obtained, clinical observations were made during post treatment visits and photography documentation that skin tightening, soft tissue smoothing, in addition to fat reduction was occurring.

Study Design

Prior to the formal study, four proof of concept patients were treated. This was followed by the development of an Institutional Review Board-approved study involving 15 patients assessing the use of the 1,060 nm diode laser system for the treatment of post-liposuction and other surgical body contour deformities who were minimally 6-months post-liposuction alone or in combination with dermatolipectomy procedures (lower or full abdominoplasty). All patients had a body mass index of less than 30. The patients were treated with the 1,060 nm diode laser system. An average of 1.3 W/cm² was used in the treatments and two treatments were performed at 6-week intervals. Follow-up visits were performed at 1-month and 3-month periods after the final treatment. Photographic documentation of results was performed at each treatment and follow-up visit. Two blinded clinical graders reviewed all of the photographs in order to identify the pre-treatment and post-treatment photographs as well as judge the clinical improvement using the Global Aesthetic Improvement Scale (GAIS). In addition, physician satisfaction ratings and patient satisfaction ratings were determined at follow-up visits.

METHODS

The 1,060 nm diode laser delivers laser heat to the fat and water of the subcutaneous tissue, safely raising the temperature of adipocytes to 42-47°C, thereby disrupting the fat cell membrane resulting in apoptosis [4,6]. The disrupted fat cells are then normally excreted through the body's lymphatic system.

The 1,060 nm diode laser has four sapphire crystal applicator plates held in place by pre-formed templates placed flat and smooth onto the treatment areas of soft tissue deformity. These plates simultaneously treat the targeted tissue deformity by aiming the photothermal

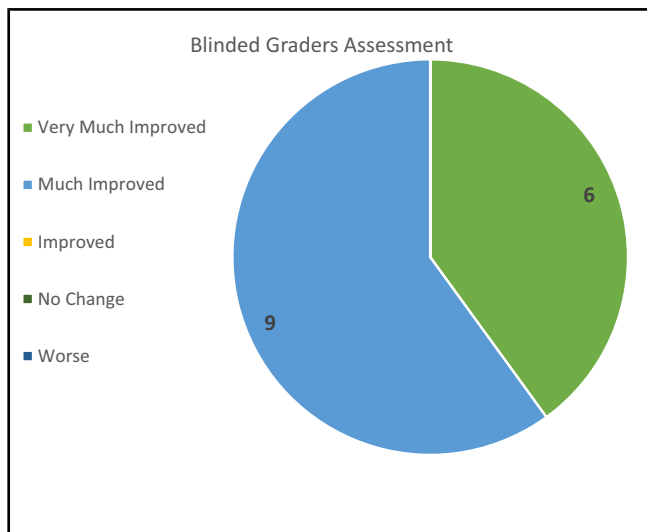
effect of the laser at the tissue below yet protecting the skin from excessive heat through the cooling units that exist at the periphery of each plate. The treatment consists of alternating 25-second cycles of heat followed by cooling, for a total treatment time of 25 minutes. The target temperature of 42-47°C is reached over a 4-minute "build" phase. This target temperature is then maintained with alternating heating and cooling cycled for the 21-minute "sustain" phase. There is no deformation of the skin or soft tissue with suction forces similar to other noninvasive fat disrupting devices. Of special note, the surrounding tissue is heated several centimeters outside the applicators to ensure proper treatment and a feathering effect of the entire contour irregularity to permit a smooth transition from treated to nontreated tissue.

CLINICAL RESULTS

Fifteen patients completed the two-treatment study protocol and necessary follow-up to be included in this study. Two clinical graders performed the blinded evaluations. The blinded clinical graders were able to accurately identify the pre-treatment from the post-treatment photographs in 85% of the cases. Using the GAIS, 100% of the patients were graded to be at least "improved" and 40% were graded to be "very much improved" (Table 1 and Figs. 1, 2, 3, 4, 5).

Thus, 100% of patients who completed the treatment protocol were "satisfied" with their results with 30%

TABLE 1. 15 patients completed the 2-treatment study protocol and the necessary follow up to be included in this study. Two clinical graders performed the blinded evaluations. The blinded clinical graders were able to accurately identify the pretreatment from the post treatment photographs in 85% of the cases. Using the Global Aesthetic Improvement Scale (GAIS), 100% of the patients were graded to be at least "improved" and 40% were graded to be "very much improved"



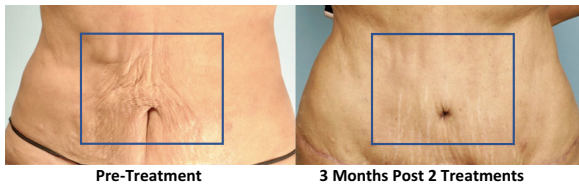


Fig. 1. 60-y/o multiparous female 9-months following lower abdominoplasty and abdominal liposuction with periumbilical skin wrinkling. The 3-month photographic result following 2 treatments spaced 6 weeks apart with the 1,060 nm diode laser demonstrates smooth and tight periumbilical contour.

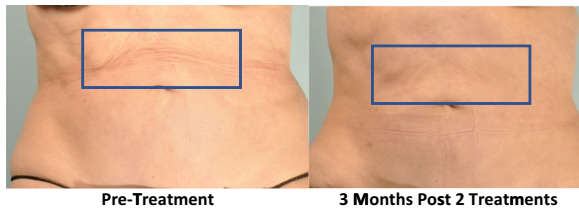


Fig. 2. 56-y/o multiparous female 2-years post abdominal liposuction demonstrates moderate skin laxity and soft tissue irregularities which are common post-pregnancy, in the middle-age group and this anatomic area of the upper abdomen. The 3-month photographic result following 2 treatments spaced 6 weeks apart with the 1,060 nm diode laser demonstrates a smoother upper abdominal soft tissue contour.

“highly satisfied”. The physician satisfaction was rated as “much improved” in 33% of the patient results and “improved” in 66% of the patient results (Table 2).

Most importantly, there were no undesirable side effects or complications of nodules, dysesthesias, ecchymosis, edema, skin ischemia, or skin necrosis in any of the study patients.

DISCUSSION

Liposuction is the second most common aesthetic surgical procedure in 2018 according to The Cosmetic Surgery National Data Bank Statistics of The American Society for Aesthetic Plastic Surgery (<https://surgery.org/>

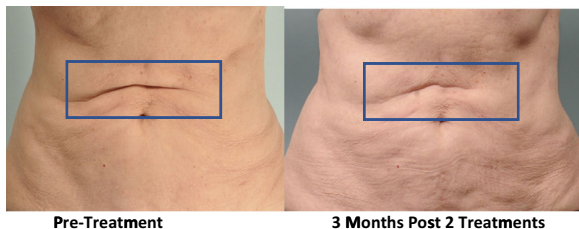

Fig. 3. 78-y/o multiparous female 8 months post abdominal liposuction demonstrates a persistent upper abdominal flexion skin fold. The 3-month photographic result following 2 treatments spaced 6 weeks apart with the 1,060 nm diode laser demonstrates a softening of the skin fold and smoother soft tissue contour of the upper abdomen in this elderly patient.

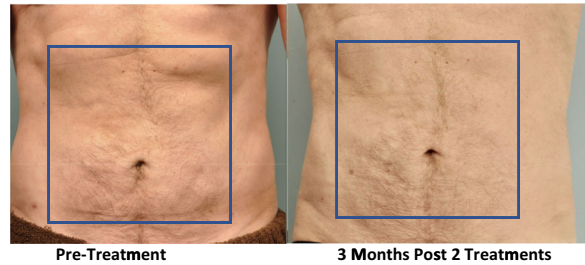


Fig. 4. 59-y/o male 2-years and 5-months following abdominal liposuction with upper abdominal and periumbilical soft tissue irregularities. The 3-month photographic result following 2 treatments spaced 6 weeks apart with the 1,060 nm diode laser demonstrates a smooth and tight abdominal soft tissue contour.

[sites/default/files/ASAPS-Stats2017.pdf](https://surgery.org/sites/default/files/ASAPS-Stats2017.pdf)). In 2018, liposuction was the second most popular cosmetic surgery procedure, an increase of 5% from 2017, as reported by The American Society of Plastic Surgeons® (<https://surgery.org/sites/default/files/ASAPS-Stats2017.pdf>).

There are numerous techniques for liposuction including suction alone, and various assisted-liposuction procedures employing radiofrequency, ultrasound, laser, and mechanical vibration. The cannulas for liposuction have also varied, ranging from small diameter to large diameter, end holes to side holes, blunt tips to spatula tips, suction-powered mechanical aspiration, and hand syringe aspiration. Tumescence infiltration techniques and the total amounts of tumescent fluid administered are not standardized for all liposuction cases and can be multi-variant.

Why has there been such a need to alter and augment the basic liposuction techniques over the decades? Improvement in aesthetic results, patient safety in terms of body hemodynamics, blood loss, recovery time, and minimization of postoperative undesirable sequelae are some of the motivations driving the liposuction industry to continue to develop technologies that will lead to more predictable, appealing, and safe outcomes.

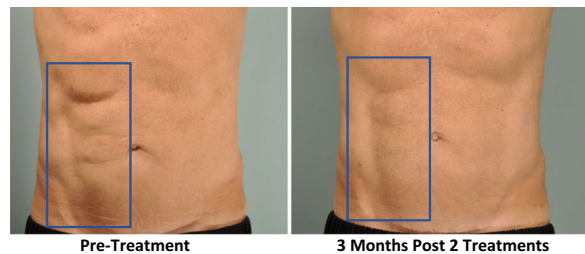
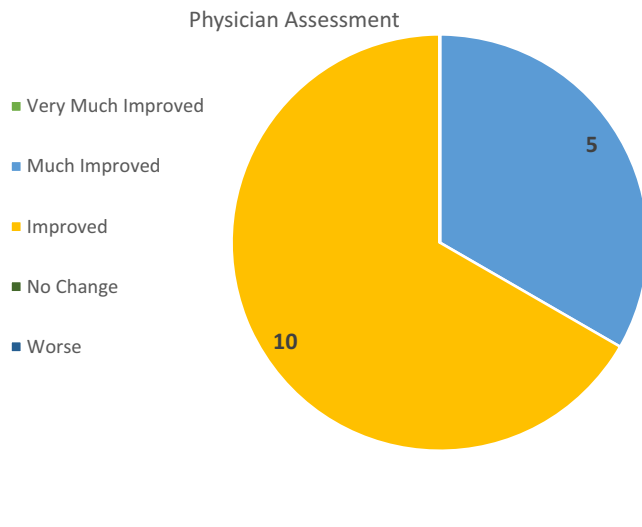


Fig. 5. 62-y/o male 10-months following abdominal liposuction with asymmetrical contour deformities, the right abdomen having undulations of the soft tissue, particularly overlying the right costal margin. The 3-month photographic result following 2 treatments spaced 6 weeks apart with the 1,060 nm diode laser demonstrates a smooth and symmetrical abdominal soft tissue contour.

TABLE 2. 100% of patients who completed the treatment protocol were "satisfied" with their results with 30% "highly satisfied". The physician satisfaction was rated as "much improved" in 33% of the patient results and "improved" in 66% of the patient results



Despite the specific technology employed during liposuction procedures, localized, or diffuse surface contour irregularities manifested by concavities due to adipose tissue deficiency or convexities due to adipose tissue excess are commonly seen as short-term and long-term following all of the various types of liposuction procedures [7]. Additionally, of paramount importance, is the clinical state of the skin in the anatomical area to be treated by liposuction techniques. The presence of skin laxity, striae, and flexion skin folds can all compromise the results of the best surgical efforts and technique to produce a smooth outcome following liposuction [7]. All surgeons performing liposuction and all patients receiving liposuction desire a smooth and tight outcome.

It is the responsibility of the surgeon to inform the patient of the status of their unique soft tissue and skin anatomy. The liposuction surgeon should always discuss with the patient the need to perform secondary surgery, if contour irregularities persist after a normal period of soft tissue healing is allowed to pass, usually 6 months to 1 year, depending on the complexity of the patient's condition and surgery. The persistence of contour deformities that are not pleasing to the patient is a source of disappointment for both patient and surgeon. It can be unpleasant, stressful, costly, and leave the surgeon legally vulnerable to recommend to the patient that the only option for correction of undesirable post-liposuction contour irregularities is a return to the operating room to perform surgical correction.

Noninvasive techniques to treat post-liposuction contour deformities are in demand and can be beneficial to patient and surgeon alike. The noninvasive 1,060 nm diode laser system has the potential to treat these post-liposuction

contour deformities. The 1,060 nm wavelength has a specificity for absorption by subcutaneous fat causing apoptosis. Additionally, this specific laser wavelength is absorbed by water, which is the major structural component of the skin allowing for some additional heating to adjacent tissue structures. Although this technology has not been FDA approved for skin tightening, we see strong evidence to suggest that is exactly what we are achieving.

The noninvasive 1,060 nm diode laser applicator design is ideal for treatment of surface and subcutaneous contour irregularities because the applicators are flat sapphire crystal plates that smooth out contours in the tissue and allow for full contact to the tissue. This ensures proper energy delivery as well as constant contact cooling, for patient comfort and safety. The 1,060 nm diode laser system uses tissue-specific laser heat, and does not require suction, nor tissue freezing (cryolipolysis), which can deform tissue and cause undesirable postoperative complications of bruising, swelling, nodules, frostbite burns, and various nerve dysesthesias. Additionally, 1,060 nm diode laser-induced fat reduction has not been associated with paradoxical hyperplasia, a recurrence of fat accumulation post-treatment, as has been reported with cryolipolysis [8–10].

Limitations

This was a nonrandomized, non-placebo-controlled study. With the deformities being nonuniform, there were no real objective measures, so all of the improvement was subjective based on grader's scoring. Large-scale studies with standardized photography may be necessary in order to confirm the results.

CONCLUSION

When analyzed using advanced imaging systems, the 1,060 nm diode noninvasive laser system was safe and effective with reproducible results for the treatment of subcutaneous contour deformities following liposuction and body contour procedures. The laser treatment produced a significant and satisfactory improvement that was appreciated by both the patient and physician.

The 1,060 nm diode laser system is convenient, comfortable, and appealing, since there is no post-treatment regimen and the side effects are minimal to none.

This original clinical study was presented at the American Society for Laser Medicine and Surgery in Dallas, April 2018.

REFERENCES

- Jacobs JMS, Schechner S, Jacobs JS. Abdominoplasty following massive weight loss. *Semin Plast Surg* 2006;20(1):15–23. <https://doi.org/10.1055/s-2006-932445>.
- Fitzpatrick RE, Rostan EF, Marchell N. Collagen tightening induced by carbon dioxide laser versus erbium:YAG laser. *Lasers Surg Med* 2000;27(5):395–403.
- Pritzker RN, Hamilton HK, Dover JS. Comparison of different technologies for noninvasive skin tightening. *J Cosmet Dermatol* 2014;13(4):315–323.
- Fakhouri TM, El Tal AK, Abrou AE, et al. Laser-assisted lipolysis: A review. *Dermatol Surg* 2012;38:155–169.

5. Sasaki G, Tevez A. Laser assisted liposuction for facial and body contouring and tissue tightening: A 2-year experience with 75 consecutive patients. *Semin Cutan Med Surg* 2009;28:226–235.
6. Ichikawa K, Miyasaki M, Tanaka R, et al. Histologic evaluation of the pulsed Nd:YAG laser for laser lipolysis. *Lasers Surg Med* 2005;36:43–46.
7. Dixit VV, Wagh MS. Unfavorable outcomes of liposuction and their management. *Indian J Plast Surg* 2013;46(2):377–392. <https://doi.org/10.4103/0970-0358.118617>.
8. Stefani WA. Adipose hypertrophy following cryolipolysis. *Aesthet Surg J* 2015;35(7):NP218–NP220. <https://academic.oup.com/asj/article/35/7/NP218/2589209>.
9. Kelly E, Rodriguez-Feliz J, Kelly ME. Paradoxical adipose hyperplasia after cryolipolysis: A report on incidence and common factors identified in 510 patients. *Plast Reconstr Surg* 2016;137:639e–640e.
10. Singh SM, Geddes ER, Boutrous SG, et al. Paradoxical adipose hyperplasia secondary to cryolipolysis: An under-reported entity? *Lasers Surg Med* 2015;47:476–478.