



Intraocular lens opacification after Descemet's stripping automated endothelial keratoplasty

Meng-Sheng Lee¹, I-Lun Tsai¹, Ching-Yao Tsai^{1,2}, Li-Lin Kuo^{1,3}, Shioh-Wen Liou^{1,4,5,6}, Lin-Chung Woung^{1,7}

Abstract:

Compared with conventional penetrating keratoplasty, Descemet's stripping automated endothelial keratoplasty (DSAEK) more effectively maintain global integrity and rapid vision rehabilitation with less ocular surface disorders in patients with endothelial dysfunction. Here, we report a case of a 76-year-old woman who experienced opacification of a hydrophilic intraocular lens (IOL) approximately 10 months after DSAEK. The patient with no history of systemic disease developed pseudophakic bullous keratopathy in the right eye 2 years after undergoing cataract surgery. The best-corrected visual acuity (BCVA) of the right eye was Snellen 0.01 when presented to our hospital. DSAEK was arranged and performed smoothly. However, the graft detached over the upper part of the cornea on postoperative day 1. Thus, rebubbling was performed immediately. After the procedure, the graft was well attached, and the cornea became clear gradually. The BCVA returned to Snellen 0.6. However, progressive opacification over the anterior surface of the IOL was observed 10 months postoperatively. Vision deteriorated to 0.5 with various refractive errors during 2-year follow-up. IOL exchange may be considered if the vision is getting worse. IOL opacification may result from a direct contact between the IOL surface and exogenous air, particularly in a hydrophilic IOL, and can be a rare but significant complication after DSAEK. Clinicians planning to perform DSAEK should consider the composition of the IOL, the amount of intracameral air, duration of air filling, and high intraocular pressure.

Keywords:

Descemet's stripping automated endothelial keratoplasty, hydrophilic intraocular lens, intracameral air, opacification

Introduction

Descemet's stripping automated endothelial keratoplasty (DSAEK) is increasingly used to treat endothelial dysfunction in Taiwan. In DSAEK, the unhealthy endothelium is replaced instead of the full-thickness cornea, as that in conventional penetrating keratoplasty (PK). DSAEK has the following advantages over PK: maintained global integrity, less corneal suture-related problems, increased accuracy in intraocular lens (IOL) power calculations, less postoperative corneal astigmatism, and

rapid vision rehabilitation with less ocular surface disorders.^[1,2] Here, we describe the case of a 76-year-old woman who experienced opacification of a hydrophilic IOL approximately 10 months after DSAEK.

Case Report

A 76-year-old Asian woman presented to our hospital with progressive blurred vision and mild pain and redness of the right eye. The best-corrected visual acuity (BCVA) of the right eye was Snellen 0.01. She had received phacoemulsification with foldable hydrophilic acrylic IOL implantation (Softec

This is an open access article distributed under the terms of the Creative Commons Attribution-NonCommercial-ShareAlike 3.0 License, which allows others to remix, tweak, and build upon the work non-commercially, as long as the author is credited and the new creations are licensed under the identical terms.

For reprints contact: reprints@medknow.com

How to cite this article: Lee MS, Tsai IL, Tsai CY, Kuo LL, Liou SW, Woung LC. Intraocular lens opacification after Descemet's stripping automated endothelial keratoplasty. Taiwan J Ophthalmol 2017;7:160-3.

¹Department of Ophthalmology, Taipei City Hospital, ²Institute of Public Health, National Yang-Ming University, ³Institute of Public Health and Community Medicine Research Center, National Yang-Ming University, ⁴Department of Ophthalmology, Shin Kong Wu Ho-Su Memorial Hospital, ⁵Department of Ophthalmology, Taipei Medical University, ⁶Department of Ophthalmology, Taiwan University Hospital, ⁷Faculty of Medicine, School of Medicine, National Yang-Ming University, Taipei, Taiwan

Address for correspondence:

Dr. I-Lun Tsai,
6-F, No. 145, Zheng Zhou Road, Datong District, Taipei City 103, Taiwan.
E-mail: dac51@tpech.gov.tw

Submission: 12-03-2017
Accepted: 04-05-2017

HD, Lenstec, Florida, USA) 2 years ago. The right cornea was edematous with some bullae and Descemet's membrane folds [Figure 1]. Therefore, a diagnosis of pseudophakic bullous keratopathy was established. The right pupil was corectopic and fixed without a light reflex. The IOL was clear. DSAEK was arranged and performed smoothly. The routine surgical procedures are described as follows: After stripping the patient's Descemet's membrane with a reverse Sinsky Hook, an 8.0 mm diameter precut donor tissue (Saving Sight Eye Bank, USA) was pulled into the anterior chamber (AC) through a scleral tunnel by using a Busin glide. The main incision and opposite stab wound were sutured with interrupted 10-0 nylon sutures. In the assistance of AC maintainer, the donor graft unfolded completely. Air was slowly injected under the graft to fill the AC, keeping the donor graft firmly attached to the recipient's bed. After approximately 15 min, fluid air exchange was performed, leaving approximately 80% air bubble in the AC. The patient remained in the supine position for 2 h postoperatively. However, the air bubble was only one-fourth of its original size on postoperative day 1, and the graft detached over the upper part of the cornea. Thus, rebubbling was performed immediately. To make sure graft attachment, we kept the AC firmly filled with room air for 15 min. The intraocular pressure (IOP) was above 40 mmHg for pushing fluid out from the donor and recipient graft interface. Minimal fluid-air exchange was made to leave approximately 90% air bubble in the AC. The IOP was around 30 mmHg. The patient was asked to keep in the supine position as possible as she can till the next morning. After the procedure, the graft was well attached, and the remaining postoperative recovery was uneventful. During the follow-up period, the cornea became clear gradually. The patient's BCVA improved to Snellen 0.6 in the right eye 3 months after DSAEK. However, progressive opacification over the anterior subsurface of the IOL was observed approximately 10 months after DSAEK and was defined by the pupillary margin with a circle of a clear zone [Figures 2 and 3]. Thereafter, she complained of progressive blurring of vision, and the BCVA decreased to Snellen 0.5 at last follow-up 28 months after DSAEK. If the vision continually deteriorates, IOL exchange may be considered.

Discussion

The most common postoperative complications of DSAEK are posterior graft dislocation, endothelial graft rejection, primary graft failure, and iatrogenic glaucoma.^[2] Moreover, complications can be associated with previous IOL implantation. The longevity of an implant is determined by the properties of the implant material. A flexible hydrophilic acrylic IOL can be easily inserted and has higher tissue biocompatibility. Despite

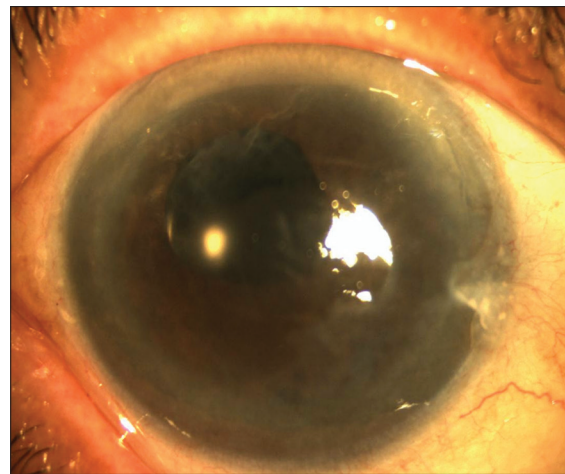


Figure 1: Pseudophakic bullous keratopathy occurred 2 years after cataract surgery

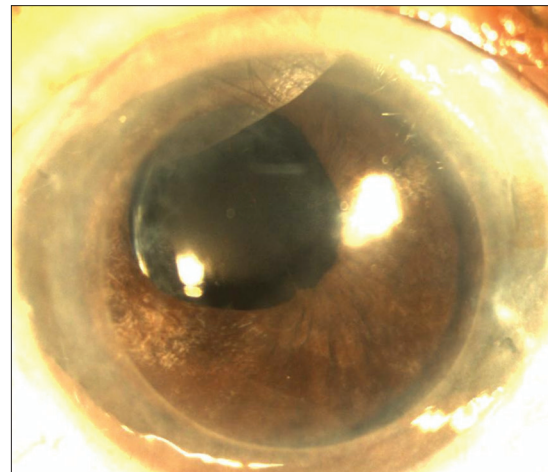


Figure 2: Intraocular lens opacification occurred 10 months after Descemet's stripping automated endothelial keratoplasty

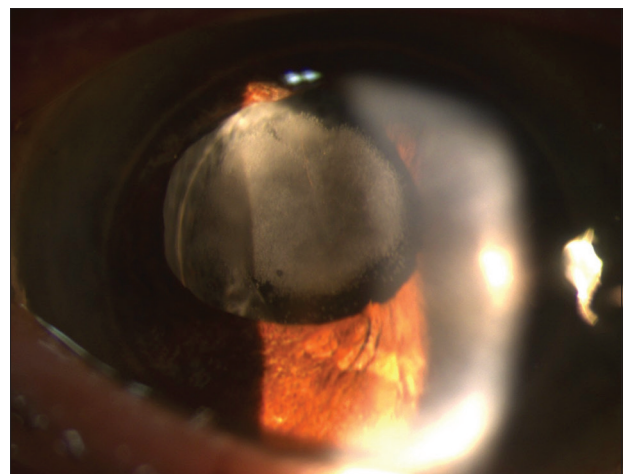


Figure 3: Intraocular lens opacification occurred 41 months after Descemet's stripping automated endothelial keratoplasty

the marked progress in the field of new materials and intraocular implant production technology, the incidence

of IOL opacification is common.^[3-16] IOL opacification is a rare but significant complication after DSAEK. The incidence of IOL opacification after DSAEK ranged from approximately 5% of 160 eyes (8 eyes)^[11] to 9.7% of 154 eyes (15 eyes)^[7] in a large number of patients. IOL opacification resulted in foggy and blurred vision and decreased visual acuity in patients.^[11] The opacification is typically located on the anterior surface or subsurface of IOLs and is defined by the pupillary or capsulorhexis margin in a confluent patch and circular pattern.^[4,7]

The mechanism underlying opacification remains unclear. Possible risk factors include an inflammatory reaction after multiple surgical procedures disrupting the blood–aqueous barrier,^[4,8,15] injection of exogenous air or gas into the AC,^[6,11,13] rebubbling after DSAEK,^[10,12,14,15] and implantation of acrylic hydrophilic IOLs.^[3-5,7-16]

Dhital *et al.* described three cases of a distinct type of calcification in hydrophilic IOLs in complicated, traumatized eyes with a history of intraocular gas use. An *en face* environmental scanning electron microscopy view showed that in addition to the subsurface zone, the opacification could be surface lesions with a ring-like crystalline structure penetrating the surface.^[4]

IOL opacification can be a complication of cataract surgery alone. Werner *et al.* reported 18 cases (4.9%) of late postoperative opacification of the SC-60B-0UV lens.^[17] Saeed *et al.* reported 56 cases (30.9%) of significant postoperative IOL (SC-60B-0UV) opacification.^[18] Furthermore, Neuhann *et al.* reported 106 cases of hydrophilic acrylic IOLs explanted from patients who had visual disturbances caused by postoperative opacification of the lens optic. The average interval between lens implantation and opacification was 25.8 ± 11.9 months. Diabetes and glaucoma are the most frequently associated medical and ophthalmic conditions.^[19] The aforementioned IOLs were hydrophilic acrylic.

We believed that the direct contact between the IOL surface and exogenous air for a particular time period and high IOP might be the key mechanisms for causing lens opacification. The structure of the surface of hydrophilic IOL might be affected by air pressure that could cause calcium^[4,12] or other substances^[13] deposition on the lens surface or subsurface. Morgan-Warren *et al.* concluded that repeated exposure to intracameral air, elevated IOP, and other patient issues might be major etiological factors for the opacification after DSAEK.^[14] The lens capsule seems to act as a barrier because the opacification area is mostly on the anterior surface within the capsulorhexis margin. Ahad *et al.* observed a trend of opacification rate reduction after reducing the

time of high-pressure (IOP higher than 40 mmHg) air tamponade from 1 h to 10 min.^[7] However, additional studies involving a large sample size are required to validate the present findings.

Intraocular gas or air is more frequently used after vitrectomy; however, IOL opacification is a rare complication after vitrectomy. Dhital *et al.*^[4] reported this rare complication in one of the cases, and Lee *et al.*^[20] and Walker *et al.*^[21] reported it in two cases each who underwent combined vitrectomy with gas tamponade and cataract surgery. The migration of gas into the AC through the zonular fiber defects after vitreous tamponade can be possible. Bruna *et al.* reported a case of opacification of a hydrophilic acrylic IOL (Oft Cryl®) after vitrectomy for retinal detachment. The leakage of gas into the AC was noted for days because of the patient's noncompliance in terms of head positioning.^[22]

Our case had an acrylic hydrophilic IOL (Softec HD) implantation; it was a bi-aspheric IOL with a water content of 26%. This IOL is commercially available in Taiwan since 7 years, with an average sale of 3500 pieces annually. The course of DSAEK in our patient was smooth. Unfortunately, the graft partially detached at the first round. Therefore, we performed the rebubbling procedure on the 2nd day. Full air tamponade in AC with IOP above 40 mmHg for 15 min was noted. Minimal fluid-air exchange to leave approximately 90% air bubble in the AC with around 30 mmHg IOP was followed. Furthermore, the patient lay with the supine position for more than 12 h. The duration of contact time between the air and IOL surface was long. Therefore, the possibility of IOL opacification increased. Management for IOL opacification after DSAEK depends on the nature of the patient's symptoms. Neodymium-doped yttrium aluminum garnet laser has failed to clean the calcification opacity.^[3-6,23] Since the opacification is on the subsurface zone of IOL, surgical removing the opacity has also failed.^[3-6] IOL exchange is the treatment of choice that may be considered if the vision continually deteriorates.^[3-6,23]

Conclusion

IOL opacification may result from a direct contact between the IOL surface and exogenous air. It could be a rare but significant complication occurring months after DSAEK, particularly in hydrophilic IOLs. In patients with poor endothelial function, hydrophilic IOL implantation is not recommended in cataract surgery if DSAEK will be performed in the future. Furthermore, clinicians planning to perform DSAEK should consider the composition of the IOL, the amount of intracameral air, duration of air filling, and high IOP.

Acknowledgments

This study was funded by Taipei City Hospital, Taiwan, in 2012 (Grant Number: TCHIRB-1000906).

Financial support and sponsorship

Nil.

Conflicts of interest

There are no conflicts of interest.

References

1. Melles GR, Eggink FA, Lander F, Pels E, Rietveld FJ, Beekhuis WH, *et al.* A surgical technique for posterior lamellar keratoplasty. *Cornea* 1998;17:618-26.
2. Lee WB, Jacobs DS, Musch DC, Kaufman SC, Reinhart WJ, Shtein RM. Descemet's stripping endothelial keratoplasty: Safety and outcomes: A report by the American Academy of Ophthalmology. *Ophthalmology* 2009;116:1818-30.
3. Patryn E, van der Meulen IJ, Lapid-Gortzak R, Mourits M, Nieuwendaal CP. Intraocular lens opacifications in descemet stripping endothelial keratoplasty patients. *Cornea* 2012;31:1189-92.
4. Dhital A, Spalton DJ, Goyal S, Werner L. Calcification in hydrophilic intraocular lenses associated with injection of intraocular gas. *Am J Ophthalmol* 2012;153:1154-60.e1.
5. Fellman MA, Werner L, Liu ET, Stallings S, Floyd AM, van der Meulen IJ, *et al.* Calcification of a hydrophilic acrylic intraocular lens after descemet-stripping endothelial keratoplasty: Case report and laboratory analyses. *J Cataract Refract Surg* 2013;39:799-803.
6. Neuhann IM, Neuhann TF, Rohrbach JM. Intraocular lens calcification after keratoplasty. *Cornea* 2013;32:e6-10.
7. Ahad MA, Darcy K, Cook SD, Tole DM. Intraocular lens opacification after descemet stripping automated endothelial keratoplasty. *Cornea* 2014;33:1307-11.
8. De Cock R, Fajgenbaum MA. Calcification of Rayner hydrophilic acrylic intra-ocular lenses after descemet's stripping automated endothelial keratoplasty. *Eye (Lond)* 2014;28:1383-4.
9. Norouzpour A, Zarei-Ghanavati S. Hydrophilic acrylic intraocular lens opacification after descemet stripping automated endothelial keratoplasty. *J Ophthalmic Vis Res* 2016;11:225-7.
10. Werner L, Wilbanks G, Nieuwendaal CP, Dhital A, Waite A, Schmidinger G, *et al.* Localized opacification of hydrophilic acrylic intraocular lenses after procedures using intracameral injection of air or gas. *J Cataract Refract Surg* 2015;41:199-207.
11. Nieuwendaal CP, van der Meulen IJ, Patryn EK, Werner L, Mourits MP, Lapid-Gortzak R. Opacification of the intraocular lens after descemet stripping endothelial keratoplasty. *Cornea* 2015;34:1375-7.
12. MacLean KD, Apel A, Wilson J, Werner L. Calcification of hydrophilic acrylic intraocular lenses associated with intracameral air injection following DMEK. *J Cataract Refract Surg* 2015;41:1310-4.
13. Verdaguer P, Gris O, Casaroli-Marano RP, Elies D, Muñoz-Gutierrez G, Güell JL. Intraocular lens opacification after endothelial keratoplasty as analyzed by environmental scanning electron microscopy. *Cornea* 2015;34:972-5.
14. Morgan-Warren PJ, Andreatta W, Patel AK. Opacification of hydrophilic intraocular lenses after descemet stripping automated endothelial keratoplasty. *Clin Ophthalmol* 2015;9:277-83.
15. Park JC, Habib NE, Moate RM. Intraocular lens opacification after corneal endothelial keratoplasty: Electron microscopy and x-ray element spectroscopy analysis. *J Cataract Refract Surg* 2015;41:140-5.
16. Mojzis P, Studeny P, Werner L, Piñero DP. Opacification of a hydrophilic acrylic intraocular lens with a hydrophobic surface after air injection in descemet-stripping automated endothelial keratoplasty in a patient with Fuchs dystrophy. *J Cataract Refract Surg* 2016;42:485-8.
17. Werner L, Apple DJ, Kaskaloglu M, Pandey SK. Dense opacification of the optical component of a hydrophilic acrylic intraocular lens: A clinicopathological analysis of 9 explanted lenses. *J Cataract Refract Surg* 2001;27:1485-92.
18. Saeed MU, Jafree AJ, de Cock R. Intralenticular opacification of hydrophilic acrylic intraocular lenses. *Eye (Lond)* 2005;19:661-4.
19. Neuhann IM, Werner L, Izak AM, Pandey SK, Kleinmann G, Mamalis N, *et al.* Late postoperative opacification of a hydrophilic acrylic (hydrogel) intraocular lens: A clinicopathological analysis of 106 explants. *Ophthalmology* 2004;111:2094-101.
20. Lee SJ, Choi JH, Sun HJ, Choi KS, Jung GY. Surface calcification of hydrophilic acrylic intraocular lens related to inflammatory membrane formation after combined vitrectomy and cataract surgery. *J Cataract Refract Surg* 2010;36:676-81.
21. Walker NJ, Saldanha MJ, Sharp JA, Porooshani H, McDonald BM, Ferguson DJ, *et al.* Calcification of hydrophilic acrylic intraocular lenses in combined phacovitrectomy surgery. *J Cataract Refract Surg* 2010;36:1427-31.
22. Ventura BV, MacLean KD, Lira W, Oliveira DM, Ventura CV, Werner L. Microscopic analysis of an opacified OFT CRYL® hydrophilic acrylic intraocular lens. *Arq Bras Oftalmol* 2016;79:255-7.
23. Werner L, Wilbanks G, Ollerton A, Michelson J. Localized calcification of hydrophilic acrylic intraocular lenses in association with intracameral injection of gas. *J Cataract Refract Surg* 2012;38:720-1.