

Intrascrotal solitary neurofibroma: A case report and review of the literature

Mohammad Mehdi Hosseini, Bita Geramizadeh^{1,2}, Saeed Shakeri¹, Mohammad Hossein Karimi²

Departments of Urology and ¹Pathology, ²Transplant Research Center, Shiraz University of Medical Sciences, Shiraz, Iran

Abstract

Solitary Neurofibroma of the scrotum is an extremely rare benign tumor, particularly when it is not associated with neurofibromatosis type I. To the best of our knowledge, less than 10 cases have been reported in the English literature. Herein, we report a 52-year-old man with the diagnosis of scrotal solitary neurofibroma.

Key Words: Neurofibroma, scrotum, spermatic cord

Address for correspondence:

Dr. Bita Geramizadeh, Department of Pathology, Shiraz University of Medical Sciences, Shiraz, Iran, PO BOX: 71345-1864. E-mail: geramib@sums.ac.ir

Received: 06.12.2010, Accepted: 27.02.2011

INTRODUCTION

Scrotal tumors are mostly extratesticular, originating from spermatic cord and epididymis. Benign mesenchymal scrotal tumors are leiomyoma, fibroma, lipoma, hemangioma, and epidermoid cysts.^[1] Solitary scrotal neurofibromas unassociated with neurofibromatosis type I (NF I) are extremely rare and to the best of our knowledge, only 10 cases have been reported in the English literature.^[2] Herein, we report a patient with scrotal mass who was diagnosed as scrotal neurofibroma after pathologic examination.

CASE REPORT

A 52-year-old man presented with painless bulging in the scrotal area for 9 months. There has been no significant enlargement of the mass since he noticed the bulging.

Physical examination showed a large firm painless, nontransilluminating, and ovoid mass in the left inguinal

area. Testicular and extratesticular examinations were normal; however, because of the presence of large mass, relation of the mass with epididymis and spermatic cord could not be exactly located. No hernia was detected. Ultrasonography showed a large hypoechoic mass in left scrotal sac, measuring 9 × 4.5 cm [Figure 1]. Laboratory studies were unremarkable. With the clinical diagnosis of hydrocele, the patient was scheduled for surgery. A left inguinal incision was performed and a large oval and firm mass was detected occupying a large portion of the spermatic cord. Testis and epididymis were uninvolved. Frozen section of the mass was in favor of a benign tumor, most probable origin of the neural tissue. The mass was dissected off the surrounding tissue and then completely removed. The testis and epididymis were intact and the mass was most probably arisen from the wall of spermatic cord, because it was firmly attached to it. The excised mass was round to oval with low vascularity and creamy color. The exact relation of the mass with the external spermatic fascia, ilioinguinal and genitofemoral nerves could not be identified.

Pathologic examination of the tumor showed a large well-circumscribed smooth creamy-yellow mass measuring 9 cm in greatest diameter [Figure 2]. Cut section of the mass was solid homogenous and gelatinous. Microscopic studies showed typical neurofibroma [Figure 3] composed of uniformly distributed spindle cells with wavy nuclei, dispersed chromatin, and inconspicuous nucleoli. No evidence of atypia or mitosis was present. Immunohistochemical study of the spindle cells

Access this article online	
Quick Response Code:	Website: www.urologyannals.com
	DOI: 10.4103/0974-7796.95569

was positive for vimentin and S100, but negative for SMA (smooth muscle actin), keratin, and desmin.

The patient was discharged in good condition and now after 2 years, he is doing well without evidence of recurrence, confirmed by ultrasonography.

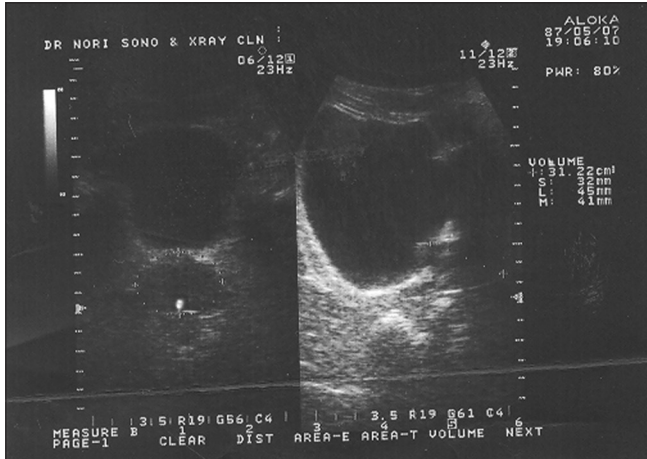


Figure 1: Ultrasonography of the inguinal area shows a large intrascrotal mass

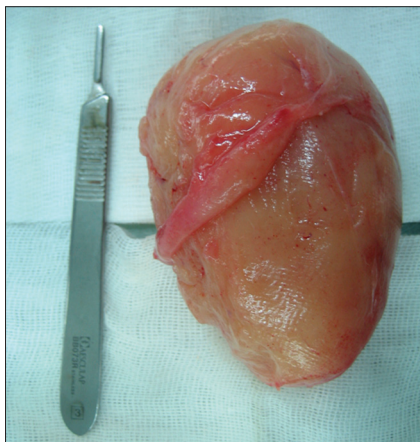


Figure 2: Gross of the large inguinal mass

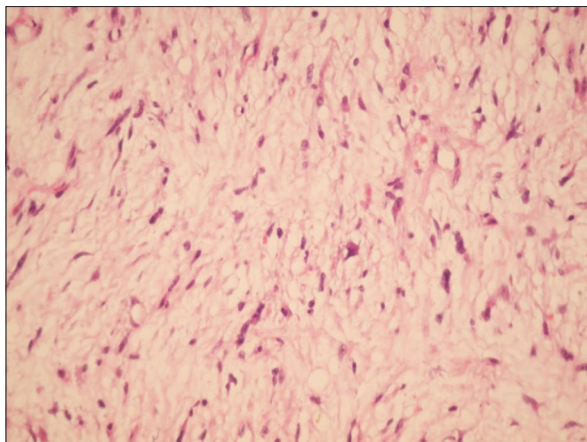


Figure 3: Microscopic view of the mass diagnosed as neurofibroma (H and E, x250)

DISCUSSION

Neurofibroma is a benign tumor of the nerve sheath originating from the Schwann cells. They are commonly seen in the neck, thorax, cranium, retroperitoneum, and flexure aspects of the upper and lower extremities.^[3] Neurofibroma of scrotum in the absence of NF I is extremely rare and to the best of our knowledge, about 10 cases [Table 1] have been reported in the English literature so far.^[2] Solitary scrotal neurofibroma of the scrotum has been reported in a wide range of ages, mostly presenting with painless or painful swelling of the scrotal area.^[4-10]

Our case was a 52-year-old man who presented with painless swelling of the scrotal area. There was no stigmata of NF I, although no genetic study was available for confirmation.

In most cases of scrotal neurofibroma, the exact origin of the tumor cannot be determined, but overall the majority of them are extratesticular.^[4] Some have been originated from tunics, epididymis, subcutaneous neural tissue, and spermatic cords.^[8] In our patient, during surgery, the bulk of tumor has been attached to the spermatic cord, so the most probable origin of the tumor might be genitofemoral or the ilioinguinal nerve or even smaller nerve axons.^[10]

This type of tumors can be solitary or multiple. Multiple neurofibromas are mostly in favor of NF I and investigations should be targeted toward the other signs of this syndrome such as café-au-lait macules, sphenoidal dysplasia, Lisch nodules, and optic glioma.^[1] The histopathologic features of the mass did not show plexiform neurofibroma which is seen classically in NF I. Meanwhile, all of the previously reported scrotal neurofibromas in the patients with NF type I are part of genitourinary neurofibromatosis involving urethra, penis, and perineum.^[11,12] Thorough investigation including imaging studies did not reveal any stigmata of NF I. Therefore, the mass was considered as solitary neurofibroma of scrotum most probably originating from the spermatic cord.

Treatment of choice in these tumors is excision. Frozen section diagnosis is very helpful in this regard to exclude malignancy avoiding orchiectomy.^[5]

Table 1: The clinical characteristics of the reported scrotal neurofibromas in the English literature

	Size (cm)	Age (years)	Location
Schulte <i>et al.</i> ^[9]	13 × 10 × 8	49	Spermatic cord
Yamamoto <i>et al.</i> ^[5]	5 × 1.5 × 1.5	8	Scrotum
Yoshimura <i>et al.</i> ^[8]	5 × 3.5 × 3	41	Scrotum
Issa <i>et al.</i> ^[4]	13 × 4.5 × 3	77	Genitofemoral nerve
Turkiylmaz <i>et al.</i> ^[11]	9.5 × 7 × 4.5	14	Genitofemoral nerve
Deliveliotis <i>et al.</i> ^[10]	4 × 4 × 1	74	Spermatic cord
Milathianakis <i>et al.</i> ^[3]	5 × 4 × 2.5	86	Spermatic cord
Gupta <i>et al.</i> ^[2]	10 × 9	24	Scrotum
Current case	9 × 4.5	52	Spermatic cord

In conclusion, scrotal neurofibroma is a rare benign tumor which should be considered in the differential diagnoses of scrotal masses that are extratesticular in origin.

REFERENCES

1. Turkyilmaz Z, Sonmez K, Karabulut R, Dursun A, Bassklar C, *et al.* A childhood case of Intrascrotal neurofibroma with a brief review of the literature. *J Pediatr Surg* 2004;39:1261-3.
2. Gupta S, Gupta R, Singh S, Pant L. Solitary intrascrotal neurofibroma: A case diagnosed on aspiration cytology. *Diagn Cytopathol* 2011;39:843-6.
3. Milathianakis KN, Karamanolakis D, Mpogdanos IM, Trihia-Spyrou E. Solitary neurofibroma of the spermatic cord. *Urol Int* 2004;72:271-4.
4. Issa MM, Yagol R, Tsang D. Intrascrotal neurofibromas. *Urology* 1993;41:350-2.
5. Yamamoto M, Miyake K, Mitsuya H. Intrascrotal extratesticular neurofibroma. *Urology* 1982;20:200-1.
6. Arciola AJ, Golden S, Zapinsky J, Fracchia JA. Primary Intrascrotal nontesticular schannoma. *Urology* 1985;26:304-6.
7. Livolsi VA, Schiff M. Myxoid neurofibroma of the testis. *J Urol* 1977;118:341-2.
8. Yoshimura K, Maeda O, Saiki S, Kuroda M, Miki T, Usami M, *et al.* Solitary neurofibroma of scrotum. *J Urol* 1990;143:823.
9. Schulte L, McDonald JR, Priestley JT. Tumors of the spermatic cord, report of a case of neurofibroma. *JAMA* 1939;112:2405-6.
10. Deliveliotis C, Albanis S, Skolarikos A, Varkarakis J, Protogerou V, Tamvakis N, *et al.* Solitary neurofibroma of spermatic cord. *Int Urol Nephrol* 2002;34:373-5.
11. Ogawa A, Watanabe K. Genitourinary neurofibromatosis in a child presenting with an enlarged penis and scrotum. *J Urol* 1986;135:755-7.
12. Jepson PM. Von Recklinghausen's disease presenting as scrotal tumor. *Urology* 1975;5:270-4.

How to cite this article: Hosseini MM, Geramizadeh B, Shakeri S, Karimi MH. Intrascrotal solitary neurofibroma: A case report and review of the literature. *Urol Ann* 2012;4:119-21.

Source of Support: Nil, **Conflict of Interest:** None.

Announcement

Android App



Download
**Android
application**

FREE

A free application to browse and search the journal's content is now available for Android based mobiles and devices. The application provides "Table of Contents" of the latest issues, which are stored on the device for future offline browsing. Internet connection is required to access the back issues and search facility. The application is compatible with all the versions of Android. The application can be downloaded from <https://market.android.com/details?id=comm.app.medknow>. For suggestions and comments do write back to us.