



Shoulder Arthroscopic Rotator Cuff Repair With Biceps Tenodesis and Acromioplasty Using a Single Working Portal

Dany Aouad, M.D., and George El Rassi, M.D.

Abstract: Rotator cuff repair, acromioplasty, and biceps tenodesis operations have become some of the most common shoulder surgical procedures, evolving from open techniques to minimally invasive arthroscopic techniques. The use of many arthroscopic portals has been associated with surgical risks to many surrounding anatomic structures. We present an arthroscopic technique using a single anterolateral working portal for rotator cuff repair, acromioplasty, distal clavicle excision, and long head of the biceps tenodesis; this technique decreases the risk of injury to the surrounding neurovascular and musculotendinous structures, enables a faster recovery, and is minimally invasive.

One of the most common surgical procedures on the shoulder is rotator cuff repair.¹⁻³ It has evolved from open techniques to an all-arthroscopic technique throughout the past decade. Despite satisfactory results, open techniques have been associated with increased morbidities such as deltoid weakness or detachment, arthrofibrosis, and severe postoperative pain.^{1,4} Fewer deltoid muscle complications have been seen using more recent mini-open techniques with the same results as open surgery.⁵⁻⁷ The advancement of all-arthroscopic techniques has relatively decreased the incidence of most previously reported morbidities, with less dissection, smaller incisions, and access to intra-articular structures with a significantly lower risk of deltoid detachment and related complications.⁸ Many surgeons still perform open techniques because of high technical demands with arthroscopy, which

requires a high learning curve, hence considering that open surgery remains the gold standard of treatment.⁹

In addition, it has been proved that arthroscopic techniques not only have therapeutic advantages but also have diagnostic utility.¹⁰ Primary and secondary portals are developed to perform most shoulder arthroscopic procedures, including rotator cuff repair, labral or SLAP and instability repair, treatment of acromioclavicular joint pathology, distal clavicle resection, biceps tenotomy or tenodesis, and subacromial decompression. Subsequently, with an increased number of portals, more anatomic structures are at risk, including musculotendinous, vascular, and nervous structures.¹¹ For example, anterior portals put many structures at risk, such as the subscapularis muscle, coracoacromial ligament, axillary artery, cephalic vein, and axillary nerve. Posterior portals can cause damage to the infraspinatus and teres minor muscles, suprascapular artery, axillary nerve, and so on.¹¹ In our technique, subacromial decompression, distal clavicle resection, biceps tenodesis, and rotator cuff repair are performed using only a single working portal (anterior), leading to lower morbidities with minimal invasiveness (deltoid sparing), a faster recovery, and fewer anatomic structures at risk during and after the procedure.

Surgical Technique

Under combined locoregional and general anesthesia, the patient is placed in the beach-chair position with arm traction and 5-kg weights. An intra-articular arthroscopic examination is performed through a posterior portal (Fig 1).

From the Department of Orthopedic Surgery and Traumatology, Saint Georges University Medical Center, Balamand University, Beirut, Lebanon.

The authors report no conflicts of interest in the authorship and publication of this article. Full ICMJE author disclosure forms are available for this article online, as [supplementary material](#).

Received November 6, 2020; accepted January 8, 2021.

Address correspondence to George El Rassi, M.D., Department of Orthopedic Surgery and Traumatology, Saint Georges University Medical Center, Balamand University, St Georges Street, Achrafieh, Beirut, Lebanon. E-mail: dany_aouad@hotmail.com

© 2021 THE AUTHORS. Published by Elsevier Inc. on behalf of the Arthroscopy Association of North America. This is an open access article under the CC BY-NC-ND license (<http://creativecommons.org/licenses/by-nc-nd/4.0/>).

2212-6287/201835

<https://doi.org/10.1016/j.eats.2021.01.005>

After intra-articular assessment of the shoulder, an examination reveals a normal subscapularis, an unstable and friable biceps with pulley disruption as seen by palpation, and a complete tear of the supraspinatus from the most anterior part of the greater tuberosity with a partial infraspinatus tear. The glenohumeral joint is evaluated, and the anterior glenohumeral ligaments, anteroinferior and posteroinferior capsular recesses, and entire labral rim and attachment to the glenoid articular cartilage are examined. The posteroinferior quadrant, glenoid articular cartilage, labral attachment, peripheral capsule, and synovial tissue are inspected.

First, the long head of the biceps (LHB) tendon is tagged using a FiberWire (Arthrex, Naples, FL) and Scorpion needle (Arthrex); this is followed by tenotomy of the LHB tendon using a Coblation device (Smith & Nephew, Andover, MA). Of note, the posterior portal is created almost 1 cm lateral to the standard portal for better visualization of the anterior part of the rotator cuff and for optimal manipulation during biceps tenodesis.

Next, an anterolateral working portal is created through the most superolateral aspect of the rotator interval to reach the posterior aspect of the rotator cuff and to allow more optimal anchor insertion. Application of the Coblation device is performed, followed by the use of a shaver in the subacromial space for subacromial bursectomy, as well as debridement of the superior aspect of the torn supraspinatus tendon, under direct vision (Fig 2). After subacromial bursectomy and better visualization of the greater tuberosity, the humeral head is debrided using the Coblation device and the torn supraspinatus tendon is further prepared using a cutter (Arthrex).

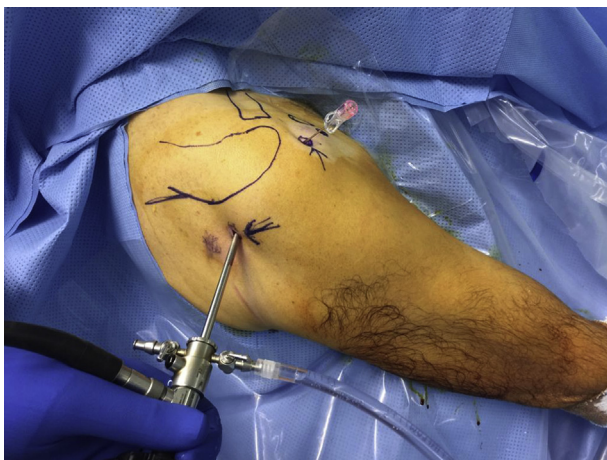

Fig 1. Patient in beach chair position, with insertion of the anterolateral portal into the right shoulder under direct vision from the posterior portal. Insertion of posterior arthroscopic portal with patient in beach-chair position for visualization and inspection of intra-articular structures, with insertion of needle under vision for creation of anterolateral portal.

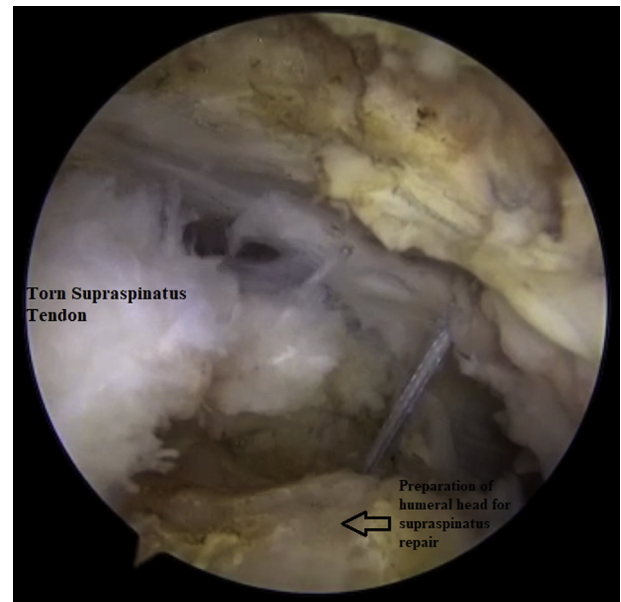


Fig 2. Debridement and preparation of humeral head for torn supraspinatus tendon repair and anchor placement.

A burr is then inserted to further debride the humeral head for the suture anchor insertion site. This is followed by further acromioplasty and distal clavicle excision, through the anterolateral portal, using a burr and a PoweRasp (Arthrex), respectively (Figs 3 and 4). Next, the first suture anchor is placed, followed by 3 other suture anchors, over the debrided greater tuberosity, over which the supraspinatus tendon is tightly secured in a double-row technique, along with biceps tenodesis (Figs 5 and 6). Because only 1 working portal is into play, the anterior suture anchors are placed with the shoulder in slight external rotation and slight adduction whereas the posteriorly placed suture anchors are inserted with the shoulder in slight internal rotation and slight abduction for better visualization. Of note, to have more freedom of manipulation through the anterolateral working portal, no cannula is used (Video 1).

Rehabilitation

The first stage of rehabilitation is the application of an arm sling for immobilization for 1 week to 10 days. The first phase of the rehabilitation protocol starts at 7 to 10 days postoperatively and lasts up to 3 weeks; it includes passive range of motion of the shoulder and elbow without any active range of motion, with isometric exercises of the deltoid. This phase aims to reduce pain and inflammation while gradually restoring passive range of motion. In the second phase (from week 3 to week 6), progressive active-assisted range of motion is initiated around the shoulder, beginning with anterior elevation of the shoulder, followed by gentle abduction and external rotation of the

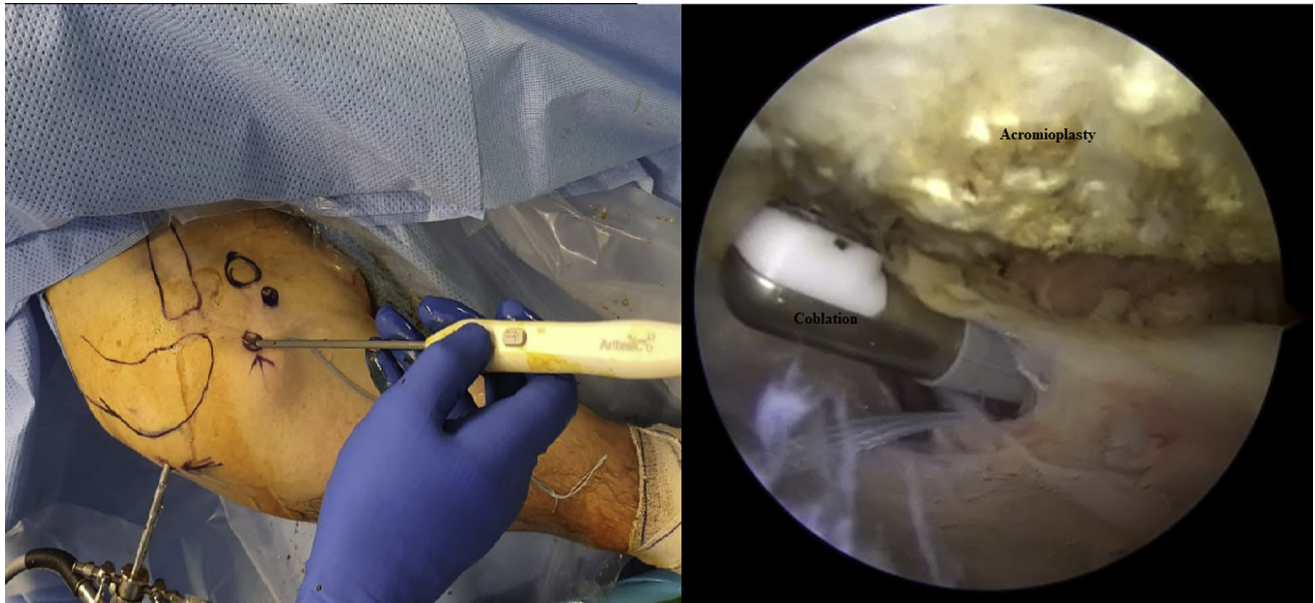

Fig 3. Acromioplasty performed after subacromial bursectomy using posterior viewing portal and anterolateral working portal.

shoulder, as well as active elbow flexion-extension and forearm supination-pronation without resistance. This aims to achieve gradual restoration of active range of motion. The last phase consists of initiating light resistance exercises, progressing as tolerated until reaching normal strength and endurance.

Discussion

The interest in arthroscopic rotator cuff repair—considered as effective as all previous techniques, with added advantages such as reduced morbidity, a more

rapid return to activities, and fewer cases of post-operative stiffness—has been constantly growing.⁸ Arthroscopic repairs are found to better reproduce the native anatomy owing to the 3-dimensional visualization of the tear configuration, helping in planning the surgical strategy.¹² Elena et al.¹³ found that subscapularis repair with a single working portal reduced the operative time, caused minor scarring, and decreased postoperative pain. Ng et al.¹⁴ described single-working portal knotless arthroscopic repair of Bankart lesions, presenting many surgical advantages, such as a shorter operative time, fewer surgical scars, greater cost-effectiveness, and less risk to the surrounding neurovascular structures; however, this technique is unsuitable for suture management in the case of knot-tying anchors. Kruse et al.¹⁵ described a modified technique for distal clavicle excision using an additional accessory anterior portal. This technique provided better visualization of the acromioclavicular joint but with an increased risk to the cephalic vein by the anterolateral portal.¹⁵ Arthroscopic shoulder portal positioning is of great importance for a successful surgical procedure: The operated zone must be well seen by the surgeon, providing a good working angle and ease of manipulation during the procedure.¹¹ Portal placement is subject to danger to the surrounding musculotendinous and neurovascular structures.¹¹ Buisson et al. presented a prospective study on 207 shoulder arthroscopies, showing a complication rate of around 23%, none of which were vascular or neural in origin.¹⁶ Meyer et al.¹¹ found that anterior portals are the most at risk of injuring neurovascular structures, with the cephalic vein being the most vulnerable. In addition, deltoid-splitting portals have been associated

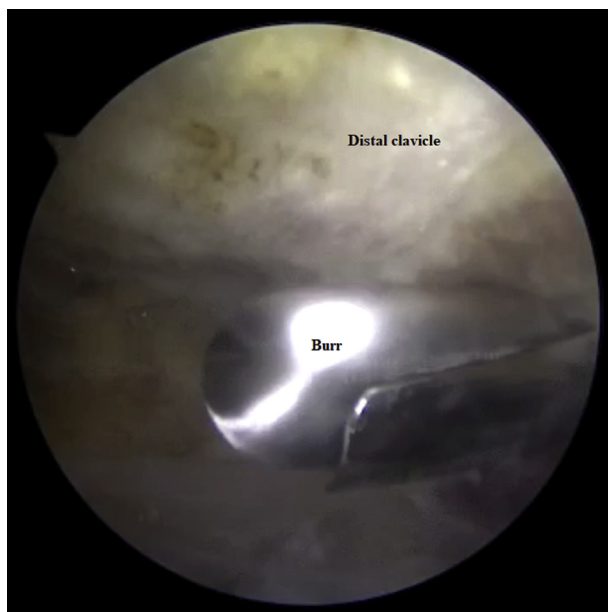


Fig 4. Distal clavicle excision through anterolateral working portal using burr.

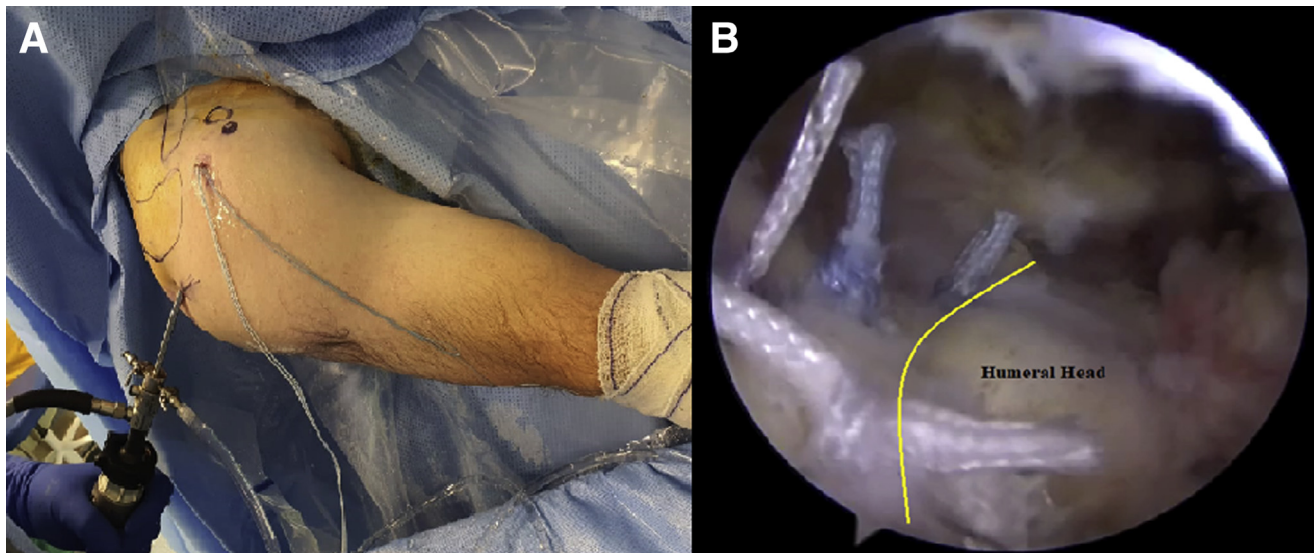


Fig 5. (A) Under direct vision via the posterior portal, suture anchors are placed using a single anterolateral portal. (B) The supraspinatus tendon is sutured using suture anchors on the previously debrided and prepared humeral head over the greater tuberosity region.

with increased postoperative pain and they increase the risk of postoperative arthrofibrosis.⁸

In the described technique, only a single anterolateral working portal, along with a posterior viewing portal, has been used to perform the following procedures: subacromial bursectomy, acromioplasty, distal clavicle excision, supraspinatus tendon tear repair, and LHB

tenodesis. After 6 months' follow-up, patients may be able to return to previous shoulder activities, including activities of daily living and mild to moderate contact sports, with satisfactory active range of motion of the shoulder, especially abduction and external rotation, which are preoperatively the most affected. This technique has shown many advantages (Table 1)—most

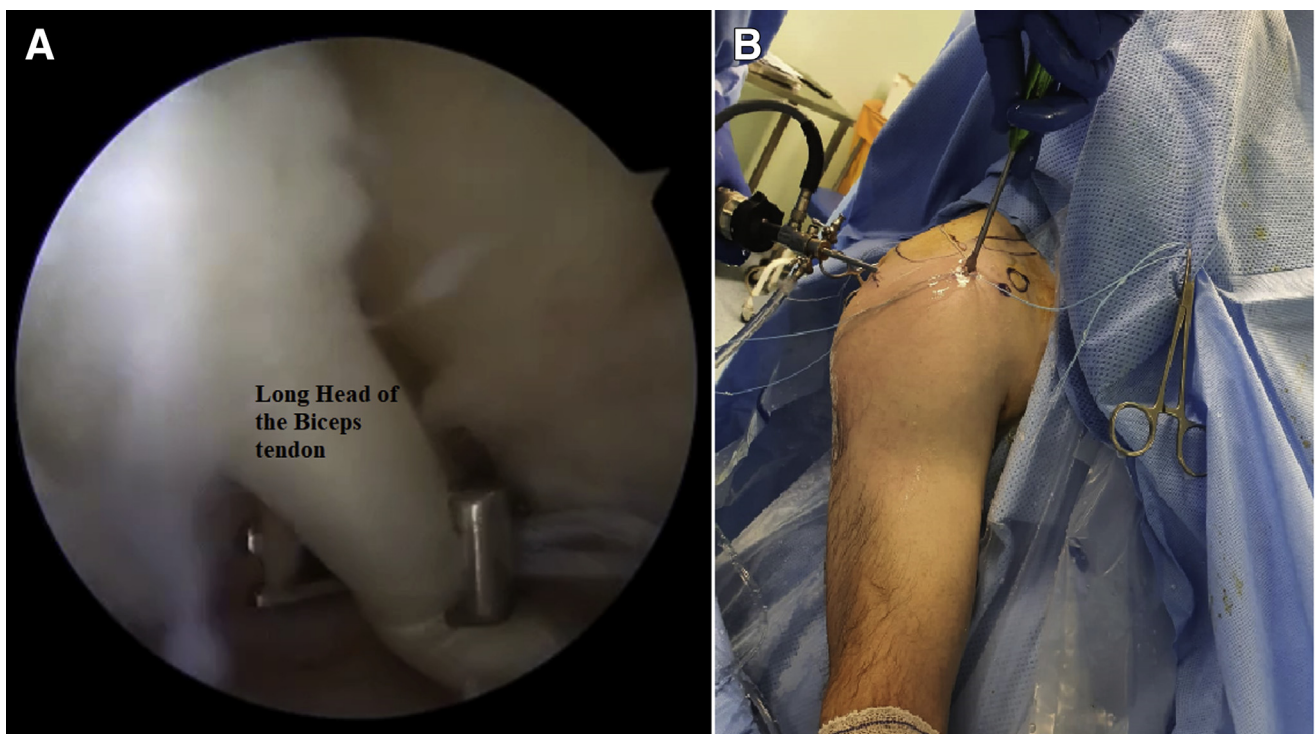


Fig 6. (A) After debridement of the long head of the biceps tendon and insertion of a suture anchor in the bicipital groove, a Scorpion needle is used to pass suture inside the body of the biceps tendon for the sake of anchoring before proximal tenotomy. (B) Through a posterior viewing portal, a Fork Tip Eyelet (Arthrex) is used to anchor the biceps tendon inside the tenodesis site.

Table 1. Advantages and Disadvantages of Single—Working Portal Technique

Advantages
Minimally invasive
Less risk of deltoid injury
Early mobilization and physical therapy
Less risk of injury to surrounding anatomic structures
Fewer postoperative analgesia requirements
More esthetic wound
Disadvantages
Requirement of high surgical skills and technically demanding
Need for more specialized curved instruments

important, an early return to activities, decreased postoperative analgesia requirements, less scarring, and deltoid sparing.

In conclusion, shoulder arthroscopy is becoming the standard of care for most shoulder pathologies, owing to fewer complications, minimal invasiveness, faster functional recovery, and less postoperative pain. Multiple arthroscopic techniques using different portals have been described, with accompanying possible injuries to the surrounding neurovascular and musculotendinous structures. With the described technique, multiple shoulder pathologies can be treated arthroscopically using a single working portal, aiming to decrease morbidity and allow early mobilization and rehabilitation, decreasing postoperative analgesia and opioid use, with better cost-effectiveness.

References

- Smith KL, Harryman DT, Antoniou J, Campbell B, Sidles JA, Matsen FA. A prospective, multipractice study of shoulder function and health status in patients with documented rotator cuff tears. *J Shoulder Elbow Surg* 2000;9:395-402.
- Romeo AA, Mazzocca A, Hang DW, Shott S, Bach BR. Shoulder scoring scales for the evaluation of rotator cuff repair. *Clin Orthop Relat Res* 2004;427:107-114.
- Galatz LM, Griggs S, Cameron BD, Iannotti JP. Prospective longitudinal analysis of postoperative shoulder function; a ten-year follow-up study of full-thickness rotator cuff tears. *J Bone Joint Surg Am* 2001;83:1052-1056.
- Bennett WF. Arthroscopic repair of massive rotator cuff tears: A prospective cohort with 2- to 4-year follow-up. *Arthroscopy* 2003;19:380-390.
- Baker CL, Liu SH. Comparison of open and arthroscopically assisted rotator cuff repairs. *Am J Sports Med* 1005:23:99-104.
- Levy HJ, Ufibe JW, Delaney LG. Arthroscopic assisted rotator cuff repair: Preliminary results. *Arthroscopy* 1990;6:55-60.
- Liu SH, Baker CL. Arthroscopically assisted rotator cuff repair: Correlation of functional results with integrity of the cuff. *Arthroscopy* 1994;10:54-60.
- Nho SJ, Shindle MK, Sherman SI. Systematic review of arthroscopic rotator cuff repair and mini-open rotator cuff repair. *J Bone Joint Surg Am* 2007;89:127-136 (suppl).
- Yamaguchi K, Levine WN, Marra G, Galatz LM, Klepps S, Flatow EL. Transitioning to arthroscopic rotator cuff repair: The pros and cons. *Instr Course Lect* 2003;52:81-92.
- Kim TK, Rauh PB, McFarland EG. Partial tears of the subscapularis tendon found during arthroscopic procedures on the shoulder: A statistical analysis of sixty cases. *Am J Sports Med* 2003;31:744-750.
- Meyer M, Graveleau N, Hardy P, Landreau P. Anatomic risks of shoulder arthroscopy portals: Anatomic cadaveric study of 12 portals. *Arthroscopy* 2007;23:529-536.
- Youm T, Murray DH, Kuöiak EN, Rokito AS, Zuckerman JD. Arthroscopic versus mini-open rotator cuff repair: A comparison of clinical outcomes and patient satisfaction. *J Shoulder Elbow Surg* 2005;14:455-459.
- Elena N, Woodall BM, Hale WP, et al. Single portal technique for subscapularis tendon repair. *Arthrosc Tech* 2018;7:e645-e649.
- Ng DZ, Lau BP, Tan BH, Kumar VP. Single working portal technique for knotless arthroscopic Bankart repair. *Arthrosc Tech* 2017;6:e1989-e1992.
- Kruse K II, Yalozis M, Neyton L. Arthroscopic distal clavical resection using “vis-à-vis” portal. *Arthrosc Tech* 2016;5:e667-e670.
- Burkhart SS, Morgan CD, Kibler WB. Shoulder injuries in overhead athletes. The “dead arm” revisited. *Clin Sports Med* 2000;1:125-158.