



Coexisting congenital mid-ureteral stricture and megaureter due to ureterovesical junction obstruction: A case report

Shotaro Nakanishi^{a,*}, Minoru Miyazato^b, Kei Tanaka^a, Namiko Uema^a, Seiichi Saito^a

^a Department of Urology, Graduate School of Medicine, University of the Ryukyus, Okinawa, 903-0215, Japan

^b Department of Systems Physiology, Graduate School of Medicine, University of the Ryukyus, Okinawa, 903-0215, Japan

ARTICLE INFO

Keywords:

Congenital mid-ureteral stricture
Ureterovesical junction obstruction
Retrograde pyelography

ABSTRACT

Congenital mid-ureteral strictures (CMS) are rare. Most congenital strictures occur at the ureteropelvic junction or ureterovesical junction, with mid-ureteral strictures accounting for only 4–5% of all cases of ureteral obstruction in children. Furthermore, there are very few reports of coexisting mid-ureteral stricture and ureterovesical junction obstruction (UVJO). Here, we report a case of coexisting UVJO and CMS. CMS was not detected on preoperative magnetic resonance imaging, and hydronephrosis remained after ureteroneocystostomy. Therefore, MRI was repeated and CMS was diagnosed, for which we performed ureteroureterostomy. Intraoperative retrograde pyelography (RGP) aids definitive diagnosis of UVJO.

1. Introduction

Congenital mid-ureteral strictures (CMS) are rare. Most congenital strictures occur at the ureteropelvic junction or ureterovesical junction, with mid-ureteral strictures accounting for only 4–5% of all cases of ureteral obstruction in children.¹ Furthermore, there are very few reports of coexisting mid-ureteral stricture and ureterovesical junction obstruction. Herein, we describe a case of megaureter due to ureterovesical junction obstruction (UVJO) that masked a mid-ureteral stricture and made diagnosis using preoperative magnetic resonance imaging (MRI) difficult. Care should be taken when these two conditions coexist, as CMS can be masked by UVJO.

2. Case presentation

A 16-month-old girl was referred to our hospital for breakthrough urinary tract infection (UTI) and left hydronephrosis. She had left hydronephrosis since the foetal period. She developed UTI the age of approximately 3 months and was prescribed prophylactic antibiotic therapy. Abdominal ultrasonography revealed a Society for Fetal Urology grade 4 left hydronephrosis and hydroureter. Voiding cystourethrography (VCUG) revealed no reflux or abnormal findings, and ^{99m}Tc-dimercaptosuccinic acid (DMSA) renal scan revealed right side 52.3% and left side 47.7%, there was no difference between the both sides. Abdominal MRI revealed left hydronephrosis and hydroureter.

The ureter was dilated up to the ureterovesical junction (Fig. 1). Based on these findings and repeated febrile UTI, we decided to perform surgery for treating megaureter due to UVJO.

We did not perform intraoperative retrograde pyelography (RGP) because the patient had already been diagnosed with megaureter due to UVJO, and we performed cross-trigonal Cohen ureteroneocystostomy and excisional tapering of the ureter.

However, hydronephrosis persisted postoperatively; therefore, renal scintigraphy and renal MRI were performed. DMSA revealed right side 74.5% and left side 25.5%, respectively. A clear decrease in renal function was observed on the left side. Renal MRI revealed left mid-ureteral stricture. On comparing the pre- and postoperative MRI images, we found that the part of the ureter that was considered a fold was actually a CMS (Fig. 2).

The patient underwent a second surgery. Intraoperative RGP confirmed the diagnosis of a mid-ureteral stricture, and we performed excision of the ureteral stricture and ureteroureterostomy as definitive management (Fig. 3). The postoperative course was uneventful, and she was discharged on the 6th postoperative day.

3. Discussion

CMS is an uncommon cause of congenital hydronephrosis; it occurs much less frequently than proximal or distal stricture.² To the best of our knowledge, there has been only one previous report of coexisting CMS

* Corresponding author.

E-mail address: shotaro@med.u-ryukyu.ac.jp (S. Nakanishi).

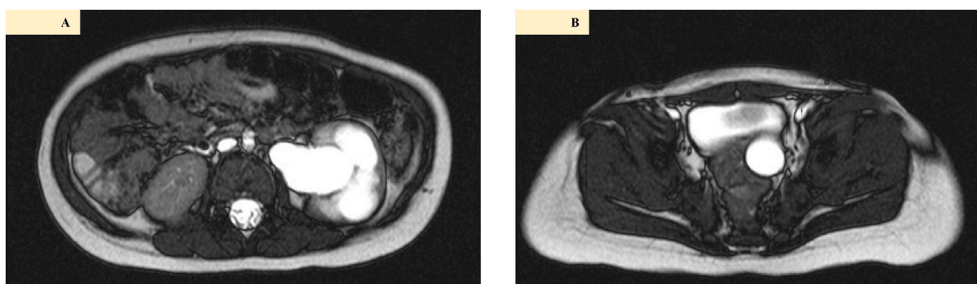


Fig. 1. Magnetic resonance imaging reveals a left hydronephrosis and hydroureter (A), the left ureter was dilated up to the ureterovesical junction (B).

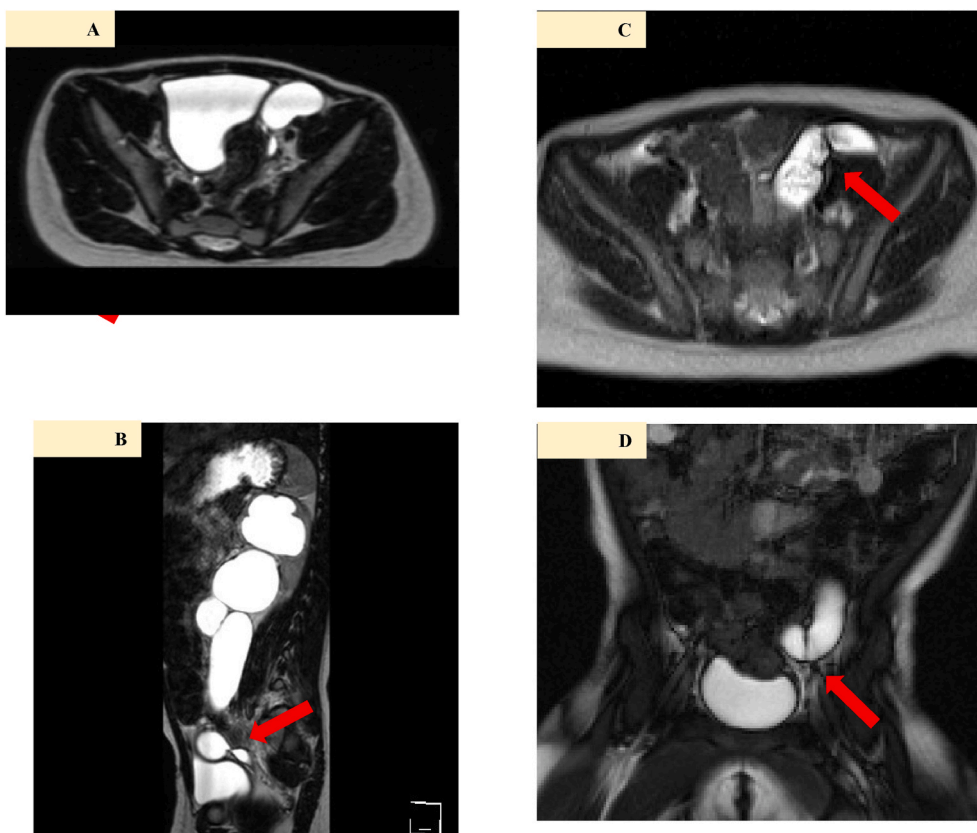


Fig. 2. Postoperative magnetic resonance imaging reveals mid-ureteral stricture. Coronal (A), Sagittal (B). Looking back at the preoperative magnetic resonance imaging, pleated findings were found (C), (D).

and UVJO.¹ Their report was diagnosed with CMS by preoperative MRI. However, there are some cases such as this case that are difficult to diagnosed by preoperative MRI. We must be aware that coexisting CMS and UVJO. Here, preoperative MRI revealed only UVJO, and CMS was not detected. Therefore, hydronephrosis persisted even after ureteroneocystostomy, and CMS was diagnosed on repeat MRI.

MRI has been widely used for evaluating children with a dilated urinary tract after preliminary assessment with ultrasonography and VCUG. A diagnostic accuracy rate of 93.4% has been reported when MRI is performed in children with hydronephrosis detected on ultrasonography.³ MRI simultaneously provides both morphological and functional information without exposure to ionising radiation and iodinated contrast agent. However, CMS was not diagnosed on preoperative MRI in this case. If UVJO is severe, there is significant ureteral dilatation, and CMS may be overlooked. In this case, fold-like findings were observed when the preoperative MRI images were reviewed postoperatively, but it was impossible to point out these findings when the MRI images were first interpreted.

CMS is typically not diagnosed preoperatively, and definite diagnosis is usually made through retrograde assessment of the ureter.² The use of RGP as a part of routine preoperative imaging in patients with congenital hydronephrosis remains controversial. Preoperative RGP is recommended in patients with unexpected ureteral lesions, such as mid-ureteral stricture, ureteral polyp, and retrocaval ureter. In addition to confirming the diagnosis, RGP will enable surgical intervention and anastomosis to be performed with an adequate exposure without the need to extend the incision.⁴ In this case, RGP was not performed because the diagnosis of UVJO was obvious on preoperative MRI. Based on our experience, we believe that RGP should be performed in all patients before starting surgery, especially since anaesthesia is already being induced in them, and therefore, there is no additional risk.

We found that the use of MRI alone could lead to CMS being overlooked. RGP was helpful not only for assessing stricture size and length, but also for ensuring appropriate decision making. Routine intraoperative RGP is strongly recommended to avoid missing unexpected ureteral lesions and minimize the impact of operator errors during MRI.

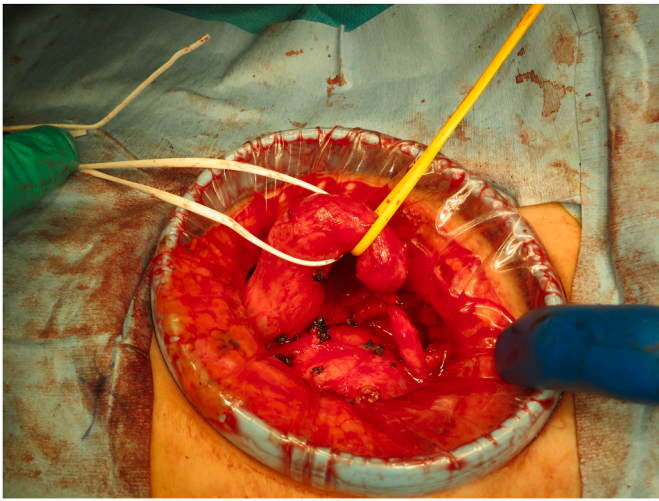


Fig. 3. There is a clear difference in diameter anterior and posterior the mid-ureteral stricture.

4. Conclusion

We report a very rare case of coexisting UVJO and CMS. CMS may be overlooked on preoperative MRI, and it is important to carefully consider the surgical treatment approach. Intraoperative RGP is very important for assessing strictures of the UVJO.

Section heading

Pediatrics.

Consent

Written informed consent was obtained from the parents of the

patient for the publication of this report.

Funding

This research did not receive any specific grant from funding agencies in the public, commercial, or not-for-profit sectors.

Author contributions

Shotaro Nakanishi, Kei Tanaka, and Namiko Uema: conceptualisation, writing-original draft, writing-review, and editing. Minoru Miyazato and Seiichi Saito: supervision.

Declaration of competing interest

None.

Acknowledgments

We would like to thank Editage (www.editage.com) for English language editing.

References

1. Wu CQ, Kirsch AJ. Robot-assisted laparoscopic Heineke-Mikulicz ureteroplasty for congenital mid-ureteral stricture and ipsilateral distal megaureter repair in a child. *J Endourol Case Rep.* 2019;5(3):88–91.
2. Hwang AH, McAleer IM, Shapiro E, Miller OF, Krous HF, Kaplan GW. Congenital mid ureteral strictures. *J Urol.* 2005;174(5):1999–2002.
3. Emad-Eldin S, Abdelaziz O, El-Diasty TA. Diagnostic value of combined static-excretory MR urography in children with hydronephrosis. *J Adv Res.* 2015;6(2):145–153.
4. Ruano-Gil D, Coca-Payeras A, Tejedo-Mateu A. Obstruction and normal recanalization of the ureter in the human embryo. Its relation to congenital ureteric obstruction. *Eur Urol.* 1975;1(6):287–293.