

# Bilateral synchronous male breast cancer

*Nnamdi J. Nwashilli, FWACS, FMCS, Ezekiel E. Ugiagbe, MBBS, FMCPATH.*

## ABSTRACT

سرطان الثدي المتزامن الثنائي هو مرض نادراً للغاية. وجد لدى رجل يبلغ من العمر 75 عاماً كتلة في الثدي الأيمن، والذي من المتوقع وجود تورم في الثدي الأيسر. وكشف فحص الثدي الأيمن من وجود قرحة في الثدي 7x10cm مع حواف مقلوبة للخارج وحلقة مدمرة بالكامل. أظهر الثدي الأيسر كتلة من الصعب قياسها 4x5cm في منطقة الهلالية للحلقة، غير مرتبط على الجلد، أو البنية التحتية. لم يكن هناك عقدة ليمفاوية إبطية محسوسة في كلا الجانبين. أكدت خزعة إسفين من اليمين قرحة الثدي واستئصال ورم الثدي الأيسر الثنائي الغازية سرطان الأبقية - في الورم من الصنف 2 في كلا الثديين. و أجري له استئصال بسيط الثنائي للثدي والعلاج الكيميائي. وتعتبر لمدة 18 شهرا خلال فترة العلاج، وعاد الورم الثنائي. إن أهمية هذا التقرير هو لنشر المزيد من الوعي بأن سرطان الثدي يمكن أن يحدث للذكور وليس فقط في الإناث، على الرغم من أن حدوثه للذكور أمر نادر. يوفر التشخيص المبكر ومتابعة العلاج نتائج أفضل.

Bilateral synchronous breast cancer is extremely rare. A 75-year-old man presented with a right breast mass, which ulcerated and a lump in the left breast. Right breast examination revealed a breast ulcer 7x10cm with everted edges and complete nipple destruction. The left breast showed a hard lump measuring 4x5cm in the nipple-areolar area, unattached to skin, or underlying structure. There was no palpable axillary lymph node bilaterally. A wedge biopsy of right breast ulcer and excision of the left breast lump confirmed bilateral invasive ductal carcinoma - Grade 2 tumor in both breasts. He had bilateral simple mastectomy and chemotherapy; defaulted for 18 months during treatment, and re-presented with bilateral tumor recurrence. The importance of this case report is to create more awareness that breast cancer can occur in males just as in females, though the incidence is rare in males. Early presentation and compliance with treatment modality provide a better outcome.

*Saudi Med J 2015; Vol. 36 (3): 359-362  
doi: 10.15537/smj.2015.3.10109*

*From the Department of Surgery, University of Benin Teaching Hospital, Benin City, Edo State, Nigeria.*

*Received 28th August 2014. Accepted 26th November 2014.*

*Address correspondence and reprint request to: Dr. Nnamdi J. Nwashilli, Department of Surgery, University of Benin Teaching Hospital, Benin City, Edo State, Nigeria. E-mail: namoforever@yahoo.com*

Male breast cancer is rare in men and accounts for 1% of all breast cancers.<sup>1</sup> A bilateral synchronous presentation is extremely rare with an incidence of 1-2.5% of the total number of patients with breast cancer.<sup>2</sup> Bilateral breast cancer is defined as the presence of an independent primary malignant tumor in each mammary gland. The term "synchronous" refers to the presence of primary tumors in both breasts, which are diagnosed simultaneously.<sup>3</sup> The incidence of metachronous breast cancer is higher than that of synchronous male breast cancer.<sup>4</sup> Most cases of male breast cancer are detected between the ages of 60 and 70 with a mean age of 67 years which is older than the mean age of females.<sup>5</sup> The risk factors for male breast cancer include familial and genetic factors (BRCA2), radiation exposure, Klinefelter's syndrome, hormonal imbalance, obesity, and testicular disease (undescended testis, orchitis, orchiectomy).<sup>1</sup> Although breast cancer in males presents in a similar way to that of females, there is limited data regarding treatment of male breast cancer, and most treatment recommendations are extrapolated from data in women.<sup>6</sup> Male breast cancer tends to be diagnosed at an older age, and at a more advanced stage than female breast cancer; hence, the overall survival rate is lower in males.<sup>7</sup> However, outcomes are comparable when age at diagnosis and stage are adjusted.<sup>5</sup> This study examines a 75-year-old man who was diagnosed with bilateral synchronous

**Disclosure.** Authors have no conflict of interests, and the work was not supported or funded by any drug company.

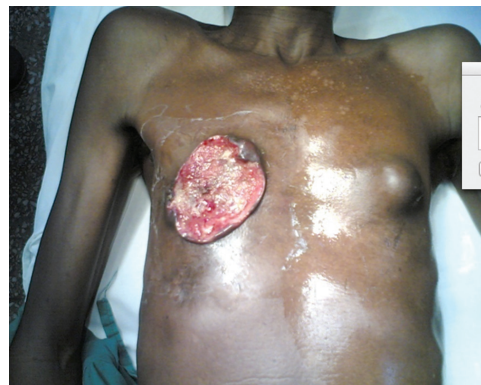male breast cancer; he had bilateral simple mastectomy and chemotherapy; then defaulted for 18 months during treatment and re-presented with bilateral tumor recurrence. Our objective in presenting this case is to highlight that breast cancer can occur in males just as in females, though the incidence is rare in males. Early presentation and compliance with treatment modality provide a better outcome.

**Case Report.** Our patient is a 75-year-old man who noticed a lump in the right breast 2 years prior to presentation. The lump was initially small in size, painless, but progressively increased in size. Following massage and application of herbal medication, the lump ulcerated with complete nipple destruction (Figure 1). Around the same time he noticed a lump in the left breast, he felt a small lump in the left breast, which was the size of a bean seed, painless, and progressively increased in size. There was no history of nipple discharge, ulcer, or itching of the left breast. There was no antecedent history of trauma to both breasts and no family history of breast disease/malignancy. He had no history of cough, chest pain, night sweats, weight loss, or difficulty in breathing. There was no history of abdominal pain/swelling, yellowness of the eyes, bone pain, or low backache. He drank 2 bottles of alcohol daily for approximately 30 years, and smoked a pack of cigarette daily for 9 years. General examination revealed an elderly man, chronically ill-looking, not pale, afebrile, anicteric, not dehydrated, with neither pedal edema, nor peripheral lymph node enlargement. The right breast examination revealed an ulcerated breast with complete nipple destruction. The ulcer measured 7 x 10 cm with everted edges, non-tender with sloughs on the floor, and hypo/hyper pigmented surrounding skin. The left breast showed a hard lump measuring 4 x 5 cm in the nipple-areolar area with no differential warmth, non-tender, and unattached to skin or underlying structure. There was no palpable axillary lymph node bilaterally. The examinations of other systems were essentially normal.

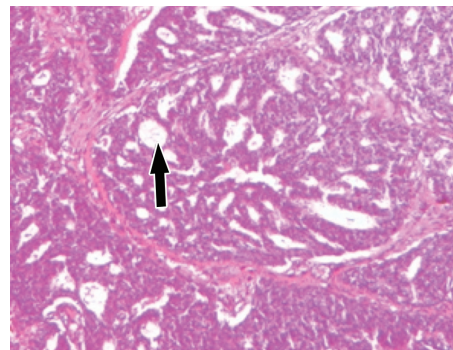
Full blood count, random blood sugar, electrolytes, urea and creatinine carried out were normal. An abdominal ultra-sonography and chest radiograph did not reveal features of metastasis. The tumor-lymph node-metastasis (TNM) staging was T4bN0Mx in the right breast, and T3aN0Mx in the left breast. A wedge biopsy of the right breast ulcer and excision biopsy of the left breast lump confirmed a bilateral invasive ductal carcinoma (Figures 2 & 3). Sections of both breasts show a malignant neoplastic lesion composed of malignant

ducts, sheets, and nests of atypical polygonal epithelial cells with invasion of the stroma and surrounding tissues by these cells. These cells have large ovoid to round hyperchromatic nuclei with numerous abnormal mitosis. Both breast tumors were grade 2 (Nottingham modification of Bloom-Richardson breast cancer grading system). The estrogen, progesterone, and Her-2-neu status were not carried out due to lack of facilities; hence, he was neither treated with tamoxifen nor Trastuzumab (Herceptin).

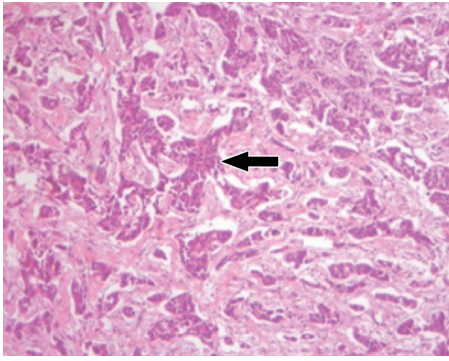
He had bilateral simple mastectomy without axillary dissection because there was no palpable axillary lymph node (Figure 4). In addition, axillary lymph node dissection in advanced breast cancer is not advocated, as it does not improve the overall survival. He had 2 cycles of Cyclophosphamide, Adriamycin, and 5-flourouracil chemotherapy regime. He defaulted after the second cycle of chemotherapy for 18 months and represented with bilateral tumor recurrence (Figure 5), marked weight loss, and ascites. He is presently being worked up for chemotherapy.



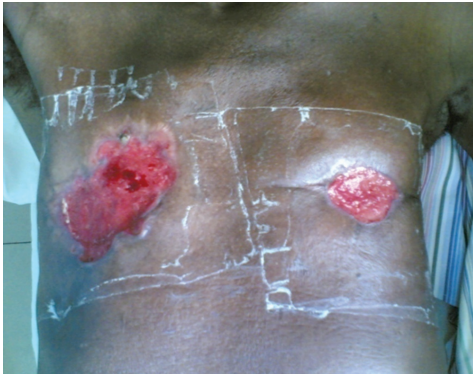
**Figure 1** - Picture at presentation showing ulcerated right breast with complete nipple destruction and a left breast lump.



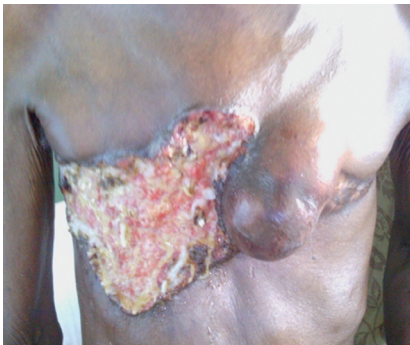**Figure 2** - Left breast: invasive ductal carcinoma. Arrow shows focal area of mucin between sheets of malignant cells.



**Figure 3** - Right breast: invasive ductal carcinoma. Arrow shows sheets of malignant cells surrounded by desmoplastic stroma.



**Figure 4** - Picture after bilateral simple mastectomy.



**Figure 5** - Tumor recurrence after patient defaulted from treatment for 18 months.

**Discussion.** Bilateral breast cancer is defined as the presence of an independent primary malignant tumor in each mammary gland while the term “synchronous” refers to the presence of primary tumors in both breasts, which are diagnosed simultaneously.<sup>3</sup> Our patient had tumors in both breasts on hospital admission. A total of 24 cases of synchronous bilateral male breast cancer

have been reported as of August 2011 using a PubMed search.<sup>4</sup> This corroborates the fact that the incidence of metachronous breast cancer is higher than that of synchronous.<sup>4</sup> Although breast cancer can affect men of all ages, the median age at diagnosis is 60-70 years,<sup>2</sup> which is in keeping with the age of 75 in our patient. Presentation is usually late with more than 46% of patients having stage III or IV of the disease at the time of diagnosis,<sup>8</sup> which is similar to our case. This can be attributed to low awareness, absence of screening protocols in men, and limited amount of mammary tissue in male, thus allowing rapid local invasion.<sup>8</sup> The most frequent histological type in men is invasive ductal carcinoma (85-90%),<sup>9</sup> which is similar to the findings of our patient. Other rare invasive tumors are invasive papillary (4.5%) and mucinous (2.8%) papillary carcinoma. Although breast cancer in males presents in a similar way to that in females, there is limited data regarding treatment of male breast cancer, and most treatment recommendations are extrapolated from data in women.<sup>6</sup> The mainstay of treatment is based on local and regional control of the disease with surgery.<sup>10</sup> Other adjuvant therapies are chemotherapy, radiotherapy, and hormone therapy.<sup>10</sup> This was similar to the treatment of our patient, which comprised simple mastectomy and chemotherapy, though he did not fully comply initially with the chemotherapy regime.

The prognosis of male breast cancer remains uncertain because of the late diagnosis, unpredictable course, and high potential for metastasis.<sup>11</sup> The prognosis does not seem to be poor compared with females when age and stage are matched.<sup>11</sup>

The importance of this case report is to create more awareness that breast cancer can occur in males just like females, although it is rare in males. A painless lump, bloody nipple discharge, or retraction in a male, especially an elderly male, requires thorough evaluation and on confirmation of cancer, compliance with treatment modalities is necessary to ensure good outcome.

In conclusion, breast cancer is rare in males, and extremely rare is bilateral synchronous breast cancer. Early presentation and compliance with treatment schedule will help reduce the incidence of tumor recurrence and provide better prognosis for the patient.

**Acknowledgment.** *Dr. Ezekiel E. Ugiagbe reviewed the slides for clarity and correctness.*

## References

1. Weiss JR, Moysich KB, Swede H. Epidemiology of male breast cancer. *Cancer Epidemiol Biomarkers Prev* 2005; 14: 20-26.



2. Sosnovskikh I, Naninato P, Gatti G, Caldarella P, Masullo M, De Brito LL, et al. Synchronous bilateral breast cancer in men: a case report and review of the literature. *Tumori* 2007; 93: 225-227.
3. Sun WY, Lee KH, Lee HC, Ryu DH, Park JW, Yun HY, et al. Synchronous bilateral male breast cancer: a case report. *J Breast Cancer* 2012; 15: 248-251.
4. Lambley J, Maguire E, Yin Lam K. Synchronous bilateral breast cancer in an elderly man. *Breast J* 2005; 11: 153.
5. Giordano SH. A review of the diagnosis and management of male breast cancer. *Oncologist* 2005; 10: 471-479.
6. Burstein HJ, Harris JR, Morrow M, editors. Malignant tumors of the breast. In: Principles and practice of oncology. 9th ed. Philadelphia (PA): Lippincott Williams & Wilkins; 2011. p. 14001-14006.
7. Giordano SH, Cohen DS, Buzdar AU, Perkins G, Hortobagyi GN. Breast carcinoma in men: a population-based study. *Cancer* 2004; 101: 51-57.
8. dos Santos VM, Cintra Osterne EM, de Castro RA, Marques HV Jr. Bilateral male breast cancer: too many concerns? *Asian Pac J Cancer Prev* 2007; 8: 640-641.
9. Burga A, Fadare O, Lininger RA, Tavassoli F. Invasive carcinoma of the male breast: a morphologic study of the distribution of histologic subtypes and metastatic patterns in 778 cases. *Virchows Arch* 2006; 449: 507-512.
10. Gomez RC, Zambrana F, Serreno M, Lopez M, Casado E. Male breast cancer. *Treat Rev* 2010; 36: 451-457.
11. Borgen PI, Seine RT, McKinnon WM, Rosen PP. Carcinoma of the male breast: analysis of prognosis compared with matched female patients. *Ann Surg Oncol* 1997; 4: 385-388.

## References

- \* References should be primary source and numbered in the order in which they appear in the text. At the end of the article the full list of references should follow the Vancouver style.
- \* Unpublished data and personal communications should be cited only in the text, not as a formal reference.
- \* The author is responsible for the accuracy and completeness of references and for their correct textual citation.
- \* When a citation is referred to in the text by name, the accompanying reference must be from the original source.
- \* Upon acceptance of a paper all authors must be able to provide the full paper for each reference cited upon request at any time up to publication.
- \* Only 1-2 up to date references should be used for each particular point in the text.

Sample references are available from:  
[http://www.nlm.nih.gov/bsd/uniform\\_requirements.html](http://www.nlm.nih.gov/bsd/uniform_requirements.html)