



Case report

Surgical and histological evidence of case reports showing Schwannomas in the nasal area

Pier Francesco Galzignato^a, Salvatore Chirumbolo^{b,*}, Walter Cestaro^c, Antonio Scapinello^d, Dario Bertossi^a, Riccardo Nocini^e

^a Department of Surgery, Dentistry, Paediatrics and Gynaecology-Unit of Oral and Maxillofacial Surgery, University of Verona, Verona, Italy

^b Department of Neurosciences, Biomedicine and Movement Sciences, University of Verona, Verona, Italy

^c ENT Consultant, Head and Neck Department, ULSS 2 Marca Trevigiana, Treviso, Italy

^d Division of Medical Oncology 2, Veneto Institute of Oncology IOV - IRCCS, Padua, Italy

^e Department of Surgery, Dentistry, Gynaecology, and Paediatrics, Unit of Otorhinolaryngology, University of Verona, Verona, Italy

ARTICLE INFO

Keywords:

Schwannoma
Nasal cavity
Nasal TC
Nasal surgery
Endoscopy
Case report

ABSTRACT

Introduction and importance: Schwannomas are benign neurogenic neoplasms with an uncommon involvement of the nasal cavity and paranasal sinus, which usually appear as a painless formation. We report two cases of nasal schwannoma that was successfully treated by surgical excision with satisfactory functional outcomes. The aim of this study is to discuss the clinical assessment and imaging, (CT, MRI) differential diagnosis, histological examination, surgical approaches of this rarely encountered neoplasm in the sinus-nasal area.

Case presentation: Case 1: a 53 years-old Caucasian male, hospitalized in the ENT Department with a 5-month progressive history of right nasal obstruction without epistaxis was diagnosed as a Schwannoma following clinical, histology and ENT endoscopy examination. Case 2: a 45 years-old Caucasian male with asymptomatic swelling arising 4 months before in the nasal tip area with progressive nasal deformity, diagnosed as a schwannoma and analyzed with MRI.

Clinical discussion: Case 1: The patient had an uneventful post-operative course and a follow-up examination at 36 months showed no recurrence of the neoplasm with satisfactory functional result. Case 2: The patient had an uneventful post-operative course and a follow-up examination at 5 years showed no recurrence of the neoplasm and satisfactory aesthetic result.

Conclusions: Schwannomas arising from sinonasal area are extremely rare, painless and with slow-growing evolution. The surgical option and histologic analysis are mandatory for a correct diagnosis.

1. Introduction

Schwannomas are benign low-growing nerve sheath tumors that occur in the head and neck area in the 25–50% of total cases [1–3]. The sinus-nasal involvement is even uncommon and represents less than 4% of all head and neck schwannomas [3,4]. In the literature approximately 100 cases of intranasal schwannomas have been reported so far [1–3]. From a clinical standpoint, they often appear as slowly growing formation with progressive nasal obstruction with or without epistaxis, hyposmia and headaches [5]. Nasal endoscopy, computing tomography (CT) and magnetic resonance imaging (MRI), with intravenous contrast, are recommended to determine the extent of the neoplasm and the more appropriate surgical approach. If pre-operative biopsy allows

differential diagnosis with other sinus-nasal neoplasms, the surgical excision is the treatment of choice, whereas histopathology provides the conclusive diagnosis. In this manuscript, we are reporting two cases of frontal sinus schwannomas, localized in the nasal area (septum and the nasal tip) successfully treated with conservative surgical excision and resulting in a satisfactory functional outcome without any sign of recurrence.

2. Case presentation

2.1. Case 1

A 53 years-old Caucasian male was hospitalized in the ENT

* Corresponding author at: Department of Neurosciences, Biomedicine and Movement Sciences, University of Verona, Strada Le Grazie 9, Italy.

E-mail address: salvatore.chirumbolo@univr.it (S. Chirumbolo).

<https://doi.org/10.1016/j.ijscr.2022.107165>

Received 11 April 2022; Received in revised form 1 May 2022; Accepted 1 May 2022

Available online 4 May 2022

2210-2612/© 2022 Published by Elsevier Ltd on behalf of IJS Publishing Group Ltd. This is an open access article under the CC BY-NC-ND license (<http://creativecommons.org/licenses/by-nc-nd/4.0/>).

Department with a 5-month progressive history of right nasal obstruction without epistaxis. No history of nasal trauma, infection or previous surgery was reported. The clinical and ENT endoscopy examination revealed a soft, mobile and non-pulsatile right-sided nasal formation arising from the septum and partially occluding the right-side nasal airway. A CT scan of the paranasal sinuses with intravenous contrast showed a well-outlined formation arising from the right side of the nasal septum mucosa without bone erosion (Fig. 1, arrow). No biopsy was performed before surgery. Under both general and local anaesthesia of the nose with infiltration of mepivacaine 2% with epinephrine (1:200.000), the surgical procedure started with a unilateral right hemitransfixion incision 4 mm cephalic to the lower border of the caudal septum with a n°15 blade. Through a complete sub-perichondrium dissection the entire right septum was exposed and the formation was clearly identified and completely excised with partial resection of the adjacent septal cartilage maintaining the integrity of the left septal mucosa. Nasal packing was placed for 2 days and pre-operative antibiotic prophylaxis therapy with 2 g intravenous cefazolin was carried out. Clinical and radiological outcome at 3 years of follow-up showed any local recurrence of the formation. The lesion consisted of a nodule of 0,8 cm overlaid by smooth mucosal surface (Fig. 2). Immunohistochemistry and haematoxylin-eosin stain were performed. Histology revealed a sub-epithelial spindle cell proliferation with Antoni-A and Antoni-B areas of variable cellularity without evidence of malignancy (i. e. cytological atypia, mitotic activity, necrosis and haemorrhage) (Fig. 3). From an immuno-histochemical view, the tumour cells were strongly and diffusely positive for S-100 staining (Fig. 4). A final diagnosis of nasal septum schwannoma was therefore reported. The patient had an uneventful post-operative course and a follow-up examination at 36 months showed no recurrence of the neoplasm with satisfactory functional result. Following the intervention, the tumoral formation was excised (CT scan, Fig. 5).

2.2. Case 2

A 45 years-old Caucasian male entered the ENT Department complaining of a progressive asymptomatic swelling arising 4 months before in the nasal tip area with progressive nasal deformity, having left partial

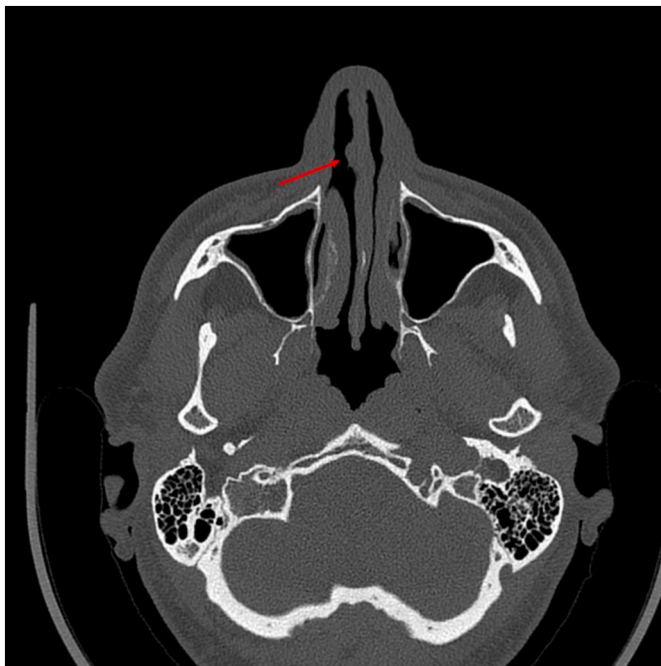


Fig. 1. Case 1: CT scan showing a focal bulging formation of right lateral nasal septum (arrow).

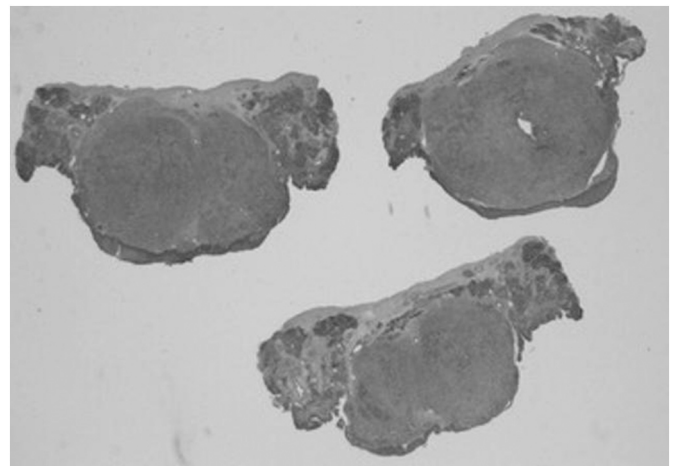


Fig. 2. Case 1: Scan at low power magnification shows the nodular conformation of the lesion.

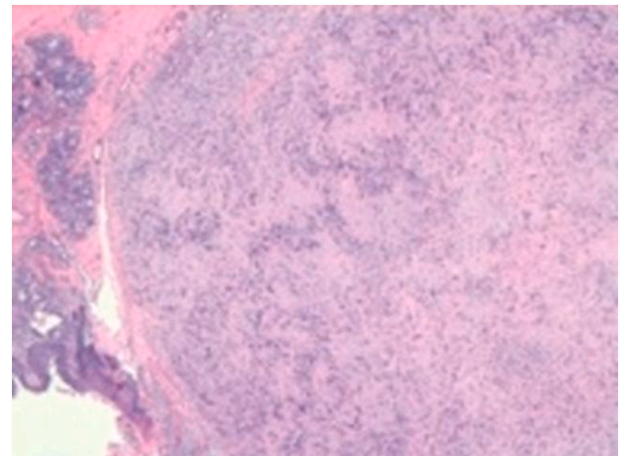


Fig. 3. Case 1: The lesion is composed by spindle cell proliferation with Antoni-A and Antoni-B areas.

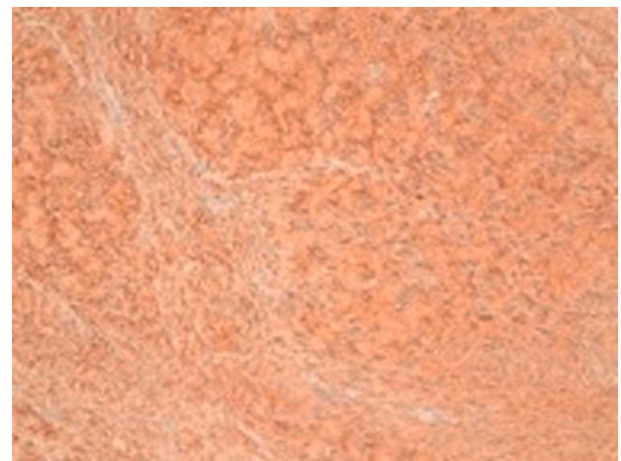


Fig. 4. Case 1: spindle cells were strongly and diffusely positive at S100 immuno-stain (brown, S100, 250 diameters). (For interpretation of the references to colour in this figure legend, the reader is referred to the web version of this article.)

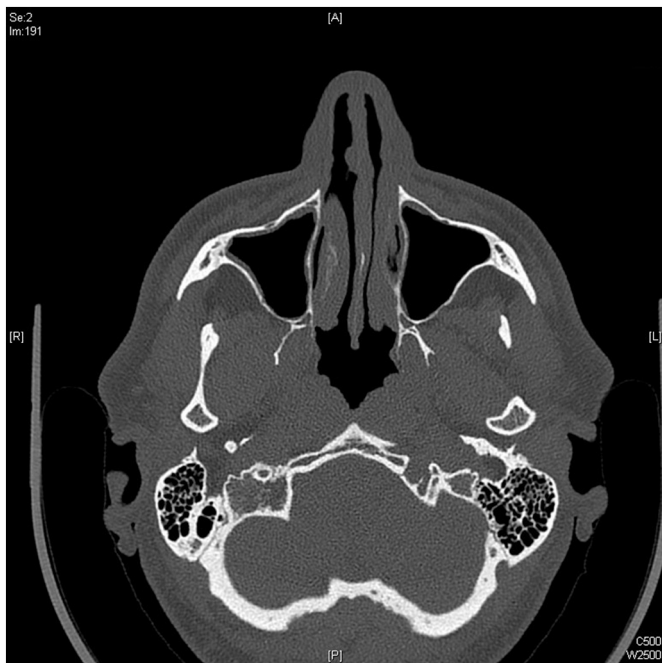


Fig. 5. Case 1: CT scan showing the excision (absence) of the previous formation shown in Fig. 1.

nasal obstruction (Fig. 5). An MRI with contrast showed a round well-defined soft tissue formation located in the tip area (Fig. 6). Under general anaesthesia with local infiltration with mepivacaine 2% endowed with epinephrine (1:200.000), the surgical procedure was

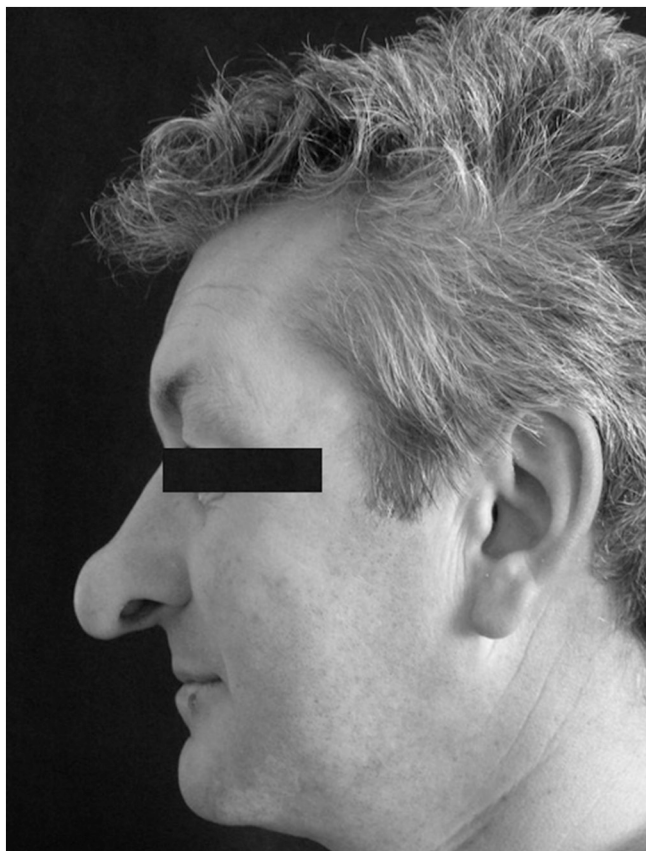

Fig. 6. Case 2: Preoperative lateral view showing the nasal tip deformity.

performed via an open approach with a trans-columellar incision followed by marginal incisions. A careful dissection from surrounding tissues, such as nasal skin superiorly and sub-perichondrial inferiorly from lower lateral cartilages was performed bilaterally to expose a well-encapsulated tissue formation that was later completely excised. An inter-domal suture was performed to correct the weakened alar cartilages and to maintain the tip projection and shape. The appearance of the surgical specimen was a white, polyploid and soft nodular lesion with smooth surface of maximum 2 cm of diameter. Haematoxylin-Eosin (HE) and immunohistochemical (IHC) stains were performed (Fig. 7). A well delimited spindle cell proliferation with thick-walled vessels and pattern of alternating Antoni A and B areas was observed in HE stains. In Antoni A, nuclear palisading and Verocay bodies formation were evident (Fig. 8). Nuclear atypia was absent and the mitotic index was unremarkable (less than 1/50 high power field). Immunohistochemically, tumour cells were strongly and diffusely positive for S-100 staining. A final diagnosis of nasal septum schwannoma was reported (Fig. 9). The patient had an uneventful post-operative course and a follow-up examination at 5 years showed no recurrence of the neoplasm and satisfactory aesthetic result (Fig. 10 MRI) (Figs. 11 and 12).

3. Discussion

All case reports did not show drug history, family history including any relevant genetic information, and psychosocial history including smoking status and where relevant accommodation type, walking aids, etc. Data and procedures were performed by expert authors of us (PFG, WC, DB). When appropriate the patient should share their perspective on the treatments they received. No relevant - intervention adherence and tolerability were needed. Moreover, no particular peri-intervention considerations - administration of intervention and particular pharmacological therapies were applied.

Nasal schwannomas (NSs) are a rare, benign and a slow growth tumour and only approximately 100 cases in the sinus-nasal tract have been reported in the literature [4,5]. Syndromic forms should not be confused with the wider spectra of neurofibromatosis, for which there are two main types of neurofibromatosis, namely a) type 1 neurofibromatosis (NF1), which is the most common type of neurofibromatosis,

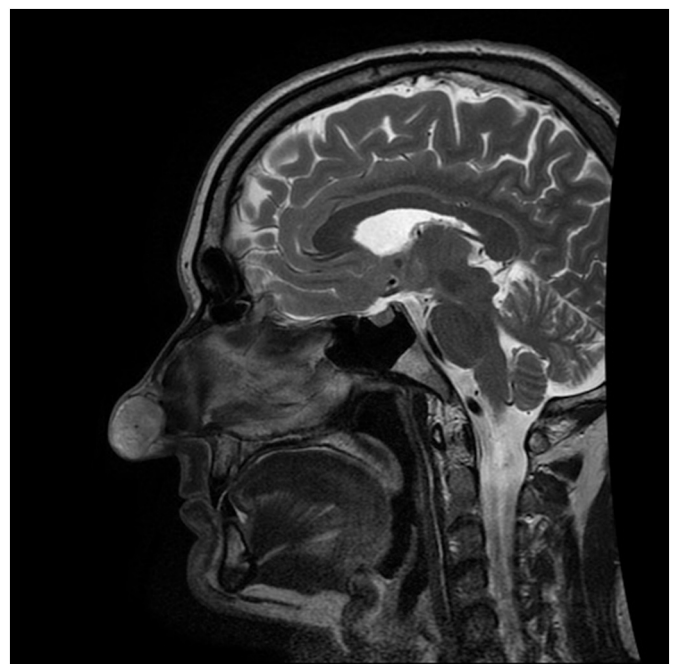


Fig. 7. Case 2: Sagittal view of non-contrast MRI scan showing the nasal tip mass.

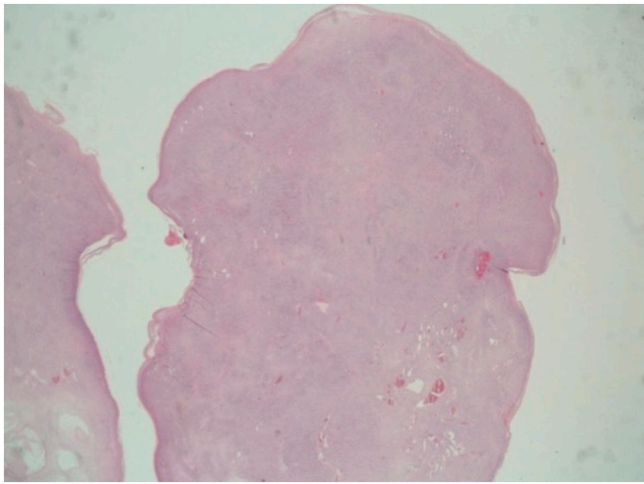


Fig. 8. Polypoid lesion covered by squamous epithelium with cellular stroma.

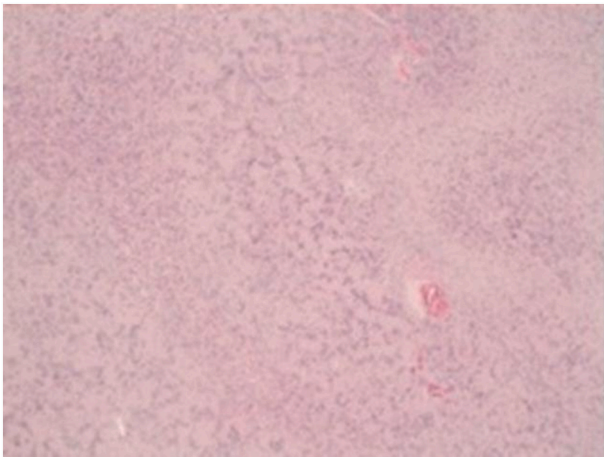


Fig. 9. Case 2: spindle cell proliferation with thick-walled vessels and pattern of alternating Antoni A and B areas (HE, 200 diameters).

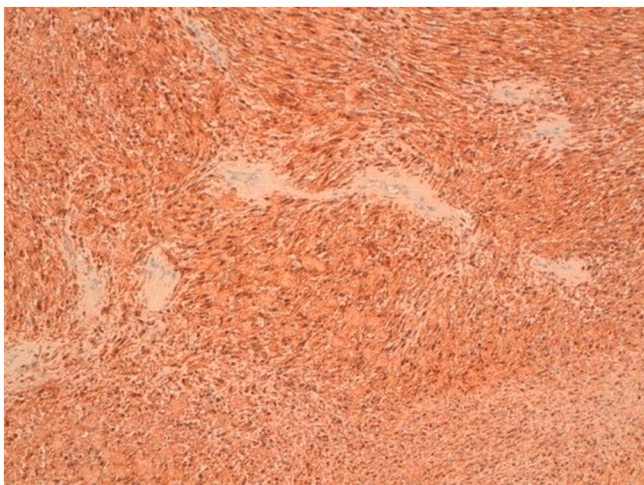


Fig. 10. Case 2: spindle cells were strongly and diffusely positive at S100 immuno-stain (brown, S100, 250 diameters). (For interpretation of the references to colour in this figure legend, the reader is referred to the web version of this article.)

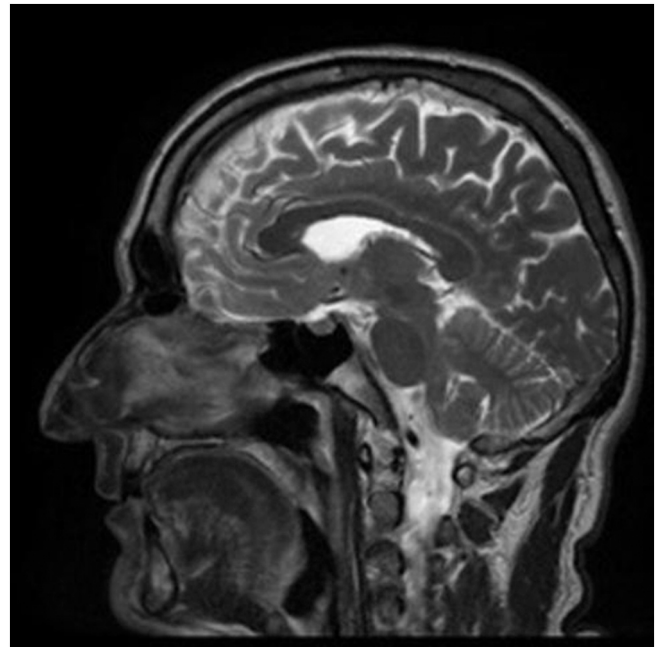


Fig. 11. Case 2: Sagittal view of non-contrast MRI showing the nasal tip after the surgical excision of the formation.

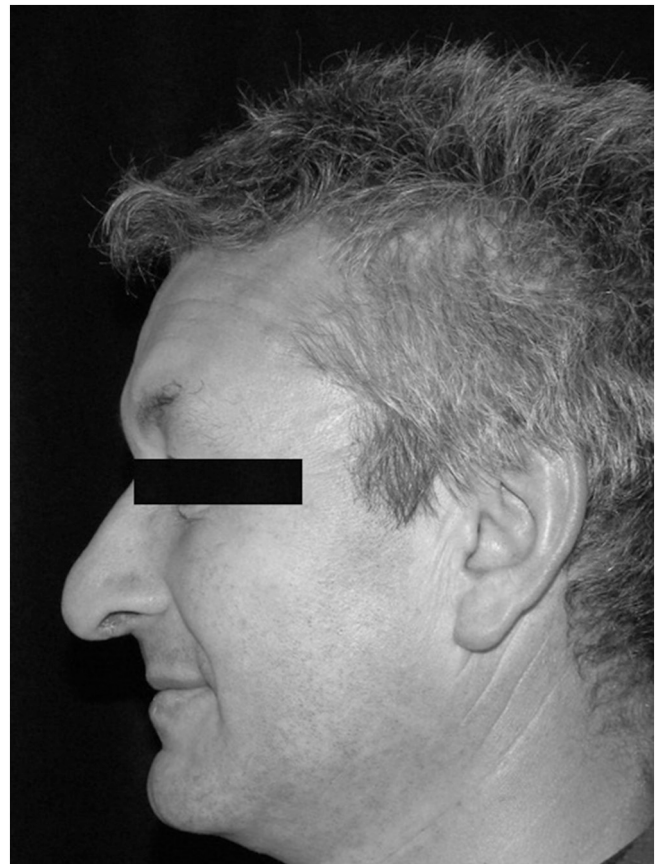


Fig. 12. Case 2: Postoperative view after 2 years since surgical excision.

affecting approximately one in 3000 people, and b) type 2 neurofibromatosis (NF2) is less common, affecting approximately one in 35,000 people. Despite sharing the same name, the two types of neurofibromatosis are distinct conditions that have different causes and symptoms.

Neurofibromatosis type 2 (NF-2) is caused by a mutation in the “merlin” gene, a tumour suppressor gene located in the 22q12 region. It has an autosomal dominant mode of inheritance with high penetrance. 50% of cases are represented by new mutations. This pathological condition is found in about 5% of subjects suffering from acoustic neuroma (retro-cochlear sensorineural deafness) The clinical picture is represented by the presence of tumors of the central and peripheral nervous system (neuromas, gliomas, meningiomas), which depending on their location give rise to different symptoms. Neurofibromatosis type II (or “MISME Syndrome”, for “Multiple Inherited Schwannomas, Meningiomas, and Ependymomas”/Inherited Multiple Schwannomas, Meningiomas, and Ependymomas”) or Central Neurofibromatosis, or Neurofibromatosis type 2 (NF2), is a disease hereditary, genetic characterized by a predisposition to develop a variety of tumors of the central and peripheral nervous system. The main manifestation of the disease is the development of symmetrical non-malignant brain tumors in the region of the VIII cranial nerve, which is the “cochlear-vestibular nerve” that transmits sensory information from the inner ear to the brain. Most people with this condition can have vision problems. NF2 is caused by mutations in the “Merlin” gene [6] which appear to affect the shape and movement of cells. The main treatments consist of neurosurgical removal of tumors and surgical treatment of ocular lesions. In contrast to type 1 neurofibromatosis (NF1), NF2 produces a paucity of skin manifestations.

The diagnostic placing of schwannomas is therefore a major matter of debate [7–19]. Schwannomas, can be found in many sites, including the nasal septum, paranasal sinus, tip of the nose, turbinate, and nasopharynx [5,6,20] and moreover can occur at any age, with a peak incidence generally between 20 and 50 years without gender difference [21]. From a pathological insight, schwannomas are very unusual tumors of the sinus-nasal tract and are often associated with nonspecific symptoms, besides to histologically differing from schwannomas found in other locations [14]. Usually, sinus-nasal schwannomas are treated with conservative surgical resection giving an excellent prognosis.

If schwannomas of head and neck typically arise from sympathetic or parasympathetic peripheral nerves, however, in the sinus-nasal area the nerve origin is difficult to assess [5] and it has been suggested that nasal schwannomas (NSs) may originate from the ophthalmic or maxillary branches of the trigeminal nerve or from sympathetic or parasympathetic fibres from the carotid plexus or sphenopalatine ganglion [22]. In both cases NSs may arise from the somatosensory nerves of the nasal septum (nasopalatine nerve or nasal-ciliary nerve branches). Patients are generally asymptomatic or non-specific, depending on the site of the neoplasm. The most common symptom is a painless progressive unilateral nasal obstruction with infrequent epistaxis, headache, hyposmia or anosmia in case of intracranial involvement or with ptosis or diplopia in case of orbital involvement [23]. Usually the diagnostic workup for NSs should include ENT endoscopy, CT and MRI of the paranasal sinuses to determine the extent of neoplasm and the treatment planning [5]. These cases highlight the need to include schwannoma in any differential diagnosis of any soft tissue formation of the sinus-nasal spaces. The differential diagnosis includes mainly further causes such as inflammatory processes (sarcoidosis, Wegener's granulomatosis, foreign body granuloma and other autoimmune causes), neoplastic lesions (juvenile angiofibroma, solitary fibrous tumour, hemangiopericytoma, basal and squamous cell carcinoma, lymphoma, aesthesia-neuroblastoma, malignant peripheral nerve sheath tumour, meningioma, sarcomas and melanoma) and non-neoplastic processes such as polyps, cysts, and mucoceles [5]. The final diagnosis of schwannoma can be achieved only by histologic analysis of the excised mass specimen that usually shows encapsulated nodule with alternation of Antoni areas A and B and strong immunohistochemical staining with S100. In more difficult cases a larger panel of immunohistochemical markers could be useful in differential diagnosis with muscle differentiated neoplasm (smooth muscle actin, desmin, and caldesmon) and CD34 could be

useful in differentiating from solitary fibrous tumors. Malignant lesion as melanotic schwannomas generally have quite different histologic aspect but could be separated by immunohistochemical positivity for anti-human melanosome clone B5 (HMB45) and melan A (MART1) [24]. In both cases we found a nasal septum encapsulated lesion with thick-walled vessels and bundles of organized spindle cells with histologic and immunohistochemical aspect highly characteristic of schwannoma without any sign (mitotic activity, atypia or necrosis) of malignancy. As most schwannomas have focal origin and are in the most part slow-growing and encapsulated, these tumors are commonly amenable to endoscopic resection [25,26]. In our experience the surgical option for the treatment of NSs was based on their localization and extension. However, the endoscopic and the open rhinoplasty approach have been proved to be adequate approaches for a complete excision of both formations. The potential recurrence of this neoplasm is due to its incomplete excision.

4. Conclusions

Our work has been reported in line with the SCARE checklist [27].

This manuscript adds new views about the diagnosis of sinonasal (nasal) schwannomas, posing new insights to expand the debate in the field.

Schwannomas arising from sinus-nasal area are extremely rare, painless and with slow-growing evolution. Approaches to address them and retrieve the best outcome expected, needs further research to be accomplished and further technology tools and devices to improve surgery. The surgical option and histologic analysis are mandatory for a correct diagnosis and treatment.

Provenance and peer review

Not commissioned, externally peer-reviewed.

Sources of funding

None.

Ethical approval

N.A. Outpatients giving their consent for the study.

Consent

Written informed consent was obtained from the patient for publication of this case report and accompanying images. A copy of the written consent is available for review by the Editor-in-Chief of this journal on request.

Author contribution

PFG: conceptualization; surgical performance, data collection, manuscript validation; SC: manuscript writing, manuscript revision, data search, validation, manuscript submission; WC: data management, lab analysis, data collection; AS: data collection and elaboration; DB data management, validation, approval; RN data and research management.

Research registration

N.A.

Guarantor

PFG.

Declaration of competing interest

None.

References

- [1] M.M. Sheikh, O.De Jesus, Schwannoma, in: StatPearls [Internet] 2021 Jan, StatPearls Publishing, Treasure Island (FL), 2021 Feb 7.
- [2] C. Suárez, F. López, W.M. Mendenhall, S. Andreasen, L.H. Mikkelsen, J. A. Langendijk, S. Bondi, J.P. Rodrigo, L. Bäck, A.A. Mäkitie, V. Fernández-Alvarez, A. Coca-Pelaz, R. Smee, A. Rinaldo, A. Ferlito, Trends in the management of non-vestibular skull base and intracranial schwannomas, *Cancer Manag Res* 13 (2021) 463–478.
- [3] K. Devaraja, D.R. Nayak, B. Ramaswamy, P. Rao, Nasal septal schwannoma: a rare sinonasal tumour with certain peculiarities, *BMJ Case Rep.* 2018 (2018), bcr2017223850.
- [4] A. Iyer, A. Meyer, A.M. Iloreta, S. Govindaraj, B. Miles, R. Shrivastava, Schwannomas of the frontal sinus: cases and review of the literature, *World Neurosurg.* 110 (2018) 485–491.
- [5] O. Cakmak, H. Yavuz, T. Yucel, Nasal and paranasal sinus schwannomas, *Eur. Arch. Otorhinolaryngol.* 260 (4) (2003) 195–197.
- [6] W. Pellet, P.H. Roche, La microchirurgie des schwannomes vestibulaires, *Neurochirurgie* 50 (2-3Pt2) (2004) 195–243.
- [7] B.A. Khalele, Schwannoma of the hard palate: a case report and a systematic review of literature, *Future Dent. J.* 4 (1) (2018) 30–35, <https://doi.org/10.1016/j.fdj.2018.01.004>.
- [8] M. Röhrich, C. Koelsche, D. Schrimpf, D. Capper, F. Sahm, A. Kratz, et al., Methylation-based classification of benign and malignant peripheral nerve sheath tumors, *Acta Neuropathol.* 131 (6) (2016) 877–887.
- [9] Y. Leu, K. Chang, Extracranial head and neck schwannomas: a review of 8 years' experience, *Acta Otolaryngol.* 122 (4) (2002) 435–437.
- [10] M. Bisceglia, C. Galliani, G. Giannatempo, W. Lauriola, M. Bianco, V. D'Angelo, et al., Solitary fibrous tumor of the central nervous system: a 15-year literature survey of 220 cases (August 1996-july 2011), *Adv. Anat. Pathol.* 18 (5) (2011) 356–392.
- [11] A. Minovi, O. Basten, B. Hunter, W. Drafi, U. Bockmühl, Malignant peripheral nerve sheath tumors of the head and neck: management of 10 cases and literature review, *Head Neck* 29 (5) (2007) 439–445.
- [12] S.L. Hasegawa, T. Mentzel, C.D.M. Fletcher, Schwannomas of the sinonasal tract and nasopharynx, *Mod. Pathol.* 10 (8) (1997) 777–784.
- [13] M. Berlucchi, C. Piazza, L. Blanzuoli, G. Battaglia, P. Nicolai, Schwannoma of the nasal septum: a case report with review of the literature, *Eur. Arch. Otorhinolaryngol.* 257 (7) (2000) 402–405.
- [14] D. Buob, A. Wacrenier, D. Chevalier, S. Aubert, J. Quinchon, B. Gosselin, et al., Schwannoma of the sinonasal tract: a clinicopathologic and immunohistochemical study of 5 cases, *Arch. Pathol. Lab. Med.* 127 (9) (2003) 1196–1199.
- [15] A.F. Nascimento, C.D.M. Fletcher, The controversial nosology of benign nerve sheath tumors: neurofilament protein staining demonstrates intratumoral axons in many sporadic schwannomas, *Am. J. Surg. Pathol.* 31 (9) (2007) 1363–1370.
- [16] J. Vitte, F. Gao, G. Coppola, A.R. Judkins, M. Giovannini, Timing of Smarcb1 and Nf2 inactivation determines schwannoma versus rhabdoid tumor development, *Nat. Commun.* 8 (1) (2017) 1–4.
- [17] E. Langner, A. Del Negro, H.K. Akashi, P.P.C. Araújo, A.J. Tincani, A.S. Martins, Schwannomas in the head and neck: retrospective analysis of 21 patients and review of the literature, *Sao Paulo Med. J.* 125 (4) (2007) 220–222.
- [18] R.V. Moukarbel, A.N. Sabri, Current management of head and neck schwannomas, *Curr. Opin. Otolaryngol. Head Neck Surg.* 13 (2) (2005) 117–122.
- [19] M.P. Colreavy, P.D. Lacy, J. Hughes, D. Bouchier-Hayes, P. Brennan, A.J. O'Dwyer, et al., Head and neck schwannomas - a 10 year review, *J. Laryngol. Otol.* 114 (2) (2000) 119–124.
- [20] R. Sharma, I. Tyagi, D. Banerjee, R. Pandey, Nasoethmoid schwannoma with intracranial extension. Case report and review of literature, *Neurosurg. Rev.* 21 (1) (1998) 58–61.
- [21] C. Ross, E. Wright, J. Moseley, R. Rees, Massive schwannoma of the nose and paranasal sinuses, *South. Med. J.* 81 (12) (1998) 1588–1591.
- [22] B. McMonagle, A. Al-Sanosi, G. Croxson, P. Fagan, Facial schwannoma: results of a large case series and review, *J. Laryngol. Otol.* 122 (11) (2008) 1139–1150.
- [23] K.P. O'Connor, P.E. Pelargos, A.H. Palejwala, H. Shi, L. Villeneuve, C.A. Glenn, Resection of pediatric trigeminal schwannoma using minimally invasive approach: case report, literature review, and operative video, *World Neurosurg.* 127 (2019) 518–524.
- [24] E. Keskin, S. Ekmekci, O. Oztekin, G. Diniz, Melanotic schwannomas are rarely seen pigmented tumors with unpredictable prognosis and challenging diagnosis, *Case Rep. Pathol.* 2017 (2017) 1807879, <https://doi.org/10.1155/2017/1807879>.
- [25] A.A.K. Abdel Razeq, O.A. Gamaleldin, N.A. Elsebaie, Peripheral nerve sheath tumors of head and neck: imaging-based review of World Health Organization classification, *J. Comput. Assist. Tomogr.* 44 (6) (2020) 928–940.
- [26] H.J. Min, S.C. Hong, K.S. Kim, Nasal septal schwannoma: advances in diagnosis and treatment, *J. Craniofac. Surg.* 28 (1) (2017) e97–e101.
- [27] R.A. Agha, T. Franchi, C. Sohrabi, G. Mathew, for the SCARE Group, The SCARE 2020 guideline: updating consensus Surgical CAse REport (SCARE) guidelines, *International Journal of Surgery* 84 (2020) 226–230.