


# In-stent restenosis of superficial femoral artery: use all arrows in the quiver

Giuseppe Vadalà<sup>1</sup> , Fabrizio Ceresa<sup>2</sup>, Francesco Costa<sup>3</sup>, Antonio Bottari<sup>3</sup>, Giuseppe Roscitano<sup>4</sup>, Francesco Patanè<sup>2</sup> and Antonio Micari<sup>3,\*</sup>

<sup>1</sup>Cardiovascular Department, University Hospital "Policlinico P. Giaccone", Palermo, Italy

<sup>2</sup>Division of Cardiac Surgery, Department of Cardio-Thoraco-Vascular Surgery, Papardo Hospital, Messina, Italy

<sup>3</sup>Department of Biomedical, Dental, Morphological and Functional Imaging Sciences, University of Messina, Messina, Italy

<sup>4</sup>Department of General Surgery and Medical Specialities, University of Catania, Catania, Italy

\*Correspondence address. Interventional Cardiology Department, Policlinic G. Martino, University of Messina, Via C. Valeria 1, Messina 98100, Italy.  
E-mail: micarantonio@gmail.com

## Abstract

In-stent restenosis (ISR) is a common superficial femoral artery (SFA) stenting complication, occurring in more than one third of patients within 2–3 years after the index procedure. Moreover, there is no standard treatment for ISR, and although many options are available, there is still limited data regarding its optimal management. We report a paradigmatic case report of a patient complaining of symptomatic peripheral arterial disease, underwent multiple endovascular revascularizations for recurrent femoro-popliteal ISR. A step-by-step approach was followed. At the time of the first presentation, the ISR was treated by drug-eluting balloon (DEB) angioplasty. The repeated ISR was treated by laser debulking, achieving a good angiographic result. Finally, after the third repeated restenosis, a combined approach with laser debulking and DEB angioplasty guaranteed a good acute angiographic result. Long-term duplex-scan follow-up demonstrated the good patency of the femoro-popliteal target lesion.

A 53-year-old man treated with percutaneous transluminal angioplasty (PTA) and bare-metal stent in the left superficial femoral artery (SFA), popliteal artery and tibioperoneal trunk 1 year earlier (Fig. 1A and B), presented with recurrent symptoms of Rutherford stage 3 claudication. He was an active heavy smoker since he was 18 years old and hypercholesterolemic on treatment with statins. No other cardiovascular risk factors or diseases were reported in the past medical history. He was scheduled to repeat the lower limb revascularization. Selective angiography revealed severe in-stent restenosis (ISR) (i.e. Tosaka class 2; Fig. 1C), which was treated with PTA and paclitaxel drug-eluting balloon (DEB) (Inpact Pacific 4.0/150 and 5.0/80, Medtronic Vascular, Santa Clara, CA) with a satisfactory result (Fig. 1D). After 18 months, the patient suffered rapidly evolving recurrent pain at rest. Duplex scan and angiography revealed recurrent ISR, with a focal pattern (Tosaka class 1; Fig. 2A and B). Re-intervention was carried out with lesion debulking with excimer laser atherectomy (TurboTandem, Spectranetics, Colorado Springs, CO) followed by re-PTA with paclitaxel DEB (Inpact Admiral 4.0/120 and 5.0/120, Medtronic Vascular, Santa Clara, CA), with good immediate result (Fig. 3A and B). The patient remained free of symptoms thereafter and 24-month duplex scan revealed stent patency without signs of ISR (Fig. 3C).

## DISCUSSION

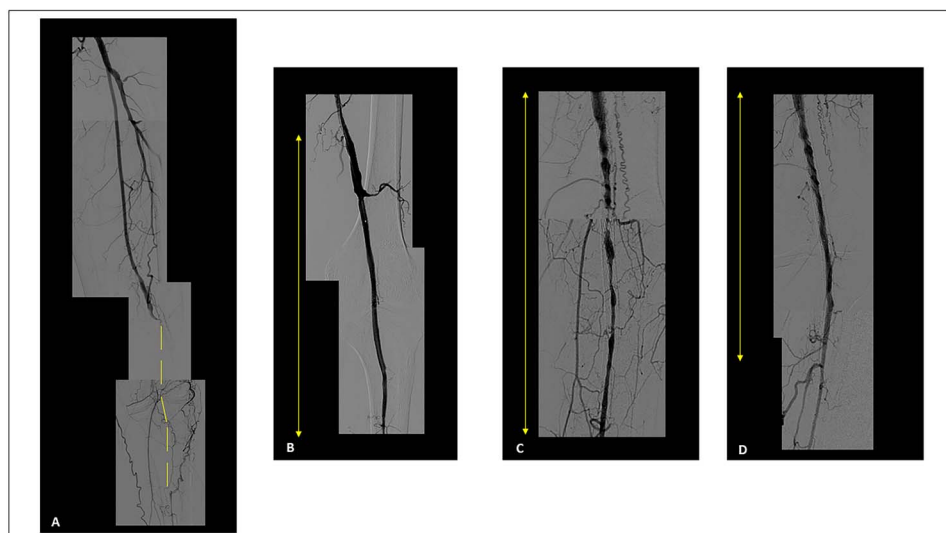
ISR is a frequent complication of SFA stenting, occurring in ~40% of patients within 2–3 years after device implantation. Currently, there is no standard treatment for ISR, and although many options

are available, there is still limited data regarding its optimal management. In this paradigmatic case, we have shown that re-intervention after SFA is common, and different approaches have been needed to achieve longer-term results. Data from randomized controlled trials (RCT) and meta-analysis confidently show that PTA with DEB is superior to plain balloon angioplasty in terms of patency rate and target lesion revascularization, reducing the risk of re-intervention by 56% at 12 months [1]. Yet, results with different types of DEB have been inconsistent. Hence, given the heterogeneous clinical response to different DEB technologies, results from trials should be considered device-specific rather than class-specific [2, 3]. In our case, treatment with DEB provided good immediate results, but focal ISR was evident within 18 months. A mixed technique including both atherectomy and DEB angioplasty provided better results. At difference with de-novo atherosclerosis, ISR is predominantly caused by neointimal hyperplasia, with excessive proliferation of smooth muscle cells and hydrated collagen matrix. Direct removal of this tissue with atherectomy and subsequent elution of antiproliferative drug through DEB could provide more durable results. To date, only one RCT compared DEB alone with atherectomy plus DEB, showing better stent patency at 12 months, with roughly halved ISR rates in the experimental arm [4]. These data are in line with our explanatory case, yet this was a single center, relatively small, study. In addition, results from this trial do not necessarily apply to all kinds of atherectomy devices. The optimal treatment for ISR is still unknown, and future studies testing DEB (and types thereof), atherectomy (and types thereof), covered stents or drug-

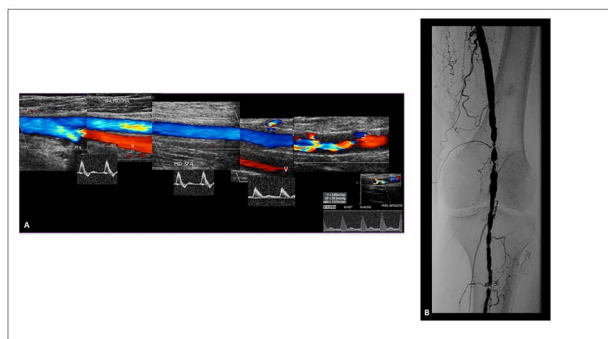
Received: March 11, 2022. Revised: July 29, 2022. Accepted: August 21, 2022

© The Author(s) 2022. Published by Oxford University Press. All rights reserved. For permissions, please e-mail: journals.permissions@oup.com

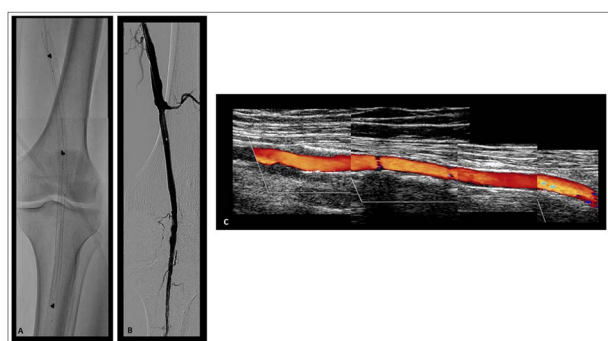
This is an Open Access article distributed under the terms of the Creative Commons Attribution Non-Commercial License (<http://creativecommons.org/licenses/by-nc/4.0/>), which permits non-commercial re-use, distribution, and reproduction in any medium, provided the original work is properly cited. For commercial re-use, please contact journals.permissions@oup.com



**Figure 1.** Selective digital subtraction angiography. (A) Left distal superficial femoral and popliteal arteries occlusion (yellow dot line). (B) Result after uncoated balloon angioplasty and stenting. The yellow arrow marks the total treated stented segment. (C) Diffuse in-stent restenosis (Tosaka class II) at 1 year follow-up. (D) Result after drug eluting balloon repeated angioplasty.



**Figure 2.** (A) Duplex scan shows a focal critical in-stent restenosis. (B) Focal ISR at both proximal and distal segment of the stent.



**Figure 3.** (A) Excimer laser debulking. (B) Result after excimer laser debulking and drug eluting balloon angioplasty. (C) Duplex scan at 24 months shows the patency of the stented segment.

eluting stents should be rigorously conducted to provide novel insights in this field.

## CONFLICT OF INTEREST

No conflicts of interest must be declared.

## FUNDING

This is an own work. No funds must be declared.

## ETHICAL APPROVAL

For the case report submission is not required an ethical approval of our Institution.

## CONSENT

The patient provided the consent to undergo all the endovascular procedures and he provided the authorization for his case publication.

## GUARANTOR

All the authors are nominated Guarantor of the manuscript.

## REFERENCES

1. Tong Z, Guo L, Qi L, Cui S, Gao X, Li Y et al. Drug-coated balloon angioplasty and debulking for the treatment of femoropopliteal in-stent restenosis: a systematic review and meta-analysis. *Biomed Res Int* 2020;**2020**:3076346–14. <https://doi.org/10.1155/2020/3076346>.
2. Micari A, Cioppa A, Vadalà G, Stabile E, Castriota F, Pantaleo P et al. A new paclitaxel-eluting balloon for angioplasty of femoropopliteal obstructions: acute and midterm results. *EuroIntervention* 2011;**7**:K77–82. <https://doi.org/10.4244/EIJV7SKA14>.
3. Scheinert D, Micari A, Brodmann M, Tepe G, Peeters P, Jaff MR et al. Drug-coated balloon treatment for femoropopliteal artery disease. *Circ Cardiovasc Interv* 2018;**11**:e005654. <https://doi.org/10.1161/CIRCINTERVENTIONS.117.005654>.
4. Gandini R, Del Giudice C, Merolla S, Morosetti D, Pampana E, Simonetti G. Treatment of chronic SFA in-stent occlusion with combined laser atherectomy and drug-eluting balloon angioplasty in patients with critical limb ischemia: a single-center, prospective, randomized study. *J Endovasc Ther* 2013;**20**:805–14. <https://doi.org/10.1583/13-4308MR.1>.