



Contents lists available at ScienceDirect

## International Journal of Surgery Case Reports

journal homepage: [www.casereports.com](http://www.casereports.com)

## Surgical management of complicated intra-mural duodenal hematoma: A case-report and review of literature



Walid Elmoghazy<sup>a,\*</sup>, Islam Noaman<sup>a</sup>, Ahmed-Emad Mahfouz<sup>b</sup>, Ahmed Elaffandi<sup>a</sup>, Hatem Khalaf<sup>a</sup>

<sup>a</sup> Department of Surgery, Division of Organ Transplant, Hamad General Hospital, Doha, Qatar

<sup>b</sup> Department of Radiology, Hamad General Hospital, Doha, Qatar

### ARTICLE INFO

#### Article history:

Received 5 July 2015

Received in revised form 19 October 2015

Accepted 20 October 2015

Available online 30 October 2015

#### Keywords:

Duodenal hematoma

Bleeding

Duodenal diverticulum

Failed conservation

Surgical management

### ABSTRACT

**INTRODUCTION:** Intramural duodenal hematoma (IDH) is a rare pathological entity that occurs as a complication of trauma, pancreatitis, peptic ulcer disease or endoscopic biopsy procedures. In this report, we present a case of IDH related to a duodenal diverticulum that was complicated by intra-abdominal bleeding and peritonitis.

**PRESENTATION OF CASE:** We report a 31-year old male who presented with pancreatitis that was complicated with IDH, as diagnosed using endoscopy and CT scan of the abdomen. The condition was related to a duodenal diverticulum as appears on imaging. The patient was treated conservatively over a course of 1 week when he started to have intra-abdominal bleeding and developed peritonitis. The patient was successfully treated with laparotomy, drainage of intra-abdominal abscess, evacuation of IDH and repair of duodenal perforation. We discuss this case in the context of the current indications of surgery in cases of IDH.

**CONCLUSION:** Despite shift towards conservative management of IDH cases over last few decades, these cases should be handled carefully as they might develop life-threatening complications.

© 2015 The Authors. Published by Elsevier Ltd. on behalf of IJS Publishing Group Ltd. This is an open access article under the CC BY-NC-ND license (<http://creativecommons.org/licenses/by-nc-nd/4.0/>).

### 1. Introduction

Intramural duodenal hematoma (IDH) is a rare pathology that commonly results from blunt abdominal trauma. Other causes include pancreatitis, peptic ulcer disease, and endoscopic procedures [1,2]. As awareness of this pathological entity and diagnostic abilities has improved, there is changing paradigm towards conservative management.

We report a case of intramural duodenal hematoma that happened in relation to pancreatitis and duodenal diverticulum. It was complicated by intra-abdominal bleeding, peritonitis and sepsis that required prompt surgical intervention.

### 2. Case presentation

A 31 years old alcoholic male presented with a 3-day history of epigastric pain, recurrent vomiting, and constipation. The patient had no co-morbidities and was not on any medications

at time of presentation. He had normal vital signs, and abdominal examination was unremarkable except for revealed mild epigastric tenderness.

Laboratory work-up showed a raised white cell count (23,000 cells/mm<sup>3</sup>), normal liver and kidney functions. Amylase and lipase were however, elevated. Coagulation profile was normal. An abdominal ultrasound showed no evidence of collection or inflammation in the gallbladder or elsewhere in the abdomen. Based on the previous findings, a provisional diagnosis of acute alcoholic pancreatitis was made and the patient was admitted to the hospital.

Two days later, he had hematemesis and underwent an endoscopy that showed complete obstruction of the duodenum. No active bleeding was detected down to the level of this mass (Fig. 1).

Subsequent magnetic resonance imaging (MRI) showed the presence of retroperitoneal duodenal hematoma extending to the root of the mesentery, duodenal diverticulum, radiological evidence of acute pancreatitis, but no evidence of active bleeding or perforation (Fig. 2).

The patient was managed conservatively by keeping him nil per oral, nasogastric tube insertion, and by administration of intravenous antibiotics, and intravenous fluids. The patient had no further attacks of hematemesis, white cell count dropped to 9700 cells/mm<sup>3</sup>, and fever subsided.

On the 6th day of admission, the patient's clinical condition started to deteriorate; he developed high grade fever, tachycardia and signs of peritonitis. His hemoglobin dropped from 12.2 gm/dl

*Abbreviation:* IDH, intramural duodenal hematomas.

\* Correspondence to: Hamad Medical Corporation (HMC), P.O. Box 3050, Doha, Qatar. Fax: +974 44357106.

*E-mail addresses:* [wshehata@hamad.qa](mailto:wshehata@hamad.qa), [Moghazyw@gamil.com](mailto:Moghazyw@gamil.com)

(W. Elmoghazy), [INoaman@hamad.qa](mailto:INoaman@hamad.qa) (I. Noaman), [AMAHFOUZ@hamad.qa](mailto:AMAHFOUZ@hamad.qa) (A.-E. Mahfouz), [AElaffandi@hamad.qa](mailto:AElaffandi@hamad.qa) (A. Elaffandi), [HKhalaf2@hamad.qa](mailto:HKhalaf2@hamad.qa) (H. Khalaf).

<http://dx.doi.org/10.1016/j.ijscr.2015.10.028>

2210-2612/© 2015 The Authors. Published by Elsevier Ltd. on behalf of IJS Publishing Group Ltd. This is an open access article under the CC BY-NC-ND license (<http://creativecommons.org/licenses/by-nc-nd/4.0/>).

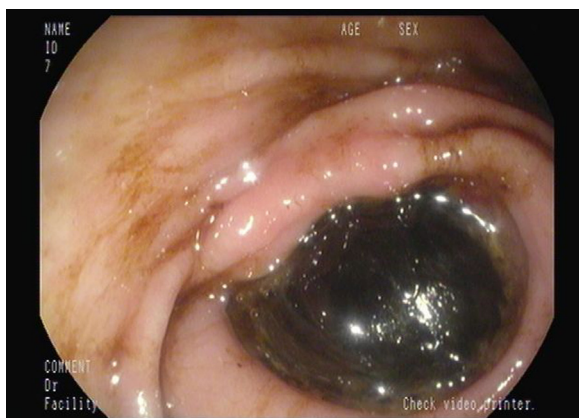


Fig. 1. endoscopic view of the hematoma.

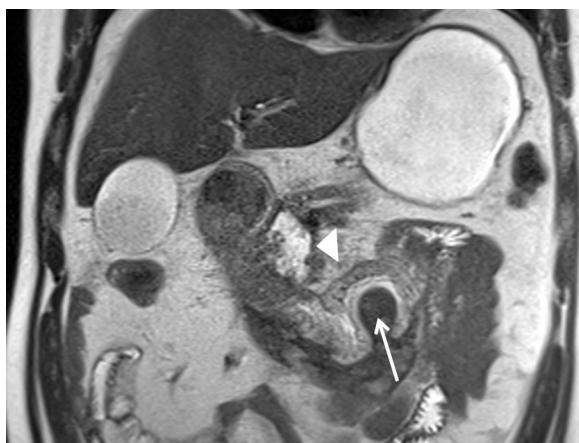


Fig. 2. Coronal T2-weighted magnetic resonance image shows an intramural hematoma causing thumb-printing of the third part of the duodenum (arrow) and fluid-filled diverticulum medial to the second part of the duodenum (arrowhead).

to 10 gm/dl over the course of 2 h. A routine chest X-ray showed free air under the right side of the diaphragm that was not evident before. However, in view of diagnosis of peritonitis, an exploratory laparotomy was decided.

Hemoperitoneum was found throughout the abdomen with an intra-abdominal abscess found between the loops of proximal small bowel and the greater omentum. Duodenal perforation was diagnosed, and blood clots were retrieved from the duodenum, however the duodenal mucosa looked healthy. The adjacent wall

of the second part of the duodenum was seen to be dusky with an overlying pyogenic membrane.

A prepyloric gastrotomy was performed, through which the duodenal mucosa was examined. An old healed ulcer could be palpated in the first part of the duodenum.

Peritoneal lavage was done, then duodenal exclusion with a Bancroft suture and gastrojejunostomy were performed, gastroduodenal artery was ligated (the presumed source of bleeding), and cholecystectomy was done. The site of perforation looked unhealthy for doing either a Graham’s patch repair or primary closure, and thus a controlled duodenal fistula was fashioned using a 14 Fr silicone catheter at the site of the perforation.

A follow-up computed tomography scan (CT) was done on post-operative day 12, and showed clearance of hematoma with enhancing duodenal tissues apart from the unhealthy area in the second part.

The patient’s postoperative period was uneventful. In the middle of his second postoperative week a trans-tubal dye study was conducted through the duodenostomy tube, and revealed no leak prior to its removal. The patient was discharged from the hospital 3 weeks after surgery. Six months after surgery, patient was seen in the outpatient clinic, he is doing well with no medical or surgical concerns.

This report is consistent with the guidelines published by the CARE group [3].

### 3. Discussion

We present a case of intramural duodenal hematoma that happened in relation to pancreatitis and duodenal diverticulum, and was further complicated by rupture and intra-abdominal bleeding and peritonitis, and necessitated surgical intervention.

IDH occurs mostly due to blunt abdominal trauma however; it may complicate pancreatitis, endoscopic biopsy, or peptic ulcer disease [4–6].

As diagnostic abilities, using CT and MRI have improved markedly over the last few decades as well as awareness of duodenal hematomas has increased, conservative management has become the standard of care. In most cases, IDH responds to this management within 10–15 days [7,8].

However, conservative management may fail, and intervention using endoscopy, surgery or radiological guidance becomes necessary [8]. Several reports [9,10] presented cases of IDH with persistent or even worsening gastric outlet obstruction using the conservative management. Lee et al. [9], reported successful endoscopic decompression of IDH with worsening gastric outlet obstruction over a course of 1 week using conservative management, symptoms improved rapidly after evacuation of hematoma.

Table 1  
Review of cases of intramural duodenal hematoma requiring surgical intervention.

| Author                   | Year | Number of cases | Age group                | Etiology  | Management  |
|--------------------------|------|-----------------|--------------------------|---|---|
| Moore et al. [11]        | 1963 | 33              | 14 adults<br>19 children | Mainly trauma                                       | 31 operative<br>2 diagnosed at autopsy                    |
| Jewett et al. [12]       | 1988 | 182             | All children             | Trauma  | 121 operative<br>61 conservative                          |
| Diniz Santos et al. [13] | 2006 | 18              | 12 children<br>6 adults  | Endoscopic duodenal biopsy                          | 3 operative<br>1 US-guided drainage<br>14 conservative    |
| Yeung et al. [14]        | 2009 | 16              | All children             | Trauma  | 3 operative<br>2 laparoscopic drainage<br>11 conservative |
| Shiozawa et al. [15]     | 2010 | 33              | 8 children<br>25 adults  | 17 endoscopic biopsy<br>11 pancreatitis<br>5 others | 7 operative<br>26 conservative                            |

Simi et al. [10] described surgical evacuation of IDH to relieve gastrointestinal obstruction after failure of conservative management.

Current indications for intervention include complicated IDH with compression of bile duct and development of jaundice, and massive intra-abdominal bleeding [8,10].

The change of paradigm in management of such intramural hematomas was described by Sorbello et al. [7], who reviewed small bowel hematomas that occur secondary to anticoagulant therapy, and noted that the percentage of cases requiring surgical intervention declined from 40% in the 1981–1986 period, to 28% in the post 1986 period, and all of the surgical interventions in the cases reviewed prior to 1986 were for diagnostic purpose, while post 1986 67% of the surgical intervention were for therapeutic purpose. This shift correlates with the advent of CT scan as a diagnostic method [7].

Similar shift can be observed in IDH cases, as shown in Table 1, large case series and reports of IDH discussed 236 cases before the year 2000 and 157 (67%) cases were managed by operative intervention. After 2000, there are 46 reported cases of IDH with 10 (22%) of them required drainage [2,11–15].

To the best of our knowledge, this is the first report of a case of intra-mural duodenal hematoma related to duodenal diverticulum that gets complicated by intra-abdominal bleeding and peritonitis.

In conclusion, despite the successful shift towards conservative management of IDH cases over last few decades, these cases should be handled carefully as they might develop life-threatening complications.

#### Conflicts of interest

Nothing to disclose.

#### Sources of funding

None.

#### Ethical approval

Approved, Hamad Medical Research Centre, Qatar, HMC R00760.

#### Consent

Written informed consent was obtained from the patient for publication of this case report and any accompanying images.

#### Authors' contributions

WE prepared material, drafting and review. IN prepared material and drafting. AEM reviewed and prepared images. AE drafting. HK review.

All authors read and approved the final manuscript.

#### Guarantors

Walid Elmoghazy, Islam Noaman, Ahmed-Emad Mahfouz, Ahmed Elaffandi, Hatem Khalaf.

#### Acknowledgement

None.

#### References

- [1] T. Khurana, A. Shah, I. Ali, R. Islam, A.A. Siddiqui, Intramural duodenal hematoma with acute pancreatitis a patient with an overt pancreatic malignancy, *ACG Case Rep. J.* 1 (4) (2014) 209–211.
- [2] M.S. Ahn, K. Miyai, J.M. Carethers, Intramural duodenal hematoma presenting as a complication of peptic ulcer disease, *J. Clin. Gastroenterol.* 33 (1) (2001) 53–55.
- [3] J.J. Gagnier, G. Kienle, D.G. Altman, D. Moher, H. Sox, D. Riley, The CARE guidelines: consensus-based clinical case reporting guideline development, *BMJ Case Rep.* (October) (2013).
- [4] J.D. Silva, N. Veloso, R. Godinho, L. Gonçalves, I. Medeiros, C. Viveiros, Fatal acute pancreatitis following sclerosis of a bleeding duodenal ulcer complicated by an intramural duodenal hematoma, *Rev. Esp. Enferm. Dig. (Madrid)* 104 (11) (2012) 603–604.
- [5] K. Chang-II, K.H. Ko, H.Y. Kim, S.P. Hong, S.G. Hwang, P.W. Park, et al., Bowel obstruction caused by an intramural duodenal hematoma: a case report of endoscopic incision and drainage, *J. Korean Med. Sci.* 24 (2009) 179–183.
- [6] N. Fukunaga, M. Ishikawa, Y. Yamamura, T. Ichimori, A. Sakata, Spontaneous intramural duodenal hematoma complicating acute pancreatitis, *Surgery* 149 (2011) 143.
- [7] M.P. Sorbello, E.M. Utiyama, J.G. Parreira, D. Birolini, S. Rasslan, Spontaneous intramural small bowel hematoma induced by anticoagulant therapy: review and case report, *Clinics* 62 (6) (2007) 785–790.
- [8] T. Takishima, M. Hirata, Y. Kataoka, et al., Delayed development of obstructive jaundice and pancreatitis resulting from traumatic intramural haematoma of the duodenum: report of a case requiring deferred laparotomy, *J. Trauma* 49 (2000) 160–162.
- [9] J.Y. Lee, J.S. Chung, T.H. Kim, Successful endoscopic decompression for intramural duodenal hematoma with gastric outlet obstruction complicating acute pancreatitis, *Clin. Endosc.* 45 (2012) 202–204.
- [10] S. Simi, T.M. Anoop, K.C. George, Spontaneous intramural duodenal hematoma—a rare cause of upper gastrointestinal obstruction, *Am. J. Emerg. Med.* 28 (5) (2010) 642, e1–2.
- [11] S.W. Moore, M.E. Erlandson, Intramural hematoma of the duodenum, *Ann. Surg.* 157 (May (5)) (1963) 798–809.
- [12] T.C. Jewett Jr., V. Caldarola, M.P. Karp, J.E. Allen, D.R. Cooney, Intramural hematoma of the duodenum, *Arch. Surg.* 123 (January (1)) (1988) 54–58.
- [13] D.R. Diniz-Santos, R.C. de Andrade Cairo, H. Braga, C. Araújo-Neto, I.B. Paes, L.R. Silva, Duodenal hematoma following endoscopic duodenal biopsy: a case report and review of the existing literature, *Can. J. Gastroenterol.* 20 (2006) 39–42.
- [14] V.H.P. Yeung, N.S.Y. Chao, M.W.Y. Leung, W.K. Kwok, An unusual cause of intestinal obstruction in an adolescent: a case report and management review, *Pediatr. Rep.* 1 (2009) e8.
- [15] K. Shiozawa, M. Watanabe, Y. Igarashi, Y. Matsukiyo, T. Matsui, Yasukiyo Sumino, Acute pancreatitis secondary to intramural duodenal hematoma: case report and literature review, *World J. Radiol.* 2 (July (7)) (2010) 283–288.

#### Open Access

This article is published Open Access at [sciedirect.com](http://sciedirect.com). It is distributed under the [IJSCR Supplemental terms and conditions](#), which permits unrestricted non commercial use, distribution, and reproduction in any medium, provided the original authors and source are credited.