

RESEARCH ARTICLE

Open Access

Solid component ratio influences prognosis of GGO-featured IA stage invasive lung adenocarcinoma



Fenghao Sun[†], Yiwei Huang[†], Xiaodong Yang, Cheng Zhan, Junjie Xi, Zongwu Lin, Yu Shi, Wei Jiang and Qun Wang^{*}

Abstract

Background: The computed tomography (CT) characteristic of ground glass opacity (GGO) were shown to be associated with clinical significance in lung adenocarcinoma. We evaluated the prognostic value of the solid component ratio of GGO IA invasive lung adenocarcinoma.

Methods: We retrospectively analyzed the records of GGO IA patients who received surgical resection from April 2012 to December 2015. The solid component ratio was calculated based on thin-slice CT scans. Baseline features were compared stratified by the ratio. Cox proportional hazard models and survival analyses were adopted to explore potential prognostic value regarding overall survival (OS) and disease-free survival (DFS).

Results: Four hundred fifteen patients were included. The higher ratio was significantly associated with larger tumor diameter, pathological subtypes and choice of surgical type. There was a significantly worse DFS with a > 50% ratio. The subgroups of 0% and ≤ 50% ratio showed close survival curves of DFS. Similar trends were observed in OS. Multivariate analyses revealed that the ratio was a significant predictor for DFS, but not for OS. No significant prognostic difference was observed between lobectomy and limited resections.

Conclusion: A higher solid component ratio may help to predict a significantly worse prognosis of GGO IA lung adenocarcinoma.

Keywords: Lung adenocarcinoma, Solid component ratio, Ground glass opacity, Prognosis

Synopsis

The higher ratio of solid component was significantly associated with clinicopathological features of GGO patients with IA stage disease, such as tumor diameter and pathological subtype. A higher solid component ratio may help to predict a significantly worse prognosis of GGO IA lung adenocarcinoma.

Introduction

Lung adenocarcinoma is the most common histological subtype of non-small cell lung cancer with high morbidity and mortality worldwide, which also presents an increasing incidence rate [1]. Early stage lung adenocarcinoma is often detected as showing ground glass opacity (GGO) in thoracic thin-slice computed tomography (CT).

In 2011, the International Association for the Study of Lung Cancer, American Thoracic Society, and European Respiratory Society proposed a new multidisciplinary classification system for lung adenocarcinoma, which were mainly composed of adenocarcinoma in situ,

* Correspondence: wang.qun@zs-hospital.sh.cn

[†]Fenghao Sun and Yiwei Huang contributed equally to this work.
Department of Thoracic Surgery, Zhongshan Hospital, Fudan University, No. 180, Fenglin Road, Shanghai 200032, China



© The Author(s). 2020 **Open Access** This article is licensed under a Creative Commons Attribution 4.0 International License, which permits use, sharing, adaptation, distribution and reproduction in any medium or format, as long as you give appropriate credit to the original author(s) and the source, provide a link to the Creative Commons licence, and indicate if changes were made. The images or other third party material in this article are included in the article's Creative Commons licence, unless indicated otherwise in a credit line to the material. If material is not included in the article's Creative Commons licence and your intended use is not permitted by statutory regulation or exceeds the permitted use, you will need to obtain permission directly from the copyright holder. To view a copy of this licence, visit <http://creativecommons.org/licenses/by/4.0/>. The Creative Commons Public Domain Dedication waiver (<http://creativecommons.org/publicdomain/zero/1.0/>) applies to the data made available in this article, unless otherwise stated in a credit line to the data.

minimally invasive, and invasive adenocarcinoma [2]. The histology subtype and tumor invasion status under the new classification system have significant prognostic impact in lung adenocarcinoma [3–5]. The possible relationships between the radiological features of GGO and clinicopathological features in lung adenocarcinoma have drawn much attention. Our previous work indicated that the CT characteristics of GGO were significantly correlated with histological subtype and gene mutation rate in lung adenocarcinoma [6]. With respect to prognosis, studies also showed that solid components were a negative factor in lung adenocarcinoma [7]. However, Hattori et al. found that solid component size and its corresponding ratio were not prognostic predictors in part-solid clinical N0M0 lung cancer [8]. Therefore, further studies are required to investigate the potential role of the solid components in different subgroups regarding stage and invasion status in GGO-featured lung adenocarcinoma.

In this study, we selected patients with stage IA (The 8th TNM stage of lung cancer) invasive lung adenocarcinoma with GGO imaging features as the study cohort. Patients' records were reviewed in our institution and analyzed. We explored the clinical and prognostic values of the solid component ratio in early lung invasive adenocarcinoma and provided additional evidence for clinical practice regarding this issue.

Methods

Study cohort

This study was approved by the Ethics Committee of Zhongshan Hospital, Fudan University. We retrospectively reviewed records of all GGO patients who received curative surgical resection in our department from April 2012 to December 2015. The selection criteria were described as follows: (1) final pathological report confirmed the diagnosis of invasive lung adenocarcinoma; (2) pathological stages showed IA disease; and (3) R0 resections were achieved. Patients with missing radiological or clinicopathological data were excluded from this study.

Pathological information was acquired from the surgical pathology reports as previously stated [6]. The predominant pattern constituting the largest percentage of pathological findings were defined as the histological subtype. Tumor size was defined as the largest dimension in any plane of the tumor. According to previous reports, the lung adenocarcinoma subgroups were classified into three groups: lepidic predominant type (low - grade), acinar/papillary predominant type (intermediate - grade) and micropapillary/solid predominant type (high - grade) [3, 9–11].

CT scans were reviewed by one radiologist and one thoracic surgeon. Disagreements were solved by

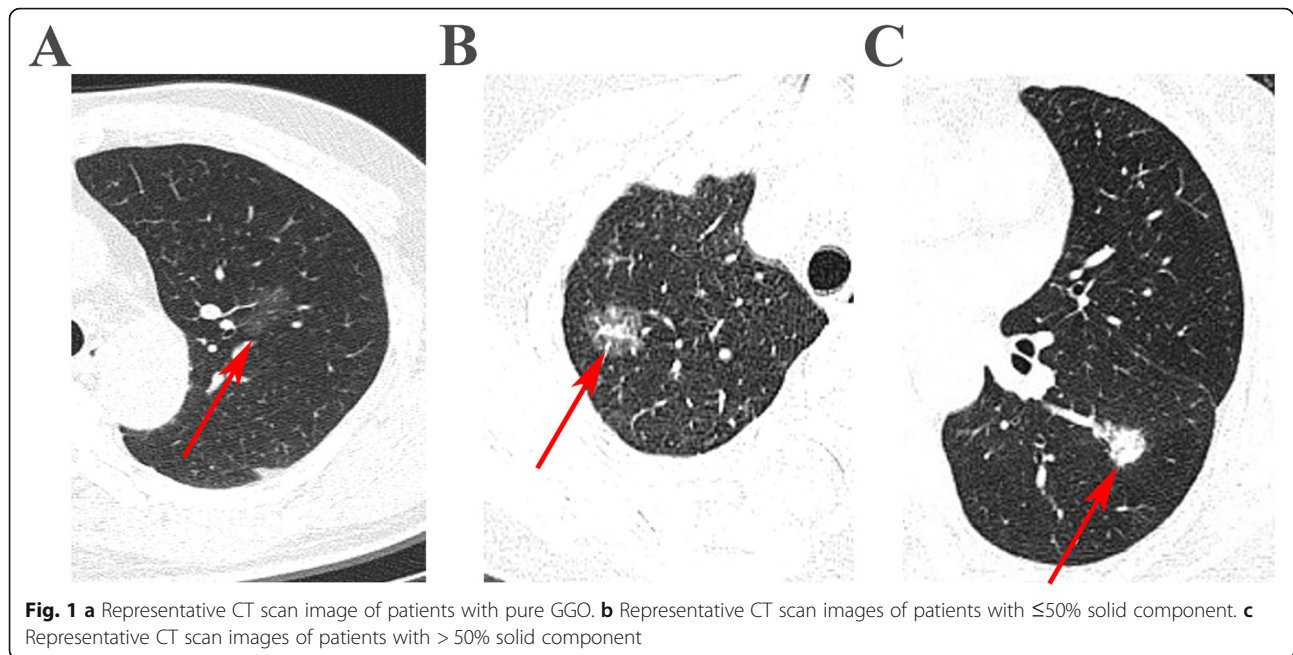
consensus. The proportion of the solid component was measured from thin-slice CT images (1 mm per slice). CT images were checked on both the mediastinal window (C-40 W400) and lung window (C-600 W1000) settings. The consolidation component was defined as an area of increased opacification, which completely obscured the underlying vascular structures. The solid component ratio was calculated by dividing the maximum consolidation diameter by the maximum tumor dimension including the GGO part in the lung window. To reduce the potential bias in estimating the ratio (percent), we also divided its value into three groups (0%, ≤ 50%, and > 50%). Representative CT scan images of the three classes of cohorts were showed in Fig. 1. To verify the cut-off of the solid component ratio for optimal sensitivity and specificity, we performed ROC analysis and identified that 50% as a cut-off value to group patients has good specificity and sensitivity (Supplementary Figure 1). Based on the solid component ratio, tumors were also classified as pure and mixed GGO subgroups (ratio = 0% or > 0% respectively).

Statistical analyses

All statistical analyses in this study were performed using R version 3.5.0 (R Foundation for Statistical Computing, Vienna, Austria) and IBM SPSS, version 22.0 (IBM, Inc., Armonk, NY, USA). Baseline characteristics stratified by the solid component ratio were compared using Pearson's χ^2 tests. Overall survival (OS) was defined as the interval from the time of surgery to any death or the last follow-up. Disease-free survival (DFS) was defined as the interval from the date of surgery to the time of the first recurrence or death from any cause or the last follow-up. Survival was calculated by the Kaplan - Meier method, and any survival differences were assessed by using a log-rank test. Univariate and multivariate Cox proportional hazard models were adopted to evaluate the prognostic values of the solid component ratio with respect to both DFS and OS. Differences were considered to be statistically significant if $P < 0.05$.

Results

A total of 415 patients were included in the study cohort. Baseline clinicopathological information of the study cohort is shown in Table 1. The differences of patients' clinical factors are also compared and stratified by the subgroup of solid component ratios. As shown in Table 1, the diameters of the resected tumors were significantly larger with the increasing of the solid component ratios ($P < 0.001$). The lung adenocarcinoma subtype was also significantly associated with the solid component ratio ($P < 0.001$).

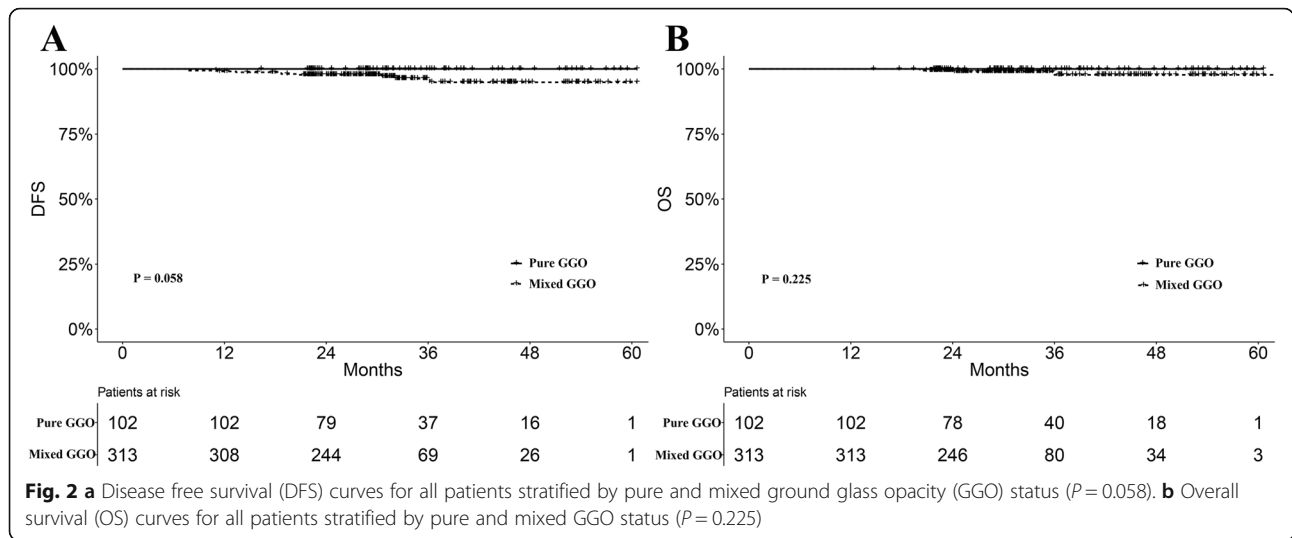


The median follow-up time in the entire cohort was 30.8 months. We compared the prognostic difference between pure and mixed GGO subgroups. The mixed GGO subgroup was associated with worse prognosis regarding DFS and OS, although the differences did not achieve statistical significance ($P = 0.058$ and 0.225 , Fig. 2a-b). Furthermore, there was a significantly worse DFS in the subgroup with $> 50\%$ solid component ratio ($P = 0.002$, Figure 3a). The subgroups with 0% and $\leq 50\%$ solid component ratios showed very close survival curves

of DFS (Fig. 3a). Nine patients with $> 50\%$ solid component ratios had relapse or metastases, while one patient with metastasis was observed in the $\leq 50\%$ ratio group. There was no relapse or metastasis found in the pure GGO group. Moreover, similar trends were also observed in the comparison regarding OS ($P = 0.245$, Fig. 3b). Patients with $> 50\%$ solid component ratios were associated with worse OS compared with those with $\leq 50\%$ ratios. There were five deaths in the $> 50\%$ ratio group and one death in the $\leq 50\%$ ratio group. No death was

Table 1 Baseline clinicopathological characteristics of ground glass opacity (GGO)-featured patients with IA stage invasive lung adenocarcinoma stratified by the solid component ratio

Variables	All	Ratio = 0	Ratio $\leq 50\%$	Ratio $> 50\%$	P value
Age	58.34 \pm 10.18	56.38 \pm 10.69	58.26 \pm 10.54	59.76 \pm 9.21	0.060
Sex					0.058
Female	260 (62.7)	74 (72.5)	96 (58.9)	90 (60)	
Male	155 (37.3)	28 (27.5)	67 (41.1)	60 (40)	
Tumor diameter	1.58 \pm 0.66	1.24 \pm 0.54	1.57 \pm 0.58	1.81 \pm 0.70	< 0.001
Smoking status					0.250
No/unknown	368 (88.7)	95 (93.1)	143 (87.7)	130 (86.7)	
Yes	47 (11.3)	7 (6.9)	20 (12.3)	20 (13.3)	
Surgical type					< 0.001
Lobectomy	323 (77.8)	69 (67.6)	122(74.8)	132 (88)	
Limited	92 (22.2)	33 (32.4)	41 (25.2)	18 (12)	
Histology subtype					< 0.001
Lepidic	64 (15.4)	28 (27.5)	30 (18.4)	6 (4.0)	
Acinar/papillary	344 (82.9)	74 (72.5)	132 (81)	138 (92.0)	
Mircopapillary/solid	7 (1.7)	0 (0.0)	1 (0.6)	6 (4.0)	



observed in patients in the pure GGO group. Cox regression analyses revealed that the solid component ratio was a significant predictor for DFS ($P = 0.017$, Table 2), but not for OS ($P = 0.171$, Table 3).

We also compared the surgical type stratified by the solid component ratio. There was a significantly larger proportion of lobectomy adopted in the $>50\%$ ratio group ($P < 0.001$, Table 1). Survival analyses showed that no significant difference was observed between survival curves of lobectomy and limited resections regarding DFS and OS in patients with 0% or $\leq 50\%$ solid component ($P = 0.537$ and 0.530 , Fig. 4a-b). There was also no significantly different prognosis regarding surgical types in patients with $>50\%$ solid components ($P = 0.341$ and 0.271 , Fig. 4c-d).

Discussion

Lung cancer remains a leading cause of cancer deaths all worldwide. Lung adenocarcinoma accounts for the major histological type and GGO is one of its important radiological features. It was reported that the solid component of GGO may represent alveolar collapse and intra-tumor fibrosis [12]. In previous studies, lung adenocarcinoma displayed as GGO features was reported to present a favorable prognosis [13, 14]. Berry et al. found that a small GGO component has significantly better survival than pure solid tumors in resected cN0 lung adenocarcinoma [15]. Part-solid lung adenocarcinoma was also proposed as one special subtype with different clinicopathological features [16]. However, Hattori et al. observed that the solid component ratio and

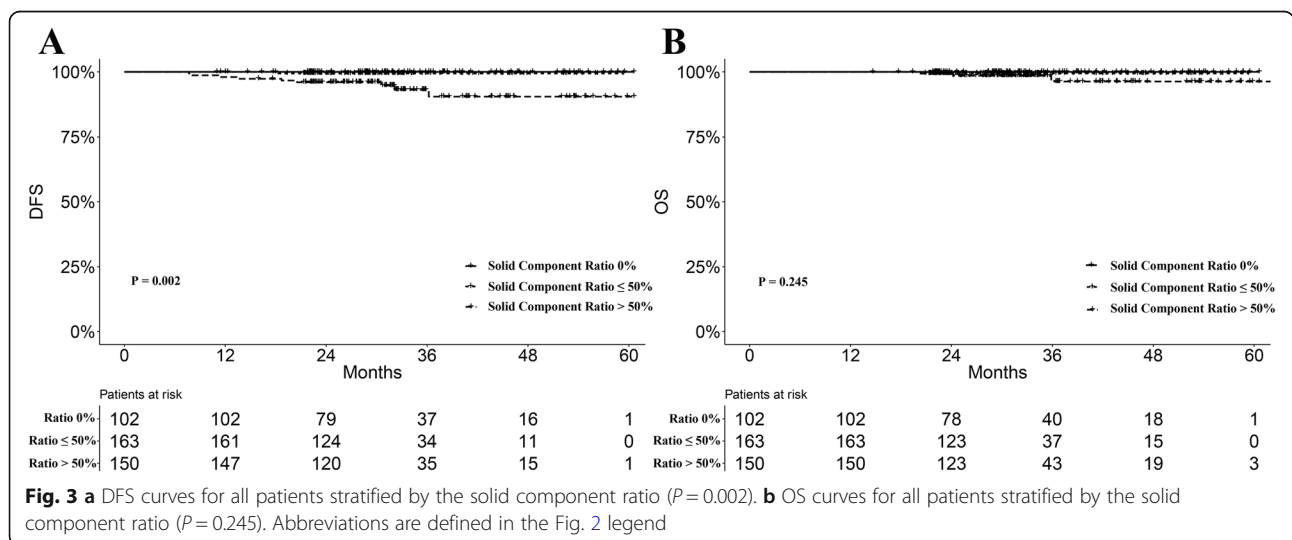


Table 2 Univariate and multivariate Cox regression analyses of disease free survival for patients with GGO-featured IA stage lung adenocarcinoma. Abbreviations are defined in the Table 1 legend

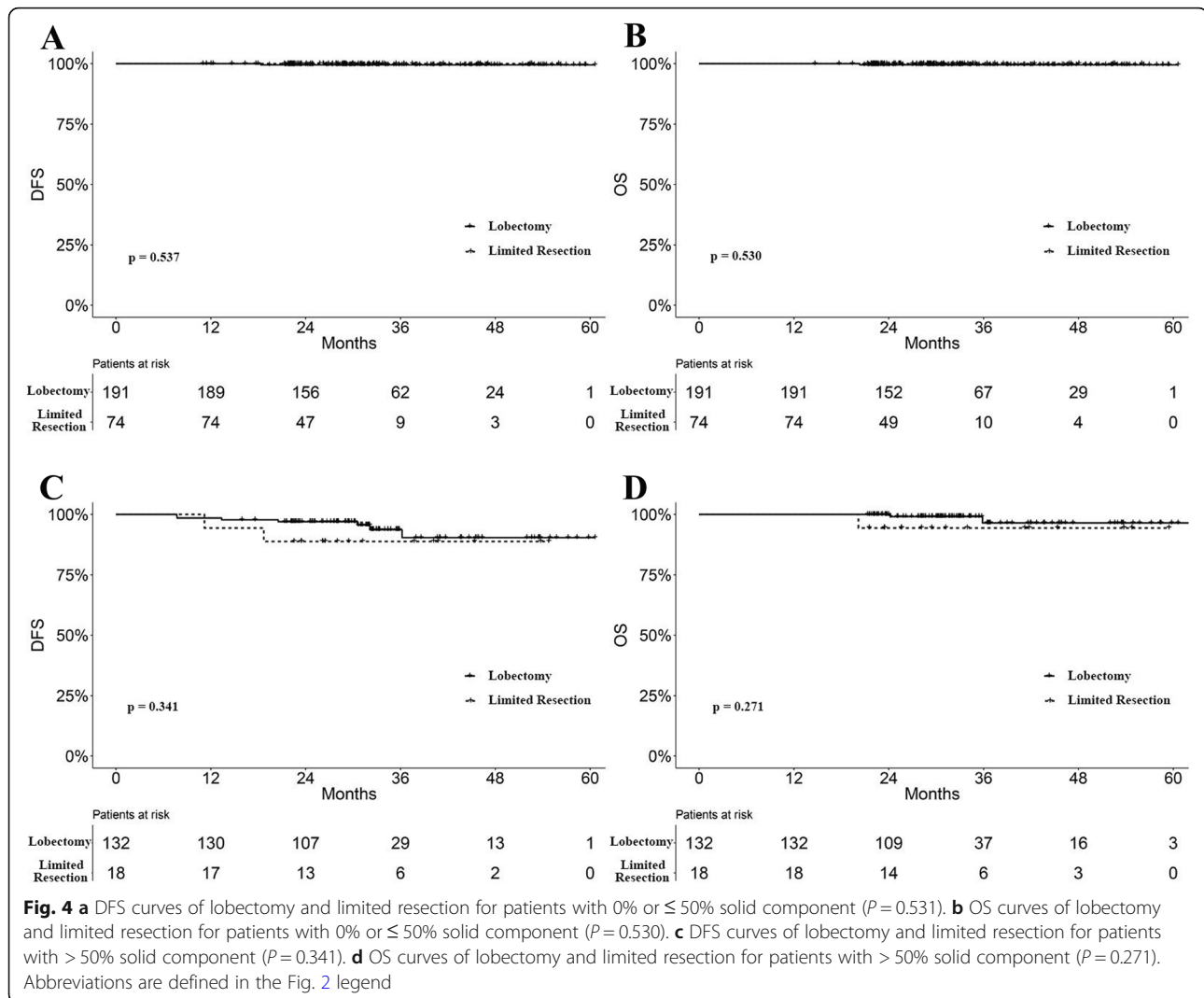
Variable	HR	95% CI	P value	HR	95% CI	P value
Age	1.030	0.966–1.099	0.366			
Sex			0.796			
Female	Reference					
Male	1.181	0.333–4.189				
Tumor diameter	0.854	0.352–2.371	0.914			
Smoking status			0.355			
No/unknown	Reference					
Yes	2.077	0.441–9.786				
Surgical type			0.985			
Lobectomy	Reference					
Limited	1.015	0.214–4.807				
Histology subtype			0.894			
Lepidic	Reference					
Acinar/papillary	1.646	0.209–12.996				
Mircopapillary/solid	< 0.001	–				
Solid component ratio			0.017			0.017
0	Reference			Reference		
≤ 50%	> 100	0.001- > 100		> 100	0.001- > 100	
> 50%	> 100	0.001- > 100		> 100	0.001- > 100	

Table 3 Univariate Cox regression analyses of overall survival for patients with GGO-featured IA stage lung adenocarcinoma. Abbreviations are defined in the Table 1 legend

Variable	HR	95% CI	P value
Age	1.146	1.009–1.301	0.036
Sex			0.586
Female	Reference		
Male	1.724	0.243–12.244	
Tumor diameter	0.476	0.090–2.528	0.384
Smoking status			0.383
No/unknown	Reference		
Yes	2.737	0.284–26.333	
Surgical type			0.776
Lobectomy	Reference		
Limited	1.391	0.143–13.542	
Histology subtype			0.888
Lepidic	Reference		
Acinar/papillary	0.570	0.059–5.478	
Mircopapillary/solid	< 0.001	–	
Solid component ratio			0.171
0	Reference		
≤ 50%	> 100	< 0.001- > 100	
> 50%	> 100	< 0.001- > 100	

tumor maximum diameter could not predict the OS in radiological part-solid lung cancer [8]. Therefore, the prognostic model of GGO-featured lung adenocarcinoma in different subgroups, such as stage and histology, has not been well established. In our study, we selected GGO-featured patients diagnosed with IA stage invasive lung adenocarcinoma as the study cohort. We reviewed their medical records and evaluated the roles of the solid component ratio. The solid component ratio was significantly associated with clinical factors, like tumor diameter, histological subtype, and choice of surgical resection. Pure GGO tumors showed a trend of better DFS and OS compared with part-solid tumors. Subgroup analyses showed that patients with > 50% solid component ratios had significantly worse DFS. Compared with the group of patients with lower solid components (≤50%), the higher ratio group (> 50%) had a trend of worse DFS, although the difference was not statistically significant.

Huang et al. found that a GGO ratio ≥ 0.75 provided a favorable prognostic prediction in resected lung adenocarcinoma [17]. A cut-off value of 50% solid component ratio was also proposed to predict recurrence of clinical IA stage tumor [18]. In this study, we divided the entire cohort into three subgroups (0%, ≤ 50% and > 50% solid component ratio) to reduce potential bias in estimating the values. We observed that the subgroups of 0% and ≤



50% solid component ratios shared very similar DFS and OS values. The cut-off value we adopted was only estimated. More advanced calculating tools and statistical algorithm are needed to determine the optimal cut-off value of the solid component ratio.

Lobectomy was recommended as the standard surgical approach for early-stage non-small cell lung cancer [19]. Recently, sublobar resection has been advocated for selected patients [20, 21]. The subgroup are defined by: peripheral nodules sized ≤ 2 cm with adenocarcinoma in situ and minimally invasive adenocarcinoma, or $\geq 50\%$ ground-glass appearance on CT, or doubling time (≥ 400 days) by radiological surveillance. However, sublobar resection is also a practical choice for patients with advanced age or poor pulmonary function, regardless of the solid component ratio. In GGO-predominant adenocarcinoma Tsutani Y et al. demonstrated that segmentectomy and wedge resection could provide comparable 3-year recurrence-free survival compared with

lobectomy [22]. Su H et al. also found that no difference between lobectomy and limited resection was revealed in the GGO-predominant IA stage adenocarcinoma group [18]. Similar results could also be found in previous studies [23, 24]. However, Ye T et al. indicated that wedge resection may be inadequate for invasive lung adenocarcinoma ≤ 2 cm, with GGO features [14]. In this study, we found that there was no significantly prognostic difference of lobectomy and limited resections stratified by the solid component value of 50%. Further prospective studies with a larger population are needed to explore the optimal surgical choice.

There are also some limitations in our study. First, this was a single-institution retrospective study. Prospective or multi-institutional studies cohorts may be further needed. A larger study cohort may help to identify the prognostic value of solid component ratios in a more detailed subgroup analysis. Moreover, the median follow-up time was 30.8 months in the study cohort. Survival

analysis with longer follow-up time could better characterize the prognostic feature of GGO tumors, especially for IA stage disease. However, our study indicated that the solid component ratio was of particular importance in predicting recurrence and survival in the short term after surgery, which may help to improve individualized follow-up plans. Selection bias may also exist due to the exclusion of patients with missing radiological or clinicopathological data in.

Conclusion

A higher ratio of solid component may help to predict significantly worse prognoses in GGO-featured patients with IA stage lung adenocarcinoma.

Supplementary Information

The online version contains supplementary material available at <https://doi.org/10.1186/s40644-020-00363-6>.

Additional file 1: Supplementary Figure 1. ROC analysis to determine cut-off of the solid component ratio for optimal sensitivity and specificity.

Abbreviations

CT: Computed tomography; GGO: Ground glass opacity; OS: Overall survival; DFS: Disease-free survival

Acknowledgements

We would like to thank International Science Editing Co. for the language editing service.

Authors' contributions

Fenghao Sun: data collection, data analysis, drafting and reviewing, final approval. Yiwei Huang: data collection, drafting and reviewing, final approval. Xiaodong Yang: data collection, drafting and reviewing. Junjie Xi and Zongwu Lin: drafting and reviewing. Yu Shi and Wei Jiang: drafting and reviewing. Cheng Zhan: drafting and reviewing, final approval, supervision. Qun Wang: study design, data analysis, drafting and reviewing, final approval, supervision. The authors read and approved the final manuscript.

Funding

This work was supported by the Excellent Talents Program of Zhongshan Hospital, Fudan University (2019ZSYXGG06) and the Youth Foundation of Zhongshan Hospital, Fudan University (2018ZSQN34).

Availability of data and materials

The datasets analysed during the current study available from the corresponding author on reasonable request.

Ethics approval and consent to participate

All procedures performed in studies involving human participants were in accordance with the ethical standards of the institutional and/or national research committee and with the 1964 Helsinki declaration and its later amendments or comparable ethical standards. Informed consent was obtained from all individual participants included in the study.

Consent for publication

Not applicable.

Competing interests

The authors declare that they have no competing interests.

Received: 24 November 2019 Accepted: 26 November 2020

Published online: 12 December 2020

References

- Zhang L, Li M, Wu N, Chen Y. Time Trends in Epidemiologic Characteristics and Imaging Features of Lung Adenocarcinoma: A Population Study of 21,113 Cases in China. *PLoS One*. 2015;10(8):e136727 2015-01-20.
- Travis WD, Brambilla E, Noguchi M, et al. International association for the study of lung cancer/american thoracic society/european respiratory society international multidisciplinary classification of lung adenocarcinoma. *J Thorac Oncol*. 2011;6(2):244–85 2011-02-01.
- Russell PA, Wainer Z, Wright GM, Daniels M, Conron M, Williams RA. Does lung adenocarcinoma subtype predict patient survival?: A clinicopathologic study based on the new International Association for the Study of Lung Cancer/American Thoracic Society/European Respiratory Society international multidisciplinary lung adenocarcinoma classification. *J Thorac Oncol*. 2011;6(9):1496–504 2011-09-01.
- Murakami S, Ito H, Tsubokawa N, et al. Prognostic value of the new IASLC/ATS/ERS classification of clinical stage IA lung adenocarcinoma. *Lung Cancer*. 2015;90(2):199–204 2015-11-01.
- Takahashi M, Shigematsu Y, Ohta M, Tokumasa H, Matsukura T, Hirai T. Tumor invasiveness as defined by the newly proposed IASLC/ATS/ERS classification has prognostic significance for pathologic stage IA lung adenocarcinoma and can be predicted by radiologic parameters. *J Thorac Cardiovasc Surg*. 2014;147(1):54–9 2014-01-01.
- Sun F, Xi J, Zhan C, et al. Ground glass opacities: Imaging, pathology, and gene mutations. *J Thorac Cardiovasc Surg*. 2018;156(2):808–13 2018-08-01.
- Li J, You W, Zheng D, et al. A comprehensive evaluation of clinicopathologic characteristics, molecular features and prognosis in lung adenocarcinoma with solid component. *J Cancer Res Clin Oncol*. 2018; 144(4):725–34 2018-04-01.
- Hattori A, Matsunaga T, Takamochi K, Oh S, Suzuki K. Neither Maximum Tumor Size nor Solid Component Size Is Prognostic in Part-Solid Lung Cancer: Impact of Tumor Size Should Be Applied Exclusively to Solid Lung Cancer. *Ann Thorac Surg*. 2016;102(2):407–15 2016-08-01.
- Lee HY, Cha MJ, Lee KS, et al. Prognosis in Resected Invasive Mucinous Adenocarcinomas of the Lung: Related Factors and Comparison with Resected Nonmucinous Adenocarcinomas. *J Thorac Oncol*. 2016;11(7):1064–73 2016-07-01.
- Travis WD, Brambilla E, Riely GJ. New pathologic classification of lung cancer: relevance for clinical practice and clinical trials. *J Clin Oncol*. 2013; 31(8):992–1001 2013-03-10.
- Warth A, Muley T, Meister M, et al. The novel histologic International Association for the Study of Lung Cancer/American Thoracic Society/European Respiratory Society classification system of lung adenocarcinoma is a stage-independent predictor of survival. *J Clin Oncol*. 2012;30(13):1438–46 2012-05-01.
- Maeshima AM, Niki T, Maeshima A, Yamada T, Kondo H, Matsuno Y. Modified scar grade: a prognostic indicator in small peripheral lung adenocarcinoma. *Cancer Am Cancer Soc*. 2002;95(12):2546–54 2002-12-15.
- Sawada S, Yamashita N, Sugimoto R, Ueno T, Yamashita M. Long-term Outcomes of Patients With Ground-Glass Opacities Detected Using CT Scanning. *Chest*. 2017;151(2):308–15 2017-02-01.
- Ye T, Deng L, Xiang J, et al. Predictors of Pathologic Tumor Invasion and Prognosis for Ground Glass Opacity Featured Lung Adenocarcinoma. *Ann Thorac Surg*. 2018;106(6):1682–90 2018-12-01.
- Berry MF, Gao R, Kunder CA, et al. Presence of Even a Small Ground-Glass Component in Lung Adenocarcinoma Predicts Better Survival. *Clin Lung Cancer*. 2018;19(1):e47–51 2018-01-01.
- Ye T. DLWS. Lung adenocarcinomas manifesting as radiological part-solid nodules define a special clinical subtype. *J Thorac Oncol*. 2019;14(4):617–27.
- Huang TW, Lin KH, Huang HK, et al. The role of the ground-glass opacity ratio in resected lung adenocarcinoma. *Eur J Cardiothorac Surg*. 2018;54(2): 229–34 2018-08-01.
- Su H, Dai C, Xie H, et al. Risk Factors of Recurrence in Patients With Clinical Stage IA Adenocarcinoma Presented as Ground-Glass Nodule. *Clin Lung Cancer*. 2018;19(5):e609–17 2018-09-01.
- Ginsberg RJ, Rubinstein LV. Randomized trial of lobectomy versus limited resection for T1 N0 non-small cell lung cancer. Lung Cancer Study Group. *Ann Thorac Surg*. 1995;60(3):615–22 622–3. 1995-09-01.

20. Altorki NK, Yip R, Hanaoka T, et al. Sublobar resection is equivalent to lobectomy for clinical stage 1A lung cancer in solid nodules. *J Thorac Cardiovasc Surg.* 2014;147(2):754–62 762–4. 2014-02-01.
21. Wisnivesky JP, Henschke CI, Swanson S, et al. Limited resection for the treatment of patients with stage IA lung cancer. *Ann Surg.* 2010;251(3):550–4 2010-03-01.
22. Tsutani Y, Miyata Y, Nakayama H, et al. Segmentectomy for clinical stage IA lung adenocarcinoma showing solid dominance on radiology. *Eur J Cardiothorac Surg.* 2014;46(4):637–42 2014-10-01.
23. Tsutani Y, Miyata Y, Nakayama H, et al. Appropriate sublobar resection choice for ground glass opacity-dominant clinical stage IA lung adenocarcinoma: wedge resection or segmentectomy. *Chest.* 2014;145(1):66–71 2014-01-01.
24. Moon Y, Sung SW, Moon SW, Park JK. Risk factors for recurrence after sublobar resection in patients with small (2 cm or less) non-small cell lung cancer presenting as a solid-predominant tumor on chest computed tomography. *J Thorac Dis.* 2016;8(8):2018–26 2016-08-01.

Publisher's Note

Springer Nature remains neutral with regard to jurisdictional claims in published maps and institutional affiliations.

Ready to submit your research? Choose BMC and benefit from:

- fast, convenient online submission
- thorough peer review by experienced researchers in your field
- rapid publication on acceptance
- support for research data, including large and complex data types
- gold Open Access which fosters wider collaboration and increased citations
- maximum visibility for your research: over 100M website views per year

At BMC, research is always in progress.

Learn more biomedcentral.com/submissions

