



Contents lists available at ScienceDirect

International Journal of Surgery Case Reports

journal homepage: www.casereports.com

A rare intramuscular osteolipoma: A case report

Jae Hwi Han^a, Sung Choi^{a,*}, Kyung-Rak Sohn^b, Seong Mun Hwang^a^a Department of Orthopedic Surgery, Daegu Fatima Hospital, Daegu, Republic of Korea^b Department of Pathology, Daegu Fatima Hospital, Daegu, Republic of Korea

ARTICLE INFO

Article history:

Received 23 October 2019

Received in revised form 14 January 2020

Accepted 20 January 2020

Available online 25 January 2020

Keywords:

Lower leg

Lipoma

Osteolipoma

Pathogenesis

Excisional biopsy

Case report

ABSTRACT

INTRODUCTION: Lipomas are frequently presented in adults and account for almost 50% of all soft-tissue tumors. Osteolipomas are rare and usually located in the intraosseous region or adjacent to bone. It is very unusual for osteolipomas with no connection to bony structures. We report a rare intramuscular osteolipoma independent of bone tissue.

PRESENTATION OF CASE: We report a case of a 58-year-old man with painful and progressively enlarging mass in the right lower leg. A plain X-ray and computed tomography (CT) scans revealed a large homogeneous, low-fat density mass containing an oval shape calcification without bone connection. MRI showed a circumscribed mass in the peroneus muscle with a large calcified component. The patient underwent surgical excision of the mass. Histologically, benign osteolipoma was the final diagnosis. No recurrence was observed at six months follow-up.

DISCUSSION: Lipoma is a common benign soft tissue neoplasm but osteolipoma is rare. Most cases osteolipomas are connected with bone. independent of bone tissue has been reported in very few cases. Most of them occurred in the head and neck area. The pathogenesis of osteolipoma is still not clear. Although CT and MRI are useful for differential diagnosis, care should be taken because sometimes they are indistinguishable from well-differentiated liposarcomas. Excisional biopsy is useful for definitive diagnosis.

CONCLUSION: Although ossifying lipomas are very rare, it is important to keep them in mind when a lesion with adipose tissue in combination with ossification is encountered.

© 2020 The Authors. Published by Elsevier Ltd on behalf of IJS Publishing Group Ltd. This is an open access article under the CC BY license (<http://creativecommons.org/licenses/by/4.0/>).

1. Introduction

Lipomas are frequently presented in adults and account for almost 50% of all soft-tissue tumors [1,2]. Variants of lipoma have been described according to the type of tissue present: fibrolipoma, myxolipoma, myolipoma, angioliipoma, pleomorphic lipoma, spindle-cell lipoma, angiomyolipoma [1,3,4]. In contrast lipomas with osseous or cartilaginous metaplasia are rare histological variants. Osteolipomas are less common than chondrolipomas and normally are presented in large and long term evolution lesions [3]. Osteolipomas are usually located in the intraosseous region or adjacent to bone tissue. It is very unusual for lipomas with no connection to bony structures to contain mature osseous components [1,5]. To the best of our knowledge, an intramuscular osteolipoma independent of bone tissue presented below the knee has not been previously reported in the literature. The work has been reported in line with the SCARE criteria [6].

2. Case presentation

A 58-year-old man presented to our hospital with a painful and progressively enlarging mass in the right lower leg. The patient noted a soft tissue mass in the anterolateral aspect of his lower leg seven years before. He had no family history, no medical history and had not any severe trauma or irradiation to the region. One month prior to presentation, his discomfort became obvious and he began experiencing pain and tenderness. The pain was dull-aching in nature and did not radiate to other regions.

On physical examination, a giant mass that was ovoid, firm, tender, well demarcated, and relatively fixed was palpated in the right peroneus muscle upper area and size was about 10 cm length and 2 cm width. The knee movements was normal. The neurological examination was within normal limits, and no lymphadenopathy was present. Laboratory data showed normal values including calcium, phosphorus, and alkaline phosphatase.

A plain X-ray and computed tomography (CT) scans revealed a large homogeneous, low-fat density mass containing an oval shape calcification from fibula neck to fibula shaft about 11 cm length and 2 cm width. Continuity between a tumor and fibula was not found. (Fig. 1). Magnetic resonance imaging (MRI) showed a cir-

* Corresponding author at: Department of Orthopedic Surgery, Daegu Fatima Hospital, 99 Ayang-ro, Dong-gu, Daegu 41199, Republic of Korea.
E-mail address: oschoisung@gmail.com (S. Choi).

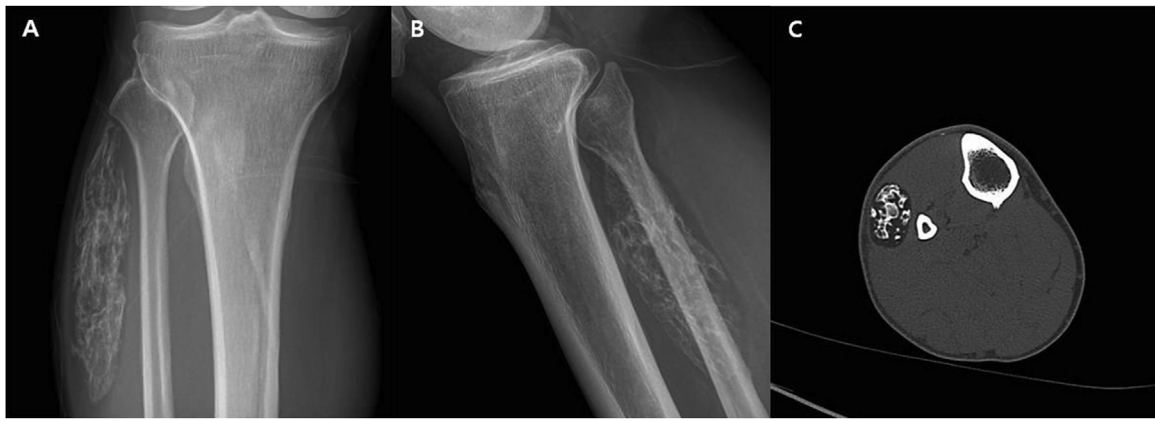

Fig. 1. Plain X-ray (A,B) and CT (C) scan showing an ossified soft tissue mass. The density of the mass was similar to the subcutaneous fat. Diffuse ossification is seen in the center. Continuity between a tumor and fibula was not found.

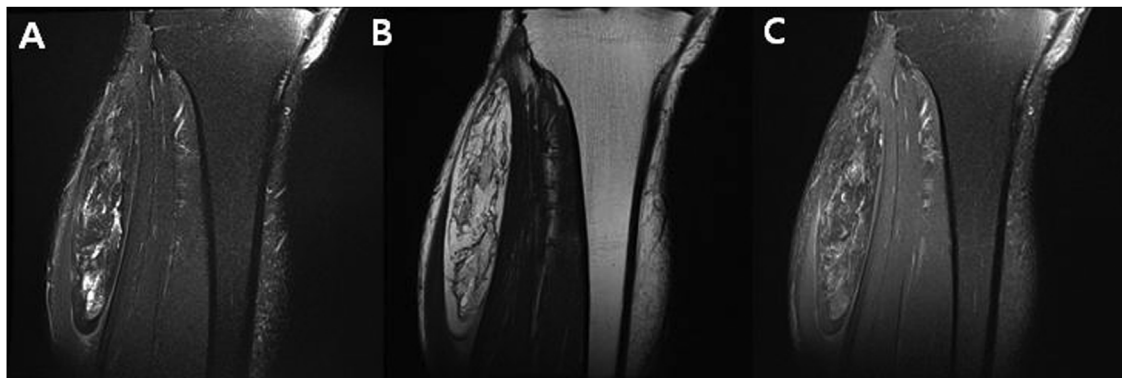


Fig. 2. MRI showing a well defined ossified mass in the peroneus muscle. Coronal T2-weighted Fat-suppression (A), Coronal T2-weighted (B), Coronal T1-weighted Fat-suppression contrast enhanced (C).

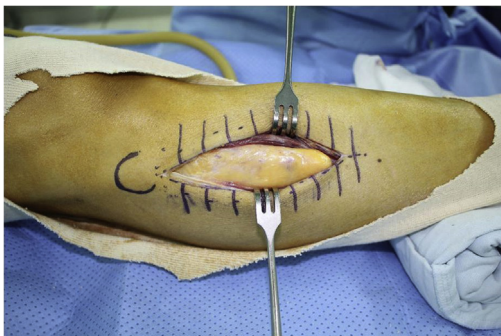

Fig. 3. There was no continuity between the mass and the adjacent bone.

cumscribed mass in the peroneus muscle with a large calcified component (Fig. 2).

An excisional biopsy was undertaken. During the operation, a well encapsulated tumor mass was found to be located in the peroneus muscle (Fig. 3). There was no continuity between the mass and the adjacent bone. The tumor mass was removed surgically, and the incision was closed without a drain. The wound healed well, and the patient returned to daily activity after 2 days without complications.

Grossly, the resected specimen is a well demarcated, diffusely yellowish adipose tissue mass measuring 11 × 3.5 × 2 cm and 43 g in weight. Outer surface is diffusely smooth because of a thin fibrous

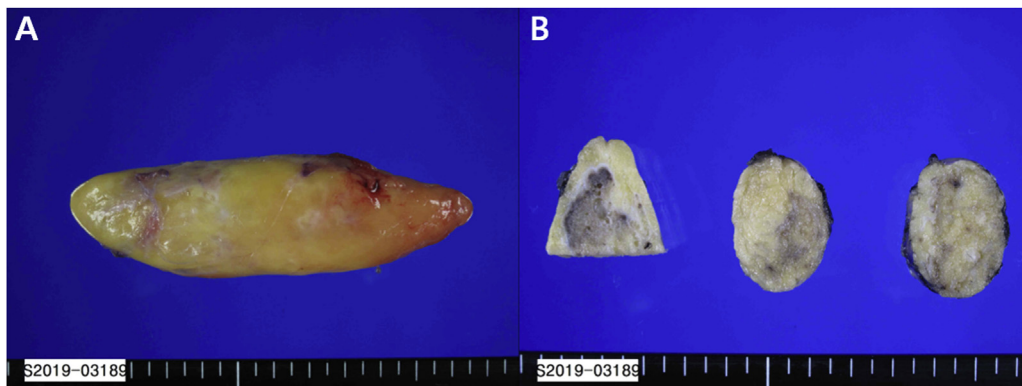


Fig. 4. Grossly (A) mass was a well demarcated, diffusely yellowish adipose tissue mass. On sectioning (B), the cut surface consists of deep yellowish fat admixed with multiple scattered calcified white or brown bone.

Table 1
Reported cases of osteolipoma.

Author	Location	Connection with bone	Management	Length of follow up	Recurrence
Kumar et al. [14]	Eyelid	No	Excisional biopsy	Not described	Not described
de Castro et al. [3]	Buccal mucosa	Not described	Excisional biopsy	Not described	No
Durmaz et al. [11]	Nasopharynx	Yes	Excisional biopsy	6 months	No
Adebiyi et al. [16]	palate	Not described	Excisional biopsy	Not described	Not described
Piattelli et al. [13]	Tongue	No	Excisional biopsy	4 years	No
Kameyama et al. [12]	Neck	No	Excisional biopsy	Not described	Not described
Yang et al. [15]	Posterior Neck	No	Excisional biopsy	6 months	No
Jaiswal et al. [18]	Lumbar	Yes	Excisional biopsy	3 weeks	Not described
Yabe et al. [10]	SC joint	No	Excisional biopsy	Not described	No
Obermann et al. [8]	Scapula	Yes	Excisional biopsy	Not described	Not described
Demiralp et al. [5]	Inguinal	No	Excisional biopsy	18 months	No
Electricwala et al. [19]	Femur	Yes	Excisional biopsy	8 months	No
Heffernan et al. [1]	Thigh	No	Wide excisional biopsy	Not described	Not described

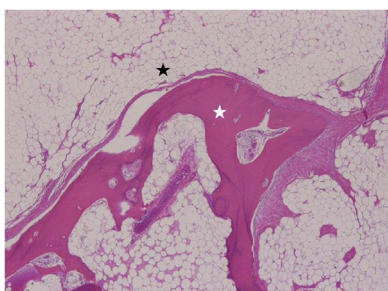


Fig. 5. Histopathology of the mass showing mature adipose tissue (black star) and mature trabecular bone (white star).

capsule. On sectioning, the cut surface consists of deep yellowish fat admixed with multiple scattered calcified white or brown bone (Fig. 4).

The microscopic analyses revealed osseous trabeculae inside a mature adipose tissue. No cellular atypia or increased of mitotic figures were observed. These findings led us histopathological diagnosis of benign osteolipoma (Fig. 5).

The definitive pathological diagnosis was intramuscular osteolipoma without evidence of malignancy. No recurrence was observed at six months follow-up.

3. Discussion

Lipoma is a common benign soft tissue neoplasm that sometimes may have mixed tissue components. Lipomas with mixed components are named according to the type of tissue. Ossification of a lipoma was first described in 1959, and it is rarely reported [7]. In a series of 635 lipomas seen over a 5-year period, only 6 cases with ossification were found [1]. A lipoma containing mature osseous elements is called osteolipoma. The terms ossifying lipoma, osseous lipoma, and lipoma with osseous metaplasia have been used interchangeably with osteolipoma [8]. Most cases of lipomatous lesions with osseous tissue connected with bone (inside a bone or adjacent to bone) [8–10]. They are intraosseous lipoma or parosteal lipoma. Osteolipoma independent of bone tissue has been reported in very few cases. Most of them occurred in the head and neck area [3,11–14]. There have been very few reports of ossifying lipomas arising either away from the head and neck or independently from bone [1,5] (Table 1). In the presented case, there was no connection between intramuscular osteolipoma and adjacent bone tissue.

The pathogenesis of osteolipoma is still not clear. Two main theories exist for the pathogenesis of osteolipomas [3,5]. First, These tumors appear to be of mesenchymal origin, which is derived from pluripotent cells then it may be called as benign mesenchymoma [3]. This pathology is defined as a rare soft tissue lesion composed

of fibrous tissue associated with two or more types of mesenchymal cells well differentiated, that would not normally be found in the same area [3]. According to the second theory, ossification may also have been induced by poor nutritional supply in the centre of a large lipoma after repetitive trauma, metabolic changes, or ischemia leading to transformation of fibroblasts into osteoblasts [5,15]. Our histological finding does not clarify which of the two hypotheses is true.

Congenital malformations of bones, benign tumors containing bony tissue (teratomas, dermoid), secondary ossification due to trauma, liposarcoma with metaplastic changes should be considered in the differential diagnosis. The use of CT scanning provides excellent visualization of the calcified or ossified components of a lipoma and confirmation of proximity to adjacent bone, and MR imaging can also provide detailed information that is useful for further evaluation [16,17]. However, on Magnetic Resonance Imaging, lipoma variants have unusual features on imaging studies. Intraleisional non-adipose components can confound the correct imaging diagnosis because they can mimic findings associated with well-differentiated liposarcomas [17]. Definitive diagnosis of the lesion can easily be done with histopathologic examination and treatment is by surgical excision [18]. Lipomas with osseous changes have the same prognosis as lipomas [8].

4. Conclusion

Although ossifying lipomas are very rare, it is important to keep them in mind when a lesion with adipose tissue in combination with ossification is encountered.

Sources of funding

No funding was requested.

Ethical approval

This is a case report study, no ethical approval was needed. On the other hand, the patient had been informed and gave their consent regarding this publication.

Consent

Written informed consent was obtained from the patient for publication of this case report.

Author contribution

JH Han performed the operation and perioperative management of the patient. JH Han also acquired and interpreted the data and drafted the manuscript. SM Hwang participated in the operation,

perioperative management of the patient. S Choi revision of the manuscript. KR Sohn reviewed pathological findings.

Registration of research studies

This manuscript is not a human study, but a case report.

Guarantor

Jae Hwi Han.

Provenance and peer review

Not commissioned, externally peer-reviewed.

Declaration of Competing Interest

No conflict of interest for all authors.

References

- [1] E.J. Heffernan, K. Lefaivre, P.L. Munk, T.O. Nielsen, B.A. Masri, Ossifying lipoma of the thigh, *Br. J. Radiol.* 81 (2008) 207–210, <http://dx.doi.org/10.1259/bjr/38805072>.
- [2] M.D. Murphy, J.F. Carroll, D.J. Flemming, T.L. Pope, F.H. Gannon, M.J. Kransdorf, From the archives of the AFIP: benign musculoskeletal lipomatous lesions, *RadioGraphics* 24 (2004) 1433–1466, <http://dx.doi.org/10.1148/rg.245045120>.
- [3] A.L. de Castro, E.V. de Castro, R.C. Felipini, A.C. Ribeiro, A.M. Soubhia, Osteolipoma of the buccal mucosa, *Med. Oral Patol. Oral Cir. Bucal* 15 (2010) 347–349, <http://dx.doi.org/10.4317/medoral.15.e347>.
- [4] B. Kutzer, Histopathology of rare chondroosteoblastic metaplasia in benign lipomas, *Pathol. Res. Pract.* 184 (1989) 437–445, [http://dx.doi.org/10.1016/S0344-0338\(89\)80040-8](http://dx.doi.org/10.1016/S0344-0338(89)80040-8).
- [5] B. Demiralp, J.F. Alderete, O. Kose, A. Ozcan, I. Cicek, M. Basbozkurt, Osteolipoma independent of bone tissue: a case report, *Cases J.* 2 (2009) 8711, <http://dx.doi.org/10.4076/1757-1626-2-8711>.
- [6] R.A. Agha, M.R. Borrelli, R. Farwana, K. Koshy, A. Fowler, D.P. Orgill, For the SCARE Group, The SCARE 2018 statement: updating consensus Surgical CAse REport (SCARE) guidelines, *Int. J. Surg.* 60 (2018) 132–136, <http://dx.doi.org/10.1016/j.ijsu.2018.10.028>.
- [7] G.S. Plaut, R. Salm, D.E. Truscott, Three cases of ossifying lipoma, *J. Pathol. Bacteriol.* 78 (1959) 292–295.
- [8] E.C. Obermann, S. Bele, A. Brawanski, R. Knuechel, F. Hofstaedter, Ossifying lipoma, *Virchows Arch.* 434 (1999) 181–183, <http://dx.doi.org/10.1007/s004280050324>.
- [9] T. Rau, S. Soeder, A. Olk, T. Aigner, Parosteal lipoma of the thigh with cartilaginous and osseous differentiation: an osteochondrolipoma, *Ann. Diagn. Pathol.* 10 (2006) 279–282, <http://dx.doi.org/10.1016/j.anndiagpath.2006.03.009>.
- [10] Y. Yabe, J. Kumagai, N. Koizumi, M. Kawamura, S. Ono, M. Hatori, Osteolipoma arising adjacent to the sternoclavicular joint. A case report, *Upsala J. Med. Sci.* 111 (2006) 257–261, <http://dx.doi.org/10.3109/2000-1967-049>.
- [11] A. Durmaz, F. Tosun, B. Kurt, M. Gerek, H. Birkent, Osteolipoma of the nasopharynx, *J. Craniofac. Surg.* 18 (2007) 1176–1179, <http://dx.doi.org/10.1097/scs.0b013e31814b2b61>.
- [12] K. Kameyama, Y. Akasaka, H. Miyazaki, J. Hata, Ossifying lipoma independent of bone tissue, *ORL J. Otorhinolaryngol. Relat. Spec.* 62 (2000) 170–172, <http://dx.doi.org/10.1159/000027741>.
- [13] A. Piattelli, M. Fioroni, G. Iezzi, C. Rubini, Osteolipoma of the tongue, *Oral Oncol.* 37 (2001) 468–470.
- [14] S. Kumar, S. Kumar, R. Kulshrestha, Osteolipoma of the eyelid, *Clin. Exp. Ophthalmol.* 36 (2008) 473–474, <http://dx.doi.org/10.1111/j.1442-9071.2008.01786.x>.
- [15] J.S. Yang, S.H. Kang, Y.J. Cho, H.J. Choi, Pure intramuscular osteolipoma, *J. Korean Neurosurg. Soc.* 54 (2013) 518–520, <http://dx.doi.org/10.3340/jkns.2013.54.6.518>.
- [16] K.E. Adebisi, V.I. Ugboko, S.M. Maaji, G. Ndubuizu, Osteolipoma of the palate: report of a case and review of the literature, *Niger. J. Clin. Pract.* 14 (2011) 242–244, <http://dx.doi.org/10.4103/1119-3077.84029>.
- [17] C.M. Gaskin, C.A. Helms, Lipomas, lipoma variants, and well-differentiated liposarcomas (atypical lipomas): results of MRI evaluations of 126 consecutive fatty masses, *AJR Am. J. Roentgenol.* 182 (2004) 733–739, <http://dx.doi.org/10.2214/ajr.182.3.1820733>.
- [18] A.K.1 Jaiswal, A. Garg, A.K. Mahapatra, Spinal ossifying lipoma, *J. Clin. Neurosci.* 12 (2005) 714–717, <http://dx.doi.org/10.1016/j.jocn.2004.08.031>.
- [19] A.J. Electricwala, Y. Panchwagh, J.T. Electricwala, Giant osteolipoma fixed to the greater trochanter of the femur in a seventy-year-old elderly woman, *Cureus* 9 (2017), e1036, <http://dx.doi.org/10.7759/cureus.1036>.

Open Access

This article is published Open Access at [sciencedirect.com](https://www.sciencedirect.com). It is distributed under the [IJSCR Supplemental terms and conditions](#), which permits unrestricted non commercial use, distribution, and reproduction in any medium, provided the original authors and source are credited.