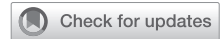

Totally endoscopic, robotic-assisted mitral valve repair after transcatheter aortic valve replacement



Andrea Amabile, MD,^a Michael LaLonde, MHA, PA-C,^a Soraya Fereydooni, BS,^a Cheryl K. Zogg, PhD, MSPH, MHS,^a Alyssa Morrison, BS,^a Christina Waldron, BS,^a Syed Usman Bin Mahmood, MBBS,^a Arnar Geirsson, MD,^a and Markus Krane, MD,^{a,b} New Haven, Conn, and Munich, Germany

^a Division of Cardiac Surgery, Department of Surgery, Yale School of Medicine, New Haven, Conn;^b Department of Cardiovascular Surgery, Institute Insure, German Heart Center Munich, Technical University of Munich, Munich, Germany

Read at the American Association for Thoracic Surgery Mitral Conclave 2023, New York, New York, May 4-5, 2023.

Received for publication June 16, 2023; revisions received Aug 20, 2023; accepted for publication Aug 31, 2023; available ahead of print Sept 18, 2023.

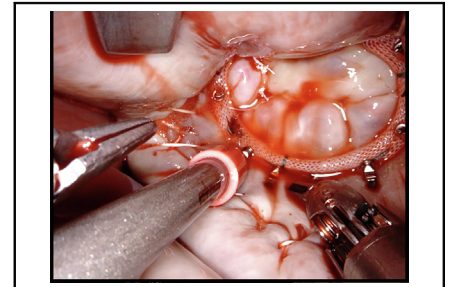
Address for reprints: Arnar Geirsson, MD and Markus Krane, MD, Division of Cardiac Surgery, Department of Surgery, Yale School of Medicine, 330 Cedar St, New Haven 06511, CT (E-mail: ag4877@cumc.columbia.edu or markus.krane@yale.edu)

JTCVS Techniques 2023;22:112-3

2666-2507

Copyright © 2023 The Author(s). Published by Elsevier Inc. on behalf of The American Association for Thoracic Surgery. This is an open access article under the CC BY-NC-ND license (<http://creativecommons.org/licenses/by-nc-nd/4.0/>).

<https://doi.org/10.1016/j.jtc.2023.08.027>



Intraoperative image after mitral valve repair.

CENTRAL MESSAGE

Totally endoscopic, robotic-assisted mitral valve repair in patients who had previously undergone transcatheter aortic valve replacement poses additional technical challenges.

▶ Video clip is available online.

Moderate-to-severe mitral regurgitation (MR) affects approximately 25% of patients with severe aortic stenosis undergoing transcatheter aortic valve replacement (TAVR).¹ Although MR may improve after TAVR in up to 50% due to left ventricular reverse remodeling,¹ persistent MR is associated with increased morbidity and hospitalization for heart failure.² The best modality for the treatment of severe MR after TAVR remains debated.

We present the case of an acutely decompensated, frail, 86-year-old patient with severe aortic stenosis and moderate-to-severe MR (due to anterolateral commissural prolapse) with multiple comorbidities (Figure 1), with symptomatic MR after TAVR with the Evolut R (Medtronic). The patient was denied conventional mitral surgery (due to high-risk status), transcatheter mitral valve

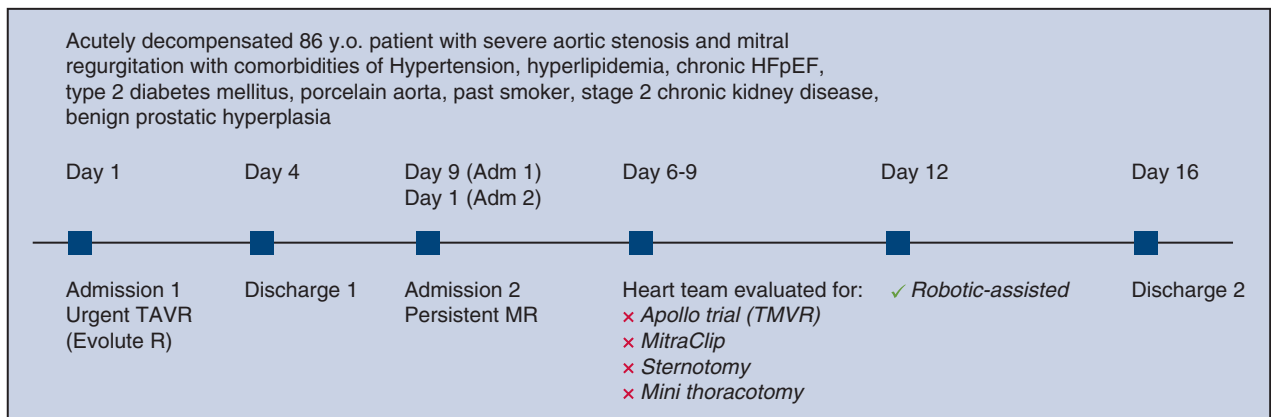
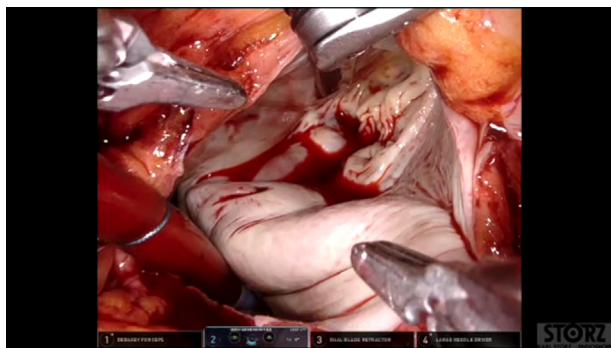


FIGURE 1. Case summary and timeline.



VIDEO 1. Narrated case video. Video available at: [https://www.jtcvs.org/article/S2666-2507\(23\)00308-5/fulltext](https://www.jtcvs.org/article/S2666-2507(23)00308-5/fulltext).

replacement (not meeting the inclusion criteria for the APOLLO trial), and MitraClip (Abbott) (due to location of the prolapse at the anterolateral commissure). We offered a totally endoscopic, robotic-assisted approach for mitral valve repair (Video 1), which was performed 12 days after TAVR (institutional review board No. 2000020356; October 19, 2021, Informed written consent for publication of study data was obtained). Ports were placed in our standard fashion,³ and cardiopulmonary bypass was achieved by percutaneous femoral cannulation.⁴ Aortic crossclamp and cardioplegia delivery were provided using the endoaortic balloon occlusion device (EABO), which was filled with indocyanine green⁵ and carefully placed in the ascending aorta. Of note, optimal and safe positioning of the EABO (well above the frame of the Evolut R aortic valve prosthesis and below the brachiocephalic trunk) was achieved by leveraging preoperative computed tomography angiography imaging (which allowed us to carefully evaluate the peripheral vascular as well as the ascending aortic anatomy of the patient), intraoperative transesophageal echocardiography imaging, bilateral upper extremities arterial pressure monitoring, and intraoperative visualization of the indocyanine green inside the EABO via the Firefly mode offered by the robotic platform. Additionally, multiple checks of the positioning of the EABO were carried out throughout the procedure. After entering the left atrium via the interatrial groove, we exposed the mitral valve while avoiding TAVR valve dislocation via careful maneuvering of the atrial retractor. The mitral valve had myxomatous degenerative changes, with flailed P1 (which explained the failed improvement after) and anterolateral commissural prolapse. We repaired the valve with commis-

sural plication and placement of a 30-mm Physioflex annuloplasty band (Edwards Lifesciences). Cardiopulmonary bypass time and aortic crossclamp time were 115 minutes and 77 minutes, respectively. At the end of the procedure, transesophageal echocardiography revealed trace MR with a mean gradient of 4 mm Hg, and a still properly positioned and well-functioning Evolut R prosthesis. The patient experienced a transient ischemic attack on postoperative day 2, but remained neurologically intact and asymptomatic thereafter.

In conclusion, using a totally endoscopic, robotic-assisted approach is safe and effective for the treatment of persistent severe MR after TAVR in selected patients.

Conflict of Interest Statement

Dr Amabile receives consulting fees from JOMDD/Sanamed. Mr LaLonde receives consulting fees from Edwards Lifesciences and Intuitive Surgical. Dr Krane is a physician proctor and a member of the medical advisory board for JOMDD/Sanamed, a physician proctor for Peter Duschek, is a medical consultant for EVOTEC and Moderna, and has received speakers' honoraria from Medtronic and Terumo. Dr Geirsson receives consulting fees for being a member of the Medtronic Strategic Surgical Advisory Board and from Edwards Lifesciences. All other authors reported no conflicts of interest.

The *Journal* policy requires editors and reviewers to disclose conflicts of interest and to decline handling manuscripts for which they may have a conflict of interest. The editors and reviewers of this article have no conflicts of interest.

References

1. Tirado-Conte G, McInerney A, Jimenez-Quevedo P, Carnero M, Marroquin Donday LA, De Agustin A, et al. Managing the patient undergoing transcatheter aortic valve replacement with ongoing mitral regurgitation. *Expert Rev Cardiovasc Ther.* 2021;19:711-23.
2. Abdelghani M, Abdel-Wahab M, Hemetsberger R, Landt M, Merten C, Toelg R, et al. Fate and long-term prognostic implications of mitral regurgitation in patients undergoing transcatheter aortic valve replacement. *Int J Cardiol.* 2019;288:39-43.
3. Amabile A, Morrison A, LaLonde M, Agarwal R, Mori M, Hameed I, et al. Two hundred robotic mitral valve repair procedures for degenerative mitral regurgitation: the Yale experience. *Ann Cardiothorac Surg.* 2022;11:525-32.
4. Amabile A, Hameed I, Shang M, LaLonde MR, Geirsson A, Krane M. Unilateral percutaneous cannulation and endoaortic balloon management in robotic-assisted cardiac surgery: the least invasive approach. *Multimed Man Cardiothorac Surg.* 2022;2022.
5. Yaffee DW, Loulmet DF, Fakiha AG, Grossi EA. Fluorescence-guided placement of an endoaortic balloon occlusion device for totally endoscopic robotic mitral valve repair. *J Thorac Cardiovasc Surg.* 2015;149:1456-8.