



CASE REPORT

Surgical Treatment for Severe Cervical Hyperlordosis and Thoracolumbar Kyphoscoliosis with Emery–Dreifuss Muscular Dystrophy: A Case Report and Literature Review

Ziyang Tang, PhD¹, Zongshan Hu, PhD², Xiaodong Qin, PhD² , Zezhang Zhu, MD^{1,2}, Zhen Liu, MD^{1,2} 

¹Division of Spine Surgery, Department of Orthopedic Surgery, Nanjing Drum Tower Hospital, The Clinical College of Nanjing Medical University and ²Division of Spine Surgery, Department of Orthopedic Surgery, Nanjing Drum Tower Hospital, The Affiliated Hospital of Nanjing University Medical School, Nanjing, China

Background: Emery–Dreifuss muscular dystrophy (EDMD) is an uncommon, gradually progressive X-linked myopathy, and it could result in rigid spinal deformity. Only a few case reports have described surgical treatment of cervical hyperlordosis and thoracolumbar kyphoscoliosis secondary to EDMD. We report a rare case of EDMD to present the surgical strategies of severe cervical hyperlordosis and thoracolumbar kyphoscoliosis.

Case presentation: The patient was a 22-year-old man with EDMD who had severe cervical hyperlordosis and thoracolumbar kyphoscoliosis. A posterior spinal fusion from T9–S2 was performed to correct the thoracolumbar kyphoscoliosis at the age of 21 years. Six months later, with an anterior C7–T1 closing wedge bone-disc-bone osteotomy and a posterior–anterior–posterior cervicothoracic fusion from C4–T4, the cervical deformity was corrected, thus achieving a horizontal gaze. During 1.5-year follow-up, no loss of correction was observed.

Conclusion: Cervical posterior–anterior–posterior closing-wedge osteotomy combined with long fusion at thoracolumbar spine can be a reliable surgical technique to correct severe spine deformity in EDMD. This two-stage revision surgical strategy can help restore a horizontal gaze on the basis of a balanced trunk. Cervical deformity in such patients should be corrected in the first stage considering its role as a “driver” of the global spine deformity.

Key words: 3-colour osteotomy; Cervical hyperlordosis; Emery–Dreifuss muscular dystrophy; Spinal fusion

Introduction

Emery–Dreifuss muscular dystrophy (EDMD) is an uncommon, gradually progressive X-linked myopathy.^{1,2} The estimated prevalence of EDMD is approximately near 1 per 100,000.^{2–4} EDMD may appear in early childhood and exhibit slow progression throughout the life. Many previous studies have reported several gene loci associated with EDMD, such as *EMD* gene, *LMNA* gene, *FHL1* gene, *SYNE1* gene and *TMEM43* gene. Deficiency or mutation of these gene loci can activate abnormal transcription, leading to impaired nuclear stability, and this defective nuclear mechanics have been implicated in the causation of EDMD.^{1,3}

The clinical features of EDMD have been described in previous studies. These include: (i) early contractures; (ii) humeral–peroneal weakness; and (iii) cardiac disease such as sinus bradycardia, ventricular tachyarrhythmias, and cardiomyopathy.^{1,2,4,5} Cardiac disease is the most common comorbidity in these patients, and may result in sudden cardiac death after the second decade of life. Contracture usually occurs in the first decade of life and become more evident and intractable in adolescence.⁶ Contractures of posterior cervical muscle leads to rigid cervical spine in a hyperextended position.^{5,6} This rare cervical hyperlordotic deformity is a feature of EDMD which impedes the

Address for correspondence Liu Zhen. Email: drluozhen@163.com

Received 19 April 2022; accepted 1 September 2022

horizontal gaze and normal gait of patients.^{1,5} Moreover, cervical deformity can cause severe dysphagia and/or dyspnea.

Although previous studies provided many effective surgical strategies for the correction of cervical deformity, most of them focused on cervical kyphosis and only two case reports have described cervical hyperlordosis in EDMD.^{5,7} In addition, in these two case reports, the cervical hyperlordosis was not associated with severe thoracolumbar kyphoscoliosis. Therefore, we describe a patient with EDMD who underwent first-stage posterior thoracolumbar fusion and second-stage posterior–anterior–posterior cervical bone-disc-bone osteotomy for correction of severe thoracolumbar kyphoscoliosis and cervical hyperlordosis.

Case Report

Written informed consent for publication of their clinical details and/or clinical images was obtained from the patient himself. A 22-year-old man presented with a history of Trendelenburg gait and frequent falling down while walking since the age of 3 years. At the age of 10 years, he was brought to a local hospital because of development of lumbar kyphosis and excessive neck lordosis which made him unable to maintain a horizontal gaze (Fig. 1). His anteroposterior and lateral radiographs before his initial operation showed 43° lumbar kyphosis and 86° cervical lordosis. His chin-brow vertical angle (CBVA) was 39° upward (Fig. 1) and he had restricted range of cervical motion⁸. The local surgeons performed posterior spinal fusion (PSF) from T12 to L4 and bilateral Achilles tendon release. After his initial surgery, his lumbar deformity was effectively corrected as his anteroposterior and lateral radiographs showed -5° lumbar kyphosis. His cervical lordosis remained at 74°, but the post-operative CBVA was 15° (Fig. 1).

However, 4 years later, his cervical hyperlordosis and thoracolumbar kyphoscoliosis relapsed and showed gradual progression. Twelve years after his initial operation, he visited our center with an abnormal gait, and he had to flex his body forward in order to try and see in the front. He had difficulty in walking and suffered from severe dysphagia and dyspnea because of oppression of the trachea and esophagus. Physical examination revealed thoracolumbar kyphoscoliosis, distal junctional kyphosis (DJK) and developing cervical lordosis. Radiographs findings were: Cobb angle 89°; cervical lordosis 106°; regional kyphosis (RK) 64°; CBVA 35° and sagittal vertical axis (SVA) 176 mm (Fig. 1). The severity of dysphagia was evaluated as severe using Bazaz–Yoo dysphagia score (frequent swallowing difficulties with almost every type of food). After physical examination, we used the American Spinal Injury Association (ASIA) impairment scale to evaluate the neurological deficit, and he was identified in grade C (motor function is preserved but with half of the key muscle strength being < grade 2).

For this revision surgery, we performed first-stage posterior thoracolumbar fusion and second-stage posterior–anterior–posterior cervical bone-disc-bone osteotomy for correction of severe thoracolumbar kyphoscoliosis and cervical hyperlordosis. After the first-stage posterior thoracolumbar

fusion from T9 to S2, his thoracolumbar deformity was effectively corrected (Cobb angle 56°; RK 12°; and SVA 52mm) (Fig. 2). There was a significant improvement in thoracolumbar kyphoscoliosis. However, because of thoracolumbar fusion, he lost the ability to flex his body forward for maintaining a horizontal gaze and his CBVA increased to 66° upward, which meant that he had a fixed upward gaze towards the ceiling. Meanwhile, there was aggravation of dysphagia and dyspnea and he could only consume a small quantity of liquid diet and could not breathe effectively without oxygen inhaler.

Therefore, 6 months later, he underwent posterior–anterior–posterior cervical osteotomy and cervical fusion from C4 to T4 for correction of cervical deformity (Fig. 3).

Surgical Technique

Posterior Thoracolumbar Fusion and Pelvic Fixation

The patient was placed in prone position on the Jackson table. Posterior midline incision was made and the paraspinal muscles were dissected subperiosteally from T9 to S2. The region from T12 to L4, which had been fused at initial surgery, was found covered by a mass of scar tissue. After sufficient release of soft tissue, original instrumentations were removed and new pedicle screws were inserted from T9 to S1. Then, using the Stealth Station Navigation System (Medtronic, Minneapolis, MN, USA), the second sacral alar-iliac (S2AI) screws were inserted. After accurate placement of all screws, L5 pedicle subtraction osteotomy (PSO) was performed for correction of lumbosacral kyphosis and restoration of global sagittal alignment.

Posterior–Anterior–Posterior Cervical Osteotomy

The patient was first positioned prone on the Jackson table for the posterior approach, a Mayfield head clamp was used to ensure stabilization and safety of his head. The paraspinal muscles were dissected subperiosteally from C4 to T4, which were severely fibrotic and tense. In order to close osteotomized gap sufficiently, thorough and extensive release of posterior soft tissue from C6 to T2 was performed, followed by Z-plasty and transverse division. Then, pedicle screws from C4 to T4 were inserted, and multi-level Smith–Peterson osteotomy (SPO) were performed for further release.

After confirming that the head was fixed steadily, the patient was placed in the supine position by rotating the Jackson table 180° transversely. An anterior transverse incision was made and then the vertebrae and discs from C5 to T2 were exposed. A C7–T1 closing wedge osteotomy was performed for a satisfactory correction of cervical hyperlordosis. The region ranging from the distal half of the C7 and proximal half of the T1 vertebral bodies was identified as the region of osteotomy. After removing the redundant bone block, the osteotomy line was closed successfully by raising the head carefully, as described by Kose *et al.* after completing the osteotomy.⁷ Then the cervical vertebrae were fixed with an 8-screw titanium plate and fused by interbody cages and autogenous bone (Fig. 3).

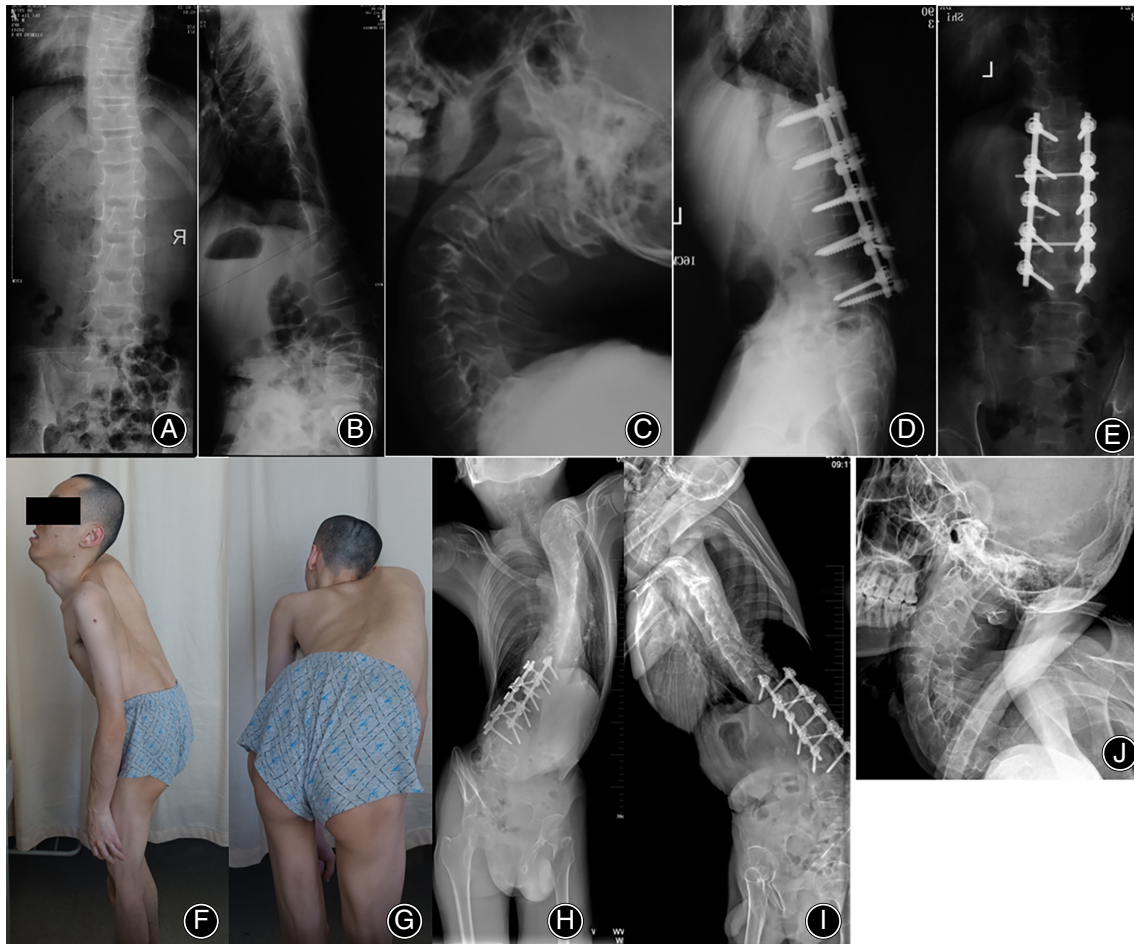


Fig. 1 Anteroposterior and lateral radiographs before the initial operation at age of 10 years showing 43° lumbar kyphosis and 86° cervical lordosis (A, B, C). X-ray radiographs obtained after his initial operation showing correction of the lumbar deformity. The anteroposterior and lateral radiographs showed -5° lumbar kyphosis. The cervical lordosis remained 74°, but his chin-brow vertical angle (CBVA) has become 15° (D, E). Twelve years after the initial operation, there was appearance of thoracolumbar scoliosis, DJK and developing cervical lordosis (F, G). The radiographs showed 89° of Cobb angle, 106° of cervical lordosis, 64° of RK, 35° upward of CBVA and 176 mm SVA (H, I, J).

After meticulously suturing the anterior incision, the patient was again placed in prone position by rotating the Jackson table 180° transversely. The cervical vertebrae were exposed posteriorly through the original incision and the C7 and C8 nerve roots were probed. The pedicle screws were connected by 5-mm titanium rods and the incision was seamed carefully (Fig. 3).

Clinical Outcome

After the cervical operation, his cervical lordosis became 57°, CBVA became 12° and he achieved a satisfactory horizontal gaze (Fig. 4). With the correction of cervical deformity, the patient's initial complaint, including dysphagia and dyspnea, were also relieved. Swallow function was improved significantly and the Bazaz-Yoo dysphagia score improved from "severe" score to "none" score. In addition, his score of the neurological

deficit was improved to grade D (motor function is preserved with half of the key muscle strength being > Grade 3).

At 1.5-year follow-up, the correction of cervical deformity, swallow function and neurological function maintained well, and the radiographs showed 46° of Cobb angle, 14° of RK, 46 mm of SVA, 58° of cervical lordosis and 15° of CBVA (Fig. 4).

Pathological and Genetic Diagnosis

The typical pathological feature of EDMD is a nonspecific myopathic change.⁹ Paraspinal muscle biopsy of this patient showed a nonspecific myopathic change. H & E stained sections of the biopsy specimens showed variation in fiber size, increased connective tissue, hypertrophic and atrophic muscle fibers, fiber splitting, several fibers with internal nuclei, abnormal mitochondrial proliferation and a few regenerating fibers (Fig. 4).

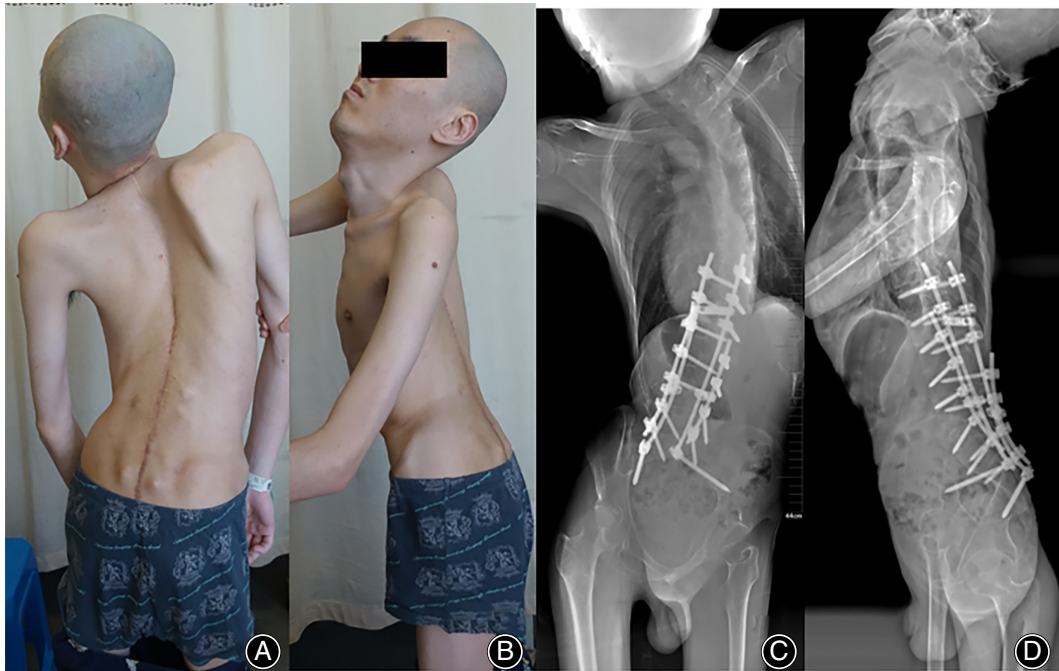


Fig. 2 After the revision of lumbosacral deformity, his thoracolumbar deformity was corrected effectively (A, B). His radiographs revealed 56° of Cobb angle, 12° of RK and 52 mm SVA. He lost the ability to flex his body forward to maintain a horizontal gaze and his CBVA became 66° upward that meant that he was just able to see the ceiling (C, D).

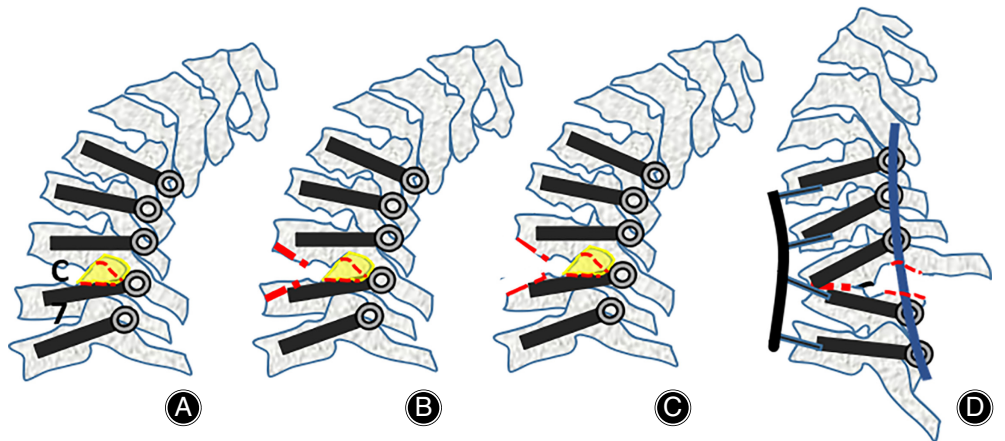


Fig. 3 Schematic illustration of the procedure for posterior-anterior-posterior cervical osteotomy.

Whole exome sequencing of this patient and his family showed mutation in that *LMNA* gene located at 1q11-q23. Further sequencing detection confirmed that the mutation occurred at the *LMNA*; NM_170707.3: C. 1357C > T (p.arg453trp), which was judged to be a pathogenic heterozygous mutation.⁹

Discussion

EDMD is an uncommon X-linked muscle disease which typically occurs in childhood.^{2,9} The reported features of EDMD include early contractures, gradually progressive

muscle weakness and cardiac disease.^{1,2} Most of the patients who were diagnosed with EDMD first presented with symptoms of cardiac disease such as palpitation or thoracalgia.^{1,2,10}

Muscle contractures usually occur in childhood and slow progression.¹¹ As the manifestation of muscle weakness range from humeral to peroneal, the contractures tend to initially present in elbows and Achilles' tendons,^{2,5,11} The contractures of muscles including cervical flexors and extensors may begin as early as the age of 5 years.^{11,12} Contracture of the cervical extensors, especially combined with contracture of

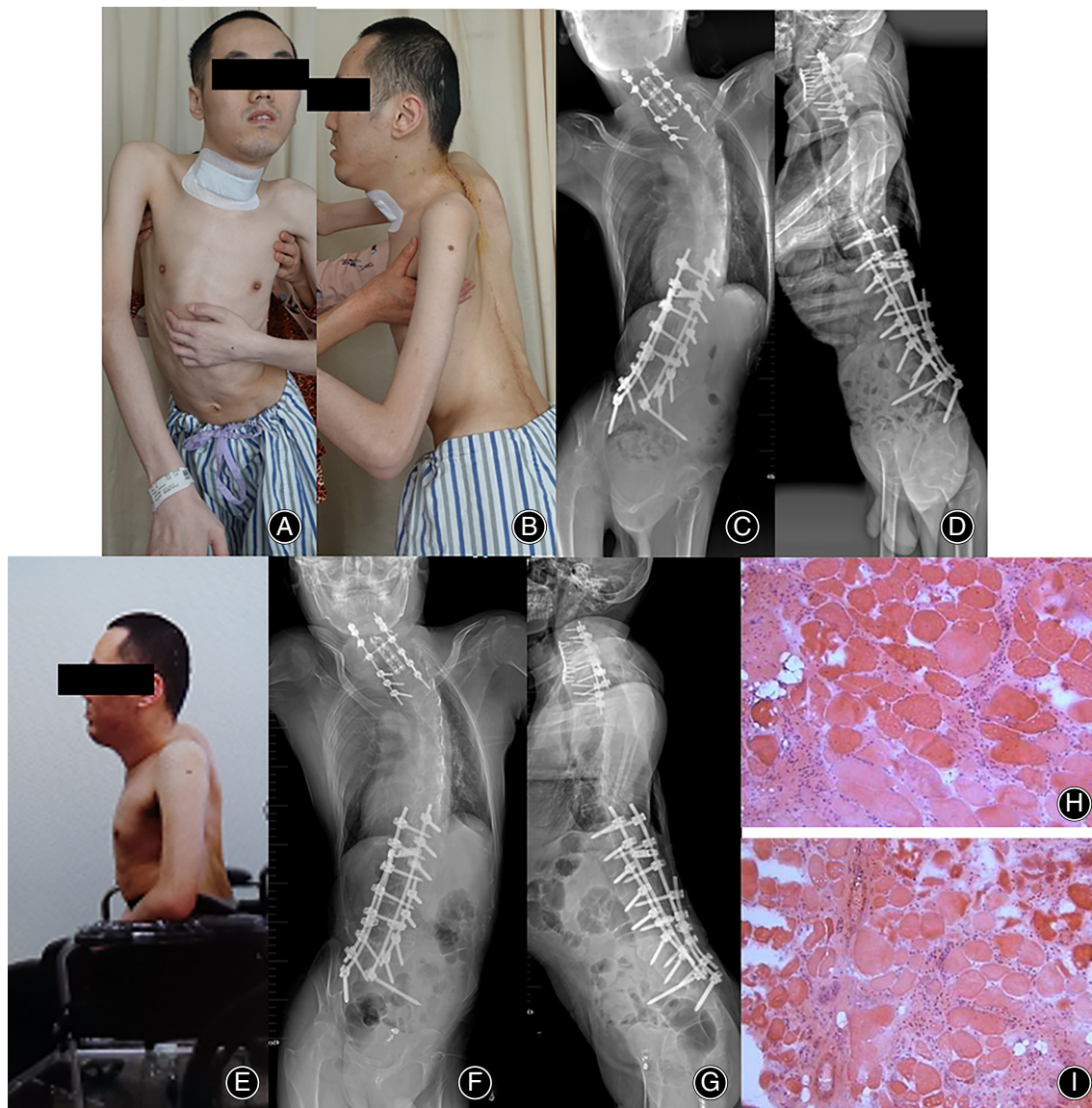


Fig. 4 Six months later, he underwent posterior–anterior–posterior cervical osteotomy. After cervical operation, his cervical lordosis became 57° , CBVA became 12° and he achieved a satisfactory horizontal gaze (A–D). At 1.5-year follow-up, the correction maintained well, and the radiographs showed 46° of Cobb angle, 14° of RK, 46 mm of SVA, 58° of cervical lordosis and 15° of CBVA (E, F, G). H & E stained sections of the paraspinal muscle specimens showed variation in fiber size, increased connective tissue, hypertrophic and atrophic muscle fibers, fiber splitting, several fibers with internal nuclei, abnormal mitochondrial proliferation and a few regenerating fibers (H, I).

paraspinal ligaments, can lead to cervical hyperextension.^{3,11} Additionally, Kose *et al.*⁷ reported difficulty moving into the osteotomy line when they attempted to raise patient's head for closing the osteotomy line after anterior cervical osteotomy, because of existence of rigid posterior cervical soft tissue. Therefore, performing posterior surgery first for sufficient release of soft tissue may be a better option.

Previous studies have described various surgical techniques for releasing posterior cervical soft tissue in detail.

Diebo *et al.*⁵ and Giannini *et al.*¹³ adopted Z-plasties to release muscle, submuscular tissue and fascia. Poulter *et al.*¹⁴ and Kose *et al.*⁷ preformed transverse division of the fibrotic muscle and resected the capsules of facet joint. These methods have been shown to be safe and effective in clinical practice. Combining Diebo *et al.*'s and Poulter *et al.*'s method, we performed Z-plasty and transverse division for releasing fibrotic muscle. Then, we resected bilateral facet joints for further release. Thorough and broad release of

posterior soft tissue made space for closing of the osteotomy line.

Diebo *et al.*⁵ observed that the restoration of global sagittal alignment after the correction of cervical deformity in EDMD during 8-year follow-up. Coincidentally, Kose *et al.*⁷ reported similar clinical outcomes in Becker muscular dystrophy (BMD), wherein sagittal alignment was restored after correction of cervical deformity. They all considered that the cervical hyperlordosis could be the driver of global sagittal malalignment, and suggested that cervical deformity should be dealt with first. Therefore, combined effects of head, thoracolumbar spine and pelvis could be the potential compensatory mechanism to maintain global spinal alignment in patients with cervical deformity. Based on these clinical theories and experience, we consider that the cervical deformity instead of compensatory thoracolumbar deformity should be corrected first.

However, because of the initial lumbar surgery, the strategy of revision should be considered prudently. It is well known that the objective of correcting cervical deformity should be to obtain a horizontal gaze.^{7,8,15} Suk *et al.*⁸ and Song *et al.*¹⁶ noted that satisfactory clinical outcomes would be achieved if the CBVA can be maintained between 10° and 20° in patients with cervical deformity. However, in our patient, there was an intractable problem that if we corrected his cervical deformity first in revision surgery, he could obtain a temporary horizontal gaze with a suitable CBVA and lose it again after the following thoracolumbar revision surgery, and then an unplanned cervical surgery might be necessary.

Hence, the thoracolumbar revision surgery was performed as the first stage of this complex revision in order to achieve a stable thoracolumbar fusion with the balanced trunk over a horizontal pelvis. L5 PSO and pelvic fixation with S2AI screws were performed for effective correction of kyphoscoliosis. As expected, after the thoracolumbar surgery, his gaze was closer to vertical, and the CBVA increased from 35° to 66°. Meanwhile, there was aggravation of dysphagia and dyspnea.

Cervical surgery was arranged 6 months after thoracolumbar surgery in order to let him recover from surgical trauma. Admittedly, cervical osteotomy is associated with a high risk of neurovascular complications. McMaster *et al.*¹⁷ performed posterior C7 osteotomy to correct kyphosis with a high incidence of subluxation and associated neurological deficit (4/15, 26.7%). However, it is undeniable that cervical osteotomy can directly provide a horizontal gaze which is strongly associated with clinical outcomes, even with a lesser angle of osteotomy.^{8,15,17,18} We decided to perform an anterior C7-T1 close wedge osteotomy, because the spinal canal at this level is relatively wider than that at other levels, which could make enough space for the cord and C8 nerve root¹⁸. In addition, the vertebral arteries are not in the

transverse foramen, which make it possible to close the osteotomy line without the risk of vascular injury.^{7,17}

In particular, anterior cervical osteotomy offer some unique advantages over posterior cervical osteotomy. First, anterior cervical osteotomy provides sufficient direct decompression of the spinal cord. Second, this technique allows for closing the osteotomy line under direct vision, which reduces the risk of neurological deficit.¹⁸ Third, use of the Jackson table allows for repeated changes in the patient's position with minimal hazard. This shortens the operation time significantly and improves surgical safety. In addition, it is worth noting that posterior cervical fusion following the anterior cervical osteotomy could allow us to explore the C7 and C8 nerve roots to ensure absence of compression and provide a chance for remediation.

Conclusion

Cervical posterior–anterior–posterior closing-wedge osteotomy combined with long fusion at thoracolumbar spinal can be a useful surgical technique for correction of severe spine deformity in EDMD. The approach facilitates restoration of horizontal gaze on the basis of a balanced trunk. Cervical deformity in such patients should be corrected in the first stage considering its role as a “driver” of the global spine deformity.

Acknowledgments

This work was supported by National Natural Science Foundation of China (82072518).

Author contributions

All authors had full access to the data in the study and take responsibility for the integrity of the data and the accuracy of the data analysis. Investigation: Ziyang Tang and Zongshan Hu. Software: Ziyang Tang. Data curation: Ziyang Tang, Zongshan hu and Xiaodong Qin. Formal analysis: Ziyang Tang, Zongshan Hu and Xiaodong Qin. Methodology: Xiaodong Qin. Resources: Xiaodong Qin, Zezhang Zhu and Zhen Liu. Conceptualization: Zezhang Zhu and Zhen Liu. Project administration: Zezhang Zhu and Zhen Liu. Funding acquisition: Zhen Liu. Supervision: Zhen Liu. Writing—original draft: Ziyang Tang and Zhen Liu. Writing—review and editing: Zongshan Hu, Zezhang Zhu and Zhen Liu.

All authors commented on previous versions of the manuscript. All authors read and approved the final manuscript.

Ethical statement

The Ethics Committee of Nanjing Drum Tower Hospital, The Affiliated Hospital of Nanjing University Medical School approved this study.

References

1. Heller SA, Shih R, Kalra R, Kang PB. Emery–Dreifuss muscular dystrophy. *Muscle Nerve* Apr 2020;61(4):436–448.
2. Wicklund MP. The muscular dystrophies. *Continuum (Minneapolis)*. 2013;19(6 Muscle Disease):1535–70.
3. Madej-Pilarczyk A. Clinical aspects of Emery–Dreifuss muscular dystrophy. *Nucleus*. 2018;9(1):268–74.
4. Flanigan KM, Kerr L, Bromberg MB, et al. Congenital muscular dystrophy with rigid spine syndrome: a clinical, pathological, radiological, and genetic study. *Ann Neurol*. 2000;47(2):152–61.
5. Diebo BG, Shah NV, Messina JC, et al. Restoration of global sagittal alignment after surgical correction of cervical Hyperlordosis in a patient with Emery–Dreifuss muscular dystrophy: a case report. *JBJS Case Connect*. 2020;10(1):e0003.
6. Emery AE. Emery–Dreifuss muscular dystrophy—a 40 year retrospective. *Neuromuscul Disord*. 2000;10(4–5):228–32. [https://doi.org/10.1016/s0960-8966\(00\)00105-x](https://doi.org/10.1016/s0960-8966(00)00105-x)
7. Kose KC, Caliskan I, Bal E, Inanmaz ME, Isik C. C7-T1 anterior closing wedge bone-disc-bone osteotomy for the treatment of cervical hyperlordosis in muscular dystrophy: a new technique for correction of a rare deformity. *Spine (Phila Pa 1976)*. 2014;39(18):E1066–72.
8. Suk KS, Kim KT, Lee SH, Kim JM. Significance of chin-brow vertical angle in correction of kyphotic deformity of ankylosing spondylitis patients. *Spine (Phila Pa 1976)*. 2003;28(17):2001–5.
9. Voit T, Krogmann O, Lenard HG, et al. Emery–Dreifuss muscular dystrophy: disease spectrum and differential diagnosis. *Neuropediatrics*. 1988;19(2):62–71.
10. Hsu DT. Cardiac manifestations of neuromuscular disorders in children. *Paediatr Respir Rev*. 2010;11(1):35–8.
11. Shapiro F, Specht L. Orthopedic deformities in Emery–Dreifuss muscular dystrophy. *J Pediatr Orthop*. 1991;11(3):336–40.
12. Quijano-Roy S, Mbieleu B, Bonnemann CG, et al. De novo LMNA mutations cause a new form of congenital muscular dystrophy. *Ann Neurol* Aug 2008;64(2):177–86.
13. Giannini S, Faldini C, Pagkrati S, Grandi G, Romagnoli M, Merlini L. Surgical treatment of neck hyperextension in duchenne muscular dystrophy by posterior interspinous fusion. *Spine (Phila Pa 1976)*. 2006;31(16):1805–9.
14. Poulter GT, Garton HJ, Blakemore LC, Hensinger RN, Graziano GP, Farley FA. Mortality and morbidity associated with correction of severe cervical hyperextension. *Spine (Phila Pa 1976)*. 2009;34(4):378–83.
15. Wang T, Song D, Zheng G, Wang Y. Staged cervical osteotomy: a new strategy for correcting ankylosing spondylitis thoracolumbar kyphotic deformity with fused cervical spine. *J Orthop Surg Res*. 2019;14(1):108.
16. Song K, Su X, Zhang Y et al. Optimal chin-brow vertical angle for sagittal visual fields in ankylosing spondylitis kyphosis. *Eur Spine J Aug 2016;25(8):2596–604*.
17. McMaster MJ. Osteotomy of the cervical spine in ankylosing spondylitis. *J Bone Joint Surg Br*. 1997;79(2):197–203.
18. Wang ZW, Shu JW, Li Md FC, et al. Cervical flexion osteotomy through one-stage posterior-anterior-posterior approach for cervical extension deformity in ankylosing spondylitis: a novel surgical technique. *Orthop Surg*. 2020;12(3):1005–9.