

# The use of middle cerebral artery Doppler ultrasonography to guide delivery of a viable pregnancy complicated by metastatic gestational choriocarcinoma

**Andrew S Thagard<sup>1</sup>**  
MD, Capt, MC, USAF

**Elizabeth A Dubil<sup>1</sup>**  
MD, LT, MC, USN

**Amy Lee<sup>2</sup>**  
MD, Capt, MC, USAF

**Jay Allard<sup>3</sup>**  
MD, CDR, MC, USN

**Craig M Zelig<sup>1</sup>**  
MD, Capt, MC, USN

<sup>1</sup>Naval Medical Center  
Portsmouth  
Department of Obstetrics  
and Gynecology  
Portsmouth VA  
USA

<sup>2</sup>Naval Medical Center  
Portsmouth  
Residency in Obstetrics  
and Gynecology  
Portsmouth VA  
USA

Department of Obstetrics  
and Gynecology  
Portsmouth VA  
USA

<sup>3</sup>Naval Medical Center  
Portsmouth  
Department of  
Obstetrics and  
Gynecology  
Division of Gynecologic  
Oncology  
Portsmouth VA  
USA

Correspondence to email  
Elizabeth.A.Dubil  
@health.mil

## Abstract

**Background:** Choriocarcinoma is a rare, aggressive subtype of gestational trophoblastic neoplasia. The diagnosis of metastatic choriocarcinoma in the setting of a viable intrauterine pregnancy is exceedingly rare and often associated with fetomaternal hemorrhage.

**Case:** An otherwise healthy Gravida 1 Para 0 at 34 weeks gestational age presented with metastatic choriocarcinoma and a viable fetus. Measured Doppler peak systolic velocity of the middle cerebral artery was used to detect fetal anemia, thus optimising the timing of delivery.

**Conclusion:** This is the first case report to our knowledge using Doppler ultrasonography to detect fetal anemia in an effort to guide delivery in a case of choriocarcinoma diagnosed during pregnancy. If choriocarcinoma is diagnosed during pregnancy, middle cerebral artery Doppler ultrasonography may serve as a critical tool to help detect anemia, allowing pregnancy prolongation to promote fetal maturity while screening for the development of fetomaternal hemorrhage.

**Keywords:** choriocarcinoma, fetomaternal hemorrhage, MCA-PSV Doppler

## Introduction

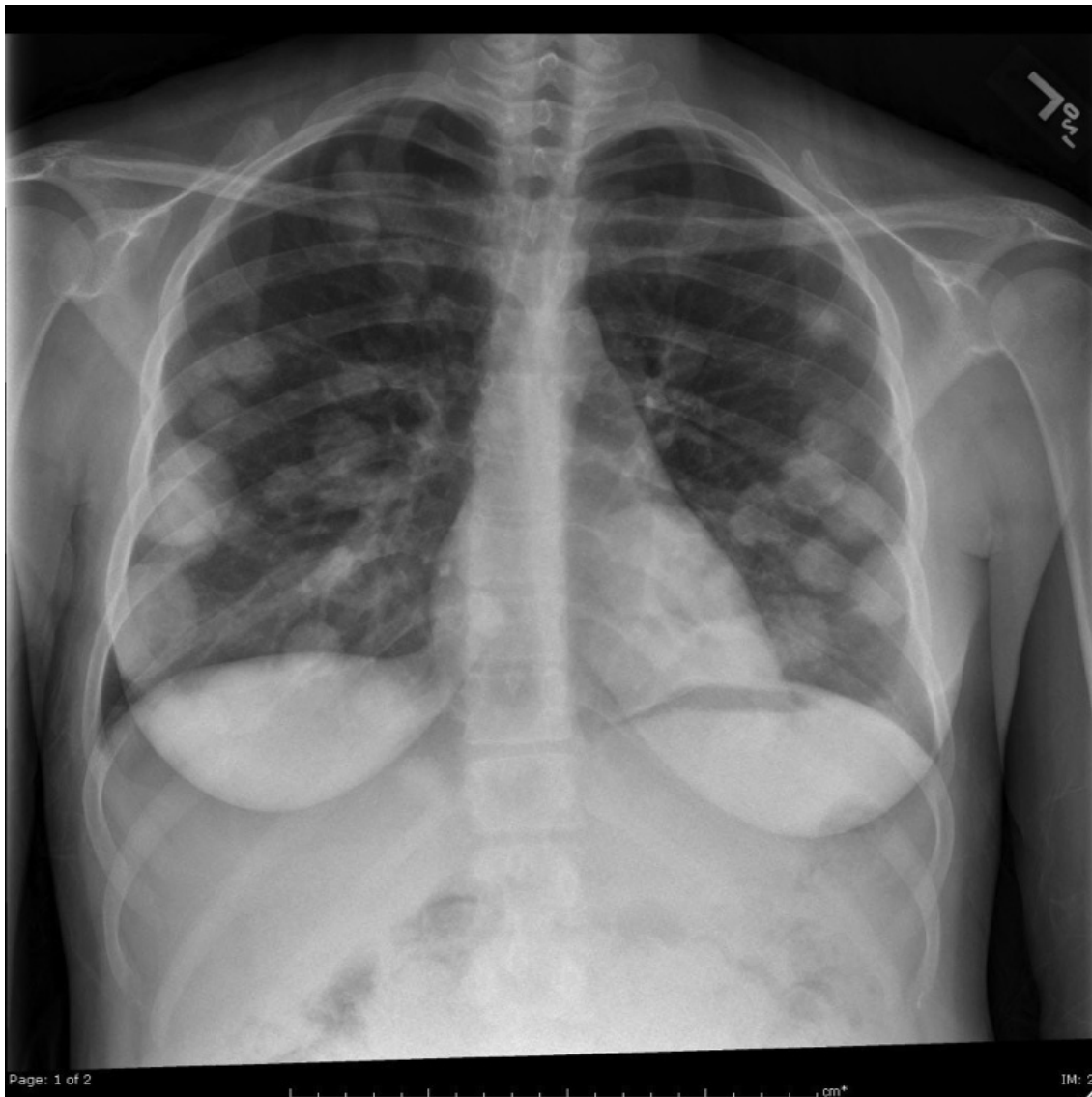Choriocarcinoma is a rare, aggressive subtype of gestational trophoblastic neoplasia that affects an estimated 1 in 24,000<sup>1</sup> to 1 in 40,000<sup>2,3</sup> pregnancies in the United States. The disease has a propensity for metastasis to the lungs, brain, liver, vagina, and pelvis and arises from hydatidiform moles in about 50% of cases, although choriocarcinoma can be associated with any type of pregnancy.<sup>2</sup> The diagnosis of metastatic choriocarcinoma in the setting of a viable intrauterine pregnancy is exceedingly rare with less than 50 cases reported in the literature<sup>4-6</sup> and carries significantly increased morbidity and mortality for mother and neonate.<sup>7</sup> Diagnosis is typically based on and abnormal hCG level as well as presence of metastatic disease.<sup>8</sup> Histopathologic diagnosis is not considered mandatory for initiation of treatment.<sup>9,10</sup> Treatment during pregnancy is acceptable; however, the optimal management of these pregnancies and timing of delivery must be individualised.<sup>11</sup>

Choriocarcinoma is characterised by invasion of trophoblastic tissue into the uterine musculature and maternal vascular spaces with hemorrhage and necrosis; this allows for fetal cells to cross the placental barrier resulting in the potential for large fetomaternal

hemorrhage.<sup>12</sup> The diagnosis of fetomaternal hemorrhage is made either by intrauterine fetal demise associated with hydrops fetalis, abnormal monitoring, or as neonatal anemia.<sup>13</sup> The diagnosis of choriocarcinoma is often not made until postpartum based on pathology or presentation of maternal disease.<sup>14</sup> Rarely is the diagnosis of choriocarcinoma made antepartum without associated fetal compromise or disease.

Measured Doppler peak systolic velocity (PSV) of the middle cerebral artery (MCA) is an established tool for the diagnosis and management of fetal anemia.<sup>15</sup> The technique involves measuring the peak velocity of blood in the MCA and comparing it to established normal values for peak velocity. Fetuses with values greater than 1.50 multiples of the median (MoM) indicate significant anemia.<sup>16</sup> First used in the diagnosis of fetal anemia secondary to alloimmunisation, MCA-PSV has also been used in the evaluation of anemia resulting from fetomaternal hemorrhage.<sup>17</sup>

We present a case of metastatic choriocarcinoma with a concurrent viable fetus diagnosed at 34 weeks gestational age in which the use of MCA-PSV Dopplers assisted in optimising the timing of delivery with positive maternal and neonatal outcomes.



**Figure 1:** X-ray showing over forty rounded opacities measuring 2–4 cm scattered throughout the lungs that appeared consistent with metastatic disease.

### Case

A 21-year-old Caucasian G1P0 initially presented for evaluation of a one week history of significant chest pain and shortness of breath at 34 weeks gestational age. She was treated for pneumonia at an outside facility after a chest x-ray revealed multiple pulmonary opacities. Her symptoms, however, failed to improve and she presented to our hospital for re-evaluation.

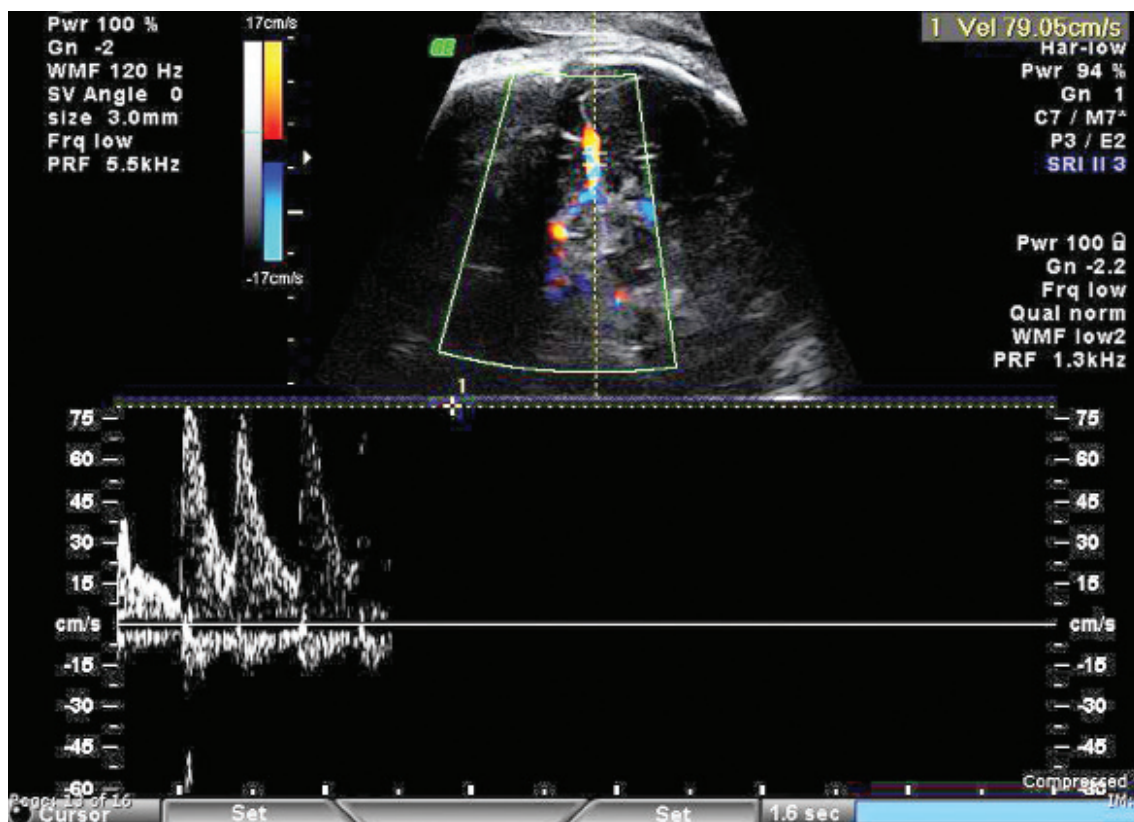
Her pregnancy up to that point was uncomplicated. She was appropriately dated and her prenatal labs, including aneuploidy screening, were unremarkable. A second trimester ultrasound had confirmed normal fetal anatomy along with an unremarkable posterior placenta. On our evaluation, the patient was well appearing but reported persistent dull chest pain. She remained afebrile with an oxygen saturation of 96% on room air. Her pulmonary exam revealed mildly course breath sounds at the left apex. The remainder of the patient's examination was normal. A chest x-ray was obtained, which showed over forty rounded opacities measuring 2–4 cm scattered throughout the lungs that appeared consistent with metastatic disease (Figure 1). Fetal wellbeing was assured with a non-stress test. A quantitative hCG was drawn which exceeded 900,000 mIU/mL, and she was

diagnosed with metastatic choriocarcinoma (Figure 1).

Examination of the patient's vagina and CT scan of the brain, chest, abdomen, and pelvis revealed no additional sites of metastasis and was notable only for bilaterally enlarged ovaries with multiple thecal lutein cysts. A follow-up growth ultrasound showed an appropriately growing fetus, with no obvious abnormalities or focal masses in the placenta.

The patient was diagnosed with stage III:11 choriocarcinoma based on WHO criteria. In consultation with the gynecologic oncology service, the decision was made to defer chemotherapy until after delivery with a cesarean selected as the planned route to allow evaluation of the ovaries and out of concern for possible hemorrhage following extraction of the placenta. Given her clinically stable condition, the patient opted for a period of conservative management. She was admitted to the hospital and monitored with daily non-stress tests and twice-weekly biophysical profiles (BPP) and MCA Dopplers with plans for scheduled delivery at 36 weeks EGA or sooner for signs of fetal or maternal compromise.

Her first BPP was obtained at a gestational age of 34 weeks and six days and reported as 8/10. MCA-PSV Dopplers done



**Figure 2:** MCA-PSV Dopplers at 33+6 weeks gestation.

at the time revealed a peak flow rate of 75–79 cm/sec which exceeded 1.5 multiples of the mean (MoM), 76.1 cm/sec at 35 weeks gestation,<sup>16</sup> and was consistent with fetal anemia thought to be secondary to hemorrhage at the placental site of the choriocarcinoma. (Figure 2). The patient underwent an exploratory laparotomy with primary low transverse cesarean delivery that day. Her surgery and post-operative course were uncomplicated with an estimated blood loss of 700 mL. A small focal abnormality was noted on the placenta by the surgeons at the time of delivery; however, there was no evidence of retro-placental clot. A post-partum Kleihauer Betke test was obtained, which showed approximately 66 mL fetomaternal hemorrhage. The patient received the appropriate dose of anti-D immune globulin. Pathologic examination of the placenta revealed a 3.1 cm focus of choriocarcinoma, which was also confirmed on histology (Figure 2).

Her female infant weighed 2270 g at delivery with 1 and 5 minute APGARs of 2 and 9 respectively and an arterial umbilical cord pH of 7.28. The infant was noted to have mild respiratory distress and was admitted to the NICU for a total of 22 days. Her admission hemoglobin was 12.3 g/dL and hematocrit 37.3% consistent with neonatal anemia (average hemoglobin is 16.5 g/dL and hematocrit is 65% at our facility), which responded to iron.

The patient was started on multiagent chemotherapy including etoposide, high-dose methotrexate with folinic acid, actinomycin D, cyclophosphamide, and vincristine (EMA-CO) for her high-risk disease two weeks post-partum. She required a total of five rounds of EMA-CO to achieve an undetectable hCG level. Her chemotherapy course was complicated by severe neutropenia preceding cycle 2, which required a one-week delay

and mild peripheral neuropathy, which has since resolved. She is currently undergoing close surveillance and is disease free to date, thirteen months since delivery.

### Discussion

As previously described, the diagnosis of choriocarcinoma is generally made in the context of elevated quantitative hCG levels and radiologic evidence of metastatic disease. The presence of choriocarcinoma in a viable pregnancy is very rare and radiologic identification of the primary tumor is difficult given its usually small size. Identification of the placental lesion is possible in some cases with its sonographic appearance described as a hypervascular, heterogenous, and echogenic mass with areas of intralesional necrosis or hemorrhage<sup>18</sup> but was not evident in our patient's two ultrasounds. In general, radiographic identification of choriocarcinoma is possible, but technically difficult as grayscale appearance and Doppler ultrasound are nonspecific.<sup>19,20</sup> Accurate antepartum diagnosis depends on correlation with clinical findings and hCG levels.<sup>9</sup> CT scanning reveals the hypervascular metastatic lesions of choriocarcinoma well and is the most suitable method for evaluation of common metastatic sites.<sup>19</sup> MRI is usually reserved for equivocal cases or evaluation of brain or vaginal metastases<sup>9</sup> and was not performed in this case.

Reference values for MCA-PSV were originally developed as a non-invasive test for suspected neonatal anemia secondary to alloimmunisation and are correlated to umbilical cord hemoglobin at time of cordocentesis or delivery.<sup>16,21</sup> Conceptually, blood with lower hemoglobin values has increased velocity. In acute events, the hemoglobin level has not had time to equilibrate, therefore, when anemia is discovered in gestational

choriocarcinoma by this method, it can be assumed the event is chronic. A chronic event, however, does not insinuate the need for expectant management as bleeding from choriocarcinoma can be sudden and catastrophic. Due to our patient's gestation and the presence of fetal anemia, the decision was made for delivery, although we recognise there are no standard guidelines.

This is the first case report to our knowledge of the use of Doppler ultrasonography to detect fetal anemia and guide delivery in a case of choriocarcinoma diagnosed during pregnancy. Although fetal anemia was detected on the first Doppler ultrasound prompting delivery, there exists the potential for this tool to be used to allow a pregnancy to progress safely. If gestational choriocarcinoma is detected antenatally, this may allow for a delay in delivery without fetal compromise in cases that have not yet developed fetomaternal hemorrhage.

There was no funding source for this research.

### Financial disclosure

No funding or financial support was received for this work.

### Disclaimer

The opinions or assertions contained herein are the private views of the authors and are not to be construed as official or as reflecting the views of the department of the Army, Navy, Air Force, or the Department of Defense or the United States Government.

### References

- Brinton LA, Bracken MB, Connelly RR. Choriocarcinoma incidence in the United States. *Am J Epidemiol* 1986; 123 (6): 1094–100.
- Lurain JR. Gestational trophoblastic tumors. *Semin Surg Oncol* 1990; 6: 347–53.
- Lurain JR. Gestational trophoblastic disease I: Epidemiology, pathology, clinical presentation and diagnosis of gestational trophoblastic disease, and management of hydatidiform mole. *Am J Obstet Gynecol* 2010; 203: 531–39.
- Ahmed A, DeGeest K, Sorosky J. Metastatic choriocarcinoma to the lung coexistent with a viable pregnancy. *Int J Gynaecol Obstet* 2006; 94 (1): 56–57.
- Liu J, Guo L. Intraplental choriocarcinoma in a term placenta with both maternal and infantile metastases: a case report and review of the literature. *Gynecol Oncol* 2006; 103 (3): 1147–51.
- Zhu Y, Cheng N, Liu J. Third-trimester intrauterine pregnancy complicated by metastatic choriocarcinoma. *Int J Gynaecol Obstet* 2012; 21: S0020-7292 (12) 00630-3.
- Steigrad SJ, Cheung AP, Osborn RA. Choriocarcinoma co-existent with an intact pregnancy: case report and review of the literature. *J Obstet Gynaecol Res* 1999; 25 (3): 197–203.
- Ngan HY, Bender JL, Benedet JL, Jones H, Montrucoli GC, Pecorelli S. Gestational trophoblastic neoplasia, FIGO 2000 staging and classification. *Int J Gynaecol Obstet* 2003; 83. Supplement 1: 175–77.
- Kani KK, Lee JH, Dighe M, Moshiri M, Kolokythas O, Dubinsky T. Gestational trophoblastic disease: multimodality imaging assessment with special emphasis on spectrum of abnormalities and value of imaging in staging and management of disease. *Curr Probl Diagn Radiol* 2012; 41 (1): 1–10.
- Wagner BJ, Woodward PJ, Dickey GE. From the archives of the AFIP. Gestational trophoblastic disease: radiologic-pathologic correlation. *Radiographics* 1996; 16 (1): 131–48.
- Sivanesaratnam VJ. Chien-Tien Hsu Memorial Lecture. Fertility and gynaecologic malignancies. *Obstet Gynaecol Res* 2001; 27 (1): 1–15.
- Benson PF, Goldsmith KL, Rankin GL. Massive fetal hemorrhage into maternal circulation as a complication of choriocarcinoma. *BMJ* 1962; 1: 841–42.
- Henningsen AK, Maroun LL, Havsteen H, Svare J. Massive fetomaternal hemorrhage caused by an intraplental choriocarcinoma: a case report. *Case Rep Med* 2010; 767218. Epub 3 March 2010.
- Lam CM, Wong SF, Lee KW, Ho LC, Yu VS. Massive fetomaternal hemorrhage: an early presentation of women with gestational choriocarcinoma. *Acta Obstet Gynecol Scand* 2002; 81: 573–76.
- Schenone MH, Mari G. The MCA Doppler and its role in the evaluation of fetal anemia and fetal growth restriction. *Clin Perinatol* 2011; 38: 83–102.
- Mari G, Mari G, Deter RL, Carpenter RL, Rahman F, Zimmerman R, Moise KJ Jr, et al. Noninvasive diagnosis by Doppler ultrasonography of fetal anemia due to maternal red-cell alloimmunization. Collaborative Group for Doppler Assessment of the Blood Velocity in Anemic Fetuses. *N Engl J Med* 2000; 342 (1): 9–14.
- Eichbaum M, Gast AS, Sohn C. Doppler sonography of the fetal middle cerebral artery in the management of massive fetomaternal hemorrhage. *Fetal Diagn Ther* 2006; 21 (4): 334–38.
- Elsayes KM, Trout AT, Friedkin AM, Liu PS, Bude RO, Platt JF, Menias CO. Imaging of the placenta: a multimodality pictorial review. *Radiographics* 2009; (5): 1371–91.
- Allen SD, Lim AK, Seckl MJ, Blunt DM, Mitchell AW. Radiology of gestational trophoblastic neoplasia. *Clin Radiol* 2006; 61: 301–13.
- Taylor KJ, Schwartz PE, Kohorn EI. Gestational trophoblastic neoplasia: Diagnosis with Doppler US. *Radiology* 1987; 165: 445–48.
- Andrei C, Vladareanu R. The value of reference ranges for middle cerebral artery peak systolic velocity in the management of rhesus alloimmunized pregnancies. *Maedica*. 2012; 7 (1): 14–19.