



Case report

An unusual association between pancreatic cancer and Purtscher-like retinopathy: Presentation of a unique case

Eva Intagliata, MD PhD^{a,*}, Salvatore Giugno, MD^b, Clarissa Vizzini, MD^a,
Rossella Rosaria Cacciola, MD PhD^c, Rosario Vecchio, MD FACS^a, Veronica Vecchio^c

^a Department of General Surgery and Medical Surgical Specialties, University of Catania, Policlinico "G. Rodolico-San Marco", Via S. Sofia 78, 95123 Catania, Italy

^b Hospital Department and Integration, Maria Immacolata Longo Hospital, Ophthalmology Unit, Via Dogliotti 1, 93014 Mussomeli, Italy

^c Department of Biomedical Science, Hematologic Unit, University of Catania, Policlinico "G. Rodolico-San Marco", Via S. Sofia 78, 95123 Catania, Italy

ARTICLE INFO

Keywords:

Pancreatic adenocarcinoma
Purtscher's-like retinopathy
Purtscher's retinopathy

ABSTRACT

Introduction: Purtscher's retinopathy causes sudden loss of vision of varying severity, secondary to head injury or chest compression. Its pathophysiology is unclear. Purtscher's-like retinopathy has more attenuated clinical and objective features and can be associated with many non-neoplastic pathologies.

Otherwise, an association of this kind of retinopathy with malignancies has been described once in the Literature. We present a case report on a unique association between pancreatic cancer and Purtscher-type retinopathy.

Case presentation: A 79-year-old man with reduced central vision in both eyes required an ophthalmic evaluation. Visual acuity was 20/40 in the right eye and 20/50 in the left eye. Fundus examination showed yellow-white peripapillary spots and bilateral retinal hemorrhages in the superficial retina.

The patient complained of abdominal pain and received a CT scan of the abdomen, which showed a pancreatic mass extending into the spleen. A percutaneous needle biopsy sample showed mucinous pancreatic adenocarcinoma.

Clinical discussion: This case report should warn of a possible association between pancreatic adenocarcinoma and Purtscher's-like retinopathy.

Conclusion: Patients with this kind of retinopathy should be evaluated to rule out not only benign associated disease, but also malignant tumors of the pancreas.

1. Introduction

Purtscher's retinopathy causes sudden loss of vision of varying severity, usually secondary to head injury or chest compression, and its pathophysiology is unclear.

Purtscher's-like retinopathy has more attenuated clinical and objective features and is mainly associated with non-neoplastic diseases, such as acute pancreatitis, embolization of fat, air or amniotic fluid, connective tissue disease, and bone marrow transplantation. An association of this kind of retinopathy with malignancies has been described once in the Literature, as an initial manifestation of multiple myeloma [1]. In this report, we describe and discuss a unique case of a pancreatic cancer and this kind of retinopathy.

2. Case report

A 79-year-old man was admitted to an ophthalmology unit due to loss of vision in both eyes. Ocular history was irrelevant, while medical history assessed irritable bowel syndrome and chronic gastritis treated with ranitidine and omeprazole. The patient reported neither recent trauma nor other pathologies. As relevant familiar history, the father affected by pancreatic cancer was reported.

The best corrected visual acuity was 20/40 in the right eye and 20/50 in the left. Anterior segment, intraocular pressure, and pupillary findings were irrelevant, while at the funduscopy examination the back of the eye showed large yellow spots and retinal hemorrhages in the superficial retina. In the early stages, fluorescein angiography showed hypofluorescence in the area of the yellow-white patches while the late stages showed hyperfluorescence (Fig. 1).

The patient also complained of nausea and upper abdominal pain

* Corresponding author.

E-mail addresses: evaintagliata@vodafone.it (E. Intagliata), rcacciol@unict.it (R.R. Cacciola), rvecchio@unict.it (R. Vecchio).

<https://doi.org/10.1016/j.ijscr.2022.107338>

Received 13 February 2022; Received in revised form 18 June 2022; Accepted 18 June 2022

Available online 22 June 2022

2210-2612/© 2022 Published by Elsevier Ltd on behalf of IJS Publishing Group Ltd. This is an open access article under the CC BY-NC-ND license (<http://creativecommons.org/licenses/by-nc-nd/4.0/>).

and additional studies were accomplished. Sample testing revealed hemoglobin of 8.9 g/dl, alanine aminotransferase of 100 U/l (normal range from 0 to 48 U/l), alkaline phosphatase of 240 U/l (normal range from 20 to 125 U/l), lactate dehydrogenase of 840 U/l (normal range 50 to 240 U/l), gamma glutamyl transferase of 160 U/l (normal range 10 to 50 U/l). Other lab test including amylase and lipase were within the normal range.

The patient received a non-enhanced CT scan of the abdomen, which revealed a large mass in the tail of the pancreas with direct extension to the vessels of splenic hilum and splenic vein thrombosis (Fig. 2). A secondary invasion of the gastric wall and left adrenal gland was also demonstrated (Fig. 3).

For his eyes' disease, the Author G.S. treated the patient with supportive medical therapy of 1 g. of methylprednisolone in saline solution 250 cc once a day for 5 days, and one eye drops of Diclofenac per eye 3 times a day for 30 days. During the follow-up, improvement of macular edema at the funduscopic examination, which corresponded to the improvement of the sight, was promptly observed.

Percutaneous needle biopsy was performed in another Institute and histopathology showed moderate to poorly differentiated mucinous pancreatic adenocarcinoma.

Continuation of the diagnostic and therapeutic process was performed elsewhere, where the patient was not found fit for surgical treatment of his pancreatic cancer and therefore oncologic palliative medical treatment was administered. The patient got lost after six months follow-up.

The work has been reported in line with the SCARE 2020 criteria [2].

3. Discussion

In 1912, Purtscher described multiple, superficial, white retinal patches and superficial retinal hemorrhages in patients with severe traumatic brain injury, naming this condition as Purtscher's retinopathy.

Purtscher's retinopathy is an occlusive microvasculopathy associated with cranial trauma or thoracic compression, whose pathophysiology is unclear. It is thought that a sudden increase in thoracic venous pressure can cause reflux shockwaves through the venous system, resulting in lymphatic extravasation. Traumatic endothelial cell damage can cause microvascular incompetence, intravascular coagulopathy and granulocytic aggregation, resulting in microvascular occlusion and focal ischemia.

Microvascular occlusion can also result from air, fat, and amniotic fluid embolism. Abnormal activation of complement C5a has been implicated in the initiation of intravascular aggregation of leukocytes in some of the conditions associated with Purtscher's retinopathy [3–5].

Besides the classic Purtscher's retinopathy, a similar clinical retinopathy having non-traumatic etiology has also been described. This

pathology, designated in the Literature as Purtscher's-like retinopathy [4], is usually associated with acute pancreatitis [6–13], whose detection could be an indicator of multi-organ failure with a poor prognosis [14]. The possible pathophysiology lies in the pancreatic injury or inflammation that causes the release of activated proteases such as trypsin, which in turn activate the complement system. The abnormal presence of activated C5a complement and aggregation of granulocytes can cause retinopathy. Acute pancreatitis can also be associated with other factors that can contribute to the development of retinopathy, such as fat embolization, increased venous pressure, retinal arteriolar spasm, blood pressure fluctuations and anemia [3–5].

Other causes of Purtscher's-like retinopathy include autoimmune diseases such as dermatomyositis [15–19], lupus anticoagulans [20–22], antiphospholipid syndrome [23], and Still's disease [24,25].

Some hematologic diseases could associate to Purtscher's-like retinopathy, such as hemolytic uremic anemia [26,27], crioglobulin [28,29], and immune thrombocytopenic purpura [30]. Cardio-vascular diseases may cause a Purtscher's-like retinopathy, as in case of heart attack [31], carotid artery dissection [32], and cerebral or cardiovascular surgery [33].

Other pathologies less frequently associated to Purtscher's-like retinopathy are renal failure [36–38], anaphylaxis [39], pre-eclampsia and HELLP syndrome [4,21,40,41]. Cases of association with Covid-19 have also been found in Literature [34,35], being the SARS-Cov-2 infection a predisposing risk of thrombosis. Only one case of association with malignancies has been described in the Literature, where Purtscher's-like retinopathy was considered as an initial manifestation of multiple myeloma [1].

Clinical features of Purtscher's retinopathy and Purtscher's-like retinopathy include loss of vision associated with multiple patches and hemorrhages in the superficial retina surrounding the optic disc. Fundus fluorescein angiography shows early hypofluorescence (edema or superficial retinal hemorrhages) and subsequent loss corresponding to the area of the white retinal lesions. White spots and bleeding resolve within a few weeks while blurred central vision persists in about 50 % of cases. Clinico-pathological studies showed occluded retinal arterioles and choroidal vessels, focal areas of edema within the internal retinal layers, cystoid spaces, small hemorrhages and interruption of photoreceptors [5]. Unlike Purtscher's retinopathy, Purtscher's-like retinopathy has more attenuated clinical and objective features.

Differential diagnoses should include branch or central retinal artery occlusion, hypertensive retinopathy, diabetic retinopathy, and HIV retinopathy with cotton-wool spots [42].

There are no consensual guidelines on the therapeutic approach [43,44] and the treatment can be difficult due to the underlying life-threatening pathology. In the majority of cases, the acute lesions resolve spontaneously within 1–3 months from the appearance. Nevertheless, there are some reports on successful treatment with

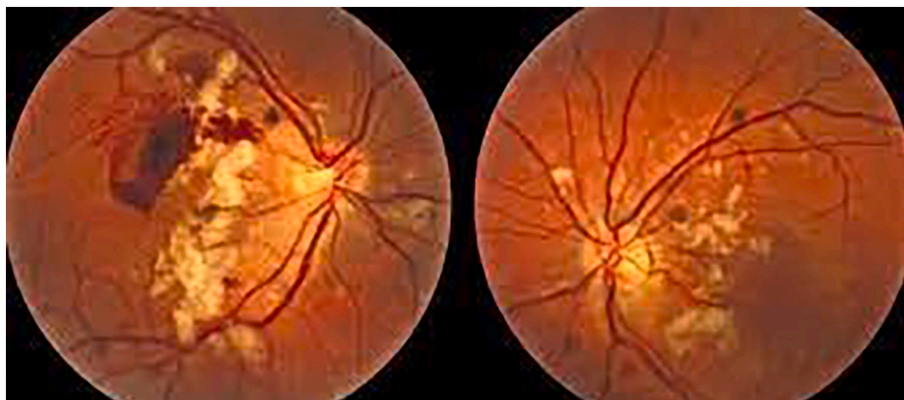

Fig. 1. Retinal fluorescein angiography.

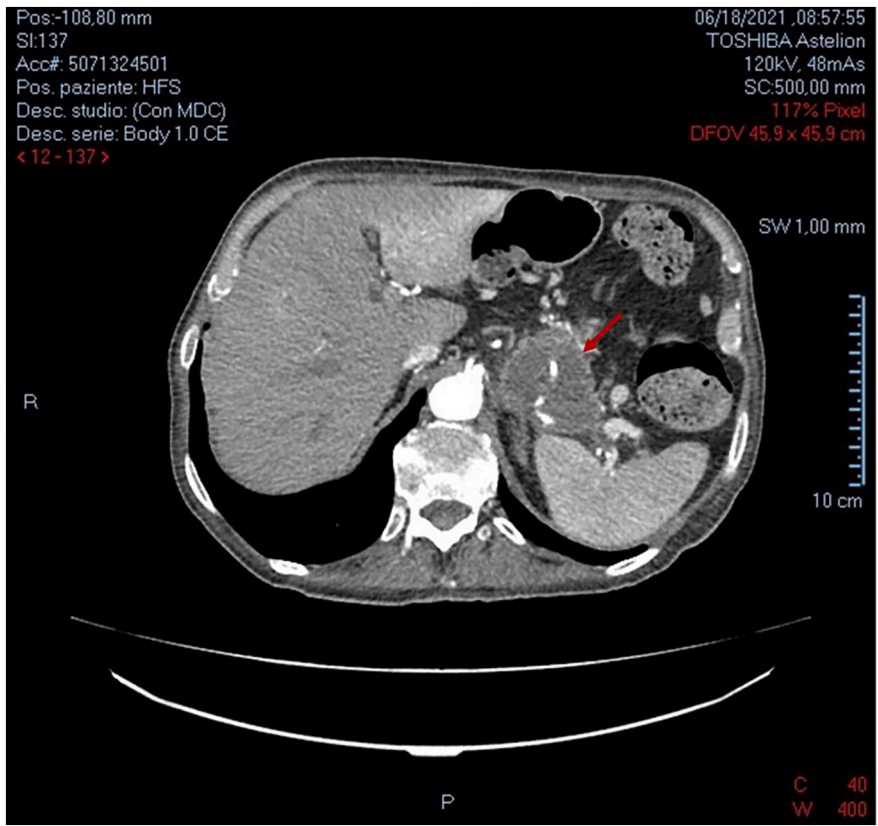


Fig. 2. Pancreas adenocarcinoma infiltrating the vessels of splenic hilum with splenic vein thrombosis.

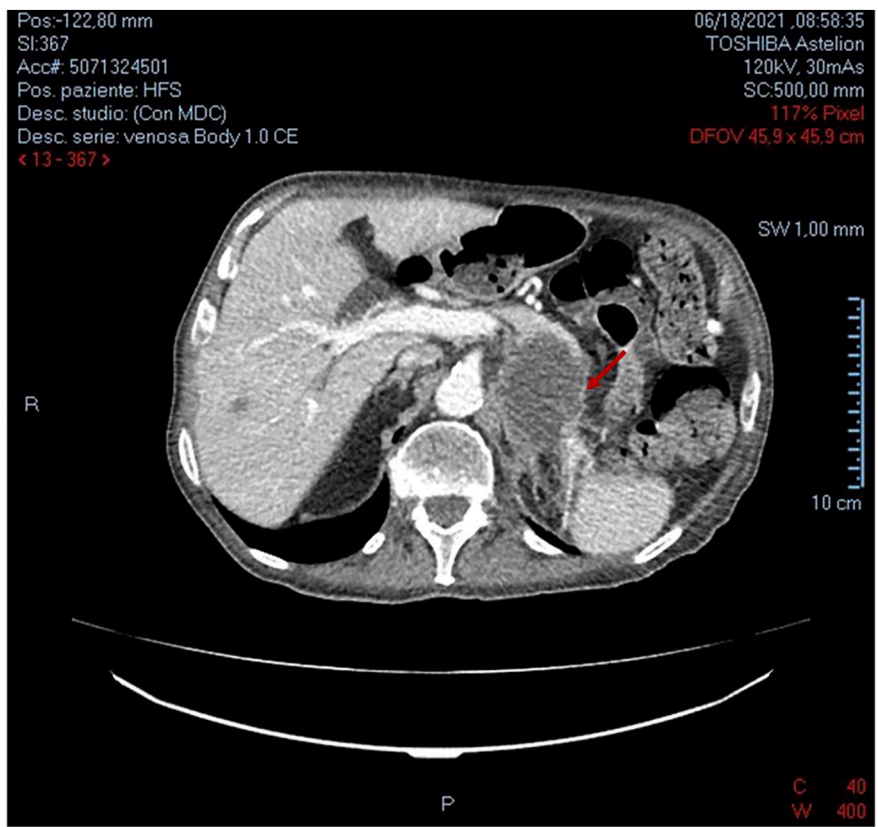


Fig. 3. Secondary invasion of the gastric wall and left adrenal gland from the pancreatic adenocarcinoma.

intravenously high-dose steroids [4].

The prognosis depends on the affected retinal areas that should be carefully monitored, and on the underlying pathology [4].

4. Conclusion

Our case report describes a unique association of Purtscher's-like retinopathy and pancreatic adenocarcinoma. We did not find any other similar association in the Literature. The pathophysiological mechanism of this association is unclear, and it could be a paraneoplastic syndrome as an early sign of pancreatic cancer. It is possible that the pancreatic insult by tumor invasion, results in the release of activated protease enzymes, which trigger the cycle of complement activation and microvascular occlusion.

This case report should warn of a possible association between pancreatic adenocarcinoma and Purtscher's-like retinopathy. Patients with this kind of retinopathy should be evaluated to rule out not only associated benign diseases, but also malignant tumors of the pancreas.

Pancreatic adenocarcinoma should be included in the list of systemic conditions associated with Purtscher's-like retinopathy, and the finding of this kind of retinopathy may suggest the presence of a severe and sneaky pathology, such as the pancreatic cancer.

Provenance and peer-review

Not commissioned, externally peer-review.

Sources of funding

There are no sources of funding.

Ethical approval

The study is exempt from ethical approval in our Hospital in Italy.

Consent

Since the patient got lost at the follow-up and his relatives are untraceable although our efforts to trace them, the hospital's management is guarantor of the case report. However, the paper has been anonymised not to cause harm to the patient or their family.

Author contributions

All the Authors contributed to conceptualization, data curation, investigation, methodology and writing.

Intagliata E, Giugno S and Vecchio R, in addition, supervised and reviewed the manuscript.

Declaration of competing interest

The authors declare that there are no conflicts of interest.

Acknowledgement

We are grateful to prof. Sciarretta Salvatore who helped in translating this work.

Research registration

NCT05350384 in Clinicaltrials.gov.

Guarantor

There are no sources of funding.

References

- [1] A. Nautiyal, G. Amescua, A. Jameson, J.F. Gradowski, F. Hong, B. Dof, Sudden loss of vision: purtscher retinopathy in multiple myeloma, *CMAJ* 181 (12) (2009 Dec 8) E277.
- [2] R.A. Agha, T. Franchi, C. Sohrabi, G. Mathew, for the SCARE Group, The SCARE 2020 guideline: updating consensus Surgical CASE REport (SCARE) guidelines, *Int. J. Surg.* 84 (2020) 226–230.
- [3] W. Behrens-Baumann, G. Scheurer, H. Schroer, Pathogenesis of Purtscher's retinopathy, *Graefes Arch. Clin. Exp. Ophthalmol.* 230 (1992) 286–291.
- [4] R Massa C Vale M Macedo MJ Furtado M Gomes M Lume A Meireles. Purtscher-like retinopathy. *Case Rep.Ophthalmol.Med*.Volume 2015, Article ID 421329, 5 pages.
- [5] A.I.M. Miguel, F. Henriques, L.F.R. Azevedo, A.J.R. Loureiro, D.A.L. Maberley, Systematic review of Purtscher's and Purtscher-like retinopathies, *Eye* 27 (2013) 1–13.
- [6] S.Y. Jeon, E. Jung, H.J. Seol, Y.J. Hur, Development of Purtscher-like retinopathy after pre-eclampsia combined with acute pancreatitis, *Obstet. Gynecol. Sci.* 56 (4) (2013 Jul) 261–264.
- [7] N. Nema, S. Ishrat, A. Verma, M. Kela, Purtscher-like retinopathy in acute alcoholic pancreatitis, *Oman J. Ophthalmol.* 9 (2) (2016 May-Aug) 110–112.
- [8] G.M. Gahn, A.M. Khanani, M. Khan, A.A. Aziz, F.A. Siddiqui, N.J. London, L. K. Mukkamala, L.S. Morse, Purtscher's-like retinopathy associated with acute pancreatitis, *Am. J. Ophthalmol. Case Rep.* 20 (20) (2020 Aug), 100892.
- [9] M.C. Kincaid, W.R. Green, D.L. Knox, C. Mohler, A clinicopathological case report of retinopathy of pancreatitis, *Br. J. Ophthalmol.* 66 (4) (1992) 219–226.
- [10] M. Wiecek, M. Caban, A. Fabisiak, E. Małecka-Panas, Purtscher's-like retinopathy as a rare complication of acute alcoholic pancreatitis, *Przeegląd Gastroenterologiczny* 16 (2021) 170–173.
- [11] P. Subudhi, S. Kanungo, Subudhi N. Rao, Purtscher's-like retinopathy in acute alcoholic pancreatitis, *BMJ Case Rep.* 2016 (2016), bcr2016215485. Sep 14.
- [12] W.M. Haque, M.A. Ananna, H.F. Haque, M.A. Rahim, T. Samad, S. Iqbal, Purtscher's retinopathy and renal cortical necrosis: two rare vaso-occlusive complications in a patient with acute pancreatitis: a case report, *J. Med. Case Rep.* 10 (1) (2016 Nov 15) 326.
- [13] T. Tariq, M. Reaume, D. Hammar, A. Shallal, M. Schauer, Blind after a binge: Purtscher-like retinopathy in acute alcoholic pancreatitis, *ACG Case Rep. J.* 6 (11) (2019 Nov 28), e00251.
- [14] G. Hollo', Frequency of Purtscher's retinopathy, *Br. J. Ophthalmol.* 92 (8) (2008) 1159.
- [15] K. Gullapalli, O. Goldzweig, K. Nanda, R. Chekka, S. Berry, H. Bukulmez, Juvenile dermatomyositis (JDM) complicated by thrombotic thrombocytopenic purpura (TTP) and Purtscher's retinopathy responsive to rituximab: case report and Literature review, *Front. Pediatr.* 4 (8) (2020) 436. Aug.
- [16] Y. Yan, X. Shen, Purtscher-like retinopathy associated with dermatomyositis, *Yan and Shen, BMC Ophthalmol.* 13 (2013) 36.
- [17] F. Vanoni, C. Jorgensen, P. Parvex, C. Chizzolini, M. Hofer, A difficult case of juvenile dermatomyositis complicated by thrombotic microangiopathy and Purtscher-like retinopathy, *Pediatr. Rheumatol.* 12 (2014), P275.
- [18] D. Vezzola, D. Allegrini, M.R. Romano, L. Pagano, A. Montericchio, P. Fogagnolo, L. M. Rossetti, S. De Cilla, Optical coherence tomography angiography in purtscher-like retinopathy associated with dermatomyositis: a case report, *J. Med. Case Rep.* 13 (1) (2019 Jul 6) 206.
- [19] M. Alzahrani, M.A. Rehman, T. Basodan, I. Adnan, M. Akhtar, Purtscher's retinopathy in scleroderma, *GMS Ophthalmol. Cases* 9 (2019), Doc07. Mar 1.
- [20] S. Chariba, R. Daoudi, Purtscher retinopathy in Lupus, *Pan. Afr. Med. J.* 22 (2015) 154.
- [21] R.M. Alahmadi, R.T. Hashim, S.M. Almogairin, A.M. Abu, Purtscher-like retinopathy as a first presentation of systemic lupus erythematosus, *Ann. Saudi Med.* 36 (1) (2016 Jan-Feb) 85–88.
- [22] A.H. Palkar, M. Delwar Hossain, Parthopratim Dutta Majumder, Purtscher-like retinopathy as presenting manifestation of systemic lupus erythromatosus following high-grade fever with myalgia and arthralgia, *Indian J. Ophthalmol.* 66 (9) (2018 Sep) 1317–1319.
- [23] V. Raval, T. Das, Bilateral Purtscher-like retinopathy with macular ischemia in preeclampsia secondary to antiphospholipid syndrome, *Indian J. Ophthalmol.* 67 (11) (2019 Nov) 1883.
- [24] K. Akiyama, Y. Iwasaki, R. Tanaka, Severe adult still's disease complicated by Purtscher-like retinopathy treated with intravenous pulse methylprednisolone and tocilizumab, *Case Rep. Ophthalmol.* 12 (2) (2021 Jun 11) 531–537.
- [25] A.A. Tang, A.L. Lin, Purtscher-like retinopathy in adult-onset Still's disease, complicated by treatment-related central serous chorioretinopathy, *Am. J. Ophthalmol. Case Rep.* 25 (18) (2020 Feb), 100631.
- [26] M. Ustaoglu, F. Onder, N. Solmaz, S. Öztürk, M. Ayer, Purtscher-like retinopathy associated with atypical hemolytic uremic syndrome, *Turk. J. Ophthalmol.* 47 (6) (2017 Dec) 348–350.
- [27] J.E. Ramos de Carvalho, R.O. Schlingemann, M. Oranje, F.J. Bemelman, M.J. van Schooneveld, Reversal of threatening blindness after initiation of eculizumab in purtscher-like retinopathy secondary to atypical hemolytic uremic syndrome, *Int. Ophthalmol.* 38 (1) (2018 Feb) 399–407.
- [28] A. Chebil, R. Mammouri, M.B. Abdallah, L. El Matri, Purtscher-like retinopathy as a rare presentation of cryoglobulinemia, *Middle East Afr. J. Ophthalmol.* 23 (2) (2016 Apr-Jun) 219–221.
- [29] A. Sauer, X. Nasica, F. Zorn, P. Petitjean, P. Bader, C. Speeg-Schatz, P. Lenoble, Cryoglobulinemia revealed by a Purtscher-like retinopathy, *Clin. Ophthalmol.* 1 (4) (2007 Dec) 555–557.

- [30] C.C. Awh, B.S. Modjtahedi, D. Elliott, Purtscher's retinopathy as the presenting manifestation of immune thrombocytopenic purpura, *Am. J. Ophthalmol. Case Rep.* 9 (6) (2017 Mar) 77–80.
- [31] L.J. Pek Seng Ang, B. Chong Ming Chang, Purtscher-like retinopathy - a rare complication of acute myocardial infarction and a review of the literature, *Saudi J. Ophthalmol.* 31 (4) (Oct-Dec 2017) 250–256.
- [32] S.C. İpek, A. Yaman, S. Men, A.O. Saatci, Unilateral purtscher-like retinopathy as the presenting feature of a case with spontaneous carotid artery dissection, *Clin. Case Rep.* 9 (5) (2020 Dec 5), e03633.
- [33] E. Oshida, S. Machida, T. Nishimura, M. Sakamoto, Purtscher-like retinopathy associated with cerebro- or cardiovascular surgery, *Am. J. Ophthalmol. Case Rep.* 7 (8) (2017 Oct) 62–66.
- [34] E.Z. Rahman, P. Shah, J.E. Ong, M. Goldberg, S.S. Ong, Purtscher-like retinopathy in a patient with COVID-19 and disseminated intravascular coagulation, *Am. J. Ophthalmol. Case Rep.* 24 (2021 Dec), 101229.
- [35] A.R. Bottini, S. Steinmetz, K.J. Blinder, G.K. Shah, Purtscher-like retinopathy in a patient with COVID-19, *Case Rep. Ophthalmol. Med.* 20 (2021) (2021 Mar), 6661541.
- [36] A. Dwivedi, D. Dwivedi, C. Chalisgaonkar, S. Lakhtakia, Purtscher-like retinopathy: a rare ocular finding in nephrotic syndrome, *Oman J. Ophthalmol.* 11 (1) (2018 Jan-Apr) 42–45.
- [37] V.D. Stoumbos, M.L. Klein, S. Goodman, Purtscher's-like retinopathy in chronic renal failure, *Ophthalmology* 99 (12) (1992 Dec) 1833–1839.
- [38] G. Slater, S.E. Goldblum, A.H. Tzamaloukas, W.L. Jones, R.T. Goldhahn, Renal cortical necrosis and Purtscher's retinopathy in hemorrhagic pancreatitis, *Am. J. Med. Sci.* 288 (1) (Jul-Aug 1984) 37–39.
- [39] Z.X. Huang, Z.B. Zeng, Z.P. Xu, Purtscher-like retinopathy associated with antibiotic anaphylaxis, *Nan Fang Yi Ke Da Xue Xue Bao* 38 (3) (2018 Mar 20) 239–242.
- [40] Y. Ozdamar Erol, M. Inanc, Purtscher-like retinopathy with serous macular detachment in pre-eclampsia, *Oxf Med Case Rep.* 2018 (11) (2018), omx086. Oct 8.
- [41] D. Cernea, A. Dragoescu, M. Novac, HELLP syndrome complicated with postpartum subcapsular ruptured liver hematoma and purtscher-like retinopathy, *Case Rep. Obstet. Gynecol.* 2012 (2012), 856135.
- [42] A. Agrawal, M.A. McKibbin, Purtscher's and Purtscherlike retinopathies: a review, *Surv. Ophthalmol.* 51 (2) (2006) 129–136.
- [43] C. Atabay, T. Kansu, G. Nurlu, Late visual recovery after intravenous methylprednisolone treatment of Purtscher's retinopathy, *Ann. Ophthalmol.* 25 (9) (1993) 330–333.
- [44] D.E. Hammerschmidt, J.G. White, P.R. Craddock, H.S. Jacob, Corticosteroids inhibit complement-induced granulocyte aggregation. A possible mechanism for their efficacy in shock states, *J. Clin. Invest.* 63 (4) (1979) 798–803.