

 **Review Article** 

Updates on Ultrasonography Imaging in Abdominal Aortic Aneurysm


Shinichi Iwakoshi, MD, Toshiko Hirai, MD, and Kimihiko Kichikawa, MD

Abdominal aortic aneurysms (AAAs) are life-threatening and are associated with >80% mortality when they rupture. Therefore, detecting these aneurysms before they rupture is critical. Ultrasonography is a non-invasive tool that is used for screening AAAs by measuring abdominal aorta diameter. A recent meta-analysis demonstrated the positive effects of ultrasonography. To date, aneurysm diameter is the most reliable predictor for aneurysm rupture and is used as a criterion for surgical intervention. However, some AAAs rupture at small diameters. Therefore, a better predictor for AAA rupture that is independent of aneurysm diameter is needed. Recently, an aortic wall strain examined using ultrasonography has been reported to have a potential in predicting AAA rupture. Since the introduction of endovascular aneurysm repair (EVAR), a paradigm shift has occurred in the management of AAAs. EVAR is broadly spread with the advantage of early favorable results but with concerning endoleak complications. At present, computed tomography angiography (CTA) is considered to be a gold standard for surveillance following EVAR, but it encounters some problems, such as contrast usage or radiation exposure. Ultrasonography offers an examination free from these problems and can this be an alternative to CTA. In this review article, current trends and new technologies regarding AAA assessment using ultrasonography are introduced.

Keywords: abdominal aortic aneurysm, ultrasound, screening, endoleak

Department of Radiology, Nara Medical University, Kashihara, Nara, Japan

Received: May 21, 2019; Accepted: May 22, 2019
Corresponding author: Toshiko Hirai, MD. Department of Radiology, Nara Medical University, 840 Shijo-cho, Kashihara, Nara 634-8521, Japan
Tel: +81-744-29-8900, Fax: +81-744-24-1988
E-mail: thirai@naramed-u.ac.jp

 ©2019 The Editorial Committee of Annals of Vascular Diseases. This article is distributed under the terms of the Creative Commons Attribution License, which permits use, distribution, and reproduction in any medium, provided the credit of the original work, a link to the license, and indication of any change are properly given, and the original work is not used for commercial purposes. Remixed or transformed contributions must be distributed under the same license as the original.

Introduction

Abdominal aortic aneurysms (AAAs) are an important cause of morbidity. At present, ultrasonography has two applications: for disease detection and surveillance following endovascular treatment due to its inherent characteristic advantages, including being non-invasive, non-iodinated contrast usage, and radiation-free exposure. We have divided the manuscript into two parts, detection and prediction and post-treatment surveillance, to introduce and highlight the current and future role of ultrasonography in each application.

Disease Detection

AAA screening using ultrasonography

Randomized control trials (RCTs) designed to investigate the efficacy of ultrasonography for AAAs in males started in the 1990s. To date, late outcomes of these trials over 10 years have been published.

One review article reported a meta-analysis of the long-term results of >13 years of follow-up from four randomized controlled trials of AAA screening in males >64 years old.¹⁾ The article concluded that inviting males for screening significantly reduced AAA-related mortality (odds ratio [OR]: 0.66; 95% confidence interval [CI]: 0.47–0.93; P=0.02) but did not reduce non-AAA-related mortality (OR: 1.00; 95%CI: 0.98–1.02; P=0.96). Moreover, invitation to screening also significantly reduced all-cause mortality according to time-to-event data (hazard ratio: 0.98; 95%CI: 0.96–0.99; P=0.003) and caused no reduction according to dichotomous data (OR: 0.99; 95%CI: 0.96–1.01; P=0.23). The United States Preventive Services Task Force recommends using ultrasonography for AAA in males aged 65–74 who have ever smoked.

One-time surveillance showed long favorable results and saved people from AAA-related deaths. However, a concern on the long-term follow-up has been raised. Compared with the early results of the UK Multicentre Aneurysm Screening Study, mortality benefit was slightly less in the long follow-up.²⁾ This “late catch-up” phenomenon could be attributed to the ruptured AAA in males originally screened as normal, with a baseline aortic

diameter in the range of 2.5–2.9 cm. Half the ruptured AAA cases in the invited group were reported to occur in males diagnosed as “normal.” Thompson et al.²⁾ suggested a significant solution to reduce late ruptures in the future by lowering the threshold of screening to 2.5 cm from the original threshold of 3.0 cm. Then, they proposed to recall all men with a baseline aortic diameter in the range of 2.5–2.9 cm only after, for example, 5 years in the first instance because the chance of developing an AAA >5.5 cm or having an AAA rupture before that time is very small. Although this suggestion seems reasonable, it should be discussed in terms of cost effectiveness.

Method of AAA measurement

The Japan Society of Ultrasonics in Medicine recommends an AAA measurement method. For a fusiform aneurysm, aneurysm diameter is defined as the measure of the maximum short diameter on the short-axis view, whereas for a saccular aneurysm, the major axis is recommended. Both measurements are based on external aortic diameter.

However, the measurement method used has varied in different trials. One study adopted the internal aortic diameter,³⁾ whereas another adopted the external aortic diameter.⁴⁾ Consequently, readers should pay attention to differences in the measurement method in comparing the outcomes between studies.

Other predictors for aneurysm rupture independent of aneurysm diameter

At present, the only established predictor for aneurysm rupture is aortic aneurysm diameter. An AAA diameter >50 mm has a rupture risk of 1.0%–11% per year, which justifies surgical treatments, including endovascular aneurysm repair (EVAR) for patients with this condition. However, AAA growth is nonlinear and rupture can occur in aneurysms with small diameter. Consequently, some attempts have been made to investigate other factors associated with AAA rupture, which include being female, smoking, hypertension, AAA expansion rate, and AAA wall shear stress. These factors appear to have less convincing supporting evidence compared with AAA diameter but might be important for considering the management of patients.

Aneurysm rupture occurs as a result of mechanical failure of the vascular wall at the point where aortic wall stress becomes higher than the tensile strength of the vascular tissue.⁵⁾ Whether aortic wall stress is associated with AAA rupture risk is worth investigating. At present, ultrasonography has been utilized to analyze aortic wall stress via the observation of aortic wall motions. Bihari et al.⁵⁾ analyzed strain parameters using three-dimensional ultrasonography in five patients with AAA. They identified strong local differences in the aortic wall strain, suggesting

that the strain parameters of AAA were heterogeneous. Derwich et al.⁶⁾ investigated the spatial distribution of circumferential wall strain using four-dimensional ultrasonography and compared it between patients >60 years of age with normal aortic diameters to those with infrarenal aortic aneurysm. Their results demonstrated that spatial distribution of circumferential wall strain was significantly higher in the AAA group. These two studies consistently prove the heterogeneity of aortic wall strain in AAA. As the discrepancy of wall strain becomes larger, the peak strain may increase, which is a result of local weakening of the AAA wall, where the AAA wall deforms more significantly than that at other sites. Therefore, peak strain or high heterogeneity of the wall strain may have a potential to predict the rupture risk of AAA. Although the reports introduced above consist of small series and single-center experiences, these insights may have the potential to change clinical practices.

Surveillance Following EVAR

Long-term outcomes following EVAR

Since the application of EVAR to treat AAA, several papers have reported its effectiveness and safety. Given the favorable perioperative and postoperative results of some RCTs that compared EVAR to open surgical repairs, the adoption of EVAR has been widespread. Recently, long-term follow-up (up to 15 years) of original RCTs have been published, which show that EVAR has an early survival benefit but an inferior late survival as compared with open repair.⁷⁾ In particular, type II endoleak is associated with these late unfavorable outcomes. A meta-analysis of 45 studies with a total of 36,588 participants reported that the pooled prevalence of type II endoleaks after EVAR was 22% (95% CI: 19%–25%).⁸⁾ Lifelong surveillance of EVAR is mandatory, which provokes a discussion on a suitable modality.

Computed tomography angiography (CTA) is considered a gold standard technique to survey patients following EVAR. However, CTA has some disadvantages due to radiation exposure and radiocontrast nephropathy. Ultrasonography, including contrast-enhanced ultrasonography (CEUS), can be an alternative technique. In the next part, we introduce studies comparing CTA and ultrasonography.

Surveillance after EVAR using ultrasonography

Recently, a review paper regarding ultrasonography for surveillance after EVAR has been published by Brazzelli et al.,⁹⁾ in which a systematic review of RCTs and cohort studies of patients with AAAs who were receiving surveillance using CTA, color-duplex ultrasonography (CDU), and CEUS with or without plain radiography was

conducted. They found two non-randomized comparative studies, 25 cohort studies of interventions, and nine systematic reviews of diagnostic accuracy. Chisci et al.¹⁰ reported one of the non-randomized comparative studies and compared CTA and CDU surveillance at 1 month after EVAR and at every 6 months thereafter (Protocol I; 376 participants) with CTA and CDU at 1 month after EVAR and CDU and radiography at every 6 months thereafter (Protocol II; 341 participants). Their analysis found no evidence of a difference between the two protocols with regard to early and late reinterventions and mortality. A higher proportion of graft kinking was identified by Protocol II as compared with Protocol I (3.0% vs. 1.3%; $P=0.050$) possibly due to the ease of radiography to overview the entire stent graft. Given these large data,

surveillance using ultrasonography seems to be favorable in conjunction with radiography.

Further possibility of ultrasonography

As described above, the meta-analysis proved the non-inferiority of ultrasonography when compared with CTA. In fact, CEUS examination outweighs CTA in some respects. Some papers reported “false positive” endoleaks, which are endoleaks that are not detected on CTA but are detected on ultrasonography, including the “slow endoleak,” which can only be detected in the super-delayed phase on CTA.¹¹ Given the nature of this endoleak, CTA with inadequate delay time after contrast injection cannot identify this endoleak where CEUS has demonstrated successful identification. In addition, differences in contrast

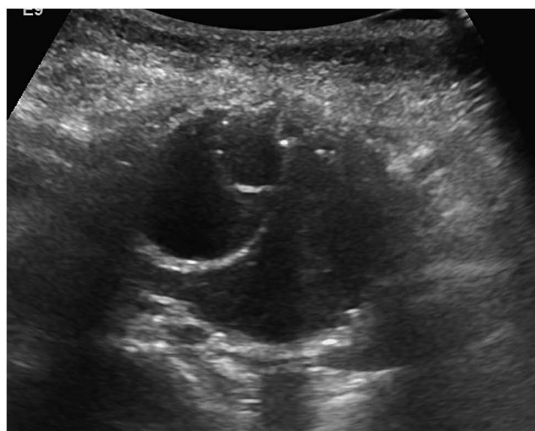


Fig. 1 Ultrasound image (B mode) of the slow endoleak case. This image demonstrates a large abdominal aortic aneurysm and stent graft.

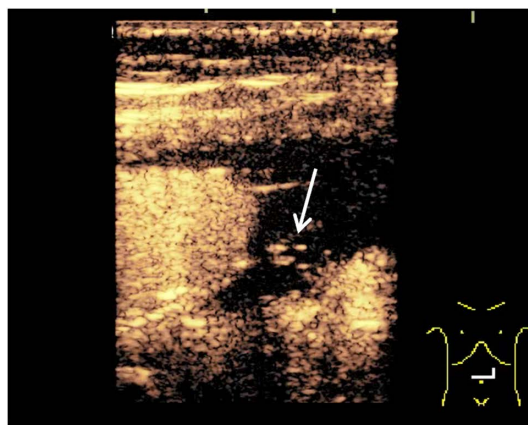


Fig. 3 Contrast-enhanced ultrasound image of the slow endoleak case at 2 min after injection of the contrast material. A small amount of the contrast material is detected (white arrow) in the aneurysm sac.

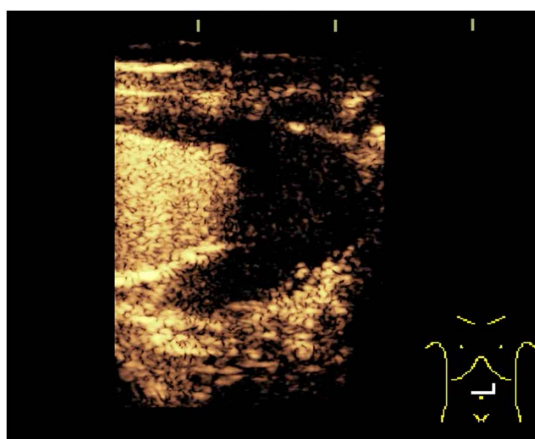


Fig. 2 Contrast-enhanced ultrasound image of the slow endoleak case at 30s after injection of the contrast material. No contrast material is visualized in the aneurysm except in the stent graft.

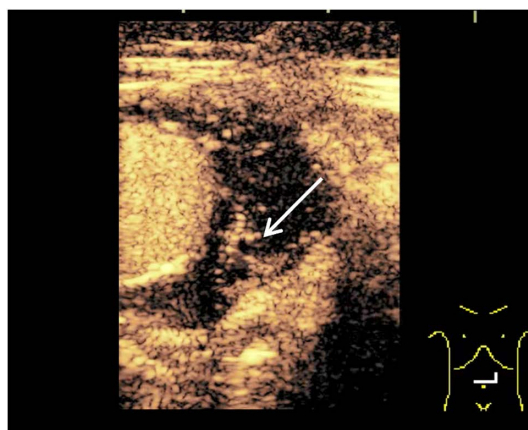


Fig. 4 Contrast-enhanced ultrasound image of the slow endoleak case at 7 min after injection of the contrast material. A larger amount of the contrast material is seen in the aneurysm sac as compared with 2 min, which suggests a slow endoleak.

resolution between CTA and CEUS may also contribute to the detectability of a slow endoleak. Although the contrast density of iodinated contrast material used for CTA dilutes over time, the resolution of the micro bubbles used for CEUS remains high even when the agent becomes diluted. We encountered a patient with a similar endoleak and an interesting clinical course.

The patient was a 70-year-old woman who underwent EVAR 3 years before and experienced AAA expansion during follow-up. Her renal function was too poor to perform CTA; therefore, CEUS using micro bubbles was conducted, which demonstrated a major endoleak located dorsal to the stent graft. This endoleak was observed from 2 min after injection to 10 min after injection as the contrast material became denser, which could have been missed in an early phase of CTA (Figs. 1–4). The patient had a previous history of cerebral infarction and was taking an antiplatelet drug. After discussion with her neurosurgeon, antiplatelet drug administration was terminated due to which sac expansion stopped.

Conclusion

At present, with several technical developments and established studies, ultrasonography is emerging as a key non-invasive technology for AAAs before and after treatments. Vascular specialists should update their knowledge and incorporate new technologies into their clinical practice.

Disclosure Statement

The authors declare no potential conflicts of interest with respect to the research, authorship, and/or publication of this article.

Author Contributions

Study conception: TH

Data collection: SI

Analysis: SI

Investigation: SI

Writing: SI

Funding acquisition: none

Critical review and revision: all authors

Final approval of the article: all authors

Accountability for all aspects of the work: all authors

References

- 1) Takagi H, Ando T, Umemoto T. Abdominal aortic aneurysm screening reduces all-cause mortality: make screening great again. *Angiology* 2018; **69**: 205-11.
- 2) Thompson SG, Ashton HA, Gao L, et al. Final follow-up of the Multicentre Aneurysm Screening Study (MASS) randomized trial of abdominal aortic aneurysm screening. *Br J Surg* 2012; **99**: 1649-56.
- 3) Darwood R, Earnshaw JJ, Turton G, et al. Twenty-year review of abdominal aortic aneurysm screening in men in the county of Gloucestershire, United Kingdom. *J Vasc Surg* 2012; **56**: 8-13.
- 4) Hafez H, Druce PS, Ashton HA. Abdominal aortic aneurysm development in men following a "normal" aortic ultrasound scan. *Eur J Vasc Endovasc Surg* 2008; **36**: 553-8.
- 5) Bihari P, Shelke A, Nwe TH, et al. Strain measurement of abdominal aortic aneurysm with real-time 3D ultrasound speckle tracking. *Eur J Vasc Endovasc Surg* 2013; **45**: 315-23.
- 6) Derwich W, Wittek A, Pfister K, et al. High resolution strain analysis comparing aorta and abdominal aortic aneurysm with real time three dimensional speckle tracking ultrasound. *Eur J Vasc Endovasc Surg* 2016; **51**: 187-93.
- 7) Patel R, Sweeting MJ, Powell JT, et al. Endovascular versus open repair of abdominal aortic aneurysm in 15-years' follow-up of the UK endovascular aneurysm repair trial 1 (EVAR trial 1): a randomised controlled trial. *Lancet* 2016; **388**: 2366-74.
- 8) Guo Q, Du X, Zhao J, et al. Prevalence and risk factors of type II endoleaks after endovascular aneurysm repair: a meta-analysis. *PLoS ONE* 2017; **12**: e0170600.
- 9) Brazzelli M, Hernández R, Sharma P, et al. Contrast-enhanced ultrasound and/or colour duplex ultrasound for surveillance after endovascular abdominal aortic aneurysm repair: a systematic review and economic evaluation. *Health Technol Assess* 2018; **22**: 1-220.
- 10) Chisci E, Setacci F, Iacoponi F, et al. Surveillance imaging modality does not affect detection rate of asymptomatic secondary interventions following EVAR. *Eur J Vasc Endovasc Surg* 2012; **43**: 276-81.
- 11) Chung J, Kordzadeh A, Prionidis I, et al. Contrast-enhanced ultrasound (CEUS) versus computed tomography angiography (CTA) in detection of endoleaks in post-EVAR patients. Are delayed type II endoleaks being missed? A systematic review and meta-analysis. *J Ultrasound* 2015; **18**: 91-9.