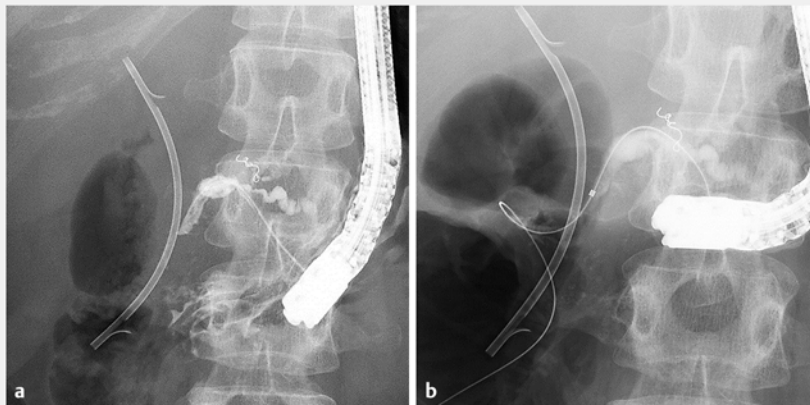
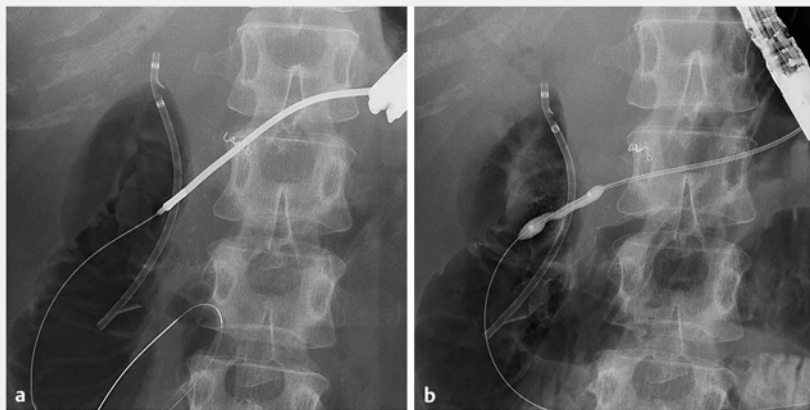


## Pancreatic duct stenting using an endoscopic ultrasound-guided intrapancreatic duct rendezvous technique

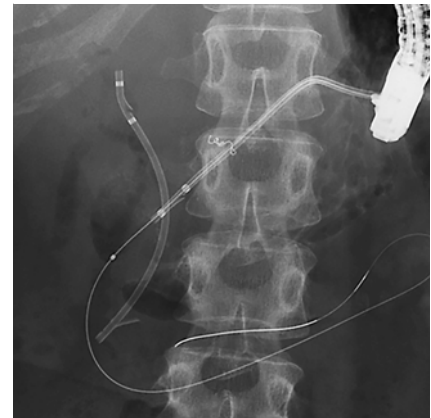OPEN  
ACCESS



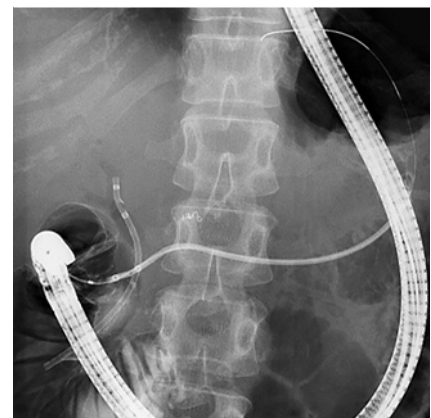► **Fig. 1** Guidewire placement. **a** The pancreatic duct was cannulated through the fistula created via the endoscopic ultrasound-guided pancreatic duct drainage. **b** The guidewire passed through the pancreatic duct stricture and was placed in the duodenum via the minor papilla.



► **Fig. 2** The pancreatic stricture was dilated using the dilators via the fistula of endoscopic ultrasound-guided pancreatic duct drainage. **a** 7-Fr stent retriever. **b** 6-mm balloon catheter.



► **Fig. 3** The plastic stent could only be inserted halfway through the stricture and could not be placed across the minor papilla.

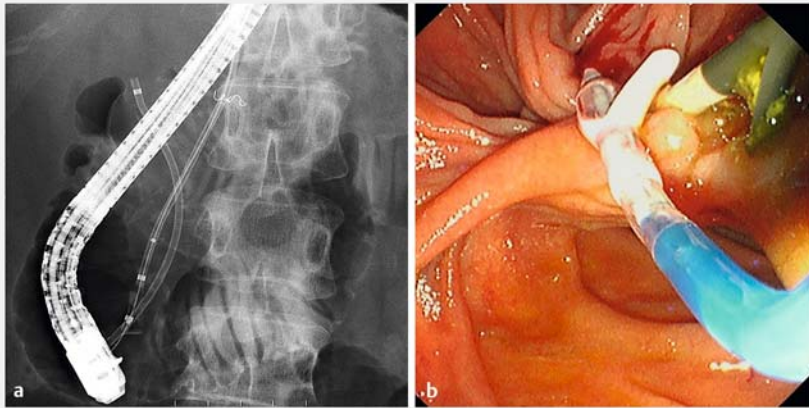


► **Fig. 4** The pancreatic duct was cannulated via the minor papilla, and the guidewire was inserted into the stent lumen, which was placed via the fistula in an antegrade manner.

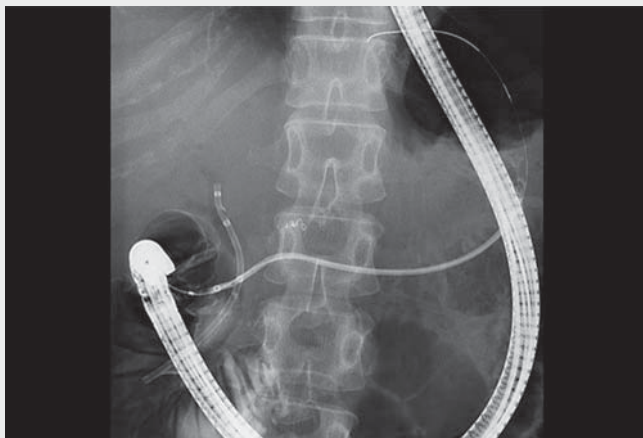
A patient was admitted for pancreatic stenting for pancreatic duct stricture due to chronic pancreatitis. However, transpapillary stenting failed because a guidewire could not pass the severe stricture in the pancreatic head. Therefore, endoscopic ultrasound-guided pancreatic duct drainage (EUS-PD) was conducted by puncture from the stomach,

and a plastic stent was placed on the caudal side of the stricture [1,2]. Following EUS-PD fistula creation, the pancreatic duct was cannulated through the fistula (► **Fig. 1 a**), and the guidewire passed through the stricture and was placed in the duodenum via the minor papilla (► **Fig. 1 b**). The endoscope was withdrawn leaving the guidewire in

place, followed by duodenoscope insertion into the duodenum. Pancreatic duct cannulation and endoscopic pancreatic sphincterotomy were performed using a rendezvous technique [3]; however, the cannula and dilators could not pass the stricture. Therefore, we again switched to the procedure via the EUS-PD fistula, and a 7-Fr stent retriever allowed the



► **Fig. 5** The plastic stent was successfully placed across the minor papilla by pulling the balloon catheter inflated within the stent. **a** Fluoroscopic view. **b** Endoscopic view.



► **Video 1** Pancreatic duct stenting using an endoscopic ultrasound-guided intrapancreatic duct rendezvous technique.

breakthrough of the stricture [4] (► **Fig. 2a**), followed by dilation of the stricture with a 6-mm balloon catheter (► **Fig. 2b**). However, the plastic stent (7 Fr; SUZAKU, Kaneka Medics, Tokyo, Japan) could only be inserted to the midpoint of the stricture (► **Fig. 3**). Therefore, the pancreatic duct was cannulated via the minor papilla, and the guidewire was inserted into the stent lumen (► **Fig. 4**). Subsequently, a thin-tipped balloon catheter (4 mm; REN; Kaneka Medics) was inserted into the stent over the guidewire, and the balloon was inflated. Finally, the balloon catheter was pulled, and the stent was successfully placed across the minor papilla (► **Fig. 5a,b**).

Stent insertion might fail owing to difficulty in advancing the stent through a severe stricture in EUS-guided antegrade stenting [5]. In such a situation, the abovementioned intrapancreatic duct rendezvous technique can be useful (► **Video 1**).

Endoscopy\_UCTN\_Code\_TTT\_1AS\_2AD

### Competing interests

The authors declare that they have no conflict of interest.

### The authors

**Kazunari Nakahara**, **Yosuke Michikawa**, **Junya Sato**, **Yosuke Igarashi**, **Akihiro Sekine**, **Yusuke Satta**, **Keisuke Tateishi**

Department of Gastroenterology, St. Marianna University School of Medicine, Kawasaki, Japan

### Corresponding author

**Kazunari Nakahara, PhD**

Department of Gastroenterology,  
St. Marianna University School of Medicine,  
2-16-1 Sugao, Miyamae-ku, Kawasaki 216-  
8511, Japan  
nakahara@marianna-u.ac.jp

### References

- [1] François E, Kahaleh M, Giovannini M et al. EUS-guided pancreaticogastrostomy. *Gastrointest Endosc* 2016; 56: 128–133
- [2] Itoi T, Sofuni A, Tsuchiya T et al. Initial evaluation of a new plastic pancreatic duct stent for endoscopic ultrasonography-guided placement. *Endoscopy* 2015; 47: 462–465
- [3] Bataille L, Deprez P. A new application for therapeutic EUS: main pancreatic duct drainage with a “pancreatic rendezvous technique”. *Gastrointest Endosc* 2002; 55: 740–743
- [4] Baron TH, Morgan DE. Dilation of a difficult benign pancreatic duct stricture using the Soehendra stent extractor. *Gastrointest Endosc* 1997; 46: 178–180
- [5] Itoi T, Kasuya K, Sofuni A et al. Endoscopic ultrasonography-guided pancreatic duct access: techniques and literature review of pancreatography, transmural drainage and rendezvous techniques. *Dig Endosc* 2013; 25: 241–252

### Bibliography

*Endoscopy* 2022; 54: E954–E955

DOI 10.1055/a-1882-4799

ISSN 0013-726X

published online 21.7.2022

© 2022. The Author(s).

This is an open access article published by Thieme under the terms of the Creative Commons Attribution-NonDerivative-NonCommercial License, permitting copying and reproduction so long as the original work is given appropriate credit. Contents may not be used for commercial purposes, or adapted, remixed, transformed or built upon. (<https://creativecommons.org/licenses/by-nc-nd/4.0/>)

Georg Thieme Verlag KG, Rüdigerstraße 14,  
70469 Stuttgart, Germany

